



# IAP Color Atlas of PEDIATRICS

*Editor-in-Chief*  
**A Parthasarathy**

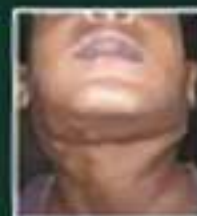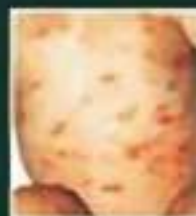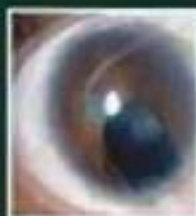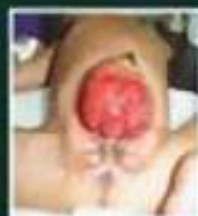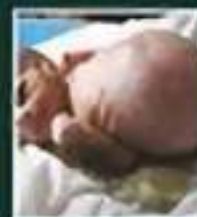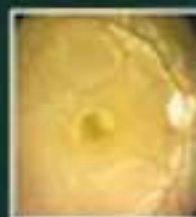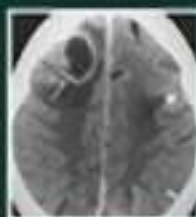
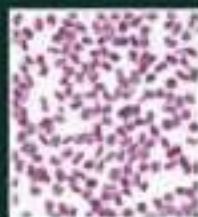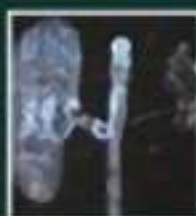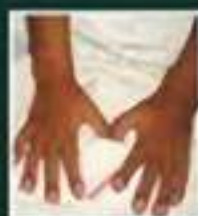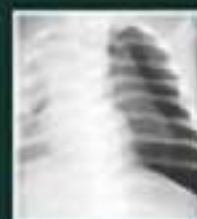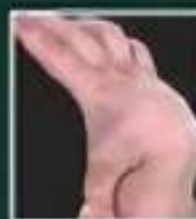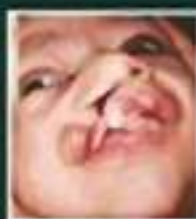*Chief Academic Editor*  
**Rohit Agrawal**

*Academic Editors*  
**Nitin K Shah**  
**Vijay N Yewale**

*Executive Editors*  
**Piyush Gupta**  
**Ritabrata Kundu**  
**Digant Shastri**

*Ex-Officio Editors*  
**TU Sukumaran**  
**Deepak Ugra**  
**Tanmay Amladi**  
**Sailesh Gupta**

*Publication Editor*  
**Dhanya Dharmapalan**



*A Publication of Indian Academy of Pediatrics*

**JAYPEE**

Printed by  
*Dr. Prodigious*

**IAP**  
Color Atlas of  
**PEDIATRICS**



A Publication of Indian Academy of Pediatrics

# IAP

# Color Atlas of

# PEDIATRICS



#### *Editor-in-Chief*

#### **A Parthasarathy**

Distinguished Professor  
The Tamil Nadu Dr MGR Medical University  
Retd Senior Clinical Professor of Pediatrics  
Madras Medical College  
Deputy Superintendent  
Institute of Child Health and Hospital for Children  
Chennai, Tamil Nadu, India

#### *Chief Academic Editor*

#### **Rohit Agrawal**

Director and Consultant Pediatrician  
Chandrajyoti Children Hospital, Mumbai  
Visiting Consultant, Kohinoor Hospital  
Mumbai, Maharashtra, India

#### *Academic Editors*

#### **Nitin K Shah**

Consultant Pediatrician  
PD Hinduja Hospital for Children  
Honorary Hemato-Oncologist  
BJ Wadia Hospital and Lion's Hospital  
Mumbai, Maharashtra, India

#### **Vijay N Yewale**

Director and Consultant Pediatrician  
Dr Yewale's Multispecialty Hospital for Children  
Sector 9, Vashi, Maharashtra, India  
Honorary Pediatric Consultant  
Mathadi Trust Hospital, Navi Mumbai  
Maharashtra, India

#### *Executive Editors*

#### **Piyush Gupta**

Professor of Pediatrics  
University College of Medical Sciences  
New Delhi, India

#### **Ritabrata Kundu**

Professor of Pediatrics  
Institute of Child Health  
Kolkata, West Bengal, India

#### **Digant Shastri**

CEO and Chief Pediatrician  
Killol Children Hospital and NICU  
Majuragate, Surat,  
Maharashtra, India

#### *Ex-Officio Editors*

#### **TU Sukumaran**

Professor of Pediatrics  
PIMS, Thiruvalla, Kerala, India

#### **Deepak Ugra**

Consultant Pediatrician  
Lilavati Hospital, Mumbai, Maharashtra, India

#### **Tanmay Amladi**

Honorary Head  
Department of Neonatology  
Wadia Hospital  
Mumbai, Maharashtra, India

#### **Sailesh Gupta**

Consultant Pediatrician  
Arushree Childcare Hospital  
Malad, Mumbai, Maharashtra, India

#### *Publication Editor*

#### **Dhanya Dharmapalan**

Consultant Pediatrician  
Dr Yewale's Multispecialty Hospital for Children  
Navi Mumbai, Maharashtra, India  
Dharmapalan's Clinic  
Tilak Nagar, Mumbai, Maharashtra, India

#### *Forewords*

#### **Rohit Agrawal**

#### **TU Sukumaran**



**JAYPEE BROTHERS MEDICAL PUBLISHERS (P) LTD**

New Delhi • Panama City • London



## Jaypee Brothers Medical Publishers (P) Ltd.

### Headquarter

Jaypee Brothers Medical Publishers (P) Ltd  
4838/24, Ansari Road, Daryaganj  
New Delhi 110 002, India  
Phone: +91-11-43574357  
Fax: +91-11-43574314  
Email: [jaypee@jaypeebrothers.com](mailto:jaypee@jaypeebrothers.com)

### Overseas Offices

J.P. Medical Ltd.  
83 Victoria Street, London  
SW1H 0HW (UK)  
Phone: +44-2031708910  
Fax: +02-03-0086180  
Email: [info@jpmedpub.com](mailto:info@jpmedpub.com)

Jaypee-Highlights Medical Publishers Inc.  
City of Knowledge, Bld. 237, Clayton  
Panama City, Panama  
Phone: +507-301-0496  
Fax: +507-301-0499  
Email: [cservice@jphmedical.com](mailto:cservice@jphmedical.com)

Website: [www.jaypeebrothers.com](http://www.jaypeebrothers.com)  
Website: [www.jaypeedigital.com](http://www.jaypeedigital.com)

© 2012, Authors and Publishers

All rights reserved. No part of this book may be reproduced in any form or by any means without the prior permission of the Authors/Publishers.

**Inquiries for bulk sales may be solicited at:** [jaypee@jaypeebrothers.com](mailto:jaypee@jaypeebrothers.com)

This book has been published in good faith that the contents provided by the contributors contained herein are original, and is intended for educational purposes only. While every effort is made to ensure accuracy of information, the publisher and the author specifically disclaim any damage, liability, or loss incurred, directly or indirectly, from the use or application of any of the contents of this work.

***IAP Color Atlas of Pediatrics (A Publication of Indian Academy of Pediatrics)***

*First Edition: 2012*

ISBN 978-93-5025-710-4

Printed at

**Dedicated to**

*The Parents of the suffering Tiny Tots who successfully protected them from the clutches of malnutrition and vaccine preventable diseases but could not succeed in protecting them from congenital malformations, metabolic, endocrine and genetic disorders*

# Contributors

---

## *Editor-in-Chief*

### **A Parthasarathy**

Distinguished Professor  
The Tamil Nadu Dr MGR Medical University  
Retd Senior Clinical Professor of Pediatrics  
Madras Medical College  
Deputy Superintendent  
Institute of Child Health and Hospital for Children  
Chennai, Tamil Nadu, India

## *Chief Academic Editor*

### **Rohit Agrawal**

Director and Consultant Pediatrician  
Chandrajyoti Children Hospital  
Visiting Consultant, Kohinoor Hospital  
Mumbai, Maharashtra, India

## *Academic Editors*

### **Nitin K Shah**

Consultant Pediatrician  
PD Hinduja Hospital for Children  
Honorary Hemato-Oncologist  
BJ Wadia Hospital and Lion's Hospital  
Mumbai, Maharashtra, India

### **Vijay N Yewale**

Director and Consultant Pediatrician  
Dr Yewale's Multispecialty Hospital for Children  
Sector 9, Vashi, Navi Mumbai, Maharashtra, India  
Honorary Pediatric Consultant  
Mathadi Trust Hospital, Navi Mumbai  
Maharashtra, India

## *Executive Editors*

### **Piyush Gupta**

Professor of Pediatrics  
University College of Medical Sciences  
New Delhi, India

### **Ritabrata Kundu**

Professor of Pediatrics  
Institute of Child Health  
Kolkata, West Bengal, India

### **Digant Shastri**

CEO and Chief Pediatrician  
Killol Children Hospital and NICU  
Majuragate, Surat  
Maharashtra, India

## *Ex-Officio Editors*

### **TU Sukumaran**

Professor of Pediatrics  
PIMS, Thiruvalla, Kerala, India

### **Deepak Ugra**

Consultant Pediatrician  
Lilavati Hospital  
Mumbai, Maharashtra, India

### **Tanmay Amladi**

Honorary Head  
Department of Neonatology  
Wadia Hospital  
Mumbai, Maharashtra, India

### **Sailesh Gupta**

Consultant Pediatrician  
Arushree Childcare Hospital  
Malad, Mumbai, Maharashtra, India

## *Publication Editor*

### **Dhanya Dharmapalan**

Consultant Pediatrician  
Dr Yewale's Multispecialty Hospital for Children  
Navi Mumbai, Maharashtra, India  
Dharmapalan's Clinic  
Tilak Nagar, Mumbai, Maharashtra, India

---

## SECTION 1: NEONATOLOGY

---

## *Editors*

### **Rhishikesh Thakre**

Professor  
Department of Pediatrics  
MGM Medical College and Hospital  
N5 Cidco, Aurangabad, Maharashtra, India  
[rhishikesht@gmail.com](mailto:rhishikesht@gmail.com)

### **Ruchi Nanavati**

Professor and Head  
Department of Neonatology  
Seth GS Medical College and KEM Hospital  
Mumbai, Maharashtra, India  
[drruchinanavati@gmail.com](mailto:drruchinanavati@gmail.com)

## SECTION 2: GROWTH AND DEVELOPMENT

---

*Editors*

### **KN Agarwal**

President

Health Care and Research Association for Adolescents  
D-115, Sector-36, Noida, Uttar Pradesh, India  
*adolcare@hotmail.com*

### **MKC Nair**

Director

Child Development Center  
Medical College Campus  
Thiruvananthapuram, Kerala, India  
*cdcmkc@gmail.com*

## SECTION 3: NUTRITION

---

*Editor*

### **Meenakshi Mehta**

Head of Department  
Consultant Pediatrician  
MGM Hospital, Parel

Mumbai, Maharashtra, India  
*meenakshinmehta2011@gmail.com*  
*dr\_meenakshi37@rediffmail.com*

## SECTION 4: INFECTIOUS DISEASES

---

*Editors*

### **Jaydeep Choudhury**

Associate Professor  
Institute of Child Health  
Dr Biresh Guha Street  
Kolkata, West Bengal, India  
*drjaydeep\_choudhury@yahoo.co.in*

### **Nupur Ganguly**

Associate Professor  
Institute of Child Health  
Dr Biresh Guha Street  
Kolkata, West Bengal, India  
*nupur\_diya@yahoo.com*

## SECTION 5: NEUROLOGY

---

*Editors*

### **PAM Kunju**

Professor and Head  
Department of Pediatric Neurology

Government Medical College  
Thiruvananthapuram, Kerala, India  
*drpamkunju@gmail.com*

### **Anoop Verma**

Consulting Pediatrician  
Swapnil Nursing Home and Research Center  
Civil Lines, Raipur, Chhattisgarh, India  
*anoopve@yahoo.com*

## SECTION 6: CARDIOLOGY

---

*Editor*

### **M Zulfikar Ahamed**

Professor and Head  
Department of Pediatric Cardiology  
Government Medical College  
Thiruvananthapuram, Kerala, India  
*zulfikarahamed@gmail.com*

## SECTION 7: PULMONOLOGY

---

*Editors*

### **TU Sukumaran**

Professor of Pediatrics  
PIMS, Thiruvalla, Kerala, India  
*tusukumaran@gmail.com*

### **Devaraj Raichur**

Professor of Pediatrics  
Karnataka Institute of Medical Sciences  
Hubli, Karnataka, India  
*drdevaraj@rediffmail.com*

## SECTION 8: GASTROINTESTINAL SYSTEM AND HEPATOLOGY

---

*Editors*

### **Malathi Sathiyasekaran**

Consultant Pediatric Gastroenterologist  
KKCTH, SMF and Apollo Hospitals  
Chennai, Tamil Nadu, India  
*mal.bwcs@gmail.com*

### **A Riyaz**

Pediatric Gastroenterologist  
Professor and Head of Pediatrics  
Government Medical College  
Calicut, Kerala, India  
*riyazped@gmail.com*

## SECTION 9: NEPHROLOGY

---

*Editor*

### **Pankaj Deshpande**

Consultant Pediatric Nephrologist  
Hinduja Hospital, Mahim  
Veer Savarkar Marg  
Dr Yewale's Hospital, Sector-9, Vashi  
Navi Mumbai, Maharashtra, India  
[ajinkyapl@hotmail.com](mailto:ajinkyapl@hotmail.com)

## SECTION 10: HEMATOLOGY

---

*Editors*

### **MR Lokeshwar**

Consultant Pediatrician and Pediatric Hematologist  
of Lilavati Hospital and Research Center  
Bandra(W), Mumbai, Maharashtra, India  
Shushrusha Citizen's Cooperative Hospital  
Dadar, Mumbai, Maharashtra, India  
[mrlokeshwar@gmail.com](mailto:mrlokeshwar@gmail.com)

### **Bharat Agarwal**

Head  
Department of Pediatric Hematology and Oncology  
BJ Wadia Hospital for Children, Parel  
Mumbai, Maharashtra, India  
[parulbrat@gmail.com](mailto:parulbrat@gmail.com)

## SECTION 11: ONCOLOGY

---

*Editors*

### **Purna Kurkure**

Professor and Incharge Pediatric Oncology  
Convenor, Pediatric Solid Tumor Group  
Tata Memorial Hospital, Parel  
Mumbai, Maharashtra, India  
[purna.kurkure@gmail.com](mailto:purna.kurkure@gmail.com)

### **Anupama S Borker**

Associate Professor  
Department of Pediatrics  
Kasturba Medical College, Manipal University  
Manipal, Karnataka, India  
[anupama.sb@manipal.edu](mailto:anupama.sb@manipal.edu)  
[dranupamasb@gmail.com](mailto:dranupamasb@gmail.com)

## SECTION 12: ENDOCRINOLOGY

---

*Editors*

### **Vaman Khadilkar**

Pediatric and Adolescent Endocrinologist  
Jehangir Hospital, Pune, Maharashtra, India  
Bombay Hospital  
Mumbai, Maharashtra, India  
Head  
Division of Pediatric Endocrinology  
Bharati Vidyapeeth Medical College, Pune  
Mumbai, Maharashtra, India  
[vamankhadilkar@gmail.com](mailto:vamankhadilkar@gmail.com)

### **PSN Menon**

Consultant and Head  
Department of Pediatrics  
Jaber Al-Ahmed Armed Forces Hospital  
PO Box No 5819, Salmiya 22069, Kuwait  
[psnmenon@hotmail.com](mailto:psnmenon@hotmail.com)  
[psnmenon@yahoo.com](mailto:psnmenon@yahoo.com)

## SECTION 13: GENETICS

---

*Editors*

### **Shubha R Phadke**

Professor  
Department of Medical Genetics  
Sanjay Gandhi Postgraduate Institute of Medical Sciences  
Lucknow, Uttar Pradesh, India  
[shubharaophadke@gmail.com](mailto:shubharaophadke@gmail.com)

### **ML Kulkarni**

Head  
Department of Pediatrics  
JJM Medical College  
Davangere, Karnataka, India  
[kulkarniml@yahoo.com](mailto:kulkarniml@yahoo.com)

## SECTION 14: ALLERGY, RHEUMATOLOGY

---

*Editor for Allergy*

### **Major K Nagaraju**

Senior Consultant in Pediatric Allergy  
and Clinical Immunology  
Kanchi Kamakoti Child Trust Hospital  
Nungambakkam, Chennai  
Tamil Nadu, India  
[majorknr@gmail.com](mailto:majorknr@gmail.com)  
[majorknr@yahoo.co.in](mailto:majorknr@yahoo.co.in)



*Editor for Rheumatology*

**Vijay Viswanathan**

Consultant in Pediatric Rheumatology  
Sandhi Children's Clinic, Unit No 4, Doctor House  
Plot No 101, Sector 21, Nerul (E), Navi Mumbai  
Maharashtra, India  
*dr\_vjay77@yahoo.co.in*  
*drvjayv@gmail.com*

---

**SECTION 15: ADOLESCENT HEALTH  
AND MEDICINE**

---

*Editor*

**Swati Y Bhave**

Senior Visiting Consultant  
Indraprastha Apollo Hospitals  
New Delhi, India  
Executive Director  
AACCI  
CII/47 Shahjahan Road, New Delhi, India  
*sybhave@gmail.com*

---

**SECTION 16: CHILD ABUSE, NEGLECT AND  
CHILD LABOR**

---

*Editor*

**Meenakshi Mehta**

Head of Department  
Consultant Pediatrician  
MGM Hospital, Parel  
Mumbai, Maharashtra, India  
*meenakshinmehta2011@gmail.com*  
*dr\_meenakshi37@rediffmail.com*

---

**SECTION 17: DERMATOLOGY**

---

*Editor*

**Jayakar Thomas**

Professor and Head  
Department of Dermatology and STD  
Sree Balaji Medical College and Hospital  
Chromepet, Chennai, Tamil Nadu, India  
*jayakarthomas@gmail.com*

---

**SECTION 18: OPHTHALMOLOGY**

---

*Editors*

**TS Surendran**

Vice Chairman, Director  
Department of Pediatric Ophthalmology  
President-Strabismological Society of India  
Sankara Nethralaya, 18, College Road  
Nungambakkam, Chennai, Tamil Nadu, India  
*t\_surendran@yahoo.co.uk*

**S Meenakshi**

Senior Consultant  
Department of Pediatric Ophthalmology  
Director-Department of Academics  
Sankara Nethralaya, 18, College Road  
Nungambakkam, Chennai, Tamil Nadu, India  
*drms@snmail.org*

**R Srikanth**

Fellow  
Department of Pediatric Ophthalmology  
Sankara Nethralaya, 18, College Road  
Nungambakkam, Chennai, Tamil Nadu, India  
*dr\_sri1981@yahoo.com*

---

**SECTION 19: OTORHINOLARYNGOLOGY**

---

*Editor*

**Divya Prabhat**

Head  
ENT Department  
BJ Wadia Hospital for Children, Parel  
Mumbai, Maharashtra, India  
Jeevak Hospital, Near Dadar TT  
Mumbai, Maharashtra, India  
*divyaprabhat@gmail.com*  
*www.drdivyaprabhat.com*

---

**SECTION 20: PEDIATRIC SURGERY**

---

*Editors*

**Ketan Parikh**

Consultant Pediatric Surgeon and Pediatric Laparoscopist  
302 Royal Chambers,  
Gulmohar Road, JVPD  
Mumbai, Maharashtra, India  
*Website info: <http://www.pedsurg.in>*  
*<http://www.pedlap.com>*

## **Arbinder Kumar Singal**

Pediatric Urologist and Hypospadiologist  
MGM Hospital, Vashi, Navi Mumbai  
Maharashtra, India  
MITR Urology Center and Hypospadias Foundation  
Kharghar, Navi Mumbai  
Maharashtra, India  
*arbinders@gmail.com*  
*www.hypospadiasfoundation.com*

---

## **SECTION 21: ORTHOPEDICS**

---

### *Editors*

#### **K Sriram**

Consultant Orthopedic Surgeon  
Kanchi Kamakoti Childs Trust Hospital  
Formerly, Professor and Head  
Department of Orthopedics  
Madras Medical College, Chennai, Tamil Nadu, India  
Kanchi Kamakoti Child Trust Hospital  
Nungambakkam, Chennai  
Tamil Nadu, India  
*sriramortho@gmail.com*

#### **Vijay Sriram**

Consultant Orthopedic Surgeon  
Kanchi Kamakoti Child Trust Hospital  
Nungambakkam, Chennai  
Tamil Nadu, India

## **SECTION 22: PEDIATRIC IMAGING**

---

### *Editors*

#### **Nishigandha Burute**

Consultant Radiologist  
Bhaveshwar Vihar  
383, Sardar VP Road  
Mumbai, Maharashtra, India  
*nishirad@gmail.com*

#### **Bhavin Jankharia**

Consultant Radiologist  
President  
SRL Diagnostics-Jankharia Imaging  
Bhaveshwar Vihar  
383, Sardar VP Road  
Mumbai, Maharashtra, India  
*bhavin@jankharia.com*



# Foreword

---

*IAP Color Atlas of Pediatrics* is an innovative attempt of IAP under Presidential Action Plan 2012, envisaged to disseminate academics in a novel pictorial format, for the first time in the history of IAP, probably only second in the world after *Color Atlas of Tropical Pediatrics* by American Academy of Pediatrics (AAP). This mammoth collection of images compiled in an atlas should be a visual treasure in the library of an academician, which should also serve as *ready-reckoner* for a busy practitioner and a boon for postgraduate students as well. I am sure this master creation artfully crafted by a dedicated team of Executive Editors comprising, Drs Vijay N Yewale, Piyush Gupta, Ritabrata Kundu, Digant Shastri and Publication Editor, Dhanya Dharmapalan and the 37 learned Section Editors who are experts in their respective specialty, under the leadership of Dr A Parthasarathy, the Editor-in-Chief, the past President of IAP, who is not only the custodian but crusader of child health. I must admit, the conceptuality was inspired and conceived from the *Color Atlas of Tropical Pediatrics* but my dream was realized by missionary Dr A Parthasarathy and his editorial board taking the challenge on war-footing and completing the job in a span of six months.

An honest attempt is being made to cover entire pediatric science under 22 subspecialty sections edited by section editors who are *Key Academic Opinion Leaders* (KAOL) and experts in their respective fields. I, sincerely, appreciate with deep admiration all those fellow academicians who have contributed by sharing their valuable collection of images towards this esthetic creation, which in nutshell is exemplary par excellence.

**Rohit Agrawal**

National President  
Indian Academy of Pediatrics, 2012



# Foreword

---

It is my pleasure and privilege to write a foreword for *IAP Color Atlas of Pediatrics*. Let me at the outset congratulate Dr Rohit Agrawal, President IAP 2012 and Dr A Parthasarathy, Editor-in-Chief; Drs Nitin K Shah, Dr Vijay N Yewale, Piyush Gupta, Ritabrata Kundu, Digant Shastri and Dhanya Dharmapalan, all editorial board members for launching this fantastic book within a short span of time. Let me also congratulate all the contributors of this book for their wonderful performance. The color atlas is quite unique in that it is first *Color Atlas of Pediatrics* in the country and will be a ready-reckoner for a busy practicing pediatrician and a guide book for postgraduate students. I have gone through the contents of this book and it is quite fascinating. It contains color pictures, X-rays, CT scans and MRI of common pediatric problems affecting all systems, some of the rare and uncommon conditions encountered in pediatric practice with highlights on management.

I wish this maiden endeavor all the best.

**TU Sukumaran**

National President  
Indian Academy of Pediatrics, 2011



# Preface

---

It is a matter of pride for the Indian Academy of Pediatrics to present the *IAP Color Atlas of Pediatrics*, the first ever publication of an atlas in the history of Indian Academy of Pediatrics. The atlas, is modeled after the *Color Atlas of Tropical Pediatrics* published by the American Academy of Pediatrics in 2009 for which Dr A Parthasarathy, Editor-in-Chief, *IAP Textbook of Pediatrics* as well as of this color atlas, was invited to serve as one of the international associate editors. In fact, this atlas is one-step ahead of *Color Atlas of Tropical Pediatrics* as it includes the entire pediatric science in its ambit.

The *IAP Color Atlas of Pediatrics* provides an unsurpassed visual archive of pediatric illnesses both common and rare, which a health professional dealing with children, encounters in day-to-day practice. Each colorful image, which speaks volumes for itself, is supplemented with a brief description of the condition and suggested management. The images are well organized under 22 specialty sections and furthermore, the conditions have been arranged in an alphabetical order for easy and convenient reference. Each section has been framed and edited by the most experienced key opinion leaders in the respective pediatric subspecialty field, from across the country. This has, in addition, undergone a further level of scrutiny by well-known academicians.

Rather than a highly detailed, academic text, the *IAP Color Atlas of Pediatrics* is a practical working resource. This rich color atlas features more than 1000 high-quality color images and relevant text details with a brief note on management which spans almost every pediatric specialty. It focuses on early and rapid diagnosis of various pediatric illnesses, and offers an outstanding, must have, ready-reckoner asset for students and in the practitioner's office shelf.

Though private publications of Color Atlases in Neonatology, Pediatrics, Dermatology, etc., are available, but there is no authentic publication by a professional body. It is indeed a pleasure to thank all the section editors and contributors for their invaluable contributions in making this a bright academic success. We also thank the publishers for providing this wonderful, superior print and flawless book.

It will always be a relentless endeavor of the Indian Academy of Pediatrics to provide better and latest information in pediatrics. We welcome your feedback and criticism from all our readers which will only motivate us to improvise and deliver the best.

We dedicate this wonderful creation to the parents and *tiny tots in whose sufferings we have discovered learning experience*.

**A Parthasarathy**  
*Editor-in-Chief*

**Rohit Agrawal**  
*Chief Academic Editor*

**Piyush Gupta, Ritabrata Kundu, Digant Shastri**  
*Executive Editors*

**Nitin K Shah, Vijay N Yewale**  
*Academic Editors*

**Dhanya Dharmapalan**  
*Publication Editor*



# Acknowledgments

---

The Editor-in-Chief acknowledges with gratitude the dedication, devotion, commitment, hardwork and assistance provided by the Chief Academic Editor, Dr Rohit Agrawal; Academic Editors, Drs Nitin K Shah and Vijay N Yewale; Executive Editors, Drs Piyush Gupta, Ritabrata Kundu and Digant Shastri, for their untiring last minute scrutiny, coordination, cooperation and concerted efforts in shaping the sections assigned to them to a near *state-of-art version*.

Special mention must be made about the Publication Editor Dr Dhanya Dharmapalan's secretarial-cum-editorial assistance in an untiring manner, despite her busy academic and professional commitments, with last minute efforts to procure, scrutinize and proofread all the 22 Sections; but for her sincere efforts the atlas would not have seen the light of the day.

Our gratitude and appreciation to all 37 learned Section Editors who made this publication possible with their brilliant contributions sacrificing their professional and academic commitments for the last six months.

We acknowledge with gratitude the hard work of all our contributors for the crystal clear images and practical text provided by them in different sections.

The editorial board is indebted to CIAP and its Office Bearers of IAP 2011, Dr TU Sukumaran, President; Tanmay Amladi, Honorary Secretary General; Sailesh Gupta, Honorary Treasurer; Pravin Mehta, Academic Affairs Administrator; Mr Gonsalves, Superintendent and his team of dedicated staff of CIAP and all executive board members of 2011 for their moral support in executing this project successfully.

I would like to especially acknowledge our illustrious publishers M/s Jaypee Brothers Medical Publishers (P) Ltd, New Delhi, India; Mr Jitendar P Vij (Chairman and Managing Director) for his innovative ideas and kind acceptance to publish this unique atlas from his international publishing house; Mr Tarun Duneja (Director-Publishing) and Ms Samina Khan (PA to Director-Publishing) for coordination, Mr KK Raman (Production Manager), Mr Sunil Dogra (Production Executive), Mr Neelambar Pant (Production Coordinator), Mr Rajesh Sharma (Production Coordinator), Subrata Adhikari (Author Coordinator) and Parul Goswami (Coordinator), and the team of Mr Gurnam Singh (Proofreader), Mr Rajesh Kumar (Typesetter) and Mr Manoj Pahuja (Graphic Designer), for working hard day and night, to publish this atlas in a record time with high production value matching international publication standards; Mr RP Mukherjee, Branch Manager-Chennai Branch and Mr R Jayanandan (Sr Commissioning Editor), for coordination and the entire family of publication for continued patronage to IAP publications.

My sincere gratitude to Mrs (Dr) Prathiba Janardhanan, Mrs Kavitha Balaji, Mr R Janardhanan, Mr P Balaji, Ms Shruthi Pavana, Ms Swathi Pavana, Ms Kavya and Ms Mahiya for secretarial assistance and Mrs Nirmala Parthasarathy (PRO), AP Child Care, Chennai, Tamil Nadu, India, for correspondence assistance.

**A Parthasarathy**  
*Editor-in-Chief*

# Contents

---

## Section 1: Neonatology

*Rhishikesh Thakre, Ruchi Nanavati*

1.1	Normal Newborn.....	3
1.2	Common Neonatal Conditions.....	6
1.3	Neonatal Systemic Disorders .....	10
1.4	Uncommon Neonatal Conditions but not Rare .....	15
1.5	Neonatal Diagnostic Imaging.....	18
1.6	Newborn Screening .....	21
1.7	Humane Neonatal Care .....	22

## Section 2: Growth and Development

*KN Agarwal, MKC Nair*

2.1	Physical Growth Stages During First-Five Years of Life .....	27
2.2	Common Errors in Growth Measurements .....	28
2.3	Graphs Related to Growth .....	30
2.4	Development Assessment .....	32

## Section 3: Nutrition

*Meenakshi Mehta*

3.1	Malnutrition Burden.....	35
3.2	Protein-Energy Malnutrition (PEM) and Nutrient Deficiencies .....	37
3.3	Nutrition Education .....	40
3.4	Amylase Rich Foods.....	42

## Section 4: Infectious Diseases

*Jaydeep Choudhury, Nupur Ganguly*

4.1	Common Conditions .....	51
4.2	Uncommon Conditions but not Rare.....	59
4.3	Infectious Disease Emergencies .....	61
4.4	Syndromes.....	62

## Section 5: Neurology

*PAM Kunju, Anoop Verma*

5.1	Common Conditions .....	67
5.2	Uncommon Conditions but not Rare.....	80
5.3	Neurologic Emergencies.....	87
5.4	Syndromes.....	90

## Section 6: Cardiology

*M Zulfikar Ahamed*

6.1	History and Clinical Examination .....	95
6.2	Heart Diseases Subsections.....	96
6.3	Emergencies.....	112
6.4	Syndromes.....	114

## Section 7: Pulmonology

*TU Sukumaran, Devaraj Raichur*

7.1	Common Conditions .....	119
7.2	Uncommon Conditions but not Rare.....	131
7.3	Emergency Situations.....	137
7.4	Syndrome .....	140
7.5	Miscellaneous .....	140

## Section 8: Gastrointestinal System and Hepatology

*Malathi Sathiyasekaran, A Riyaz*

8.1	Common Conditions .....	147
8.2	Uncommon Conditions but not Rare.....	160
8.3	GI Emergencies .....	163
8.4	Syndromes.....	165

## Section 9: Nephrology

*Pankaj Deshpande*

9.1	Common Conditions .....	169
9.2	Uncommon Conditions but not Rare.....	174
9.3	Syndromes.....	178



## Section 10: Hematology

*MR Lokeshwar, Bharat Agarwal*

10.1 Common Conditions .....	183
10.2 Uncommon Conditions but not Rare.....	199
10.3 Hematological Emergencies .....	204
10.4 Syndromes.....	205

## Section 11: Oncology

*Purna Kurkure, Anupama S Borker*

11.1 Common Conditions .....	211
11.2 Uncommon Conditions but not Rare.....	225
11.3 Oncologic Emergencies.....	229
11.4 Syndromes.....	230

## Section 12: Endocrinology

*Vaman Khadilkar, PSN Menon*

12.1 Common Conditions .....	233
12.2 Uncommon Conditions but not Rare.....	249
12.3 Endocrine Emergencies.....	253
12.4 Syndromes.....	254

## Section 13: Genetics

*Shubha R Phadke, ML Kulkarni*

13.1 Chromosomal Disorders .....	261
13.2 Syndromes with Growth Disorders .....	264
13.3 Lysosomal Storage Disorders.....	268
13.4 Skeletal Dysplasias.....	269
13.5 Malformations/Malformation Syndromes .....	272
13.6 Miscellaneous Monogenic Disorders .....	276

## Section 14: Allergy, Rheumatology

*Major K Nagaraju, Vijay Viswanathan*

14.1 Common Allergic Conditions.....	283
14.2 Uncommon Allergic Conditions but not Rare .....	287
14.3 Common Rheumatological Conditions .....	293

14.4	Uncommon Rheumatological Conditions but not Rare.....	296
14.5	Musculoskeletal Syndromes .....	299

## Section 15: Adolescent Health and Medicine

*Swati Y Bhave*

15.1	Growing Up Issues .....	303
15.2	Systemic Problems .....	309
15.3	Miscellaneous .....	313
15.4	Community Programs .....	332

## Section 16: Child Abuse, Neglect and Child Labor

*Meenakshi Mehta*

16.1	Child Abuse and Neglect .....	339
16.2	Child Labor .....	347

## Section 17: Dermatology

*Jayakar Thomas*

17.1	Common Conditions .....	359
17.2	Uncommon Conditions but not Rare.....	365
17.3	Dermatologic Emergencies.....	377
17.4	Syndromes.....	378

## Section 18: Ophthalmology

*TS Surendran, S Meenakshi, R Srikanth*

18.1	Common Conditions .....	381
18.2	Uncommon Conditions but not Rare.....	386
18.3	Emergencies.....	391
18.4	Syndromes.....	395

## Section 19: Otorhinolaryngology

*Divya Prabhat*

19.1	Common Conditions .....	401
19.2	Uncommon Conditions but not Rare.....	409
19.3	ENT Emergencies.....	415
19.4	Syndromes.....	420

## Section 20: Pediatric Surgery

*Ketan Parikh, Arbinder Kumar Singal*

20.1 Common External Conditions .....	425
20.2 Head and Neck Conditions .....	429
20.3 Chest and Diaphragm .....	431
20.4 Gastrointestinal and Hepatobiliary Disorders .....	433
20.5 Pediatric Urological Conditions .....	440
20.6 Solid Tumors of Childhood .....	444

## Section 21: Orthopedics

*K Sriram, Vijay Sriram*

21.1 Common Conditions .....	449
21.2 Uncommon Conditions but not Rare .....	452
21.3 Emergencies .....	457
21.4 Syndromes .....	458

## Section 22: Pediatric Imaging

*Nishigandha Burute, Bhavin Jankharia*

22.1 Abdomen .....	463
22.2 Brain .....	467
22.3 Chest .....	470
22.4 Congenital (Multiorgan) .....	475
22.5 Musculoskeletal .....	476
<i>Index</i> .....	483

## Section 1

# Neonatology

### *Section Editors*

Rhishikesh Thakre, Ruchi Nanavati

### *Photo Courtesy*

Amit Jagtap, Anirudh Thakre, Anuradha Khadilkar, Bonny Jasani, KP Sanghvi, Naveen Bajaj, Nidhi Bagdia, Pradeep Suryawanshi, Pradnya Deshmukh, PS Patil, Ramesh Sitaram Bajaj, Rhishikesh Thakre, Ruchi Nanavati, Sanjay Aher, Sanjay Ghorpade, Sanjay Lalwani, Sankaranarayanan Krishnamoorthy, Snehal Thakre, Srinivas Murki, Sheila Mathai, Vishal Pawar

- 1.1 Normal Newborn
- 1.2 Common Neonatal Conditions
- 1.3 Neonatal Systemic Disorders
- 1.4 Uncommon Neonatal Conditions but not Rare
- 1.5 Neonatal Diagnostic Imaging
- 1.6 Newborn Screening
- 1.7 Humane Neonatal Care

# SECTION OUTLINE

## 1.1 NORMAL NEWBORN 3

- ◆ Acrocyanosis 3
- ◆ Breast Engorgement 3
- ◆ Capillary Refill Time 3
- ◆ Caput Succedaneum 4
- ◆ Feeding Cues 4
- ◆ Normal Newborn 4
- ◆ Skin Peeling 5
- ◆ Skin Tags 5
- ◆ Vaginal Discharge 5
- ◆ Vernix Caseosa 6

## 1.2 COMMON NEONATAL CONDITIONS 6

- ◆ Cephalhematoma 6
- ◆ Contact Dermatitis 6
- ◆ Erb's Palsy 7
- ◆ Infant of Diabetic Mother 7
- ◆ Intrauterine Growth Retardation (IUGR) 7
- ◆ Jaundice 8
- ◆ Oral Thrush 8
- ◆ Preterm 8
- ◆ Pustules 9
- ◆ Seborrheic Dermatitis (Cradle cap) 9
- ◆ Umbilical Granuloma 9
- ◆ Undescended Testis 10

## 1.3 NEONATAL SYSTEMIC DISORDERS 10

- ◆ Abdominal Distention 10
- ◆ Acholic Stools 10
- ◆ Achondroplasia 11
- ◆ Anal Agenesis 11
- ◆ Beckwith-Wiedemann Syndrome 11
- ◆ Bilirubin Encephalopathy 12
- ◆ Capillary Leak Syndrome 12
- ◆ Cyanosis 12
- ◆ Gastroschisis 13

- ◆ Hydrops 13
- ◆ Inguinal Hernia 13
- ◆ Meconium Plug Syndrome 14
- ◆ Meningomyelocele 14
- ◆ Omphalocele 14
- ◆ Pierre-Robin Sequence 15
- ◆ Polycythemia 15

## 1.4 UNCOMMON NEONATAL CONDITIONS BUT NOT RARE 15

- ◆ Ambiguous Genitalia 15
- ◆ Chickenpox 16
- ◆ Clubfoot—Congenital Talipes Equinovarus (CTEV) 16
- ◆ Congenital Glaucoma 16
- ◆ Collodion Baby 17
- ◆ Epidermolysis Bullosa 17
- ◆ Fungal Dermatitis 17

## 1.5 NEONATAL DIAGNOSTIC IMAGING 18

- ◆ Congenital Diaphragmatic Hernia (CDH) 18
- ◆ Congenital Lobar Emphysema (CLE) 18
- ◆ ET Position 19
- ◆ NEC Stage II 19
- ◆ Pneumoperitoneum 19
- ◆ Pneumothorax 20
- ◆ Postextubation Collapse 20
- ◆ Tracheoesophageal Fistula 20
- ◆ USG Skull-IVH 21




## 1.6 NEWBORN SCREENING 21


- ◆ Hearing Screening 21
- ◆ Hypoglycemia Screening 21
- ◆ Metabolic Screening 22
- ◆ Retinopathy of Prematurity (ROP) Screening 22

## 1.7 HUMANE NEONATAL CARE 22


- ◆ Developmentally Supportive Care 22
- ◆ Kangaroo Care 23

## 1.1 NORMAL NEWBORN


Picture	Note	Management
<b>Acrocyanosis</b>		
 <p data-bbox="138 825 570 874"><b>Figure 1.1.1:</b> Acrocyanosis Photo Courtesy: Rhishikesh Thakre, Aurangabad</p>	<p data-bbox="602 322 997 478">Note the central portion (chest) of the body appears pink but the extremities, particularly the palms and soles are blue. The skin and mucosa are spared.</p>	<ul data-bbox="1045 322 1458 723" style="list-style-type: none"> <li>• Acrocyanosis is common, transient, self limiting condition seen after birth, disappearing over the next few hours.</li> <li>• It must be differentiated from central cyanosis (bluish discoloration of skin, mucous membranes), which is not normal and indicates need for urgent evaluation.</li> <li>• Acrocyanosis is also seen in babies with cold stress.</li> </ul>
<b>Breast Engorgement</b>		
 <p data-bbox="138 1336 493 1385"><b>Figure 1.1.2:</b> Breast engorgement Photo Courtesy: Anirudh Thakre, Pune</p>	<p data-bbox="602 997 997 1222">Note the bilateral fullness of both the breasts. The overlying skin shows no signs of redness, warmth or local tenderness. At times, there may be milky discharge from the breasts called “witch’s milk”, which is a benign phenomenon.</p>	<ul data-bbox="1045 997 1458 1365" style="list-style-type: none"> <li>• The condition resolves spontaneously and no intervention is required; just reassurance.</li> <li>• It results from stimulation of breast tissue by high levels of maternal hormones.</li> <li>• Massage or squeezing the breasts or nipples is not recommended as this may lead to breast infection (Mastitis).</li> </ul>
<b>Capillary Refill Time</b>		
 <p data-bbox="138 1827 518 1876"><b>Figure 1.1.3:</b> Capillary refill time (CRT) Photo Courtesy: Ruchi Nanavati, Mumbai</p>	<p data-bbox="602 1508 1019 1835">The picture shows capillary refill time (CRT) being assessed by blanching of the skin following gentle digital pressure over the sternum. Such blanching usually recovers within 3 seconds and is considered normal. If this blanching extends beyond 3 seconds, then it suggests poor perfusion and is one of the signs of shock.</p>	<ul data-bbox="1045 1508 1458 1815" style="list-style-type: none"> <li>• Assessment of CRT is an integral part of newborn assessment for perfusion.</li> <li>• CRT in neonates is best assessed over central areas like sternum or forehead. It is not assessed over extremities as it may be influenced by environmental temperature.</li> </ul>

Picture	Note	Management
<b>Caput Succedaneum</b>		
 <p data-bbox="164 615 599 664"><b>Figure 1.1.4:</b> Caput succedaneum Photo Courtesy: Vishal Pawar, Aurangabad</p>	<p data-bbox="626 273 1037 400">Note the diffuse, soft, puffy, scalp swelling, crossing the suture line with variable degree of discoloration or bruising.</p> <p data-bbox="626 410 1037 502">Caput is present at birth unlike cephalhematoma which appears after 24 to 48 hours.</p>	<p data-bbox="1070 273 1476 369">No tests or treatment is necessary. Caput usually subsides spontaneously within a few days.</p>

**Feeding Cues**


 <p data-bbox="164 1183 599 1234"><b>Figure 1.1.5:</b> Feeding cues Photo Courtesy: Ruchi Nanavati, Mumbai</p>	<p data-bbox="626 842 1037 1097">Note the mouthing-getting hands, fingers to face and mouth—with lip smacking movements which are clues to signs of hunger. These are associated with periods of alertness and wakefulness with drooling, at times. Cry is a late and last of hunger signs in newborn.</p>	<ul data-bbox="1070 842 1492 1261" style="list-style-type: none"> <li>• A healthy infant should be given the opportunity to show hunger, optimal reflexes and attachment to the areola by itself. Cue-based breastfeeding is a pleasurable experience for both, mother and baby.</li> <li>• Forcing infant to the breast can be counterproductive as it might disturb the rooting reflex and alter the tongue position, as the infant reflexively raises tongue to protect airway.</li> </ul>
--	--	---

**Normal Newborn**

 <p data-bbox="164 1755 599 1806"><b>Figure 1.1.6:</b> Normal newborn Photo Courtesy: Rhishikesh Thakre, Aurangabad</p>	<p data-bbox="626 1414 1037 1669">Note the newborn appears pink, has vigorous activity, with good muscle tone (note the flexion of elbows and knees). Following establishment of cry at birth, the heart rate is in normal range (120-180 per min) with regular respiration (40-60 per min).</p>	<ul data-bbox="1070 1414 1492 1872" style="list-style-type: none"> <li>• The cord is clamped and cut at birth and the newborn given straight to the mother for skin to skin contact and to establish breastfeeding.</li> <li>• The essential care for all newborns at birth includes helping to breathe, maintain temperature, asepsis care and exclusive breastfeeding within first hour of life.</li> <li>• All newborns at birth should receive Inj vitamin K, 1 mg, IM to prevent hemorrhagic disease.</li> </ul>
--	--	---


Picture	Note	Management
 <p><b>Figure 1.1.7:</b> Skin peeling Photo Courtesy: Anirudh Thakre, Pune</p>	<p>Note the fine, diffuse scaling and peeling of the skin at thigh and soles. The underlying skin is perfectly normal, soft, and moist. There is no hair loss, shiny membrane formation or signs of inflammation. This is typically seen from the second day of life and last a few days.</p>	<ul style="list-style-type: none"> <li>• Skin peeling is a natural phenomenon in term and postdated babies. It does not need any creams, oil, ointment or lotions.</li> <li>• Excessive peeling is seen in pathological conditions like placental dysfunction, congenital syphilis and candidiasis.</li> </ul>
 <p><b>Figure 1.1.8:</b> Skin tags Photo Courtesy: Ruchi Nanavati, Mumbai</p>	<p>Note the prominent, pedunculated skin lesions 1 to 2 cm in length over the cheek near the angle of the mouth and in the preauricular area with a narrow base. The tags show no overlying inflammation and are painless.</p>	<ul style="list-style-type: none"> <li>• When associated with other craniofacial anomalies, hearing assessment is warranted.</li> <li>• These skin tags pose more of a cosmetic problem and rarely become infected.</li> </ul>
 <p><b>Figure 1.1.9:</b> Vaginal discharge Photo Courtesy: Nidhi Bagdia, Aurangabad</p>	<p>This newborn girl has a creamy, thick vaginal discharge. This may be noted intermittently, during first few days of life; sometimes associated with vaginal spotting or bleeding.</p>	<p>The condition is self limiting and is due to withdrawal of maternal hormones. It requires no treatment, just some gentle reassurance. It subsides by first few weeks of life.</p>




Picture	Note	Management
<p><b>Vernix Caseosa</b></p>  <p><b>Figure 1.1.10:</b> Vernix caseosa Photo Courtesy: Rhishikesh Thakre, Aurangabad</p>	<p>Note that the entire body and the skin folds—thigh, axilla and face at birth is covered by a creamy white substance. Vernix appears primarily in full-term infants and is rarely seen in preterm and postdated babies.</p>	<ul style="list-style-type: none"> <li>• Vernix facilitates passage through birth canal, prevents transepidermal water loss, helps maintain body temperature, protects the delicate skin from environmental stress, and has skin cleansing, antioxidant, wound healing and probably antibacterial properties.</li> <li>• Removing vernix for cosmetic reasons is not recommended.</li> </ul>




## 1.2 COMMON NEONATAL CONDITIONS




### Cephalhematoma

 <p><b>Figure 1.2.1:</b> Cephalhematoma Photo Courtesy: PS Patil, Aurangabad</p>	<p>There is a firm, scalp swelling with clear edges not crossing the suture lines (in contrast to caput) over the left parietal bone.</p> <p>This subperiosteal swelling gradually hardens (calcification) leaving a relatively soft center and fades away in first few months.</p>	<ul style="list-style-type: none"> <li>• In majority, the management is mainly observation and assurance to parents.</li> <li>• If significant, the newborn may develop jaundice, anemia or hypotension.</li> <li>• Skull X-ray or CT scan is done, if neurological symptoms appear or concomitant skull fracture is suspected.</li> <li>• Aspiration is not recommended as it increases risk of infection.</li> </ul>
--	---	--


### Contact Dermatitis

 <p><b>Figure 1.2.2:</b> Contact dermatitis Photo Courtesy: PS Patil, Aurangabad</p>	<p>Note the skin fold at the neck shows erythematous, moist lesion extending to the adjoining area. The infant is cranky on handling the lesion. This is usually due to irritation of skin by sweat, soap, oil or lotions. If the clothes are tight, they rub the site, worsening the condition and pain causing excessive crying.</p>	<ul style="list-style-type: none"> <li>• Removing the cause of irritation is the first step. Such babies need to be bath with warm water followed by drying the skin thoroughly with a clean, soft cloth.</li> <li>• Applying moisturizer or petroleum jelly is helpful. Use loose fitting clothes that allow the skin to breath. Heavy clothes can cause baby to sweat, making the site worse.</li> <li>• Application of zinc oxide cream and mild steroid in non-flexural areas is helpful.</li> </ul>
---	--	--

Picture	Note	Management
 <p><b>Figure 1.2.3:</b> Erb's palsy Photo Courtesy: Rhishikesh Thakre, Aurangabad</p>	<p>Note the <i>Waiter's tip deformity</i> sign—the left arm hangs by the side and is rotated medially; the forearm is extended and pronated. The arm cannot be raised from the side; all power of flexion of the elbow is lost, as is also supination of the forearm. Deep tendon reflexes are absent. The hand and wrist are spared and there is a normal grasp. This is characteristic of Erb's palsy (C5-8) which accounts for 90% of all brachial plexus injuries. Klumpke's paralysis (C8-T1) leads to clawed hand with inability to grasp or flex wrist.</p>	<ul style="list-style-type: none"> <li>• Many Erb's palsy infants improve or recover spontaneously. Onset of recovery within 2 to 4 weeks is a favorable sign. Presence of "antigravity" movement by the end of the third month is an excellent prognostic sign.</li> <li>• Klumpke's palsy and total plexus injuries have worse prognoses.</li> <li>• If there are no signs of improvement by 3 to 6 months, spontaneous improvement is unlikely, and surgical exploration can be considered.</li> </ul>
 <p><b>Figure 1.2.4:</b> Infant of diabetic mother Photo Courtesy: Sheila Mathai, Mumbai</p>	<p>The baby is large for gestation (birth weight &gt; 90<sup>th</sup> percentile). The infant has excessive fat deposition in cheeks, neck (which is almost buried), trunk and the extremities. The pinnae may be hairy and may be a clue to diabetes in mother.</p>	<ul style="list-style-type: none"> <li>• Cord sugar estimation should be done in delivery room to predict subsequent hypoglycemia.</li> <li>• Management involves supervised, early, frequent feeding, close clinical monitoring for complications, and screening and treatment of hypoglycemia.</li> </ul>
 <p><b>Figure 1.2.5:</b> Intrauterine growth retardation Photo Courtesy: Bonny Jasani, Mumbai</p>	<p>Note the IUGR baby appears small with generalized loss of subcutaneous fat. The extremities are thin, the baby looks alert but emaciated. The head appears large compared to the body. When the weight is less than 10<sup>th</sup> percentile for gestation it is called SGA (small for gestational age).</p>	<p>Problems unique to IUGR babies include hypothermia, hypoglycemia, polycythemia, meconium aspiration and jaundice. Closed supervision and early detection of the problems is required.</p>


Picture	Note	Management
<p><b>Jaundice</b></p>  <p><b>Figure 1.2.6:</b> Jaundice Photo Courtesy: Ruchi Nanavati, Mumbai</p>	<p>Note the yellowish discoloration of skin over the trunk, thighs and extremities. The eyes and genitalia are covered to protect from phototherapy light.</p> <p>Jaundice is assessed in bright light, with the infant naked, by blanching the skin with finger pressure to observe for underlying yellowing of skin. Jaundice assessment for infants receiving phototherapy is unreliable.</p>	<ul style="list-style-type: none"> <li>• Visual inspection is not a reliable indicator to estimate the extent of jaundice.</li> <li>• The gold standard of jaundice estimation is total serum bilirubin (TSB). When TSB is &gt; 95<sup>th</sup> percentile for age in hours, as per AAP guidelines, detailed evaluation is mandatory.</li> </ul>
<p><b>Oral Thrush</b></p>  <p><b>Figure 1.2.7:</b> Oral thrush Photo Courtesy: Rhishikesh Thakre, Aurangabad</p>	<p>The picture shows white, curdlike plaques over the tongue, buccal mucosa, extending up to soft palate. These lesions cannot be removed and bleed on scraping. There may be chelosis of the angle of the mouth and concomitant diaper dermatitis. These lesions usually present with feeding difficulty.</p>	<ul style="list-style-type: none"> <li>• Oral thrush is a common fungal infection caused by <i>Candida albicans</i>. The diagnosis is clinical.</li> <li>• The treatment of choice is oral nystatin suspension. Simultaneous treatment of maternal nipple infection is must.</li> </ul>
<p><b>Preterm</b></p>  <p><b>Figure 1.2.8:</b> Preterm Photo Courtesy: Anirudh Thakre, Pune</p>	<p>Note the baby appears small, the skin is thin, shiny, smooth and uniformly pink. The breast buds may be absent or just palpable and the ear recoil is slow or absent. The ear pinnae appear smooth with little or no palpable ear cartilage. There may be lanugo—excessive body hairs over the back, trunk and forehead. In males, the scrotum has less of rugosity, testis are not in the scrotal sac. In females, the labia majora are spread out with labia minora visible. The soles may show few creases in the anterior third.</p>	<ul style="list-style-type: none"> <li>• A combination of physical and neurologic signs (using New Ballard score or Modified Dobowitz score) is used for gestational assessment.</li> <li>• Common problems of preterms include hypothermia, respiratory distress syndrome, poor oro-motor coordination, patent ductus arteriosus, necrotizing enterocolitis and intraventricular hemorrhage.</li> </ul>

Picture	Note	Management
<p><b>Pustules</b></p>  <p><b>Figure 1.2.9:</b> Pustules Photo Courtesy: Rhishikesh Thakre, Aurangabad</p>	<p>Note the periumbilical area shows evidence of pustules. The adjacent skin shows erythema. At times, there may be induration, hardening of the adjoining skin with pus discharge.</p>	<ul style="list-style-type: none"> <li>• A few lesions in a healthy term infant may be treated with topical antibiotic and oral therapy.</li> <li>• More extensive lesions, systemic illness, or pustulosis occurring in the premature infant requires intravenous therapy. Most common causative organism is <i>Staphylococcus aureus</i>.</li> </ul>
<p><b>Seborrheic Dermatitis (Cradle cap)</b></p>  <p><b>Figure 1.2.10:</b> Seborrheic dermatitis (Cradle cap) Photo Courtesy: PS Patil, Aurangabad</p>	<p>Note the greasy, yellow plaques on the scalp with some degree of hair loss. Pruritus is infrequent unlike atopic dermatitis. Such lesions are highly prevalent during the first 4 weeks of life and primarily affect in addition the intertriginous areas.</p>	<p>In mild cases, the condition is self-limited. Treatment options include gentle scrubbing, applying vaseline and using a soft brush to remove scale. Occasionally, topical mild corticosteroid or antifungal is indicated.</p>
<p><b>Umbilical Granuloma</b></p>  <p><b>Figure 1.2.11:</b> Umbilical granuloma Photo Courtesy: Rhishikesh Thakre, Aurangabad</p>	<p>There is a well-circumscribed, friable, moist, pinkish tissue at the base of the umbilicus. It may produce variable amounts of drainage that can irritate the surrounding skin. Such lesion differs from an umbilical polyp (represents retained intestinal or gastric mucosa from the vitelline duct) which is brighter red than a granuloma and does not respond to silver nitrate cauterization.</p>	<ul style="list-style-type: none"> <li>• Small umbilical granuloma usually respond to application of crystal salt or silver nitrate.</li> <li>• Large umbilical granuloma or those that persist after silver nitrate treatment require surgical excision.</li> </ul>


Picture	Note	Management
 <p><b>Figure 1.2.12:</b> Undescended testis Photo Courtesy: Ramesh Sitaram Bajaj, Aurangabad</p>	<p>Note that the scrotal sac appears empty with incomplete overlying rugosity. Both the testis cannot be palpated in the scrotum. Retractable testes are commonly confused with undescended testes. Retractable testis can be delivered into the scrotum, stay in the scrotum and have a well developed scrotum.</p>	<ul style="list-style-type: none"> <li>• First physical examination of newborn must confirm testis are in scrotum.</li> <li>• Patients with undescended testes should be referred for surgical evaluation no later than 3 months of age.</li> <li>• A child with bilateral nonpalpable testes should have an endocrine evaluation to rule out anorchia or intersex.</li> <li>• Definitive treatment is surgical (orchiopexy) but GnRH and hCG are used, with success rates of 30 to 50%.</li> </ul>




### 1.3 NEONATAL SYSTEMIC DISORDERS

#### Abdominal Distention

 <p><b>Figure 1.3.1:</b> Abdominal distention Photo Courtesy: Ramesh Sitaram Bajaj, Aurangabad</p>	<p>Note the infant has generalized abdominal distention with transversely stretched umbilicus. The upper segment is more prominent than the lower segment. A feeding tube is <i>in situ</i> to aspirate the abdominal contents to monitor the color, frequency and consistency of the aspirate. The veins over the abdomen are prominent and some abdominal loops visible suggesting a pathological cause. In all cases, anal patency should be confirmed. When associated with recurrent vomiting, absent bowel sounds, profuse vomiting—clear or bilious, constipation, failure to thrive, surgical cause needs to be ruled out.</p>	<ul style="list-style-type: none"> <li>• Abdominal distention may result from aerophagia, fluid accumulation, organomegaly, lump or intestinal obstruction.</li> <li>• Progressive abdominal distention warrants search for underlying cause. X-ray abdomen may be diagnostic for intestinal obstruction. If inconclusive, electrolytes, urine, USG, sepsis screen, CT imaging with contrast may be needed.</li> </ul>
--	--	--

#### Acholic Stools

 <p><b>Figure 1.3.2:</b> Acholic stools Photo Courtesy: Rhishikesh Thakre, Aurangabad</p>	<p>The stools appear clay colored or pale. The normal yellow color of the stools is because of presence of bile pigments. Decreased bile production or block in the bile flow leads to clay or acholic stools. Jaundice often occurs with acholic stools suggesting underlying cholestasis—direct hyperbilirubinemia with high colored urine staining the cloth.</p>	<p>Acholic or clay stools result from disorder in the biliary system (the drainage system of the gallbladder, liver, and pancreas) and manifests with cholestasis. Cholestasis is always pathological and needs expert evaluation.</p>
--	--	--

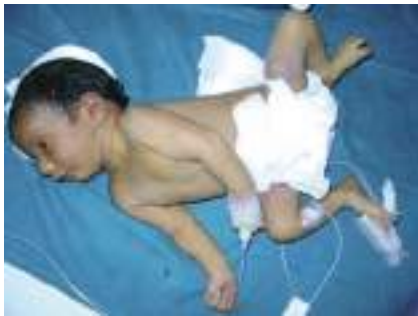Picture	Note	Management
 <p><b>Figure 1.3.3:</b> Achondroplasia Photo Courtesy: Ruchi Nanavati, Mumbai</p>	<ul style="list-style-type: none"> <li>• Picture shows a newborn with short limb dwarfism, upper to lower segment ratio &gt; 1.7:1. Also note short extremities, megaloccephaly, coarse faces, frontal bossing, low nasal bridge, protruding jaw and relatively small thorax.</li> <li>• The hands are short and stumpy and the feet may be short flat and broad. The lifespan and intelligence is 'normal' in majority.</li> </ul>	<ul style="list-style-type: none"> <li>• Most cases appear as spontaneous mutations.</li> <li>• Children are at risk of recurrent otitis media, bowing of legs, respiratory problems, hydrocephalus, motor delay and psychosocial problems.</li> <li>• Diagnostic modalities include prenatal ultrasound, DNA tests for homozygosity and radiological survey.</li> <li>• There is no specific treatment.</li> </ul>
 <p><b>Figure 1.3.4:</b> Anal agenesis Photo Courtesy: Ramesh Sitaram Bajaj, Aurangabad</p>	<p>Note the male infant has no anal opening suggesting anal agenesis—an anorectal malformation. There may be associated fistulae between the rectum, and the urinary, or the genital tracts. Such infants present soon after birth with abdominal distention and failure to pass meconium.</p>	<ul style="list-style-type: none"> <li>• First physical examination of newborn must confirm anal orifice presence and patency.</li> <li>• An invertogram or lateral pelvic radiography at 24 hours of age is used to type the lesion with relation to puborectalis sling. The treatment is surgical.</li> </ul>
 <p><b>Figure 1.3.5:</b> Beckwith-Wiedemann syndrome Photo Courtesy: KP Sanghvi, Mumbai</p>	<p>This shows macrosomia, macroglossia, omphalocele usually associated with visceromegaly. These infants have prominent occiput, transverse crease on the ear lobe, hemihypertrophy, nevus flammeus and hyperinsulinemic hypoglycemia.</p>	<ul style="list-style-type: none"> <li>• Usually sporadic occurrence.</li> <li>• May present as persistent hypoglycemia</li> </ul>

## Picture

## Note

## Management

## Bilirubin Encephalopathy

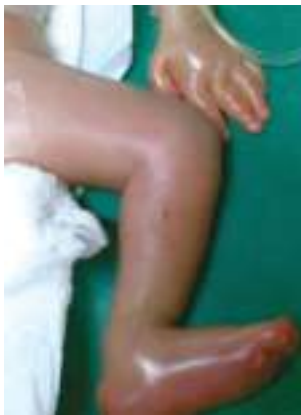

**Figure 1.3.6:** Bilirubin encephalopathy  
Photo Courtesy: Rhishikesh Thakre, Aurangabad

Note the yellowish discoloration of the infant extending up to the soles with setting sun sign—visible upper sclera with yellow staining. There is arching of the back, straightening of both the upper limbs suggesting hypertonia. Such infants have asymmetric or absent Moro's reflex with shrill cry. These signs suggest neurologic dysfunction secondary to unconjugated bilirubin binding to the brain.

- Exchange transfusion and intensive phototherapy is treatment of choice.
- In early phase, interventions can reverse brain damage. With established encephalopathy brain damage is not reversible.

## Capillary Leak Syndrome



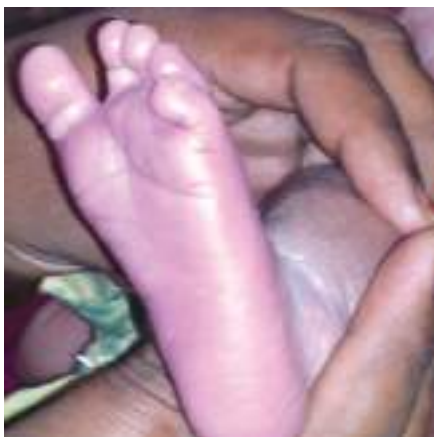**Figure 1.3.7:** Capillary leak syndrome  
Photo Courtesy: Anirudh Thakre, Pune

Note the edema of hands and lower limbs extending up to the feet. The overlying skin is shiny and stretched out due to dependent edema. Such infants develop hypotension, hemoconcentration, hypoalbuminemia, multiple organ failure due to capillary leak syndrome which is leakage of fluid from the circulatory system to the interstitial space.

It is commonly seen with severe sepsis, asphyxia, renal failure, severe liver disease and systemic inflammatory response syndrome.

Treatment of the underlying cause, aggressive supportive care with vasopressor therapy and judicious fluid replacement is the key.

## Cyanosis






**Figure 1.3.8:** Cyanosis  
Photo Courtesy: Rhishikesh Thakre, Aurangabad

Note the bluish discoloration of the sole.




It is due to increased concentration of reduced hemoglobin (>5 gm%) in the blood.


Central cyanosis is characterized by dusky skin and mucous membranes. Peripheral cyanosis involves the hands and feet without affecting the mucosa and the central body. Central cyanosis is a “danger sign” in newborn.

Cyanosis can result from a range of disorders, including hypothermia, cardiac, parenchymal/non-parenchymal pulmonary, metabolic, hematologic and neurological disorders. Cyanotic newborn requires systematic approach, urgent assessment, diagnosis, and initiation of therapy.


Picture	Note	Management
 <p><b>Figure 1.3.9:</b> Gastroschisis <i>Photo Courtesy:</i> Ramesh Sitaram Bajaj, Aurangabad</p>	<p>Note the abdominal wall defect arising outside the umbilical ring and the herniated bowel not covered by peritoneum or amnion. The defect measures 2 to 4 cm and usually lies just to the right of the umbilicus.</p> <p>The organs extruded other than bowels at times include stomach, urinary bladder, uterus and adnexa. The earlier the rupture, the more matted the bowel.</p> <p>Unlike omphalocele, gastroschisis is less commonly associated with other anomalies.</p>	<p>Avoid handling exposed bowel. Wrap bowel in sterile, moist or waterproof material to prevent drying, heat and water loss, and infection. Following stabilization primary closure is done.</p>
 <p><b>Figure 1.3.10:</b> Hydrops <i>Photo Courtesy:</i> Sanjay Aher, Nashik</p>	<p>Shows generalized edema of body, trunk, and extremities. The infant is intubated at birth due to poor lung expansion as a result of pleural effusion and ascites. There may be pericardial effusion, polyhydramnios and placental edema. Fetal hydrops as a physical sign carry the stigma of poor prognosis to the extent that hydrops itself is taken as diagnosis.</p>	<ul style="list-style-type: none"> <li>Historically associated with Rh-isoimmunization. However, currently nonimmune conditions are major causes of hydrops.</li> <li>Careful history, selected diagnostic studies are mandatory to identify the cause but etiology sometimes may remain elusive in 20% of hydrops cases.</li> <li>Management is complex and requires advanced preparation.</li> </ul>
 <p><b>Figure 1.3.11:</b> Inguinal hernia <i>Photo Courtesy:</i> Ramesh Sitaram Bajaj, Aurangabad</p>	<p>Note the bulge localized to the left inguinal area. At times, it may extend into the scrotum. The bulge becomes prominent on straining or crying. The swelling is painless and shows no signs of inflammation. The right side is unaffected. The hernia is due to protrusion of abdominal contents through the inguinal canal outside the peritoneal cavity.</p>	<ul style="list-style-type: none"> <li>The diagnosis is made on the basis of the clinical history and examination. However, in some cases, use of scrotal or inguinal ultrasonography is indicated.</li> <li>Treatment is surgical, as early as possible, for fear of obstruction or strangulation of the hernia.</li> </ul>



Picture	Note	Management
<b>Meconium Plug Syndrome</b>		
 <p data-bbox="164 600 545 649"><b>Figure 1.3.12:</b> Meconium plug syndrome Photo Courtesy: Amit Jagtap, Mumbai</p>	<p data-bbox="626 273 1040 588">The picture shows tenacious string of meconium passed which is usually by 24 to 48 hours. The lower bowel contents could be too dry and extensive forming a plug causing lower bowel obstruction. It is a diagnosis of exclusion. Meconium ileus is impaction of meconium more proximally, usually in the terminal ileum.</p>	<p data-bbox="1070 273 1484 558">Plain films with contrast enema is diagnostic and show the outline of the meconium plug. In general, this disease is observed in premature newborns who are otherwise normal. However, cystic fibrosis and Hirschsprung's disease may be associated with process and should be excluded.</p>
<b>Meningomyelocele</b>		
 <p data-bbox="164 1111 521 1191"><b>Figure 1.3.13:</b> Meningomyelocele Photo Courtesy: Ramesh Sitaram Bajaj, Aurangabad</p>	<p data-bbox="626 821 1032 1361">Note the defect over the lumbar spine with visible lesion with intact skin cover with no discharge, protruding from the spinal canal containing the spinal cord with the meninges suggesting a meningomyelocele—a neural tube defect. Such infants also have affection of the nerves to the bladder, bowel and lower extremities. The higher the level of the defect, the more severe the associated nerve dysfunction and resultant paralysis. It may occur in isolation or with other congenital malformations including midline defects.</p>	<ul data-bbox="1070 821 1484 1156" style="list-style-type: none"> <li>• An open meningomyelocele is closed early to protect against infection. A ventriculoperitoneal shunt may be required for associated hydrocephalus.</li> <li>• A multidisciplinary approach for long-term management is must.</li> <li>• Folic acid supplement is advocated prior to conception for prevention of neural tube defects.</li> </ul>
<b>Omphalocele</b>		
 <p data-bbox="164 1800 513 1878"><b>Figures 1.3.14A and B:</b> Omphalocele Photo Courtesy: Sanjay Lalwani, Pune Ruchi Nanavati, Mumbai</p>	<p data-bbox="626 1530 1040 1845">Note the herniation of the intestines through the base of the umbilicus covered by intact skin. The underlying intestines are easily seen (Fig. 1.3.14B) but with passage of time skin growth takes place over the defect if the repair is delayed (Fig. 1.3.14A). Up to 40% of infants with an omphalocele have other birth defects.</p>	<p data-bbox="1070 1530 1484 1784">Diagnosis is clinical and no tests are required. The size of the herniation determines the mode of delivery as well as the postnatal treatment of omphalocele, while the degree of liver involvement determines the level and type of omphalocele treatment.</p>


Picture	Note	Management
 <p><b>Figure 1.3.15:</b> Pierre-robin sequence Photo Courtesy: Srinivas Murki, Hyderabad</p>	<p>Note the combination of micrognathia, retrognathia leading to glossoptosis and cleft palate. These may cause upper airway obstruction. Such babies have feeding problems, aspiration, ear infections, reduced hearing, or may be part of syndrome.</p> <p>Most of these babies grow to lead a healthy and normal adult life.</p>	<ul style="list-style-type: none"> <li>• No special diagnostic tests are required. Management involves supervised feeds, head high nursing, prone or lateral positioning, and at times nasopharyngeal airway.</li> <li>• Surgical options include tongue-lip ankylosis, mandibular distraction and cleft palate repair. The small jaw usually outgrows during the first two years, and no jaw surgery is necessary.</li> </ul>




### Polycythemia




 <p><b>Figure 1.3.16:</b> Polycythemia Photo Courtesy: Ruchi Nanavati, Mumbai</p>	<p>Note the sole appear flushed and pink red. Such a baby appears plethoric—body color appears uniformly red. A diagnosis of polycythemia is made in such a baby if the hematocrit is &gt; 65%. Commonly seen with conditions causing increased placental transfusion, placental insufficiency and IUGR.</p>	<ul style="list-style-type: none"> <li>• Routine screening of term well neonates is not indicated.</li> <li>• In high-risk infants (e.g. SGA), hematocrit is done 6 to 8 hours following birth.</li> <li>• Partial exchange transfusion is done with normal saline if hematocrit is <math>\geq 70\%</math> (even in an asymptomatic infant) and <math>\geq 65\%</math> in symptomatic infant.</li> </ul>
---	--	--

## 1.4 UNCOMMON NEONATAL CONDITIONS BUT NOT RARE



### Ambiguous Genitalia




 <p><b>Figure 1.4.1:</b> Ambiguous genitalia Photo Courtesy: Anuradha Khadilkar, Pune</p>	<p>Note the baby is darkly pigmented (more so on genitals, umbilicus), has clitoral hypertrophy and impalpable gonads.</p> <p>Common presentation is salt wasting crisis—unexplained shock, metabolic acidosis, hyponatremia and hyperkalemia.</p>	<ul style="list-style-type: none"> <li>• Commonest cause of ambiguous genitalia is congenital adrenal hyperplasia (CAH).</li> <li>• Baseline tests include 17-hydroxyl progesterone (reference range &lt; 6 nmol/L), adrenocorticotrophic hormone assay (reference range 2–11 pmol/L) which are elevated and karyotyping (46XX female) confirming the diagnosis of salt wasting type of CAH.</li> <li>• These infants require replacement therapy with glucocorticoids (hydrocortisone 10–20 mg/m<sup>2</sup>/day) and mineralocorticoids (fludrocortisone 100–200 µg/day).</li> </ul>
--	--	--



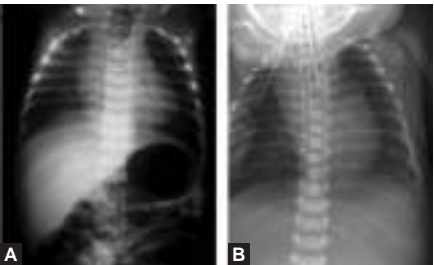
Picture	Note	Management
<b>Chickenpox</b>		
 <p data-bbox="164 594 537 645"><b>Figure 1.4.2:</b> Chickenpox Photo Courtesy: Sanjay Ghorpade, Satara</p>	<p data-bbox="626 273 1040 492">Note the generalized vesicular eruption with rash in varying stages across the body. The infant is afebrile with no eye affection with history of maternal chickenpox. Neonatal chickenpox within the first 4 days after birth is usually mild.</p>	<ul data-bbox="1070 273 1484 807" style="list-style-type: none"> <li>• Nurse mother and baby together but isolate from other patients. Continue breastfeeding.</li> <li>• Admit the infant into hospital isolation room who has rash or is unwell.</li> <li>• Zoster immunoglobulin is given (2 ml, IM) for very preterm babies or to infants whose mother develops chickenpox 1 week on either side of delivery.</li> <li>• Aciclovir is given to infants who develop chickenpox with maternal history of chickenpox, 4 days before to 2 days after delivery.</li> </ul>
<b>Clubfoot—Congenital Talipes Equinovarus (CTEV)</b>		
 <p data-bbox="164 1279 578 1330"><b>Figure 1.4.3:</b> Congenital talipes equinovarus Photo Courtesy: Srinivas Murki, Hyderabad</p>	<p data-bbox="626 932 1024 1222">Note both the feet are affected and rotated internally at the ankle. It is classified as postural (can be manipulated) or structural deformity (fixed deformity). Similar deformities are seen with myelomeningocele hence always look for spinal dysraphism and defects of the spine in such babies.</p>	<ul data-bbox="1070 932 1484 1330" style="list-style-type: none"> <li>• Approximately 50% of clubfeet in newborns can be corrected non-operatively.</li> <li>• Foot manipulation should begin within 2 weeks of birth by gentle stretching and repeated casting. A special brace is worn thereafter nearly full time for 3 months using it up to 3 years. Often tenotomy works.</li> <li>• For severe cases surgery is required.</li> </ul>
<b>Congenital Glaucoma</b>		
 <p data-bbox="164 1802 570 1853"><b>Figure 1.4.4:</b> Congenital glaucoma Photo Courtesy: Snehal Thakre, Aurangabad</p>	<p data-bbox="626 1455 1040 1870">Picture shows diffuse corneal opacity with bilateral enlargement of globe (buphthalmos). Congenital glaucoma is the commonest cause of buphthalmos. Such infants have elevated intraocular pressure (IOP), edema, and opacification of the cornea. Symptoms include photophobia, blepharospasm, and excessive tearing (hyperlacrimation). It may be associated with other ocular and/or systemic findings.</p>	<ul data-bbox="1070 1455 1484 1751" style="list-style-type: none"> <li>• Examination under anesthesia (EUA) is first required to confirm diagnosis.</li> <li>• Treatment includes goniotomy or trabeculectomy. Up to 50% of children do not achieve vision better than 20/50 despite treatment. If untreated, optic atrophy ensues.</li> </ul>


Picture	Note	Management
<p><b>Collodion Baby</b></p>  <p><b>Figure 1.4.5:</b> Collodion baby <i>Photo Courtesy:</i> KP Sanghvi, Mumbai</p>	<p>Note the infant is encased in a tight, shiny, hard, inelastic scale, resembling oiled parchment. Tightness of membranes may cause ectropion (eversion of eyelids), eclabium (turning out of the lips), flattening of ears and nose with absence of hairs. The collodion membrane cracks and peels over course of time.</p> <p>These infants are at increased the risk of infection, dehydration, fluid loss, electrolyte imbalance, body temperature instability, and pneumonia.</p>	<ul style="list-style-type: none"> <li>• Most collodion babies do have a form of ichthyosis.</li> <li>• Collodion babies need to be nursed in high humidity environment, and monitored closely for complications. Application of mild petroleum-based moisturizers is helpful.</li> <li>• A consult with a pediatric dermatologist is necessary.</li> </ul>
<p><b>Epidermolysis Bullosa</b></p>  <p><b>Figure 1.4.6:</b> Epidermolysis bullosa <i>Photo Courtesy:</i> Sanjay Ghorpade, Satara</p>	<p>Picture shows vesicobullous eruptions in different stages over extremities, chest and abdomen. EB is a disorder that causes the skin to be fragile leading to formation of painful blisters over skin and mucous membranes.</p> <p>Severity ranges from simple non-scarring bullae to severe forms with multiple large lesions with loss of large areas of epidermis.</p>	<ul style="list-style-type: none"> <li>• Mild forms do not need treatment. A skin biopsy is done to type the disease.</li> <li>• Prevention of infection and protection of fragile skin surfaces is the goal of treatment.</li> </ul>
<p><b>Fungal Dermatitis</b></p>  <p><b>Figure 1.4.7:</b> Fungal dermatitis <i>Photo Courtesy:</i> Srinivas Murki, Hyderabad</p>	<p>Note the erythematous rash that tends to occur in the creases, in the groin, in the skin folds and buttocks and is usually very red with smaller spots called “satellite” lesions. There are usually no other associated signs or symptoms. The rash is painless and is not itchy. In contrast, contact dermatitis does not involve the groins.</p>	<p>The area is kept dry and frequently exposed to air. Apply antifungal cream topically.</p>

## 1.5 NEONATAL DIAGNOSTIC IMAGING

Picture	Note	Management
	<p>Radiograph shows presence of intestinal loops in the left hemithorax with shift of mediastinum to the right. Please note the absence of the intestinal gas. CDH is suspected in newborn who presents with scaphoid abdomen, respiratory distress, cyanosis and dextrocardia with history of polyhydramnios. The differential diagnosis of X-ray includes congenital cystic adenomatoid malformation (CCAM), cystic pulmonary interstitial emphysema and staphylococcal pneumonia with pneumatocele formation.</p>	<ul style="list-style-type: none"> <li>• CDH often occur with polyhydramnios and usually after routine prenatal 16 weeks USG. Many cases are therefore diagnosed postnatally.</li> <li>• In antenatally diagnosed cases, all infants should be intubated at birth. Bag and mask resuscitation is contraindicated.</li> <li>• Factors associated with better prognosis are herniation after 2<sup>nd</sup> trimester, absence of liver herniation, coexisting cardiac anomalies and late onset of postnatal symptoms.</li> <li>• Priority is in stabilization followed by surgery.</li> </ul>
<p><b>Figure 1.5.1:</b> Congenital diaphragmatic hernia Photo Courtesy: Naveen Bajaj, Ludhiana</p>		
	<p>Radiograph shows large lucent left hemithorax with lower lobe compressed inferomedially with the shift of mediastinum to the opposite side. Differential diagnosis of large lucent hemithorax includes pneumothorax, CAM I, obstructive hyperinflation like CLE, vascular anomaly, or compensatory emphysema seen with contralateral agenesis, hypoplasia or collapse. In CLE, left upper lobe is most commonly involved followed by the right upper lobe and middle lobe. Cardiac anomalies are frequently seen in neonatal CLE.</p>	<ul style="list-style-type: none"> <li>• Airtrapping occurs within one or more lung lobes at birth producing obstructive emphysema which may be due to a malformation, a cyst in the bronchus, or a mucus/meconium plug in the bronchus.</li> <li>• Bronchoscopy may be performed to remove any obstructive material or rupture a bronchogenic cyst.</li> <li>• Pulmonary resection is usually necessary.</li> <li>• Overzealous bag and mask/mechanical ventilation as well as insertion of intercostal drain following misdiagnosis as pneumothorax may result into tension pneumothorax. Under this situation, immediate thoracotomy with lung resection is the only option.</li> </ul>
<p><b>Figure 1.5.2:</b> Congenital lobar emphysema Photo Courtesy: Naveen Bajaj, Ludhiana</p>		


Picture	Note	Management
<p><b>ET Position</b></p>  <p><b>Figure 1.5.3:</b> ET Position Photo Courtesy: Ruchi Nanavati, Mumbai</p>	<p>Radiograph shows the tip of ET tube at the level of C5 vertebra. Tip of tube should normally be just above the carina (i.e. between T1 to T3). Determination of placement of ET tube after intubation is done clinically first and confirmed by chest radiograph. The position can be confirmed by following both of the mainstem bronchi back to the carina and cephalad to the tip of the tube. The ET tube should also be positioned with the bevel in an anterior placement to avoid bevel abutting against the tracheal wall with head movement or position changes.</p>	<ul style="list-style-type: none"> <li>• Clinically, the rule of 7-8-9 is useful for ET positioning: Tip to lip measurement: add 6 to the newborn's weight in kg.</li> <li>• Neutral position of the head is a pre-requisite while taking X-ray films. With the flexion of the head, the tube may move into right main bronchus and into the neck with extension.</li> <li>• Ventilation with malpositioned tube damages the lungs.</li> </ul>
<p><b>NEC Stage II</b></p>  <p><b>Figure 1.5.4:</b> NEC Stage II Photo Courtesy: Amit Jagtap, Mumbai</p>	<p>The picture depicts bubbly or cystic gas pattern within the walls (submucosal) of small intestine described as pneumatosis intestinalis which is a radiologic hallmark of serious NEC. It denotes Stage IIa by Bell's staging criteria. Subserosal gas is seen as curvilinear shadows.</p>	<p>Loss of normal symmetric pattern of bowel gas distribution leading to asymmetrical or disorganized pattern is early radiological sign of NEC. There may be relative paucity of gas in one area with dilatation in other. The films may reveal bowel wall edema, fixed position bowel loop on serial radiographs.</p>
<p><b>Pneumoperitoneum</b></p>  <p><b>Figure 1.5.5:</b> Pneumoperitoneum Photo Courtesy: Ruchi Nanavati, Mumbai</p>	<p>Radiograph shows football abdomen with gas under both the leaves of diaphragm indicating pneumoperitoneum. The most common cause of pneumoperitoneum in preterm neonates is NEC.</p>	<p>GI perforation is the indication for surgical intervention. In extremely sick infants, peritoneal drainage may be the only option. Isolated intestinal perforation may present with pneumoperitoneum without other clinical signs.</p>

Picture	Note	Management
 <p><b>Figure 1.5.6:</b> Pneumothorax Photo Courtesy: Sankaranarayanan Krishnamoorthy, Salford</p>	<p>X-ray shows free air in right hemithorax with collapse of the underlying lung towards hilum. There are absent air markings distal to the lung shadow, increased intercostal distance, flattening of the dome of diaphragm on right side with shift of mediastinum to the opposite side suggesting tension pneumothorax. Symptomatology is depending upon the degree and severity of pneumothorax.</p>	<ul style="list-style-type: none"> <li>• Diagnosis is suspected in infant with unexplained desaturations, deterioration or sudden collapse. Absent or decreased airtentry on one side with shift of mediastinum to the opposite side clinches clinical diagnosis.</li> <li>• Diagnostic tap in the second intercostal space or transillumination is bedside tool. With mediastinal shift, intercostal drain is required.</li> </ul>
 <p><b>Figure 1.5.7:</b> Postextubation collapse Photo Courtesy: Ruchi Nanavati, Mumbai</p>	<p>X-ray shows homogeneous opacity in the right upper lobe with upward shift of transverse fissure and compensatory overinflation of lower lobes suggesting collapse of right upper lobe.</p> <p>Right upper lobe is the most common site of postextubation collapse as right main bronchus is in direct communication with trachea and right upper lobe has less collaterals.</p>	<p>Commonly seen in very low body weight (VLBW) infants who are directly extubated to oxyhood. Positioning and chest physiotherapy resolves the lesion in majority.</p>
 <p><b>Figures 1.5.8A and B:</b> Tracheoesophageal fistula Photo Courtesy: Rhishikesh Thakre, Aurangabad</p>	<p>Radiograph depicts the coiling of the feeding tube in esophagus suggesting a blind pouch with presence of intestinal gas (Fig. 1.5.8A). In most cases, the upper esophagus ends and does not connect with the lower esophagus and stomach. The top end of the lower esophagus connects to the trachea. Common symptoms include drooling, coughing, gagging, choking or cyanosis with attempted feeding soon after birth. History of polyhydramnios in mother or absence of stomach gas on prenatal ultrasound strengthens the diagnosis.</p>	<ul style="list-style-type: none"> <li>• It is a life-threatening neonatal surgical emergency. A high index of suspicion is required for diagnosis.</li> <li>• The defect is confirmed by X-ray by inserting an 8F rigid red rubber catheter through nose or mouth till felt resistance to define the level of upper pouch (Fig. 1.5.8B). Absence of a gastric bubble indicates esophageal atresia without a tracheoesophageal fistula.</li> </ul>


Picture	Note	Management
<p><b>USG Skull-IVH</b></p>  <p><b>Figure 1.5.9:</b> USG Skull-IVH Photo Courtesy: Pradeep Suryawanshi, Pune</p>	<p>The US brain parasagittal view shows &gt;50% of the ventricular area, distending the lateral ventricle suggestive of grade III IVH. Presentation occurs within first 5 postnatal days and may be clinically silent, salutatory or catastrophic. Risk factors in addition to prematurity include vaginal delivery, intrapartum asphyxia, respiratory distress syndrome, hypoxemia, acidosis, pneumothorax and seizures.</p>	<ul style="list-style-type: none"> <li>• Because one half of IVH are clinically silent, routine ultrasound screening should be performed on all infants less than 30 weeks gestation or with risk factors, at 7 to 14 days and 36 to 40 weeks post-menstrual age to detect IVH, periventricular leukomalacia (PVL) and ventriculomegaly.</li> <li>• A grading of severity is assigned based upon the location and extent of IVH.</li> </ul>

## 1.6 NEWBORN SCREENING


### Hearing Screening

 <p><b>Figure 1.6.1:</b> Hearing screening Photo Courtesy: Ruchi Nanavati, Mumbai</p>	<p>The picture shows a newborn undergoing a hearing screen by otoacoustic emission method. This is done in a quiet room with sedation ensuring the ears are clean with one ear tested at a time. If the test result is abnormal, complete evaluation including diagnostic BERA, impedance audiometry and free-field audiometry is warranted. Behavioral audiometry is done only if screening facilities not available. JCIH recommends ABR technology as the only appropriate screening technology in NICU.</p>	<p>Early hearing detection and intervention (EHDI) is essential to maximize linguistic competence and literacy development in children with hearing impairment.</p> <ul style="list-style-type: none"> <li>• Screen all newborns by 1 month of age</li> <li>• Diagnose hearing loss by 3 month of age</li> <li>• Link the infant to intervention by 6 month of age</li> </ul> <p>Infants with any degree of bilateral or unilateral permanent hearing loss is considered eligible for early intervention (EI).</p>
---	---	--


### Hypoglycemia Screening

 <p><b>Figure 1.6.2:</b> Hypoglycemia screening Photo Courtesy: Rhishikesh Thakre, Aurangabad</p>	<p>The screening is done for “at risk” newborn viz-IUGR, infant of diabetic mother, outborns, sepsis, postexchange transfusion, etc. A heel prick capillary sample with value &lt; 40 mg% suggests hypoglycemia and warrants treatment pending venous sample testing by glucose oxidase method in lab which is confirmatory.</p>	<ul style="list-style-type: none"> <li>• Hypoglycemia is a common metabolic disorder. A hypoglycemic infant requires meticulous management and search for underlying cause.</li> <li>• These infants are at risk for occipital infarcts, seizures and neurodevelopmental sequelae.</li> </ul>
--	--	---




Picture	Note	Management
<p><b>Metabolic Screening</b></p>  <p><b>Figure 1.6.3</b> Metabolic screening Photo Courtesy: Rhishikesh Thakre, Aurangabad</p>	<p>Newborn screening for several metabolic disorders is done by heel prick with sample taken on filter paper. The commonly screened metabolic disorders include congenital hypothyroidism, galactosemia, cystic fibrosis, congenital adrenal hyperplasia and G6PD deficiency.</p>	<p>Metabolic screening is just not testing but incorporates confirmation, counseling, follow-up and long-term management.</p>


### Retinopathy of Prematurity (ROP) Screening

 <p><b>Figure 1.6.4:</b> ROP screening Photo Courtesy: Pradnya Deshmukh, Aurangabad</p>	<p>Screening for ROP is done bedside using an indirect ophthalmoscope by a specialist ophthalmologist (using topical drops for pupillary dilatation and local anesthesia). Screening should be performed in all preterm neonates (&lt; 34 weeks) and/or &lt; 1750 gm birth weight at four weeks postnatal age.</p>	<ul style="list-style-type: none"> <li>• Retinopathy of prematurity (ROP) is a developmental vascular proliferative disorder that occurs in retina of preterm infants with incomplete retinal vascularization</li> <li>• The incidence and severity of ROP increase with decreasing gestational age and birth weight.</li> <li>• Treatment is indicated for high-risk prethreshold and threshold disease to prevent blindness.</li> </ul>
---	--	---

## 1.7 HUMANE NEONATAL CARE

### Developmentally Supportive Care

 <p><b>Figure 1.7.1:</b> Developmentally supportive care Photo Courtesy: Rhishikesh Thakre, Aurangabad</p>	<p>The picture shows a preterm baby being nested—provided boundaries for comfort and containment—while receiving ongoing care in NICU. This is one of the intervention practiced while rendering DSC to neonates. Other measures include Kangaroo care, clustering of activities, calming measures following procedures, reducing noise and light exposure along with family centered care. It encompasses integrated developmental care interventions individualized for each baby and environmental changes to make NICU “baby friendly”. The purpose is to lessen the negative effects of hospital care and minimize the stress newborns experience.</p>	<p>Research indicates that babies who are cared for using the individualized developmental care approach have fewer medical complications, shorter stays in the hospital, better weight gain and better developmental outcomes.</p>
---	---	---

Picture	Note	Management
 <p><b>Figure 1.7.2:</b> Kangaroo care <i>Photo Courtesy:</i> Ruchi Nanavati, Mumbai</p>	<p>The picture shows a preterm baby in NICU being placed in vertical position with direct skin-to-skin at mothers chest between her breasts. The head is covered and baby is nursed in Kangaroo bag supported by mother. Kangaroo Care (KC) is a low cost, comprehensive method of care for stable low birth weight (LBW) infants. In KC, the baby is breastfed exclusively. KC fosters the baby's health and wellbeing by promoting effective thermal control, breastfeeding, infection prevention and bonding.</p>	<ul style="list-style-type: none"> <li>• KC should be started as soon as the baby is stable. Mother acts as a source of warmth, nutrition and multimodal stimulation. Skin-to-skin contact promotes lactation and facilitates the feeding interaction.</li> <li>• KC should be continued till baby reaches 40 weeks post conceptional age or attains weight of 2500 gm.</li> <li>• KC should be practiced at all levels of neonatal care. It is important to realize that KC is not a poor man's choice but ideal way of humanizing sophisticated care imparted at tertiary level units.</li> </ul>



## Section 2

---

# Growth and Development

*Section Editor*

KN Agarwal, MKC Nair

*Photo Courtesy*

Anju Seth, KN Agarwal, MKC Nair

- 
- 2.1 Physical Growth Stages during First-Five Years of Life
  - 2.2 Common Errors in Growth Measurements
  - 2.3 Graphs Related to Growth
  - 2.4 Development Assessment

## SECTION OUTLINE

### **2.1 PHYSICAL GROWTH STAGES DURING FIRST-FIVE YEARS OF LIFE 27**

#### **2.2 COMMON ERRORS IN GROWTH MEASUREMENTS 28**

- ◆ Common Errors in Recording Length **28**
- ◆ Common Errors in Recording Height **29**
- ◆ Common Errors in Recording Head Circumference **30**

### **2.3 GRAPHS RELATED TO GROWTH 30**

- ◆ Birthweight Percentiles for Gestation in Rural India **30**
- ◆ Nutritional Status of Indian Children (NFHS-3, 2005-2006) **31**
- ◆ Height in Relation to Genital Development and Age in Affluent Indian Boys **31**

### **2.4 DEVELOPMENT ASSESSMENT 32**

## 2.1 PHYSICAL GROWTH STAGES DURING FIRST-FIVE YEARS OF LIFE

### **Babies:** By the Age of 1

- Grasping and sucking reflexes
- Make discoveries with objects (like shaking a toy/rattle)
- Roll a ball and throw objects
- Crawl, roll over, and sit and stand up (without support) catch a ball
- Build a tower of blocks
- Make clay into balls, house, and other objects.

### **Toddlers:** By the Age of 2

- Walk forwards, backwards, and move more easily
- Pick-up toys from a standing position
- Push and pull objects
- Walk-up and downstairs (with help)
- Balance and hand-eye coordination improves
- Grasp, hold, and throw a small ball

### **Children:** By the Age of 3

- More comfortable with moving and coordination
- Run forward and jump up and down
- Stand on one foot (with help)
- Use and control small objects better
- Draw and paint circles
- Roll, pound, squeeze, and pull clay

### **Children:** By the Age of 4

- Ability to move and balance improves
- Run around objects and walk on a line
- Balance on one foot
- Push and pull toys and ride a tricycle
- Throw

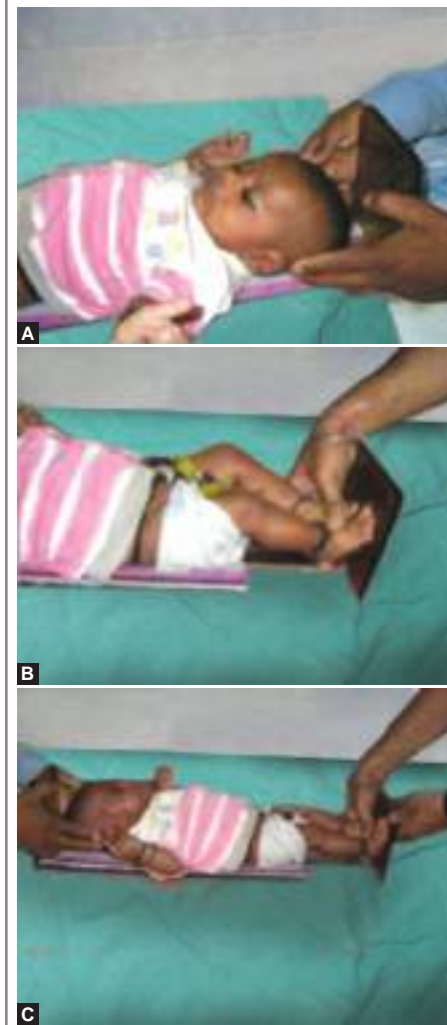
### **Children:** By the Age of 5

- More physically confident
  - Walk backwards and jump on one foot
  - Jump forward many times without falling
  - Walk up and downstairs (without help)
  - Do somersaults
  - Use safety scissors and print a few letters
-

## 2.2 COMMON ERRORS IN GROWTH MEASUREMENTS

Picture	Note	Management
---------	------	------------

### Common Errors in Recording Length



**Figures 2.2.1A to C:** Common errors in recording length

*Photo Courtesy:* Anju Seth, New Delhi

Figure 2.2.1A shows incorrect method as head is not touching the fixed board.

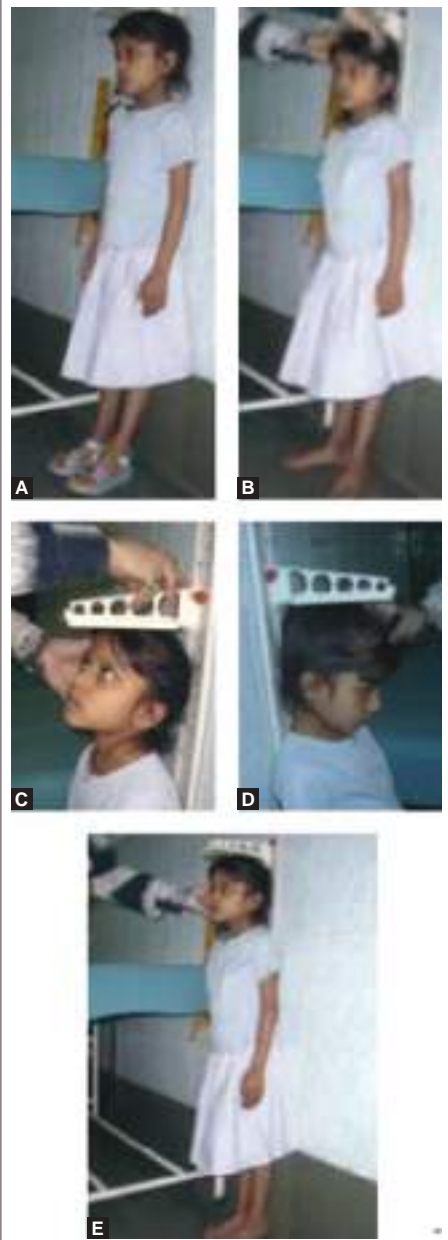
Figure 2.2.1B incorrect method as feet are not at right angles to the lower legs.

Figure 2.2.1C correct method.


The recumbent length in children below 2 years of age can be correctly measured on an infantometer by two persons. The child should be placed in supine position on the infantometer with his/her knees extended completely and feet at right angles to the lower legs. Baby's head is held against the fixed board, while the sliding board is moved closely to touch the heels. The length is read from the scale.

Picture	Note	Management
---------	------	------------

**Common Errors in Recording Height**

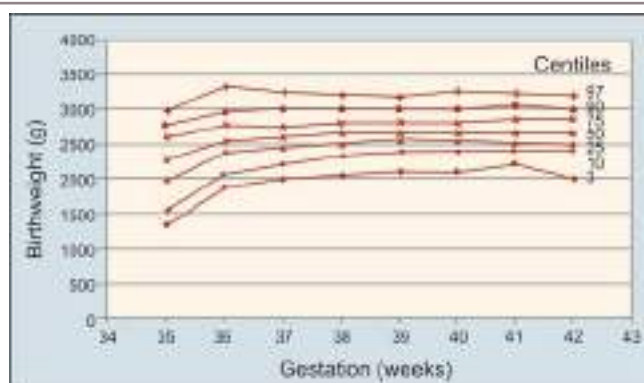
 <p><b>A</b> <b>B</b> <b>C</b> <b>D</b> <b>E</b></p>	<p>Figure 2.2.2A incorrect method as child has worn footwear.</p> <p>Figure 2.2.2B incorrect method as feet are not placed parallel to ground with heels touching against the wall.</p> <p>Figure 2.2.2C incorrect method as head is not held in Frankfurt plane.</p> <p>Figure 2.2.2D incorrect method as head is not held in Frankfurt plane.</p> <p>Figure 2.2.2E correct method of recording height.</p>	<p>Height for children above 2 years of age can be measured by a wall-mounted scale with least count of 0.1 cm and a small moveable horizontal arm that can slide up and down on the scale. A child should stand without shoes and socks with feet parallel on an even flat platform, stretching upward to the fullest, arms hanging on the sides; and buttocks and heels touching against the rod. The head should be held comfortable, erect with lower border of the orbit of the eye in the same horizontal plane as the external canal of the ear (Frankfurt plane). The horizontal arm of the device is gently lowered to the top of the head and height read from the scale.</p>
<p><b>Figures 2.2.2A to E: Errors in recording height</b>  <i>Photo Courtesy: Anju Seth, New Delhi</i></p>		



Picture	Note	Management
<b>Common Errors in Recording Head Circumference</b>		
	<p>Figure 2.2.3A incorrect method as tape is not passing over supraorbital margins in the front.</p> <p>Figure 2.2.3B incorrect method as tape is not passing over the occipital protuberance at the back.</p> <p>Figure 2.2.3C correct method of recording head circumference.</p>	<p>The head circumference is measured by passing the measuring tape over the occipital protuberance of the head at the back and supraorbital margins in the front. The objective is to record the maximum head circumference.</p>
<p><b>Figures 2.2.3A to C: Errors in recording head circumference</b>  <i>Photo Courtesy: Anju Seth, New Delhi</i></p>		

## 2.3 GRAPHS RELATED TO GROWTH

### Birthweight Percentiles for Gestation in Rural India

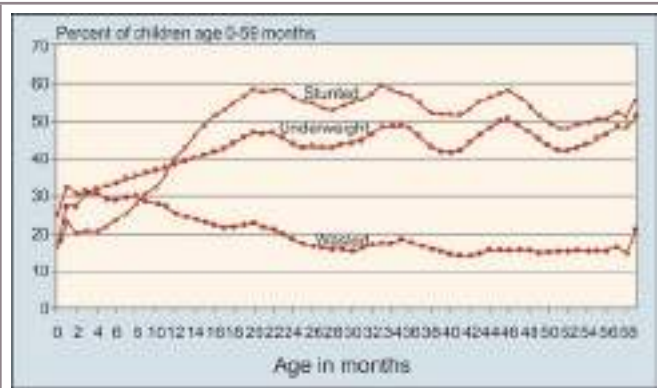


**Figure 2.3.1:** Birthweight percentiles for gestation in rural India  
*Photo Courtesy: Agarwal et al. Birthweight patterns in rural undernourished pregnant women. Indian Pediatrics. 2002;39:244-53 (Reproduced with permission)*

As seen in the graph, the fetal weight gain is severely affected in rural undernourished women, being 5 to 53 g during 36 to 41 weeks of gestation.

Picture	Note
---------	------

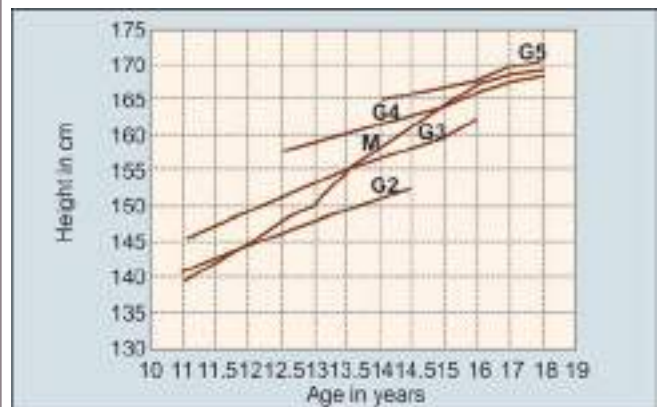
**Nutritional Status of Indian Children (NFHS-3, 2005-2006)**



As seen in the graph, the proportion of stunted or underweight children increases rapidly with the child's age through age 20 to 23 months. Undernutrition in early life continues to affect puberty and adolescence.

**Figure 2.3.2:** Nutrition status of Indian children (NFHS-3, 2005-2006)

**Height in Relation to Genital Development and Age in Affluent Indian Boys**



As seen in the graph, boy at 14 years in genital Stages 2, 3, 4 and 5 has height of 151 cm, 157 cm, 162 cm and 165 cm respectively, the mean height being 157 cm. Thus during pubescence, child's anthropometry can be assessed in relation to their sexual maturity.

**Figure 2.3.3:** Height in relation to genital development and age in affluent Indian boys  
 Photo Courtesy: KN Agarwal et al. Physical growth assessment in adolescence. Indian Pediatrics. 2001;38:1217-35 (Reproduced with permission)

## Picture

## Note

## Management

## 2.4 DEVELOPMENT ASSESSMENT



A



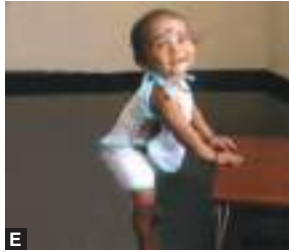B



C



D



E



F



G

**Figures 2.4A to G:** (A) 6 weeks—Head at level can change side; (B) 8 weeks—Lifts head above the body; (C) 12 weeks—Lifts head and chest; (D) 6 months—Sits with support; (E) 9–10 months—Stands with support; (F) 44 weeks—Creeps; (G) 6–12 weeks—Fixes and follows light

*Photo Courtesy:* MKC Nair, Kerala

- **Gross motor skills:** The development of large muscles and large muscle movements such as rolling, scooting, crawling, and walking. These are usually the first skills that babies and toddlers master.
- **Fine motor skills:** The development of the smaller muscles in the hands and feet which allow for tasks such as grasping, cutting, buttoning and writing. Children often do not develop fine motor skills until well into the toddler or early school years, and some experts believe that boys lag a little behind girls in this area.
- **Coordination:** The development of a sense of balance as well as the ability to put together multiple physical activities for actions such as twisting, catching, reaching and eating. Again, the development of coordination and balance will differ in each child.

**Development can be assessed by**

- Good history regarding birth weight, perinatal events and post-natal achievements of milestones.
- Keen observation, without actually formally examining the child. The gross and fine motor milestones, speech, social behavior and play should be evaluated.

In case of developmental delay, parents should be counseled. Early interventions (i.e. speech, language therapy, occupational therapy, physical therapy, special educational services) can improve the quality of life for both the child and family.

# Section 3

---

# Nutrition

***Section Editor***  
Meenakshi Mehta

***Photo Courtesy***  
Adsul BB, RM Chaturvedi, Dheeraj Shah,  
Meenakshi Mehta, Pallavi Shelke

- 
- 3.1 Malnutrition Burden
  - 3.2 Protein-Energy Malnutrition (PEM) and Nutrient Deficiencies
  - 3.3 Nutrition Education
  - 3.4 Amylase Rich Foods (ARF): The Magic

## SECTION OUTLINE

### 3.1 MALNUTRITION BURDEN 35

- ◆ A Nutrition Crisis Amid Prosperity 35
- ◆ Etiology of Malnutrition—Spider’s Web 35
- ◆ Malnutrition—Cause of Poor Learning Ability 35
- ◆ Poverty Redefined 36
- ◆ Poverty—Curse for Malnutrition 36
- ◆ The Iceberg of Malnutrition 36

### 3.2 PROTEIN-ENERGY MALNUTRITION (PEM) AND NUTRIENT DEFICIENCIES 37

- ◆ Dermatitis of Kwashiorkor 37
- ◆ Kwashiorkor 37
- ◆ Marasmic Kwashiorkor 37
- ◆ Marasmus 38
- ◆ Micronutrient Deficiency 38
- ◆ Rachitic Rosary 39
- ◆ Radiological Changes of Scurvy 39
- ◆ Vitamin A Deficiency 39
- ◆ Vitamin A Deficiency 40

### 3.3 NUTRITION EDUCATION 40

- ◆ Child Nutrition: Infant Milk Food Unsafe—Etiology of PEM 40
- ◆ Health Education Program 40

- ◆ Malnourished Child 41
- ◆ Nutrition Education: Eating Balanced Food for Good Growth 41
- ◆ Nutrition Education: Foods Rich in Vitamin A, Dairy Products and Vegetables, Fish 41
- ◆ Prevention of Kwashiorkor 42


### 3.4 AMYLASE RICH FOODS (ARF): THE MAGIC 42

- ◆ ARF—The Miracle of Germinated Cereal Powders 42
- ◆ ARF—The Possible Solutions 42
- ◆ ARF—The Concept 43
- ◆ ARF—Source from Germinated Cereals 43
- ◆ ARF—Step 1 43
- ◆ ARF—Step 2 44
- ◆ ARF—Step 3 44
- ◆ ARF—Step 4 44
- ◆ ARF—Step 5 45
- ◆ ARF—Step 6 45
- ◆ ARF—Step 7 45
- ◆ ARF—Step 8 46
- ◆ ARF—Step 9 46
- ◆ ARF—Decrease in Viscosity after Adding ARF 46
- ◆ ARF—The Magic of ARF 47


### 3.1 MALNUTRITION BURDEN

Picture	Note	Management
---------	------	------------


#### A Nutrition Crisis Amid Prosperity

 <p><b>Figures 3.1.1A to D:</b> A nutrition crisis amid prosperity  <i>Source:</i> Hindustan Times          13<sup>th</sup> and 14<sup>th</sup> October, 2011</p>	<p>Malnourished kids are seen in urban slums of wealthy Mumbai, Maharashtra.</p> <p>This is probably due to the increasing prices of essential foods, unemployment, over population, poverty, restricted water supply and sanitation and recurrent morbidity.</p>	<p>Comprehensive Welfare Schemes like National Nutrition Programs, ICDS, IMNI, RCH and MCH Services will help.</p>
--	---	--

#### Etiology of Malnutrition—Spider’s Web

 <p><b>Figure 3.1.2:</b> Etiology of malnutrition—Spider’s web  <i>Photo Courtesy:</i> Meenakshi Mehta, Mumbai</p>	<p>The various causes: bad budgeting, desire for prestige, bottle-feeding, diarrhea, stopping breast milk, poor weaning and alcoholism, all are linked with each other to cause PEM.</p>	<p>All the aspects have socioeconomic background and will have to be tackled together to prevent malnutrition.</p>
--	--	--

#### Malnutrition—Cause of Poor Learning Ability

 <p><b>Figure 3.1.3:</b> Malnutrition—cause of poor learning ability  <i>Source:</i> Hindustan Times, 25<sup>th</sup> November, 2011</p>	<p>As per UNESCO’s Global Monitoring Report 2008 malnutrition impairs brain development affecting the educational aspects of about 46% of children in South Asia including India. As per the latest National Family Health Survey, India reduced malnutrition only by a percentage point to 46% since 1998, while its economy grew by over 9%.</p>	<p>Elimination of malnutrition is the only answer for optimal brain development and educational achievement.</p>
---	--	--

Picture	Note	Management
<p><b>Poverty Redefined</b></p> <p><b>Figure 3.1.4:</b> Poverty redefined Source: Hindustan Times, 19<sup>th</sup> August 2008</p>	<p>Poverty line: Official level of income necessary to buy basic things</p> <p>Deprivation: The lack or denial of something considered essential.</p> <p>Hence, poverty is the main cause of malnutrition.</p>	<p>Extremely difficult to eliminate poverty and unemployment unless government projects on wide scale are implemented.</p>

### Poverty—Curse for Malnutrition

<p><b>Figure 3.1.5:</b> Poverty—curse for malnutrition Source: Times of India, 27<sup>th</sup> August, 2008</p>	<p>Highest incidence of national poverty is directly proportional to malnutrition in India.</p>	<p>Malnutrition cannot be eliminated unless the root cause, i.e. poverty is eliminated.</p>
---	---	---

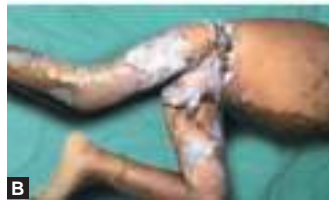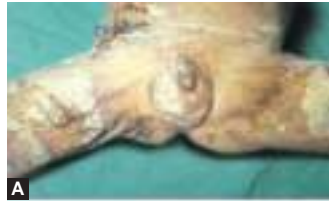### The Iceberg of Malnutrition

<p><b>Figure 3.1.6:</b> Iceberg of malnutrition Source: Meenakshi Mehta, Mumbai</p>	<p>Iceberg of malnutrition has only 1/10th, i.e. severe cases are brought for medical care, whereas 9/10th are moderate and mild cases of PEM are distributed in community, unless attended and likely to deteriorate and hence are dangerous.</p>	<p>Early diagnosis and treatment of mild malnutrition and prevention of progressing to severe forms.</p>
---	--	--

### 3.2 PROTEIN-ENERGY MALNUTRITION (PEM) AND NUTRIENT DEFICIENCIES

Picture	Note	Management
---------	------	------------

#### Dermatosis of Kwashiorkor



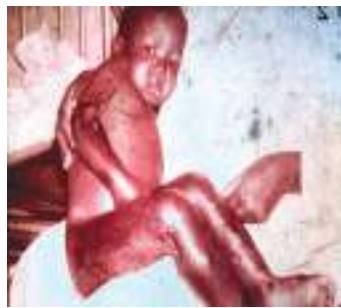**Figures 3.2.1A and B:** Dermatitis of kwashiorkor

*Photo Courtesy:* Meenakshi Mehta, Mumbai

The dermatosis of kwashiorkor are varied, mainly on lower limbs and lower abdomen and include patchy erythema, areas of hypo/hyperpigmentation, desquamation followed by depigmentation and exposing dermis, resembling “Flaky Paint Dermatitis”, “Mosaic dermatosis”. In severe cases, petechiae and ecchymoses may appear.

No specific treatment of dermatosis. Improves with treatment of kwashiorkor.

#### Kwashiorkor



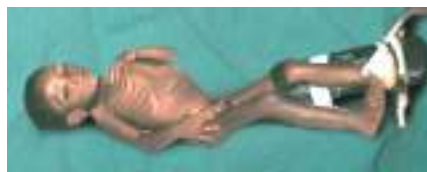**Figure 3.2.2:** Kwashiorkor

*Photo Courtesy:* Meenakshi Mehta, Mumbai

PEM due to predominant protein deficiency compared to calorie deficiency. Common age 1 year to 3/4 years. Characterized by general edema, pallor, apathy, irritability, occasionally dermatosis and hair changes associated with anorexia and diarrhea.

Right from postweaning phase ensure proper administration of adequate food both quality/quantity wise, treatment of diarrhea and other complications if any, preventive immunizations.

#### Marasmic Kwashiorkor






**Figure 3.2.3:** Marasmic kwashiorkor




*Photo Courtesy:* Meenakshi Mehta, Mumbai


Patient has combined manifestations of marasmus and kwashiorkor, i.e. wasting of whole body with edema of lower limbs and rarely upper limbs.

Dietary management involves administration of both protein and calories with Type I and Type II nutrients, i.e. micronutrients.




Picture	Note	Management
 <p><b>Figures 3.2.4A and B:</b> Marasmus Photo Courtesy: Meenakshi Mehta, Mumbai</p>	<p>PEM due to predominant calorie deficiency. Common age 6 months to 3/4 years. Characterized by thin, severely undernourished/wasted child, loss of subcutaneous fat, absence of edema, hepatosplenomegaly, alert look, in advanced cases wasting of muscles, delayed growth.</p>	<p>Right from weaning phase, 6 months onwards, proper care of quantity and quality of food intake, prevention of micronutrient deficiencies, immunization and deworming.</p>
 <p><b>Figure 3.2.5:</b> Marasmus Photo Courtesy: Dheeraj Shah, Delhi</p>	<p>Severe form of undernutrition resulting in marked muscle wasting, loss of subcutaneous fat, skeleton like look. Child appears alert.</p>	<p>Stepwise management involves:</p> <ul style="list-style-type: none"> <li>• Treatment of complications, e.g. hypoglycemia, infections.</li> <li>• Initiation of dietary therapy involving F-75.</li> <li>• Energy dense feeding during recovery phase.</li> <li>• Follow-up care.</li> </ul>
 <p><b>Figures 3.2.6A and B:</b> Micronutrient deficiency Photo Courtesy: Rural Health Training Center, Vaitarna, Department of Community Medicine, LTMM College and General Hospital, Sion, Mumbai (for both photos)</p>	<ul style="list-style-type: none"> <li>• <i>Angular stomatitis:</i> During health check-up of students of a tribal school in taluka Shahpur, district Thane. Disease due to deficiency of micronutrients are commonly seen in tribal children. In this picture, a male child with angular stomatitis is shown. It occurs due to deficiency of riboflavin.</li> <li>• <i>Pale and Fissured tongue:</i> Another student had deficiency of iron and vitamin B<sub>2</sub> and B<sub>3</sub>.</li> </ul>	<ul style="list-style-type: none"> <li>• The children were given the micronutrient supplements riboflavin and multivitamins. Health education regarding the nutrition was also provided with.</li> <li>• The child was treated with iron and multivitamins. The nutritional health education was given for long-term benefit.</li> </ul>

Picture	Note	Management
<p><b>Rachitic Rosary</b></p>  <p><b>Figure 3.2.7:</b> Rachitic rosary <i>Photo Courtesy:</i> Dheeraj Shah, Delhi</p>	<p>Prominence of costochondral junctions resulting from accumulation of unmineralized matrix in vitamin D deficiency (Rickets).</p> <p>Rachitic rosary has more rounded appearance in comparison to scorbutic rosary where angulation is sharp and may be tender.</p>	<p>Treatment of vitamin D deficiency rickets involves administration of 600,000 U of vitamin D orally or intramuscularly. Adequate intake of vitamin D and calcium should be ensured during follow-up besides adequate exposure to sunlight.</p>
<p><b>Radiological Changes of Scurvy</b></p>  <p><b>Figure 3.2.8:</b> Radiological changes of scurvy <i>Photo Courtesy:</i> Dheeraj Shah, Delhi</p>	<p>Changes of scurvy are most prominently seen around knee. The metaphysis of long bones show dense white line (WL) of Frankel. Zone of rarefaction or Trummerfeld zone (TZ) is seen in submetaphyseal region. The extension of WL over TZ produces appearance of a spur which is called Pelkan spur (PS).</p>	<p>Oral administration of vitamin C 100 to 300 mg/day for up to 12 weeks.</p>
<p><b>Vitamin A Deficiency</b></p>  <p><b>Figure 3.2.9:</b> Vitamin A Deficiency <i>Photo Courtesy:</i> Rural health training center, Vaitarna, Department of Community Medicine, LTMM College and General Hospital, Sion, Mumbai</p>	<p>In this picture, a tribal school student is having phrynoderma or toad skin which is a sign of vitamin A deficiency.</p>	<p>For treatment vitamin A was given orally. 2,00,000 IU was given on 0, 1 and 14 days along with the dietary advice to consume the locally available vitamin A enriched food like drumsticks, papaya and ripe mangoes.</p>


Picture	Note	Management
<p><b>Vitamin A Deficiency</b></p>  <p><b>Figures 3.2.10A and B:</b> Vitamin A Deficiency  <i>Photo Courtesy:</i> Rural Health Training Center, Vaitarna, Department of Community Medicine, LTMM College and General Hospital, Sion, Mumbai (for both photos)</p>	<p>1) In first picture, a tribal school student is having 'Bitot's spot' which is a sign of vitamin A deficiency.</p> <p>2) In second picture, a case of 'Xerophthamia' is seen. The patient had come for treatment in Urban Health Center, Dharavi.</p> <p>Prophylactic vitamin A supplementation is given every 6 months to children below 5 years of age under universal immunization program to prevent deficiency disorder.</p> <p>Starting at 9 months with measles as a first dose : 1,00,000 IU          At 15 months : 2,00,000 IU          Every 6 monthly up to the age of 5 years : 2,00,000 IU</p>	<p>Under national program for prevention of Blindness the prophylactic vitamin A supplementation is given up to 5 years of age to prevent the vitamin A deficiency.</p> <p>For treatment, vitamin A was given orally and the patient was referred to ophthalmology for further management.</p> <p>Immediately on diagnosis          &lt; 6 months 50,000 IU          6-12 months 1,00,000 IU          &gt; 12 months 2,00,000 IU          Next day and at least 2 weeks later: Same age specific dose.</p>

### 3.3 NUTRITION EDUCATION

#### Child Nutrition: Infant Milk Food Unsafe—Etiology of PEM


 <p><b>Figure 3.3.1:</b> Child nutrition: Infant milk food unsafe  <i>Photo Courtesy:</i> Meenakshi Mehta, Mumbai</p>	<p>Bottle-feeding in uneducated families, in poor socioeconomic circumstances, unhygienic environment with restricted water supply leads to recurrent morbidity, malnutrition and finally death.</p>	<p>Avoid bottle-feeding, instead advice fresh animal milk with cup/wati, spoon/"bondla", when supplementary feeding is advocated.</p>
--	--	---

#### Health Education Program


 <p><b>Figures 3.3.2A and B:</b> Health Education Program  <i>Photo Courtesy:</i> Urban health center, vaitarna, Department of Community Medicine, LTMM College and General Hospital, Sion, Mumbai (for both photos)</p>	<p>Health education session is being carried out during breastfeeding week.</p>	<p>The department of community medicine is carrying out the health educational activities in the community to spread the awareness regarding malnutrition. This is effective tool to bring about the community participation.</p>
---	---	---

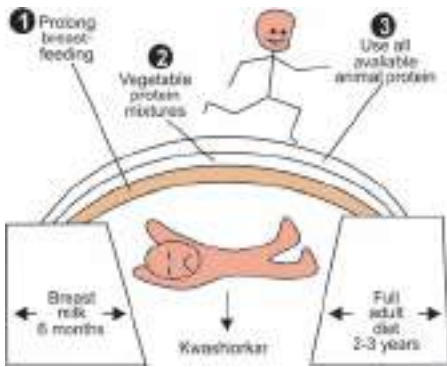
Picture	Note	Management
 <p><b>Figures 3.3.3A and B:</b> Malnourished child  <i>Photo Courtesy:</i> Urban health center, Dharavi, Department of Community Medicine, LTMM College and General Hospital, Sion, Mumbai (for both photos)</p>	<p>Malnutrition is commonly seen in infants after 5 to 6 months of age. The child in picture had come to Urban Health Center, Dharavi for treatment.</p>	<p>The child was referred to Nutritional Rehabilitation Center (NRC) run in Urban Health Center (UHC), Dharavi.</p> <p>Health education about weaning food was given. Emphasis was given to inclusion of energy rich semisolid food—NRC, UHC, Dharavi. Under ICDS program, anthropometric measurements are taken on monthly basis by <i>Anganwadi</i> worker to identify cases of malnutrition.</p>

### Nutrition Education: Eating Balanced Food for Good Growth

 <p><b>Figure 3.3.4:</b> Eating balanced food for good growth  <i>Photo Courtesy:</i> Meenakshi Mehta, Mumbai</p>	<p>Shows how children grow well by eating proper balanced diet covering all food groups</p>	<p>The teaching of nutrition must stress that there is a connection between good and proper food for growing tall, strong and healthy.</p>
--	---	--


### Nutrition Education: Foods Rich in Vitamin A, Dairy Products and Vegetables, Fish

 <p><b>Figures 3.3.5A to D:</b> Foods rich in vitamin A, dairy products and vegetables, fish  <i>Photo Courtesy:</i> Meenakshi Mehta, Mumbai</p>	<p>Shows foods rich in vitamin A: Dairy products, eggs and dark green leafy vegetables, pappaya and carrots, fish and other vegetables.</p>	<p>Advice adequate consumption from these foods as per the socio-economic status of the family.</p>
---	---	---


Picture	Note	Management
<p><b>Prevention of Kwashiorkor</b></p>  <p><b>Figure 3.3.6:</b> Three plank protein bridge for prevention of malnutrition  <i>Photo Courtesy:</i> Meenakshi Mehta, Mumbai</p>	<p>Shows three plank protein bridge in order of priority: (1) Prolonged breast feeding, (2) Use all available vegetable proteins, (3) Use all available animal proteins whenever possible, to prevent child developing kwashiorkor.</p>	<p>Judicious use of breast milk (proteins), vegetable and animal proteins starting from six months onwards—postweaning phase to about 2 to 3 years of age by the time the child has full adult diet to prevent the child falling in the river of kwashiorkor.</p>


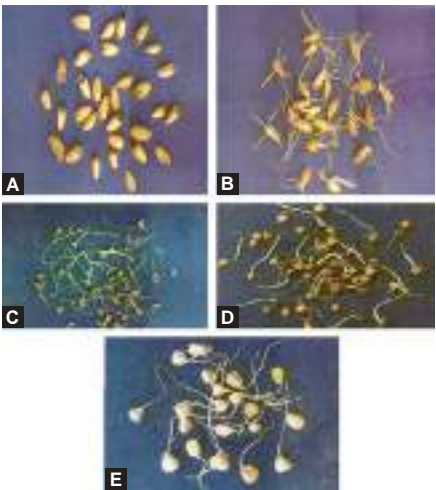

### 3.4 AMYLASE RICH FOODS (ARF): THE MAGIC

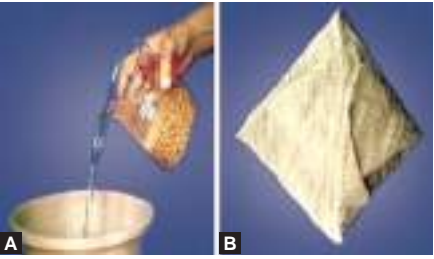
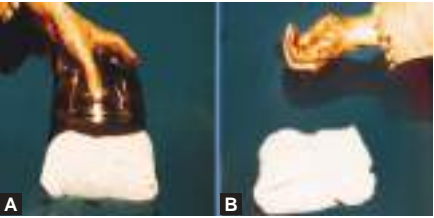

#### ARF—The Miracle of Germinated Cereal Powders

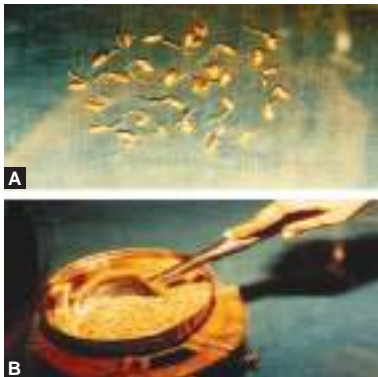


 <p><b>Figure 3.4.1:</b> The miracle of germinated cereal powders  <i>Photo Courtesy:</i> Meenakshi Mehta, Romeen Lavani, Mumbai</p>	<p>The problem: Vast majority of infants (after 6 months of age and onwards) develop malnutrition because of weaning with bulky, viscous yet low nutritious porridges/ gruels of cereals consumed in different communities. The infants are unable to consume the gruels in adequate amount per feeding and hence get less calories.</p>	<p>Porridges/gruels treated with ARF will have decreased viscosity, less bulky, hence the children will be able to consume more and will have more calories.</p>
--	--	--

#### ARF—The Possible Solutions




 <p><b>Figure 3.4.2:</b> ARF—The possible solutions  <i>Photo Courtesy:</i> Meenakshi Mehta Romeen Lavani, Mumbai</p>	<p>The solutions: To increase the calories, of the feed the alternative solutions are:</p> <ol style="list-style-type: none"> <li>1. Addition of oil</li> <li>2. Fermentation</li> <li>3. Increasing ingredients</li> <li>4. Germination of cereals and adding the product/powder to the main gruel.</li> </ol>	<p>Amongst the solutions suggested, the first 3 methods are commonly employed hence the germination of cereals producing amylase, a less known method yet, simple and cheap, is demonstrated here.</p>
--	---	--

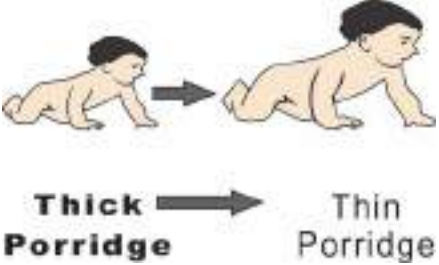
Picture	Note	Management
<p><b>ARF—The Concept</b></p>  <p><b>Figure 3.4.3:</b> ARF—The concept Photo Courtesy: Meenakshi Mehta, Romeen Lavani, Mumbai</p>	<p>Alpha-amylase is the liquefying enzyme that breaks down long chain carbohydrates of all cereals into short chain dextrin. Hence, this decreases the viscosity and the bulk of the cereal gruel/feed. Thus, germinated cereal flour which are extremely rich in <math>\alpha</math>-amylase are able to thin-cooked cereal gruels in catalytic amounts.</p>	<p>Thus, this liquefied treated gruel is consumed more by the infant and indirectly increases the calories per feed.</p>
<p><b>ARF—Source from Germinated Cereals</b></p>  <p><b>Figures 3.4.4A to E:</b> (A) Wheat 6-8 hours; (B) Wheat 48 hours; (C) Pearl millet 72 hours; (D) Sorghum 72 hours; (E) Maize 96 hours. Photo Courtesy: Meenakshi Mehta, Romeen Lavani, Mumbai</p>	<p>Shows time taken for proper germination of different cereals, wheat, pearl millet, sorghum and maize, wheat having the least time taken. “Lokwan” wheat gave best yield of amylase activity at 48 hours.</p>	<p>Use the fully germinated wheat after 48 hours for the next step of preparation.</p>
<p><b>ARF—Step 1</b></p>  <p><b>Figures 3.4.5A and B:</b> ARF—Step 1 Photo Courtesy: Meenakshi Mehta, Romeen Lavani, Mumbai</p>	<ol style="list-style-type: none"> <li>1. Select wheat, clean debris and wash.</li> <li>2. Add sufficient water (3 × vol. of grains), cover, leave for 6 to 12 hours.</li> </ol>	<p>After this step of soaking of wheat, go to the next step of germination.</p>

Picture	Note	Management
<p><b>ARF—Step 2</b></p>  <p><b>Figures 3.4.6A and B:</b> ARF—Step 2 Photo Courtesy: Meenakshi Mehta, Romeen Lavani, Mumbai</p>	<ul style="list-style-type: none"> <li>• Drain excess water</li> <li>• Wrap in a clean wet cloth.</li> </ul>	<p>These are steps in the preparation of ARF. After this process of germination, go to the next step of fully germinated wheat.</p>
<p><b>ARF—Step 3</b></p>  <p><b>Figures 3.4.7A and B:</b> ARF—Step 3 Photo Courtesy: Meenakshi Mehta, Romeen Lavani, Mumbai</p>	<ul style="list-style-type: none"> <li>• Keep covered in a cool dark place</li> <li>• Sprinkle water every 6 to 8 hours to keep the cloth moist.</li> </ul>	<p>After this process of germination of wheat, go to the next step of fully germinated wheat.</p>
<p><b>ARF—Step 4</b></p>  <p><b>Figures 3.4.8A and B:</b> ARF—Step 4 Photo Courtesy: Meenakshi Mehta, Romeen Lavani, Mumbai</p>	<p>We had selected “Lokwan“ Wheat as amongst the varieties of wheat, it yielded maximum ARF.</p> <ol style="list-style-type: none"> <li>1. Soaked wheat after 6 to 8 hours</li> <li>2. Germinated wheat after 48 hours.</li> </ol>	<p>Shows how to germinate wheat for maximum amylase activity.</p>

Picture	Note	Management
<p><b>ARF—Step 5</b></p>  <p><b>Figures 3.4.9A and B:</b> ARF—Step 5 Photo Courtesy: Meenakshi Mehta, Romeen Lavani, Mumbai</p>	<ol style="list-style-type: none"> <li>1. After above respective hours, open the germinated cereal from cloth and put for preliminary drying in air/sun for 1 to 2 hours with occasional stirring .</li> <li>2. Final drying: In sun for 6 hours in bright sunlight or light roasting on low flame in a thick-bottomed <i>kaddai</i> to make completely dry.</li> </ol>	<p>It is essential to dry the germinated wheat because any remaining moisture may spoil the amylase activity.</p>
<p><b>ARF—Step 6</b></p>  <p><b>Figure 3.4.10:</b> ARF—Step 6 Photo Courtesy: Meenakshi Mehta, Romeen Lavani, Mumbai</p>	<ol style="list-style-type: none"> <li>1. Final drying: Light roasting on low flame in mud <i>tawa</i>.</li> <li>2. Manually remove all roots and shoots on a sieve.</li> </ol>	<p>As the shoots contain cyanide, it is essential to remove them.</p>
<p><b>ARF—Step 7</b></p>  <p><b>Figures 3.4.11A and B:</b> ARF—Step 7 Photo Courtesy: Meenakshi Mehta, Romeen Lavani, Mumbai</p>	<ol style="list-style-type: none"> <li>1. Milling by hand pounding or</li> <li>2. Milling in an electric grinder.</li> </ol>	<p>To get the amylase activity the germinated dried wheat, rich in amylase activity has to be powdered so that the amylase rich powder can be used conveniently for the gruel.</p>



Picture	Note	Management
<p><b>ARF—Step 8</b></p>  <p><b>Figure 3.4.12:</b> ARF—Step 8 Photo Courtesy: Meenakshi Mehta, Romeen Lavani, Mumbai</p>	<p>Fill the ARF powder in polythelene bag and keep this bag in a wide mouth, screwcap bottle. It is essential that the ARF powder should be kept moisture proof. The powder retains its activity for 4 to 6 weeks preserved at room temperature.</p>	<p>ARF powder should be stored moisture proof to prevent deterioration of amylase activity.</p>
<p><b>ARF—Step 9</b></p>  <p><b>Figure 3.4.13:</b> ARF—Step 9 Photo Courtesy: Meenakshi Mehta, Romeen Lavani, Mumbai</p>	<ol style="list-style-type: none"> <li>1. Roast the dry ingredients with oil to desirable color and aroma</li> <li>2. Add water and jaggery</li> <li>3. Take the pan off the fire, add ARF. Stir well for 10 min for ARF to act. Bring the contents to boil on fire, stirring continuously. Cool to serve. ARF can also be added as the boiled gruel is cooled.</li> </ol>	<p>To use ARF, add 1 to 2 gm of ARF powder to 100 to 200 gm of multigrain cereal pulse porridge/ gruel to thin/decrease viscosity so that the child is able to consume more and thus has more calories and proteins.</p> <p>ARF powder should be added when the gruel/porridge is almost cooked.</p>
<p><b>ARF—Decrease in Viscosity after Adding ARF</b></p>  <p><b>Figure 3.4.14:</b> Decrease in viscosity after adding ARF Photo Courtesy: Meenakshi Mehta, Romeen Lavani, Mumbai</p>	<p>Both the graphs show decrease in the viscosity of the gruel after adding ARF.</p>	<p>Decreased viscosity decreases bulk and helps in more consumption of gruel.</p>

Picture	Note	Management
<p><b>ARF—The Magic of ARF</b></p>  <p>The illustration shows two stages of a child's development. On the left, a smaller, thinner child is crawling. An arrow points to a larger, fatter child on the right, also crawling. Below this, the text 'Thick Porridge' is written in bold, with an arrow pointing to the text 'Thin Porridge'.</p> <p><b>Figure 3.4.15:</b> The Magic of ARF  <i>Photo Courtesy:</i> Meenakshi Mehta, Romeen Lavani, Mumbai</p>	<p>Share the magic of ARF to increase the weight and quality of health by feeding the child with ARF treated gruel.</p>	<p>Besides, the cost of this ARF powder is &lt; Rs. 30 to 40 lasting for the whole month. Thus, the ARF treated porridges/gruels will help in increasing the energy intake.</p>



## Section 4

---

# Infectious Diseases

### *Section Editors*

Jaydeep Choudhury, Nupur Ganguly

### *Photo Courtesy*

Arun Shah, Atul Kulkarni, Dipankar Das, Jaydeep Choudhury,  
Nupur Ganguly, Prabhas Prasun Giri, Priyankar Pal,  
Ritabrata Kundu, Sandipan Dhar, Swapan Kumar Ray

- 
- 4.1 Common Conditions
  - 4.2 Uncommon Conditions but not Rare
  - 4.3 Infectious Disease Emergencies
  - 4.4 Syndromes

# SECTION OUTLINE

## 4.1 COMMON CONDITIONS 51

### 4.1.1 Bacterial Infections 51

- ◆ Erythema Nodosum 51
- ◆ Scarlet Fever 52
- ◆ Scrofuloderma 52
- ◆ Septic Arthritis 53

### 4.1.2 Viral Infections 53

- ◆ Chickenpox 53
- ◆ Cytomegalovirus 54
- ◆ Dengue 54
- ◆ Enterovirus 54
- ◆ Herpes Simplex Virus 55
- ◆ HIV 55
- ◆ Measles 56
- ◆ Mumps 56
- ◆ Rabies 57
- ◆ Rubella 57

### 4.1.3 Parasites 58

- ◆ Malaria 58
- ◆ Pediculus Humanus Capitis 59
- ◆ Scabies 59

## 4.2 UNCOMMON CONDITIONS BUT NOT RARE 59

- ◆ Brucellosis 59
- ◆ Leptospirosis 60
- ◆ Rickettsia 60

## 4.3 INFECTIOUS DISEASE EMERGENCIES 61


- ◆ Kawasaki Disease 61
- ◆ Purpura Fulminans 61
- ◆ Staphylococcal Scalded Skin Syndrome 62



## 4.4 SYNDROMES 62

- ◆ Lipodystrophy in HIV 62
- ◆ Post-Kala-Azar Dermal Leishmaniasis (PKDL) 63
- ◆ Recurrent Bacterial Meningitis 63
- ◆ Stevens-Johnson Syndrome (SJS) 63

## 4.1 COMMON CONDITIONS

### 4.1.1 Bacterial Infections


Picture	Note	Management
<p><b>Erythema Nodosum</b></p>  <p><b>Figure 4.1.1.1:</b> Erythema nodosum, in the shin bone  <i>Photo Courtesy:</i> Prabhas Prasun Giri, Kolkata</p>	<p>Erythema nodosum (EN) is an acute, nodular, erythematous eruption that is usually limited to the extensor aspects of the lower legs. Chronic or recurrent erythema nodosum is rare but may occur. Erythema nodosum is presumed to be a hypersensitivity reaction which may occur in association with several systemic diseases, drug therapies, or it may be idiopathic. The inflammatory reaction occurs in the panniculus.</p> <p>Lesions begin as red tender nodules (Fig. 4.1.1.1). Lesion borders are poorly defined, and lesions vary from 2 to 6 cm in diameter. During the first week, lesions are tense, hard, and painful; during the second week, they may become fluctuant, as in an abscess, but do not suppurate or ulcerate. Individual lesions last approximately 2 weeks, but occasionally, new lesions continue to appear for 3 to 6 weeks. Aching legs and swollen ankles may persist for weeks.</p> <p>Streptococcal infections and primary tuberculosis are one of the most common causes of erythema nodosum.</p>	<p>In most patients, erythema nodosum is a self-limited disease and requires only symptomatic relief using nonsteroidal anti-inflammatory drugs (NSAIDs), cool-wet compresses, elevation, bed rests, and identification and treatment of the underlying cause.</p>

Picture	Note	Management
<p data-bbox="154 216 326 247"><b>Scarlet Fever</b></p>   <p data-bbox="164 993 600 1146"><b>Figures 4.1.1.2A and B:</b> (A) Scarlet fever showing strawberry tongue and characteristic disquamation of the skin; (B) Strawberry tongue closer view <i>Photo Courtesy:</i> Nupur Ganguly Prabhas Prasun Giri, Kolkata</p>	<p data-bbox="630 277 870 308">It is characterized by:</p> <ul data-bbox="630 318 938 492" style="list-style-type: none"> <li>• Sore throat</li> <li>• Fever</li> <li>• Bright red tongue with a “strawberry” appearance</li> <li>• Rash</li> </ul> <p data-bbox="630 506 1027 1146">Rash is fine, red, and rough-textured, blanches on pressure. It appears 12 to 48 hours after the fever usually starting on the chest, armpits, and behind the ears but sparing the face (although some circumoral pallor is characteristic). It is worse in the skin-folds. Pastia lines (where the rash runs together in the armpits and groin) appear and can persist after the rash is gone. The rash begins to fade three to four days after onset and desquamation (peeling) begins. This phase begins with flakes peeling from the skin. Peeling from the palms and around the fingers occurs about a week later. Peeling also occurs in axilla, groin, and tips of the fingers and toes.</p>	<ul data-bbox="1073 277 1479 1044" style="list-style-type: none"> <li>• Penicillin is the first choice treatment, since Group A beta-hemolytic streptococci (GABHS) remains universally susceptible to penicillin. Although penicillin V is the drug of choice, ampicillin or amoxicillin are equally effective and, due to the good taste, represent a suitable option in children. Moreover, penicillin suspension is not commercially available in our country, so amoxicillin is usually prescribed.</li> <li>• The standard duration of antibiotic therapy is 10 days. To improve the patient’s compliance one should explain the importance of the complete treatment (10 days) to eradicate the bacterium even if, clinical improvement occurs in the first 4 to 5 days of treatment. Macrolides are used in patients who are allergic to beta-lactam antibiotics.</li> </ul>
 <p data-bbox="164 1616 535 1688"><b>Figure 4.1.1.3:</b> Scrofuloderma in the left cervical lymph node <i>Photo Courtesy:</i> Sandipan Dhar, Kolkata</p>	<p data-bbox="630 1279 1036 1882">Scrofuloderma, also called ‘tuberculosis colliquativa cutis’ is a common form of cutaneous tuberculosis affecting children and young adults in which there is breakdown of skin overlying a tuberculous focus in the lymph node, bone or joint. Initially, these are firm painless, subcutaneous nodules that gradually enlarge and suppurate. These lead to ulcers and sinus tracts with undermined edges and ultimately puckered scars. Diagnosis is usually performed by needle aspiration biopsy or excisional biopsy of the mass with microbiological demonstration of acid-fast bacteria. PCR has a low sensitivity but high specificity.</p>	<p data-bbox="1073 1279 1455 1463">Antitubercular drug for the total duration of 6 months which is divided into initial two months intensive phase and continuation phase of four months is recommended.</p>


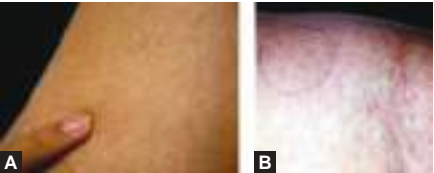

Picture	Note	Management
<p><b>Septic Arthritis</b></p>  <p><b>Figures 4.1.1.4A and B:</b> (A) Septic arthritis in multiple joints; (B) X-ray shows bony erosion in the lower end of the femur and upper end of the tibia.</p> <p><i>Photo Courtesy:</i> Priyankar Pal Prabhas Prasun Giri, Kolkata</p>	<p>The most common causative organism is <i>Staphylococcus aureus</i>. In septic arthritis, different organisms predominate in different age groups. <i>Staphylococcus aureus</i>, <i>Streptococcus agalactiae</i> and <i>Escherichia coli</i> are the most frequent causes of acute hematogenous infection in infants. <i>Staphylococcus aureus</i>, <i>Streptococcus pyogenes</i> and <i>Haemophilus influenzae</i> are common in children below the age of four years.</p>	<p>The treatment of septic arthritis is mainly nonoperative. Surgery is indicated only for drainage of pus. Treatment is supportive for pain and dehydration, splintage, antibiotics therapy and surgical decompression. Analgesics and fluids are used for pain and dehydration, the limb is splinted for comfort and to prevent contractures and antibiotics are commenced empirically. Drugs can be changed when culture and sensitivity results become available. The duration and routes of antibiotic therapy have traditionally been 1 to 2 weeks intravenously followed by 3 to 6 weeks of oral therapy. Some literature suggest a shorter duration of therapy is efficacious. Generally, however, sequential intravenous—oral therapy is the accepted standard. Appropriate intravenous therapy should be continued until there is clinical improvement and the CRP levels approach normal. Oral therapy is then commenced and continued until the ESR normalizes.</p>


#### 4.1.2 Viral Infections

##### Chickenpox

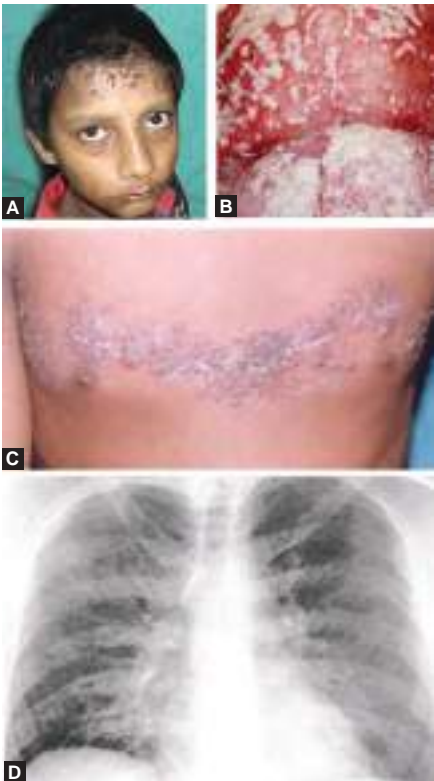
 <p><b>Figures 4.1.2.1A and B:</b> (A) Characteristic rash of chickenpox; (B) Neonatal chickenpox</p> <p><i>Photo Courtesy:</i> Jaydeep Choudhury Sandipan Dhar, Kolkata</p>	<p>Prodromal symptoms are fever, malaise, anorexia and headache. The rash typically begins as crops of small, red papules which develop into clear “tear-drop” vesicles on an erythematous base. They become cloudy and dry up forming scabs which fall off in 5 to 15 days. Various stages of the rash may be seen at the same time. Lesions are more on the trunk, back and shoulders and are pruritic. Rarely, the rash becomes hemorrhagic. The condition generally improves within 7 days.</p>	<ul style="list-style-type: none"> <li>• Treatment is mainly symptomatic and supportive. Paracetamol is given for fever. Aspirin should be avoided as it may increase the risk of Reye’s syndrome. Antihistaminics reduce pruritus.</li> <li>• Acyclovir is safe, effective, but it is not routinely recommended in uncomplicated infection. It is indicated in immunocompromised children. Varicella zoster immunoglobulin (VZIG) provides passive immunity and is indicated for postexposure prophylaxis.</li> </ul>
---	---	--




Picture	Note	Management
 <p><b>Figure 4.1.2.2:</b> Chorioretinitis in cytomegalovirus (CMV) infection <i>Photo Courtesy:</i> Prabhas Prasun Giri, Kolkata</p>	<p>Cytomegalovirus (CMV) infection is severe in immunocompromised. The features are pneumonitis, hepatitis, chorioretinitis with fever and leukopenia. It may be fatal. Retinitis is progressive.</p>	<p>Gancyclovir combined with immunoglobulin, either intravenous immunoglobulin (IVIG) or hyperimmune CMV-IVIG.</p>
 <p><b>Figures 4.1.2.3A and B:</b> Dengue hemorrhagic fever <i>Photo Courtesy:</i> Arun Shah, Muzaffarpur</p>	<p><b>Dengue hemorrhagic fever</b> Stage I – Fever, nonspecific symptoms and positive tourniquet test Stage II – Stage I + spontaneous bleeding Stage III – Circulatory failure, rapid weak pulse, hypotension and narrow pulse pressure.</p> <p><b>Dengue shock syndrome</b> Stage IV – Profound shock with unrecordable BP.</p>	<p>Adequate fluid replacement is the backbone of severe dengue therapy. Sufficient fluid should be administered to maintain effective circulation during plasma leakage. Isotonic cystalloid solution in the fluid of choice but with hypotensive shock (decompensated shock) colloid solutions are to be used. Blood transfusion are reserved for cases of severe bleeding.</p>
 <p><b>Figures 4.1.2.4A to C:</b> Erythematous maculopapular lesions seen in hand-foot-and-mouth disease <i>Photo Courtesy:</i> Sandipan Dhar, Kolkata</p>	<p>Hand-foot-and-mouth disease is a distinctive rash syndrome caused by enteroviruses. It is most frequently caused by coxsackie virus. Scattered vesicles are seen on the tongue, buccal mucosa, posterior pharynx, palate, gingival and lips with surrounding erythema. Maculopapular, vesicular and pustular lesions may also occur on the hands, fingers, feet, buttock and groin. Vesicles resolve in about one week.</p>	<p>Only symptomatic therapy is required.</p>

Picture	Note	Management
 <p><b>Figure 4.1.2.5:</b> Oral herpetic lesion Photo Courtesy: Priyankar Pal, Kolkata</p>	<p>Aggregates of thin-walled vesicles on an erythematous base. These rupture, scab and heal within 7 to 10 days without leaving a scar. Secondary bacterial infection may occur. The lesion tend to recur at the same site particularly at mucocutaneous junction. It is a common cause of gingivostomatitis in children, appear abruptly with pain and salivation.</p>	<p>Oral acyclovir is the mainstay of therapy.</p>


## HIV

 <p><b>Figures 4.1.2.6A to D:</b> (A) Warts in HIV infection; (B) Oral candidiasis; (C) Severe herpes zoster skin lesion; (D) Chest X-ray showing <i>Pneumocystis carinii</i> (PCP) or <i>jiroveci</i> infection. Photo Courtesy: Sandipan Dhar Jaydeep Choudhury, Kolkata</p>	<p>HIV disease progression is variable. Some develop profound immunodeficiency. HIV/AIDS can affect all the systems of the body and the manifestations may be varied. Revised WHO clinical staging of HIV/AIDS are:</p> <p>Stage 1 - Asymptomatic Stage 2 - Mild Stage 3 - Advanced Stage 4 - Severe</p> <p>The typical opportunistic infections are <i>Pneumocystis carinii</i> (PCP) or <i>jiroveci</i>, oral candidiasis and tuberculosis.</p>	<p>Various antiretroviral drugs act on different steps in HIV replication. Combination ART therapy using triple drug combination of nucleoside reverse transcriptase inhibitors (NRTI), non-nucleoside reverse transcriptase inhibitors (NNRTI) and protease inhibitors has changed the quality of life for HIV-infected children. Treatment of opportunistic infections is an integral part of therapy. Proper nutrition and immunization are also vital.</p>
--	---	--


Picture	Note	Management
	<p>Prodromal symptoms are fever, malaise, coryza, cough and conjunctival congestion for 2 to 4 days. Temperature rise abruptly as rash appears on 4th to 6th day. The rash starts as faint erythematous maculopapules on upper lateral aspect of neck and typically behind the ears and increasingly involve face then trunks and finally to legs and arms over next 3 to 4 days. By the time, rash appears on feet it starts disappearing from face. Temperature also suddenly normalizes. As the rash disappears it leaves behind brawny desquamation and brownish discoloration.</p>	<p>Management is mainly supportive. The child may be given antipyretics, fluids and antihistaminics during acute phase. No antiviral therapy is available. The child may be isolated for the period of infectivity. There is an inverse correlation between serum retinol concentration and measles severity. A single dose of vitamin A 100,000 units orally for children 6 to 12 months of age and 200,000 units orally for more than 1 year of age children reduces mortality.</p>

**Figure 4.1.2.7:** Characteristic rash of measles  
*Photo Courtesy:* Jaydeep Choudhury, Kolkata

## Mumps


	<p>Parotitis of one or both parotid glands is the most common manifestation. Earache, jaw tenderness with chewing, and dry mouth worsens over the next several days. The swelling is at the angle of the jaw, and obliterates the angle, often extending to the lower portion of the ear. Defervescence and resolution of parotid tenderness takes about a week.</p>	<p>There is no specific treatment. Symptomatic treatment includes simple analgesics.</p>
---	--	--

**Figure 4.1.2.8:** Parotid gland enlargement in mumps  
*Photo Courtesy:* Jaydeep Choudhury, Kolkata

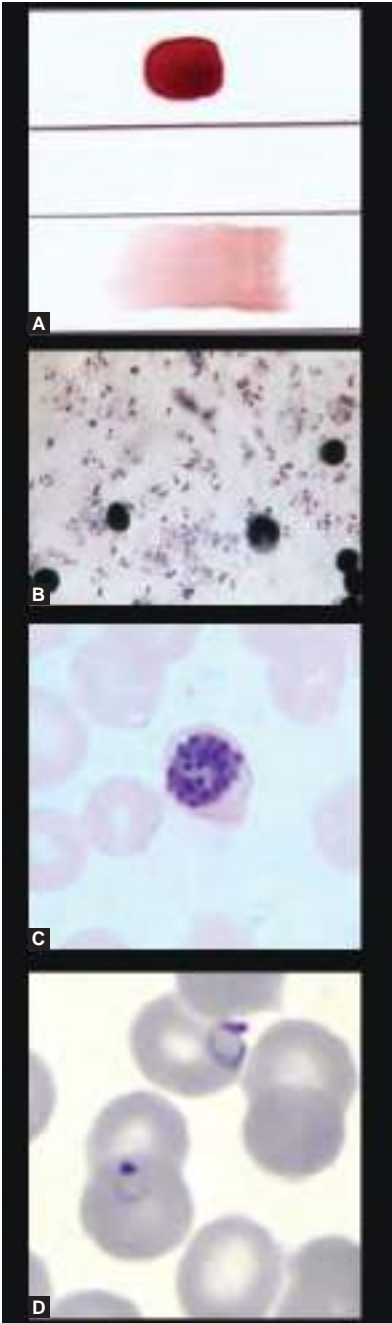
Picture	Note	Management
	<p>Lacerated wound over face and scrotum in a child due to dog bite.</p> <p>There are two distinct clinical forms of rabies:</p> <p>(1) <i>Furious type</i>—Seen in 80% cases, characterized by hydrophobia, erophobia and aggressiveness leading to coma and death.</p> <p>(2) <i>Dumb or paralytic type</i>—This is seen in 20% cases characterized by progressive onset of ascending paralysis.</p> <p>Note the category III multiple bite wounds over face.</p>	<ul style="list-style-type: none"> <li>Do not suture in category III bites. If absolutely necessary, loose sutures only along with instillation or injection of rabies immunoglobulin (RIG).</li> <li>Nursing care, symptomatic therapy with sedatives, analgesics, proper hydration and intensive therapy are some main steps of the treatment of rabies patients. Rabies should be prevented by vaccination (Pre-exposure prophylaxis) and proper precaution following exposure by wound care, rabies immunoglobulin and vaccine administration.</li> </ul>


**Figures 4.1.2.9A and B:** Animal bite injuries in face and scrotum: Dangerous category III exposure  
*Photo Courtesy:* Late Tapan Kumar Ghosh, Kolkata

## Rubella


	<p>Retroauricular, posterior cervical and postoccipital lymphadenopathy. Discrete rose-colored spots on the soft palate (Forchheimer spots) may be seen initially. Skin rash starts on face and spreads rapidly over trunk and is discrete maculopapular but quite variable in size and confluence.</p> <p>In pregnant women, rubella virus can cross the placenta and infect the developing embryo or the fetus resulting in various congenital malformations. Classically, the congenital rubella syndrome (CRS) includes a triad of malformations—cataract, sensorineural hearing loss and congenital heart disease, most commonly patent ductus arteriosus (PDA).</p>	<p>No specific antiviral therapy is available for rubella. Antipyretics are used for symptomatic relief.</p>
---	---	--

**Figures 4.1.2.10A and B:** (A) Neonate presenting with petechiae over body; (B) X-rays of limbs show alternate longitudinal bands of sclerosis and radiolucency in metaphyses, particularly around distal tibial metaphyses, giving rise to so called Celery-Stalk appearance.  
*Photo Courtesy:* Swapan Kumar Ray, Kolkata

Picture	Note	Management
<p data-bbox="152 212 357 245"><b>4.1.3 Parasites</b></p> <p data-bbox="152 255 256 288"><b>Malaria</b></p>  <p data-bbox="152 1653 589 1788"><b>Figures 4.1.3.1A to D:</b> (A) Preparation of thick and thin blood film; (B) Thick film showing numerous malaria parasites; (C) Schizont in a thin blood smear; (D) Falciparum ring form Photo Courtesy: Ritabrata Kundu, Kolkata</p>	<p data-bbox="626 312 1044 1524">Both thin and thick smear should be prepared. Thickness of the thick film should be uniform, which may be ascertained by the legibility of printed text seen through the slide. Thick films are nearly 10 times more sensitive for diagnosis of malaria as larger amount of blood are there in a given area as compared to thin film. Thick film is also used for parasite load detection and thin film is used for species identification. Smears should be prepared soon after blood collection, which ensures better adherence of the films to the slide and causes minimal distortion of parasites and red cells. Stage of parasite can also be ascertained in the peripheral blood. In general, prognosis worsens with predominance of more mature parasite stage. If more than 50% of the peripheral blood parasite are at the tiny ring stage (diameter of the nucleus &lt;50% of the diameter of the rim of cytoplasm), the prognosis is relatively good. Presence of pigment containing asexual parasite of <i>P. falciparum</i> indicates bad prognosis. The presence of malaria pigment in polymorphonuclear leukocyte are diagnostic of malaria. A minimum of 100 fields should be examined before concluding the slide to be negative.</p>	<p data-bbox="1070 312 1487 517">Treatment regimes are to be tailored (with chloroquine or artemisinin combination therapy) according to the species and specifically according to the resistance pattern of the region under consideration.</p>

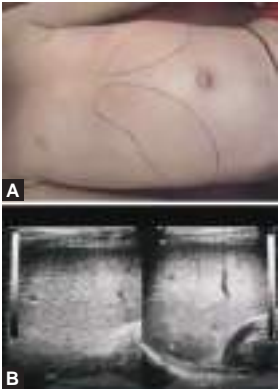
Picture	Note	Management
<p><b>Pediculus Humanus Capitis</b></p>  <p><b>Figure 4.1.3.2:</b> Infestation of the scalp with pediculus humanus capitis. Photo Courtesy: Sandipan Dhar, Kolkata</p>	<p>It is caused by infestation of the scalp with pediculus humanus capitis.</p>	<p>Treatment consists of application of gamma benzene hexachloride (1%) or malathion (0.5%) or permethrin (1%). Gamma benzene hexachloride and malathion should be applied at night and left for 10 to 12 hours and washed off in the morning. Permethrin should also be applied for 30 to 45 min and washed off. Repeat application after a week is desirable. All family contacts and close friends should be treated to prevent reinfection.</p>

### Scabies

 <p><b>Figure 4.1.3.3:</b> Characteristic vesicopapular scabies lesion in axilla Photo Courtesy: Sandipan Dhar, Kolkata</p>	<p>Lesions of scabies in infant are more extensive vesicular and vesicopapular. Eczematization is often present and there may be multiple crusted nodules on the trunk and limbs.</p>	<p>Permethrin (5%) is the treatment of choice in infants and children. It is even safe in infants as young as 2 months. The contact time is 6 to 8 hours in infants 12 to 14 hours in children. If needed, then it may be repeated after two weeks.</p>
---	---	---

## 4.2 UNCOMMON CONDITIONS BUT NOT RARE

### Brucellosis

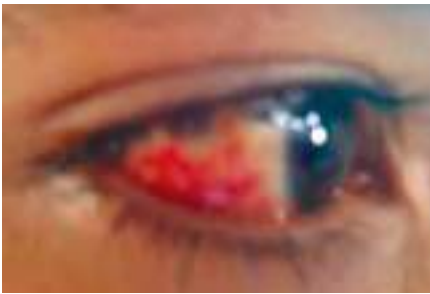 <p><b>Figures 4.2.1A and B:</b> (A) Hepatosplenomegaly in brucellosis; (B) USG showing multiple splenic abscess in brucellosis Photo Courtesy: Nupur Ganguly, Jaydeep Choudhury, Kolkata</p>	<p>The classical triad is fever, arthralgia and hepatosplenomegaly. Constitutional symptoms like anorexia, asthenia, fatigue, weakness, and malaise are very common. Bone and joint symptoms are arthralgias, low back pain, spine and joint pain. Headache, depression and fatigue are the most frequently reported.</p>	<ul style="list-style-type: none"> <li>• Combination therapy is ideal. <i>Monotherapy:</i> It has high relapse rate. Needs prolonged therapy to penetrate the intracellular pathogen.</li> <li>• <i>Above 8 years:</i> Doxycycline + Rifampicin orally for 4 to 6 weeks or Doxycycline 4 to 6 weeks + Streptomycin/Gentamicin IM for 1 to 2 weeks.</li> <li>• <i>Below 8 years:</i> Trimethoprim-Sulfamethoxazole + Rifampicin orally for 4 to 6 weeks.</li> </ul>
--	---	--

## Picture

## Note

## Management

## Leptospirosis



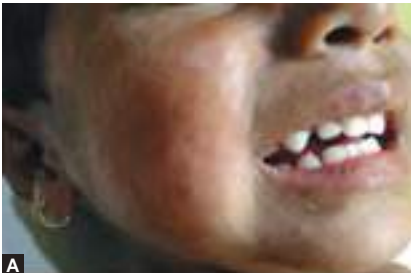**Figure 4.2.2:** Conjunctival suffusion in leptospirosis

Photo Courtesy: Nupur Ganguly  
Jaydeep Choudhury, Kolkata

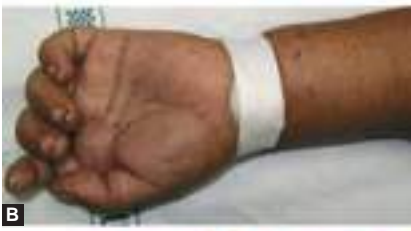The features are high fever with chills, myalgia mainly of calf, abdomen and lumbar region. Severe headache, bilateral conjunctival suffusion, usually in palpebral conjunctiva are seen. Skin rash is red, non-blanching and transient. There may be pretibial erythema. Hepatosplenomegaly may be present.

Leptospira is susceptible to beta-lactam antibiotics, macrolides, tetracycline and fluoroquinolones.

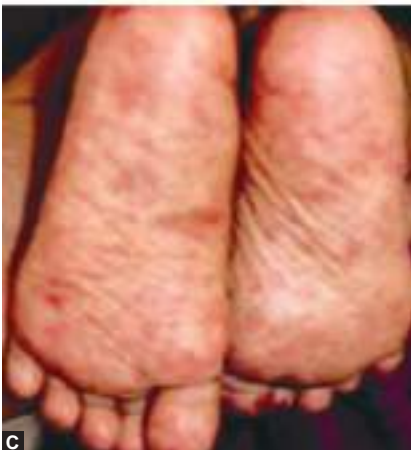## Rickettsia



A



B



C

**Figures 4.2.3A to C:** Characteristic lesion of rickettsial disease over face, palm and sole.

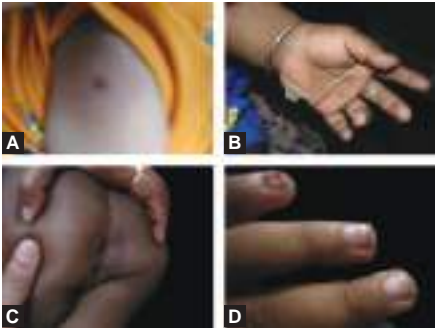
Photo Courtesy: Atul Kulkarni, Solapur

The classical triad is headache, fever and rash. The rash is rose-red blanching macules, spreads rapidly to involve entire body including soles and palms. It may become petechial or hemorrhagic.


Initially, presents with anorexia, myalgia, and arthralgia. Splenomegaly and hepatomegaly may be present. Convulsions, ataxia, meningism, coma, myocarditis, acute renal failure, pneumonitis with acute respiratory distress syndrome (ARDS) may also be present.

Doxycycline and chloramphenicol are the two time-tested drugs in patients of all ages. Other drugs are azithromycin, clarithromycin, fluoroquinolones and rifampicin.

### 4.3 INFECTIOUS DISEASE EMERGENCIES

Picture	Note	Management
<p><b>Kawasaki Disease</b></p>  <p><b>Figures 4.3.1A to D:</b> (A) Kawasaki disease—acute phase—BCG reactivation; (B) Kawasaki disease—acute phase; (C) Kawasaki disease—Subacute phase; (D) Kawasaki disease—convalescent phase—Beau's line Photo Courtesy: Priyankar Pal, Kolkata</p>	<p>Fever, bilateral non-exudative conjunctivitis, erythema of lips and oral mucosa, changes in the extremities, rash, cervical lymphadenopathy, coronary artery aneurysms or ectasia: 15 to 25%, myocardial infarction, sudden death, ischemic cardiac disease in untreated.</p>	<p>Standard therapy is IVIG with aspirin, during the acute phase of illness intravenous immunoglobulin (IVIG) (2 gm/kg) and aspirin 80 to 100 mg/kg/day. Continue high dose aspirin until day 14 of illness, if still afebrile. Continue aspirin 3 to 5 mg/kg/day until no evidence of coronary changes by 6 to 8 weeks.</p>

### Purpura Fulminans

 <p><b>Figure 4.3.2:</b> Cutaneous hemorrhage and necrosis seen in pupura fulminans. Photo Courtesy: Prabhas Prasun Giri, Kolkata</p>	<p>A 5 years old girl presented with meningococemia with purpura fulminans. Fever and features of sepsis.</p> <p>Purpura fulminans (also known as purpura gangrenosa).</p> <p>It is a life-threatening disorder of acute onset. It is characterized by cutaneous hemorrhage and necrosis (tissue death), small vessel thrombosis and disseminated intravascular coagulation. Common causes are severe infection (especially with <i>Meningococcus</i>, and <i>Capnocytophaga canimorsus</i>, and other gram-negative organisms), and deficiency of the natural anticoagulants protein C or protein S in the blood. In some cases, a cause is never found.</p>	<p>Treatment is mainly by removing the underlying cause and degree of clotting abnormalities and with supportive treatment (antibiotics, volume expansion, tissue oxygenation, etc.). Thus, treatment includes aggressive management of the septic state. Surgical debridement, escharotomies, fasciotomies, and even amputations. In many cases, digits may need to be amputated when their blood supply has ceased. The use of full dose heparin or other anticoagulant is controversial.</p>
--	---	---

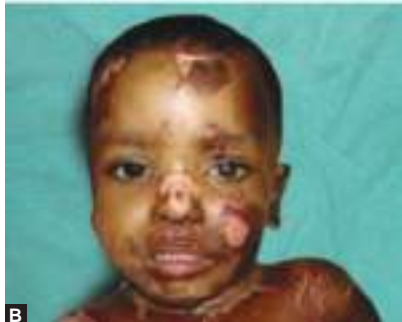
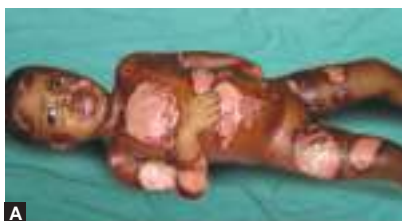
## Picture

## Note

## Management

## Staphylococcal Scalded Skin Syndrome



**Figures 4.3.3A and B:** (A) Erythematous exfoliate lesions seen in staphylococcal scalded skin syndrome; (B) Closer view of the same lesion

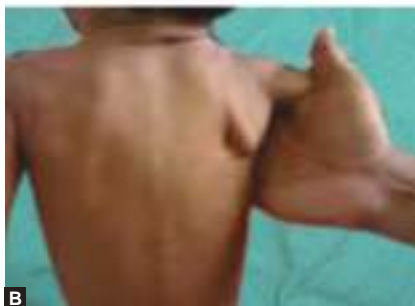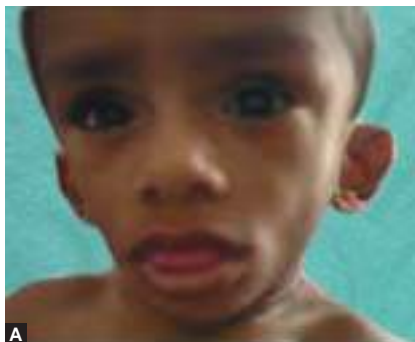Photo Courtesy: Priyankar Pal, Kolkata

Staphylococcal scalded skin syndrome (SSSS) is caused by an epidermolytic toxin producing strain of staphylococci belonging to phase group II. In the initial phase, it produces a generalized macular erythema and a fine stippled, sandpaper or nutmeg-like appearance which progresses to tender scarlatiniform phase over 1 to 2 days. The erythema progresses all over the body. The lesions exfoliate, exudes and crusts around the mouth and periorbital area. Large fragments of crusts separates and within 2 to 3 days the upper layer of the epidermis becomes wrinkled and can be easily peeled off. If there is no secondary skin infection the skin heals without scarring within 14 days of the onset of the disease.

Treatment is eradication of staphylococci from the focus of infection and thus terminating the production of toxin. Topical antibiotics are ineffective. For methicillin sensitive *Staphylococcus aureus* one can use cloxacillin, clindamycin, cefazolin. Penicillin, and cephalosporin allergic patient should receive vancomycin as initial therapy. For methicillin resistant staphylococcal aureus (MRCA), the drug of choice is vancomycin plus gentamycin. Other drugs which can be used are trimethoprim sulfamethoxazole, linezolid, quinupristin-dalfopristin, fluoroquinolone. Parenteral medication is indicated in case of serious infection and those who are severely ill.

## 4.4 SYNDROMES

## Lipodystrophy in HIV






**Figures 4.4.1A and B:** Lipodystrophy seen in the face and back

Photo Courtesy: Prabhas Prasun Giri, Kolkata

Lipodystrophy, commonly known as fat redistribution, is a condition characterized by degenerative and abnormal functioning of the adipose tissue present in an individual's body. Patients suffering from lipodystrophy generally experience loss of fat from selective regions of the body; however, the face, arms and the back are the most commonly affected regions by this disease.

Treatment with antiretrovirals.

Picture	Note	Management
<p data-bbox="126 212 586 253"><b>Post-Kala-Azar Dermal Leishmaniasis (PKDL)</b></p>  <p data-bbox="138 582 542 662"><b>Figure 4.4.2:</b> Dermal Leishmaniasis seen in the face <i>Photo Courtesy:</i> Arun Shah, Muzaffarpur</p>	<p data-bbox="586 212 1029 662">Post-kala-azar dermal leishmaniasis develop later following visceral leishmaniasis when all the parasites are not eradicated. It is seen in 20 to 30 percent of cases. The parasites proliferate locally giving rise to erythematous papule, which evolves to become a nodule with shallow ulceration and raised borders. It is commonly seen in face and extremities.</p>	<p data-bbox="1029 212 1468 662">Spontaneous resolution may take weeks to years and usually results in a flat atrophic scar. Treatment is indicated if the lesions are disfiguring, are persistent, or if the lesions are known to be or might be caused by species that might disseminate to nasopharyngeal or pharyngeal mucosa.</p>
<p data-bbox="126 703 586 744"><b>Recurrent Bacterial Meningitis</b></p>  <p data-bbox="138 1144 571 1246"><b>Figures 4.4.3A to C:</b> (A) Frontal encephalocele; (B) Nasal dermal sinus; (C) Dorsal dermal sinus <i>Photo Courtesy:</i> Dipankar Das, Kolkata</p>	<p data-bbox="586 703 1029 1438">Recurrent bacterial meningitis is two or more episodes of meningitis with a greater-than-3-week interval after the completion of therapy for the initial episode caused by a different bacterial organism. Or a second or further episode caused by the same organism with a greater-than-3-week interval after the completion of therapy for the initial episode. Here the cause of recurrent meningitis is frontal encephalocele, nasal dermal sinus, and dorsal dermal sinus. Bacteria can migrate along congenital preformed pathways or acquired tissue planes to gain entrance into the subarachnoid space or undiagnosed immunodeficiency can render the host defenses as inadequate barriers to potential bacterial pathogens.</p>	<p data-bbox="1029 703 1468 1438">Work-up for immunodeficiency and treatment of the cause.</p>
<p data-bbox="126 1479 586 1520"><b>Stevens-Johnson Syndrome (SJS)</b></p>  <p data-bbox="138 1866 571 1947"><b>Figure 4.4.4:</b> Erythema multiforme like lesions in Stevens-Johnson syndrome (SJS) <i>Photo Courtesy:</i> Arun Shah, Muzaffarpur</p>	<p data-bbox="586 1479 1029 1949">Stevens-Johnson syndrome (SJS) are manifested by erythema multiforme like lesions, typically known as target lesions. Oral and mucosal erosion and ulcerations are seen in 100% cases. Skin blisters and erosion affects body surface area. Fever and myalgia may be present. Healing process may take about two weeks.</p>	<p data-bbox="1029 1479 1468 1949">All the children should be admitted. Offending drug should be stopped. Thermoneutral environment (30-32°C) should be maintained. Role of corticosteroid is controversial. Injection methylprednisolone or dexamethasone may be given. Antihistamines and analgesics may give some symptomatic relief. Proper skin care is very important. Topical emollients and antibiotics may give some relief.</p>



# Section 5

---

# Neurology

**Section Editors**  
PAM Kunju, Anoop Verma

**Photo Courtesy**  
Anandakesavan, Anoop Verma, PAM Kunju, Ritesh Shah

- 5.1 Common Conditions
- 5.2 Uncommon Conditions but not Rare
- 5.3 Neurologic Emergencies
- 5.4 Syndromes

## SECTION OUTLINE

### 5.1 COMMON CONDITIONS 67

- ◆ Anterior Encephalocele 67
- ◆ Arnold-Chiari Malformation—Chiari II 67
- ◆ Arnold-Chiari Malformation—Chiari III—Posterior Encephalocele 67
- ◆ Spina Bifida Occulta/Spina Bifida Cystica 68
- ◆ Brachial Plexus Birth Injury 68
- ◆ Basal Exudates Meningitis 68
- ◆ Bell's Palsy 69
- ◆ Coarse Facies and Dysostosis Multiplex—MPS 69
- ◆ Coarse Facies and Umbilical Hernia—Congenital Hypothyroidism 69
- ◆ Conjunctival Telangiectasia 70
- ◆ Corpus Callosum Agenesis—Devil's Horn 70
- ◆ Corpus Callosum Agenesis—Axial CT 70
- ◆ Corpus Callosum Agenesis 71
- ◆ Diplegic CP—Commando Crawl 71
- ◆ Diplegic CP—Scissoring 71
- ◆ Diplegic with Convergent Squint 72
- ◆ Choreoathetoid CP 72
- ◆ Hemiplegic CP—Cerebral Infarct 72
- ◆ Hemiplegic CP—Cover Test 73
- ◆ Duchenne Muscular Dystrophy (DMD)—Valley Sign 73
- ◆ Duchenne Muscular Dystrophy (DMD)—Pseudohypertrophy 73
- ◆ Gratification Phenomenon (Masturbation) 74
- ◆ Hydrocephalus—Facies 74
- ◆ Hydrocephalus—Postmeningitis 74
- ◆ Hydrocephalus—Aqueductal Stenosis 75
- ◆ Benign Childhood Epilepsy with Centrotemporal Spikes (BCECTS) 75
- ◆ Lennox-Gastaut Syndrome—EEG 75
- ◆ Lennox-Gastaut Syndrome—Tonic Seizure 76
- ◆ Mesial Temporal Sclerosis (MTS) 76
- ◆ Microcephaly 76
- ◆ Myasthenia Gravis 77
- ◆ Oculogyric Spasm 77
- ◆ Rett Syndrome 77
- ◆ Ring Enhancing Lesion 78
- ◆ Sturge-Weber Syndrome 78
- ◆ Sturge-Weber Syndrome—MRI, CT 78
- ◆ Tuberous Sclerosis—MRI 79
- ◆ Tuberous Sclerosis—Skin 79
- ◆ West Syndrome EEG—Hypsarrhythmia 79

### 5.2 UNCOMMON CONDITIONS BUT NOT RARE 80

- ◆ Anencephaly with Large Meningocele 80
- ◆ Dandy-Walker Syndrome 80
- ◆ Facioscapulohumeral Muscular Dystrophy-1 80
- ◆ Facioscapulohumeral Muscular Dystrophy-2 81
- ◆ Glutaric Acidemia Type I 81
- ◆ Glutaric Acidemia Type I—MRI 81
- ◆ Hallervorden-Spatz Disease 82
- ◆ Hallervorden-Spatz Disease—MRI 82
- ◆ Hemimegalencephaly—Linear Nevus Sebaceous Syndrome—MRI 82
- ◆ Hemimegalencephaly—Linear Nevus Sebaceous Syndrome 83
- ◆ Heterotopia 83
- ◆ Periventricular Nodular Heterotopia 83
- ◆ Schizencephaly 84
- ◆ Hydranencephaly 84
- ◆ Lissencephaly 84
- ◆ Metachromatic Leukodystrophy (MLD) 85
- ◆ Myopathic Facies 85
- ◆ Radial Nerve Palsy 86
- ◆ Wilson's Disease—Neurologic 86



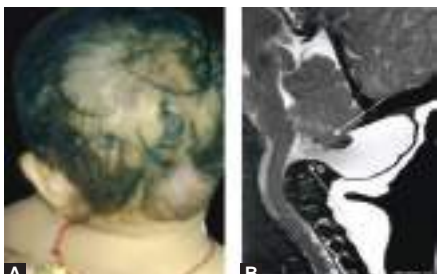
### 5.3 NEUROLOGIC EMERGENCIES 87



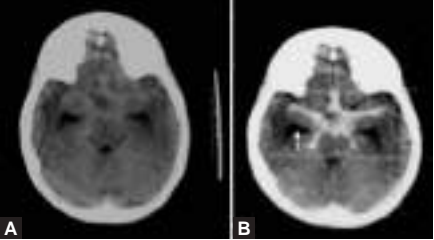
- ◆ Cranial Auscultation—Vein of Galen Malformation (VGM) 87
- ◆ Decerebrate Rigidity and Decorticate Rigidity 87
- ◆ Imaging in Herpes Encephalitis 87
- ◆ Japanese Encephalitis 88
- ◆ Medulloblastoma with Acute Hydrocephalus 88
- ◆ Pseudohypoparathyroidism 88
- ◆ Silver Beaten Appearance—Increased ICP 89
- ◆ Subarachnoid Hemorrhage 89
- ◆ Uncal Transtentorial Herniation 89


### 5.4 SYNDROMES 90

- ◆ Apert Syndrome—Facies 90
- ◆ Cherry Red Spot 90
- ◆ Cornelia de Lange Syndrome 90
- ◆ Cornelia de Lange Syndrome 91
- ◆ Fundus—Choroid Tubercles 91
- ◆ Hypomelanosis of Ito 91
- ◆ Incontinentia Pigmenti 92
- ◆ Miller-Dieker Syndrome 92
- ◆ Xeroderma Pigmentosum 92


## 5.1 COMMON CONDITIONS

Picture	Note	Management
<b>Anterior Encephalocele</b>		
 <p data-bbox="136 588 573 645"><b>Figures 5.1.1A and B:</b> Anterior encephalocele Photo Courtesy: Anandakesavan, Thrissur</p>	<p data-bbox="602 322 1013 578">Encephalocele: Sac protruding through defect in cranium. It contains CSF filled meningeal sac and portions of the brain. The defect occurs most commonly in the occipital region and rarely frontal (Fig. 5.1.1A) or nasofrontal region (Fig. 5.1.1B).</p>	<p data-bbox="1045 322 1451 414">Repair of encephalocele and decompression surgery. Prognosis depends on severity of the defect.</p>
<b>Arnold-Chiari Malformation-Chiari II</b>		
 <p data-bbox="136 1093 573 1177"><b>Figures 5.1.2A and B:</b> Cervical myelomeningocele with ACM II Photo Courtesy: PAM Kunju, Trivandrum</p>	<p data-bbox="602 807 1013 1136">Cervical myelomeningocele (Fig. 5.1.2A) with MRI showing vermis, pons, medulla and fourth ventricle displacement into the cervical canal (Fig. 5.1.2B). ACM II is diagnosed during antenatal ultrasound study to childhood. Associated commonly with lumbar myelomeningocele and hydrocephalus.</p>	<p data-bbox="1045 807 1451 1095">Chiari II malformations are decompressed with suboccipital craniectomy, multilevel cervical laminectomy, duraplasty, and arachnoid dissection. Manage hydrocephalus and myelomeningocele accordingly. Look for associations—needs regular follow-up, VP shunt care.</p>
<b>Arnold-Chiari Malformation-Chiari III—Posterior Encephalocele</b>		
 <p data-bbox="136 1635 573 1719"><b>Figures 5.1.3A and B:</b> Posterior encephalocele and ACM II Photo Courtesy: PAM Kunju, Trivandrum</p>	<p data-bbox="602 1349 1013 1504">Type III involves an occipito-cervical bony defect with herniation of cerebellum into the encephalocele. Most are incompatible with life.</p>	<p data-bbox="1045 1349 1451 1412">Repair of encephalocele and decompression surgery.</p>


Picture	Note	Management
<b>Spina Bifida Occulta/Spina Bifida Cystica</b>		
 <p data-bbox="164 486 597 568"><b>Figures 5.1.4A and B:</b> (A) Spina bifida occulta; (B) Spina bifida cystica Photo Courtesy: Anandakesavan, Thrissur</p>	<p data-bbox="626 273 1037 466">(Fig. 5.1.4A) <i>Spina bifida occulta</i>: Child may be asymptomatic and lack neurologic signs. There may be patches of hair, a lipoma, discoloration of skin or dermal sinus.</p> <p data-bbox="626 472 1037 568">(Fig. 5.1.4B) Meningocele (meninges herniated through the defect) or myelomeningocele.</p>	<p data-bbox="1070 273 1471 513">In occulta look for associations like tethering of cord, syringomyelia and diastematomyelia. Recurrent meningitis of occult origin should prompt careful examination for a small sinus tract in the posterior midline region, including the back of the head.</p>
<b>Brachial Plexus Birth Injury</b>		
 <p data-bbox="164 1236 597 1340"><b>Figures 5.1.5A and B:</b> (A) Complete Brachial plexus with trophic changes; (B) Right Erb's palsy Photo Courtesy: PAM Kunju, Trivandrum</p>	<p data-bbox="626 737 1037 1085">Complete Brachial plexus birth injury with trophic changes—non healing ulcer and callosities. Note the right Horner (Fig. 5.1.5A). Even though Erb's palsy (Fig. 5.1.5B) is the common birth injury affecting brachial plexus, careful examination must be done to find additional root involvement of a complete brachial plexus palsy or to differentiate a Klumpke's paralysis.</p>	<p data-bbox="1070 737 1471 1181">90 to 95% children who are injured during birth improve or recover by 3 to 4 months. Occupational or physical therapy along with short course of prednisolone to be given. The ability to bend the elbow (biceps function) by the third month of life is considered an indicator of probable recovery in Erb's palsy. If not consider surgery by 4 months. Neurolysis/sural nerve graft, with intraoperative EMG/SSEP studies to test the damaged segments.</p>
<b>Basal Exudates Meningitis</b>		
 <p data-bbox="164 1753 597 1874"><b>Figures 5.1.6A and B:</b> Basal exudates (A) Plain scan; (B) Contrast Photo Courtesy: PAM Kunju, Trivandrum</p>	<p data-bbox="626 1498 1037 1780">Plain (Fig. 5.1.6A) and contrast (Fig. 5.1.6B) CT scan of head showing enhancing exudates (black arrow). Note the developing hydrocephalus as the enlarging temporal horn of lateral ventricle (white arrow). Will be seen this much extend only in TBM. This CT is of pneumococcal meningitis.</p>	<p data-bbox="1070 1498 1471 1874">If less than 24 hours duration, no signs of raised intracranial pressure first perform lumbar puncture and start antibiotics. If signs of increased ICP or focal deficits give antibiotics without LP and then obtain a CT scan. Empirical drugs—cefotaxime (200 mg/kg/24 hr, q 6 hr) or ceftriaxone (100 mg/kg/24 hr OD). Treat increased ICP and associated multiple organ system failure (Shock, ARDS).</p>

Picture	Note	Management
<p><b>Bell's Palsy</b></p>  <p><b>Figure 5.1.7:</b> Right low motor neuron (LMN) facial palsy Photo Courtesy: Anoop Verma, Raipur</p>	<p>One of the most common neurologic disorders affecting the cranial nerves. Diagnostic criteria include paralysis or paresis of all muscle groups on one side of the face, sudden onset, and absence of central nervous system disease. Acute onset of unilateral upper and lower facial paralysis (over a 48 hour period), posterior auricular pain, decreased tearing.</p>	<ul style="list-style-type: none"> <li>• Facial palsy improves after treatment with combined oral acyclovir and prednisolone.</li> <li>• Regular physiotherapy from the beginning will help in improvement.</li> <li>• Look for ear infection.</li> </ul>



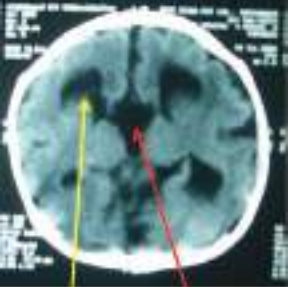
### Coarse Facies and Dysostosis Multiplex—MPS

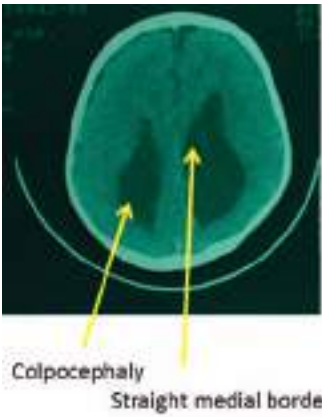


 <p><b>Figures 5.1.8A and B:</b> Hurler facies and beaking of vertebra Photo Courtesy: PAM Kunju, Trivandrum</p>	<p>Delayed development regression—Look for the coarse facies (Hurler phenotype), dysostosis multiplex (beaking of vertebra.</p> <p>Note family history and frequent RT infection/seizure. Other causes of coarse facies—chromosomal anomaly, GM1 gangliosidosis, MPS, etc.</p>	<ul style="list-style-type: none"> <li>• Diagnosis depends on the associations.</li> <li>• If seizures present investigate for GM-1 gangliosidosis.</li> <li>• If no seizures urine for MPS and try to type the MPS by enzyme analysis. Symptomatic management and offer enzyme replacement (e.g. Hurler). Genetic counseling depending on the diagnosis.</li> </ul>
--	--	--




### Coarse Facies and Umbilical Hernia—Congenital Hypothyroidism

 <p><b>Figure 5.1.9:</b> Congenital hypothyroidism Photo Courtesy: Anandakesavan, Thrissur</p>	<p>Delayed development regression—Look for the coarse facies and umbilical hernia. Note history of neonatal jaundice and constipation Most common cause for reversible treatable mental retardation—Hypothyroidism.</p>	<p>Depends on diagnosis—Ultrasound neck and thyroid function tests, skeletal survey, thyroxine to be given as early as possible.</p>
---	---	--



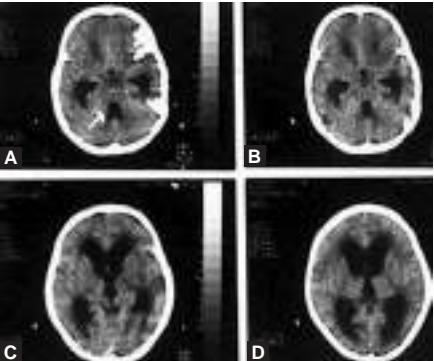


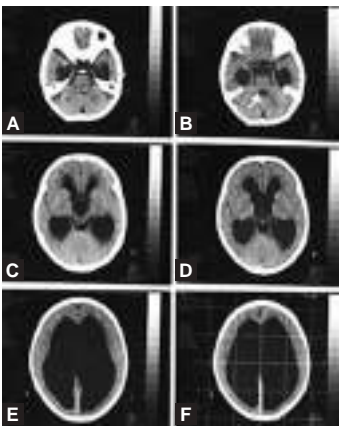
Picture	Note	Management
<b>Conjunctival Telangiectasia</b>		
 <p data-bbox="164 649 488 701"><b>Figure 5.1.10:</b> Ataxia telangiectasia Photo Courtesy: Ritesh Shah, Surat</p>	<p data-bbox="626 273 1027 717">Eight years boy with typical conjunctival telangiectasia seen in ataxia telangiectasia. They appear also on exposed skin area like auricles, nasal bridge, etc. Ataxia telangiectasia is most common inherited cause of early childhood onset ataxia characterized by progressive cerebellar ataxia, oculomotor apraxia, oculocutaneous telangiectasia, choreoathetosis, proclivity to sinopulmonary infections and lymphoreticular neoplasia.</p>	<p data-bbox="1070 273 1479 492">Vigorous supportive therapy with particular attention to recurrent sinopulmonary infection. Treatment of neoplasia must proceed with caution as they are extremely sensitive to radiation and chemotherapy.</p>
<b>Corpus Callosum Agenesis—Devil's Horn</b>		
 <p data-bbox="164 1099 583 1201"><b>Figures 5.1.11A and B:</b> Corpus Callosum Agenesis—Devil's Horn (A) Facies; (B) Sagittal MRI Photo Courtesy: Anoop Verma, Raipur</p>	<p data-bbox="626 862 1027 1279"><i>Facial features:</i> Frontal bossing and hypertelorism and often is associated with divergent squint. <i>Clinical features:</i> Varies with mental retardation or learning disabilities and epilepsy. In some it is clinically silent. Secondary destruction of corpus callosum occurs with hypoxic ischemic encephalopathy (HIE), surgery or infarcts.</p>	<ul data-bbox="1070 862 1479 1279" style="list-style-type: none"> <li>• Symptomatic; Patients with severe neuropsychiatric disorders (developmental delay, autistic features, mental retardation) rehabilitative interventions include: speech therapy, physiotherapy, psychomotor therapy, occupational or educational therapy, parent training and counseling for teachers.</li> <li>• Manage seizure and other neurological problems.</li> </ul>
<b>Corpus Callosum Agenesis—Axial CT</b>		
 <p data-bbox="164 1745 440 1796">Devil's horn appearance Superiorly placed 3<sup>rd</sup> ventricle</p> <p data-bbox="164 1810 583 1884"><b>Figure 5.1.12:</b> Corpus Callosum Agenesis—Axial CT Photo Courtesy: PAM Kunju, Trivandrum</p>	<p data-bbox="626 1432 1027 1549">Axial CT shows upward displacement of the third ventricle and resultant Devil's horn appearance.</p>	<ul data-bbox="1070 1432 1479 1622" style="list-style-type: none"> <li>• Genetic counseling for syndromes and antenatal diagnosis will help in management decision making.</li> <li>• Antenatal diagnosis of agenesis of corpus callosum is possible from 20 weeks gestation.</li> </ul>

Picture	Note	Management
 <p><b>Figure 5.1.13:</b> Corpus callosum agenesis axial CT Photo Courtesy: PAM Kunju, Trivandrum</p>	<p>Axial CT shows widely separated lateral ventricles with straight medial border, and enlargement of posterior horn (Colpocephaly). Interhemispheric lipoma replacing part of the corpus callosum is associated with a high incidence of epilepsy.</p>	<p>Look for other associations like aicardi syndrome (+ infantile spasm and retinal dysplasia), Andermann syndrome (+ mental deficiency, and peripheral neuropathy), trisomies 8, 11, 13 and Glycine encephalopathy and institute management for same.</p>
 <p><b>Figures 5.1.14A and B:</b> (A) Diplegic CP—Commando crawl; (B) Periventricular leukomalacia Photo Courtesy: PAM Kunju, Trivandrum</p>	<p>(Fig. 5.1.14A) Spastic diplegia is bilateral spasticity of the legs greater than in the arms. During crawling uses the arms in a normal reciprocal fashion but tends to drag the legs behind more as a rudder (commando crawl) (Fig. 5.1.14B) Periventricular leukomalacia cause of diplegia. Here seen as dilatation of lateral ventricle, ragged lateral margins, and loss of white matter in the periventricular area.</p>	<p>For early ambulation continuous crawling to be avoided.</p>
 <p><b>Figure 5.1.15:</b> Scissoring Photo Courtesy: PAM Kunju, Trivandrum</p>	<p>Spastic diplegia is bilateral spasticity of the legs greater than in the arms. Signs are:</p> <ol style="list-style-type: none"> <li>1. Scissoring when child is suspended by the axillae.</li> <li>2. Application of a diaper is tough because of the adductor spasm.</li> </ol> <p>Seen in preterm with asphyxia or after intraventricular periventricular hemorrhage. Due to periventricular leukomalacia, particularly the area where fibers innervating the legs are affected.</p>	<ul style="list-style-type: none"> <li>• In diplegia early physiotherapy by the mother to reduce adductor spasm, antispastic drugs like baclofen, diazepam, tizanidine and appropriate splinting.</li> <li>• Before fixed contractures develop multilevel botulinum toxin injection and physiotherapy with abduction splint will help in ambulation.</li> </ul>

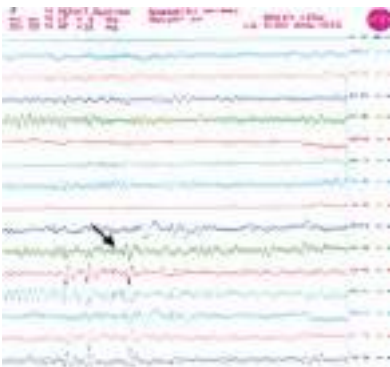
Picture	Note	Management
<b>Diplegic with Convergent Squint</b>		
 <p data-bbox="164 676 594 723"><b>Figure 5.1.16:</b> Diplegic with convergent squint Photo Courtesy: PAM Kunju, Trivandrum</p>	<p data-bbox="626 271 976 396">Common sequelae in preterm asphyxia. Convergent squint is an association of CP due to prematurity.</p>	<p data-bbox="1070 271 1474 363">Treatment by occlusion, corrective glasses and surgery before one year of age to prevent amblyopia.</p>
<b>Choreoathetoid CP</b>		
 <p data-bbox="164 1310 540 1357"><b>Figure 5.1.17:</b> Choreoathetoid CP Photo Courtesy: PAM Kunju, Trivandrum</p>	<p data-bbox="626 874 1024 1064">Extrapyramidal CP secondary to kernicterus and acute intrapartum birth asphyxic symmetric lesions in the posterior putamen and ventrolateral thalamus, viz status marmoratus</p> <p data-bbox="626 1075 808 1105">Athetoid Tetrad</p> <ol data-bbox="626 1109 881 1234" style="list-style-type: none"> <li>1. Choreoathetosis</li> <li>2. Upgaze palsy</li> <li>3. Deafness</li> <li>4. Enamel hypoplasia</li> </ol>	<p data-bbox="1070 874 1482 1193">Exclude conditions like mitochondrial disorders and glutaric aciduria. For chorea tetrabenazine, haloperidol. Trial of LDOPA to exclude DOPA responsive dystonia. Deafness → hearing aid, speech therapy, cochlear implant. Alternate communication methods. Physiotherapy Occupational therapy, special schooling.</p>
<b>Hemiplegic CP—Cerebral Infarct</b>		
 <p data-bbox="164 1810 545 1882"><b>Figure 5.1.18:</b> Porencephaly right middle cerebral artery territory Photo Courtesy: PAM Kunju, Trivandrum</p>	<p data-bbox="626 1498 1040 1622">Brain CT scan in a child with hemiplegic CP—Right middle cerebral artery territory wedge shaped porencephaly due to infarct.</p> <p data-bbox="626 1633 1024 1725">Note the features of Dyke Davidoff Mason syndrome = Hemiatrophy, thickening of skull of right side.</p>	<p data-bbox="1070 1498 1474 1590">Like spastic CP. Focal seizures can be controlled with carbamazepine/oxcarbazepine.</p>

Picture	Note	Management
<p><b>Hemiplegic CP—Cover Test</b></p>  <p><b>Figure 5.1.19:</b> Hemiplegic CP—Cover test Photo Courtesy: PAM Kunju, Trivandrum</p>	<p>Early decreased spontaneous movements on the hemiplegic side can be detected by the covering of face and observing the child always using one hand to remove the cover.</p>	<p>Like spastic CP. Left handed children (Rt sided Hemiplegic) should not be forced to write with right hand.</p>
<p><b>Duchenne Muscular Dystrophy (DMD)—Valley Sign</b></p>  <p><b>Figure 5.1.20:</b> Valley sign of DMD Photo Courtesy: PAM Kunju, Trivandrum</p>	<p><b>Valley sign of DMD</b> Infraspinatus and deltoid muscles are enlarged and between them, the muscles forming the posterior axillary fold are wasted as if there is a valley between the two mounts. Example of selective muscle involvement (atrophy and hypertrophy) Valley sign help in differentiating DMD/BMD from other progressive neuromuscular disorders.</p>	<p>Treatment is aimed at sustaining ambulation and maximizing the quality of life. Corticosteroids such as prednisolone and deflazacort at a dose of 0.6 mg/kg per day for the first 20 days of the month. Add daily vitamin D and calcium for osteoporosis. Beta 2-agonists may increase myocardial muscle strength. Mild, non-jarring physical activity such as swimming is encouraged. Physical therapy orthopedic appliances, etc. are used as per the requirement. Gene therapy like exon-skipping treatment for certain mutations are on trial.</p>
<p><b>Duchenne Muscular Dystrophy (DMD)—Pseudohypertrophy</b></p>  <p><b>Figure 5.1.21:</b> Calf muscle hypertrophy—DMD Photo Courtesy: PAM Kunju, Trivandrum</p>	<p><b>Calf muscle hypertrophy—DMD</b> Example of selective muscle involvement (atrophy and hypertrophy). Pseudohypertrophy of calf also seen in juvenile SMA.</p>	<p>Treatment is aimed at sustaining ambulation and maximizing the quality of life. Corticosteroids such as prednisolone and deflazacort at a dose of 0.6 mg/kg per day for the first 20 days of the month. Add daily vitamin D and calcium for osteoporosis. Beta 2-agonists may increase myocardial muscle strength. Mild, non-jarring physical activity such as swimming is encouraged. Physical therapy orthopedic appliances, etc. are used as per the requirement. Gene therapy like exon-skipping treatment for certain mutations are on trial.</p>

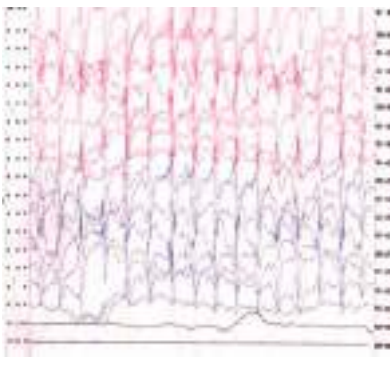
Picture	Note	Management
 <p><b>Figure 5.1.22:</b> Gratification Phenomenon <i>Photo Courtesy:</i> PAM Kunju, Trivandrum</p>	<p>Self-stimulatory behavior in girls between the ages of 2 months and 3 years. Stereotyped movements of tonic posturing associated with copulatory movements followed by flushing, grunting with no loss of consciousness. This condition is more easily identified on video than still image.</p>	<ul style="list-style-type: none"> <li>• Occurs during stress or boredom. The examination should include a search for evidence of sexual abuse or UTI. Reassure that the activity will subside and only distraction and engagement is sufficient.</li> <li>• Piracetam 50 mg/kg is found to be beneficial.</li> </ul>
 <p><b>Figure 5.1.23:</b> Hydrocephalus—Facies <i>Photo Courtesy:</i> PAM Kunju, Trivandrum</p>	<p>Head enlargement, dilated scalp veins tense anterior fontanelle: Open posterior fontanelle, setting sun sign.</p>	<ul style="list-style-type: none"> <li>• Monthly head circumference measurement and if it exceeds more than 2.5 cm/month surgical consideration</li> <li>• Medical: Acetazolamide and furosemide</li> <li>• Surgical: Ventriculoperitoneal (VP) shunt</li> <li>• Endoscopic third ventriculostomy for obstructive hydrocephalus.</li> </ul>
 <p><b>Figures 5.1.24A to D:</b> Hydrocephalus—Post meningitis <i>Photo Courtesy:</i> PAM Kunju, Trivandrum</p>	<p>Notice the enlargement of all ventricles including fourth ventricle (arrow) and the filled up cisterns and sulci—a case of postmeningitis hydrocephalus</p> <p>Seen in bacterial meningitis including tuberculous meningitis.</p>	<p>Early phase repeated lumbar puncture; when CSF protein level low with absence of infection and progressing, VP shunting.</p>


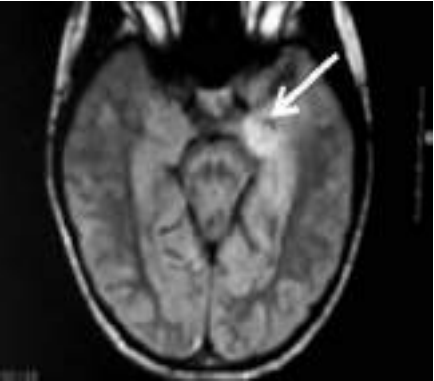

Picture	Note	Management
<p><b>Hydrocephalus—Aqueductal Stenosis</b></p>  <p><b>Figures 5.1.25A to F:</b> Hydrocephalus due to aqueductal stenosis Photo Courtesy: PAM Kunju, Trivandrum</p>	<p>CT scan shows enlargement of all ventricles except fourth ventricle (arrow). A case of Aqueductal stenosis.</p> <p>Look for associations like neural tube defects, including spina bifida occulta, neurofibromatosis.</p> <p>Aqueductal gliosis; similar image-causes: Neonatal meningitis or a subarachnoid hemorrhage in a premature infant, intra-uterine viral infections, mumps meningoencephalitis.</p>	<ul style="list-style-type: none"> <li>• Ventriculoperitoneal shunt before 6 months. Endoscopic third ventriculostomy after age of six months.</li> <li>• Shunting only if progressive and evidence of cortical compression present.</li> </ul>




### Benign Childhood Epilepsy with Centrotemporal Spikes (BCECTS)

 <p><b>Figure 5.1.26:</b> EEG Benign Childhood Epilepsy With Centrotemporal spikes Photo Courtesy: PAM Kunju, Trivandrum</p>	<p>This EEG shows spike from C3 and T3 (Lt central and temporal ) leads with normal background. A case of BCECTS—condition more common in boys, usually starts during sleep with peak age 9 to 10 years.</p> <p>Symptoms: Perirolandic (Oropharyngeal)—starts as guttural noises, unilateral paresthesias of the tongue, cheek and tonic-clonic movement of lower face and ipsilateral extremities and may proceed to secondary generalization. Many times this may cause confusion with generalized epilepsy.</p>	<ul style="list-style-type: none"> <li>• Anticonvulsants should not be prescribed automatically after the initial convulsion. If recurrence Carbamazepine (10-20 mg/kg/day), for at least 2 years or until 14 to 16 years of age.</li> <li>• Some may get aggravated; then try Sodium valproate (20-50 mg/kg/day). Common type of childhood partial epilepsy with excellent prognosis.</li> </ul>
--	--	---

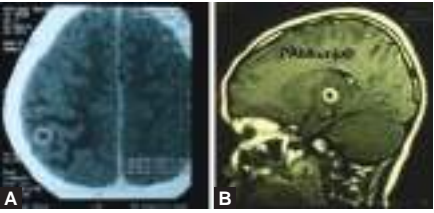

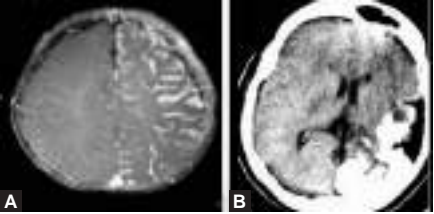
### Lennox-Gastaut Syndrome—EEG

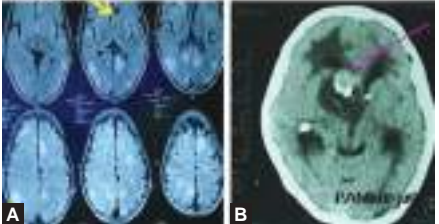
 <p><b>Figure 5.1.27:</b> EEG—slow spike wave Lennox-Gastaut syndrome Photo Courtesy: PAM Kunju, Trivandrum</p>	<p>Interictal slow spike wave 1-2/sec seen in Lennox-Gastaut syndrome. Clinical feature—triad of: (1) Intractable seizures of various types (Stare-Atypical absence, fall-tonic seizure, Jerk—myoclonic) (2) A slow spike wave EEG during the awake state, and (3) Mental retardation. Begins in the third/fourth year of life or may be continuation of west syndrome.</p>	<p>Valproic acid or benzodiazepines may decrease the frequency or intensity of the seizures. Lamotrigine, topiramate and levetiracetam may be useful. Selected cases—the ketogenic diet should be considered for patients whose seizures are refractory to anticonvulsants. Corpus callosotomy will help in reducing the drop attacks.</p>
--	---	--

Picture	Note	Management
<b>Lennox-Gastaut Syndrome—Tonic Seizure</b>		
 <p data-bbox="164 635 540 680"><b>Figure 5.1.28:</b> Tonic seizure Photo Courtesy: PAM Kunju, Trivandrum</p>	<p data-bbox="626 273 1037 560"><i>Tonic seizure:</i> One of the commonest type of seizure in Lennox-Gastaut syndrome in addition to the Triad (Stare-Atypical absence, fall-atonic seizure, Jerk-myoclonic) described above. Focal or generalized tonic-clonic seizures may antedate the onset of myoclonic epilepsy.</p>	<p data-bbox="1070 273 1438 335">Corpus callosotomy surgery will reduce tonic seizures.</p>
<b>Mesial Temporal Sclerosis (MTS)</b>		
 <p data-bbox="164 1208 597 1283"><b>Figure 5.1.29:</b> MRI—Mesial temporal sclerosis (MTS) with CPS (Complex partial seizure) Photo Courtesy: PAM Kunju, Trivandrum</p>	<p data-bbox="626 809 1008 932">Abnormal high-signal intensity in the left hippocampus (arrows); compare with the normal hippocampus on the right</p> <p data-bbox="626 942 1032 1160">Seen in children with intractable complex partial seizures. Mesial temporal sclerosis (MTS). Small hippocampus with increased signal on T2-weighted sequences; Small temporal lobe; Enlarged temporal horn</p> <p data-bbox="626 1171 1016 1201">History of febrile seizures in a few.</p>	<p data-bbox="1070 809 1471 1344">Surgery should be considered for children with intractable seizures unresponsive to anticonvulsants. This involves resection of the anteromedial temporal lobe (temporal lobectomy) or a more limited removal of the underlying hippocampus and amygdala (amygdalohippocampectomy). Prolonged EEG recording with video-monitoring, complemented by neuropsychologic testing, the Wada (intra-carotid injection of amobarbital to establish the dominant hemisphere) test, SPECT and PET are the presurgical evaluation tests.</p>
<b>Microcephaly</b>		
 <p data-bbox="164 1698 597 1774"><b>Figures 5.1.30A and B:</b> Microcephaly and MRI with cystic encephalomalacia Photo Courtesy: Anandakesavan, Thrissur</p>	<p data-bbox="626 1473 1008 1753"><i>Microcephaly:</i> It may be primary (familial, chromosomal anomaly, craniostenosis) or secondary (IU infn., maternal drugs, birth asphyxia) CT scan of this child with severe birth asphyxia and microcephaly showing multiple cystic spaces bilaterally (Cystic encephalomalacia).</p>	<p data-bbox="1070 1473 1479 1876">Establish cause of microcephaly provide accurate and supportive genetic and family counseling. They are also mentally retarded. So assist with placement in an appropriate program that will provide for maximum development of the child. If microcephaly is due to craniosynostosis treatment may include surgical opening of the sutures to let the brain grow normally (in infants younger than 6 months).</p>


Picture	Note	Management
<p><b>Myasthenia Gravis</b></p>  <p><b>Figure 5.1.31:</b> Bilateral ptosis Photo Courtesy: Anoop Verma, Raipur</p>	<p>Autoimmune disorder. Ptosis is the most obvious and prominent sign. The muscle fatigability starts with muscles of the face and neck. Facial weakness is usually bilateral. Weakness of the jaws, soft palate and pharynx produce difficulties in speech and swallowing.</p>	<ul style="list-style-type: none"> <li>• <i>Diagnosis:</i> X-ray of the chest for thymoma. EMG with repeated stimuli, the muscles respond worse and worse with increase of ptosis.</li> <li>• Prostigmine has to be injected 4 to 5 times daily, or pyridostigmine 15 mgm may be given orally immunosuppressive drugs: Prednisone, cyclosporine and azathioprine may be used. Patients are commonly treated with a combination of these drugs with a cholinesterase inhibitor.</li> </ul>
<p><b>Oculogyric Spasm</b></p>  <p><b>Figure 5.1.32:</b> Oculogyric spasm Photo Courtesy: PAM Kunju, Trivandrum</p>	<p>Acute drug-induced dystonia occurs within 24 hours of taking medication, generally metoclopramide or prochlorperazine, although any phenothiazine or related antipsychotics can be responsible. Manifestations include—Bizarre postures of face (Sustained grimacing), Eyes (oculogyric crisis), Jaw (trismus), Tongue - lingual dystonia, Neck (torticollis), Trunk (scoliosis).</p>	<ul style="list-style-type: none"> <li>• The acute reactions are usually self-limited or respond to treatment with anticholinergics such as benztropine or Promethazine injection. Counsel by saying that acute movement is self limiting—so just wait for 24 hours.</li> <li>• Drug-induced Parkinsonism on using haloperidol for Sydenham Chorea can be managed by trihexyphenidyle.</li> </ul>
<p><b>Rett Syndrome</b></p>  <p><b>Figure 5.1.33:</b> Rett Syndrome—handwashing movements Photo Courtesy: PAM Kunju, Trivandrum</p>	<ol style="list-style-type: none"> <li>1. Loss of purposeful hand movements, hand washing movements</li> <li>2. Developmental regression (autistic)</li> <li>3. Acquired microcephaly. Always in girls.</li> </ol> <p><i>Diagnosis:</i> The clinical features + molecular genetic testing for MECP2 mutation. Stages are I—Early onset stagnation period 6/12 month to 1½ year II—Rapid regression 1-3 years III—Pseudostationary stage IV—Late motor regression.</p>	<p>Multidisciplinary approach including symptomatic and supportive medical treatment; physical, occupational, and speech therapy; for seizure anticonvulsant; with late motor impairment (stage IV), L-dopa for rigidity; naltrexone to stabilize breathing irregularities monitoring for scoliosis.</p>



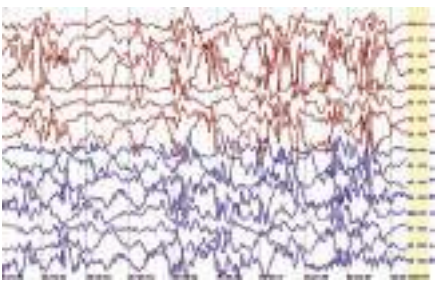
Picture	Note	Management
<b>Ring Enhancing Lesion</b>		
 <p data-bbox="164 498 597 547"><b>Figures 5.1.34A and B:</b> Ring enhancing lesion <i>Photo Courtesy:</i> Anoop Verma, Raipur</p>	<p data-bbox="630 273 1024 329">Note: Ring enhancing lesions on CT/MRI</p> <ul data-bbox="630 339 1024 684" style="list-style-type: none"> <li>• The differential lesions includes:</li> <li>• Tuberculoma</li> <li>• Neurocysticercosis</li> <li>• Cerebral abscess</li> <li>• Metastasis</li> <li>• Glioma</li> <li>• Subacute infarct/hemorrhage/contusion</li> <li>• Demyelination(open ring)</li> <li>• Radiation necrosis</li> <li>• Postoperative change.</li> </ul>	<p data-bbox="1068 273 1474 400">Depends on cause. Tuberculoma—ATT with steroid. Cysticercosis—Albendazole 15 mg/kg × 2 weeks. Antiepileptic drugs.</p>
<b>Sturge-Weber Syndrome</b>		
 <p data-bbox="164 1275 597 1324"><b>Figure 5.1.35:</b> Sturge-Weber syndrome <i>Photo Courtesy:</i> Ritesh Shah, Surat</p>	<p data-bbox="630 880 1036 1228">Eight months child with facial angioma affecting primarily upper face and child has right focal seizure on history. Sturge-Weber syndrome is characterized by angiomas involving the leptomeninges and ipsilateral skin of face, seizure, hemiparesis, headache and developmental delay are most common neurological manifestation.</p>	<p data-bbox="1068 880 1479 1160">Treatment of neurological manifestation include management of seizure and headache. Treatment option for facial angioma include laser therapy using various pulsed-dye lasers, as well as pulsed light photo-facial. Treatment of glaucoma if present is also considered.</p>
<b>Sturge-Weber Syndrome—MRI, CT</b>		
 <p data-bbox="164 1731 597 1855"><b>Figures 5.1.36A and B:</b> (A) Sturge-Weber syndrome—MRI; (B) Sturge-Weber syndrome—CT Scan <i>Photo Courtesy:</i> Ritesh Shah, Surat PAM Kunju, Trivandrum</p>	<p data-bbox="630 1504 1036 1784">(A) MRI of the child with SWS. Ipsilateral leptomeningeal angioma involving entire left hemisphere. It usually involve parietal and occipital area. Other finding on neuroimaging are ipsilateral intracranial calcification (B) And “tram-track sign” of calcific intracranial densities.</p>	<p data-bbox="1068 1504 1474 1692">Most of the patient with seizure achieve control with proper anticonvulsant drugs. Refractory patients should be carefully considered for resection of lobe(s) or hemispherectomy.</p>

Picture	Note	Management
<p><b>Tuberous sclerosis</b></p>  <p><b>Figures 5.1.37A and B:</b> (A) Tuberous sclerosis MRI with tubers; (B) Tuberous Sclerosis CT with subependymal giant cell astrocytoma Photo Courtesy: Ritesh Shah, Surat PAM Kunju, Trivandrum</p>	<p>(Fig. 5.1.37A) MRI brain in tuberous sclerosis complex showing cortical tubers (horizontal arrow) and subependymal nodules (vertical arrow). Other findings are subependymal giant cell astrocytoma (Fig. 5.1.37B) and calcification of nodules.</p>	<p>Tuberous sclerosis complex affect most organ system and treatment vary according to organ manifestation. With regard to neurological manifestation, epilepsy and behavioral disorder are two major treatment focus. Vigabatrin is particularly effective in infantile spasm. Epilepsy surgery has also a role to play in management of selected patients. Development of Subependymal giant cell astrocytoma also to be looked.</p>

### Tuberous Sclerosis—Skin

 <p><b>Figures 5.1.38A and B:</b> Tuberous sclerosis Photo Courtesy: Ritesh Shah, Surat PAM Kunju, Trivandrum</p>	<p>Hypopigmented macule (Ashleaf macule) (Fig. 5.1.38A) over buttock in a child with infantile spasm and tuberous sclerosis complex. Other cutaneous markers in TS are shagreen patch and adenoma sebaceum. (Fig. 5.1.38B) Epilepsy is the most common presenting symptom in tuberous sclerosis complex (80-90%).</p>	<p>Tuberous sclerosis complex affect most organ system and treatment vary according to organ manifestation. With regard to neurological manifestation, epilepsy and behavioral disorder are two major treatment focus. Vigabatrin is particularly effective in infantile spasm. Epilepsy surgery has also a role to play in management of selected patients. Development of Subependymal giant cell astrocytoma also to be looked.</p>
---	---	--

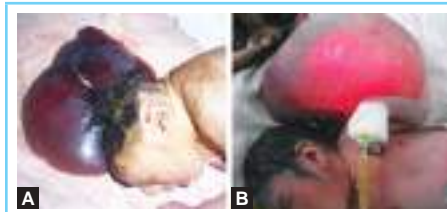### West Syndrome EEG—Hypsarrhythmia

 <p><b>Figure 5.1.39:</b> EEG—Hypsarrhythmia Photo Courtesy: PAM Kunju, Trivandrum</p>	<p>Hypsarrhythmia consists of a chaotic pattern of high-voltage, bilaterally asynchronous, slow-wave activity with multiple spike and polyspike. This EEG with mental retardation and infantile spasm constitute the triad of West syndrome. Begin between the ages of 4 months and 8 months. Three types of infantile spasms: Flexor, extensor, and mixed.</p>	<p>Adrenocorticotrophic hormone (ACTH)—preferred drug. ACTH, 20 U/day intramuscularly (IM) for 2 weeks, and if no response occurs, the dosage is increased to 30 and then 40 U/day IM for an additional 4 weeks. Vigabatrin in infantile spasm of tuberous sclerosis. Permanent Visual field constrictions has been reported.</p>
---	---	---

## 5.2 UNCOMMON CONDITIONS BUT NOT RARE

Picture	Note	Management
---------	------	------------

### Anencephaly with Large Meningocele



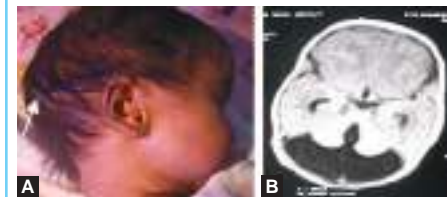**Figures 5.2.1A and B:** Anencephaly  
Photo Courtesy: Anandakesavan, Thrissur

(Fig. 5.2.1A) *Anencephaly*: The cerebral hemisphere, cerebellum. Pituitary gland is hypoplastic and the spinal cord pyramidal tracts are missing. Anomalies like defect of ear, cleft palate and congenital heart disease often associated.

(Fig. 5.2.1B) Transillumination of meningocele, showing that there is no brain tissue inside.

**Prevention:** Couples who had an anencephalic infant should have successive pregnancies monitored including amniocentesis, AFP level measurement and serial USG.

### Dandy-Walker Syndrome

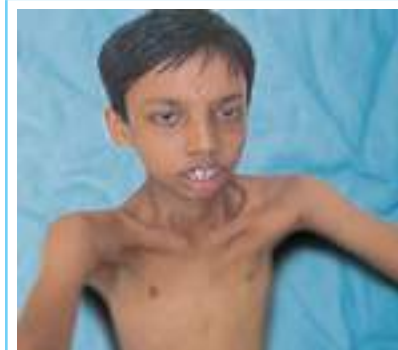

**Figures 5.2.2A and B:** Large head Dandy-Walker syndrome  
Photo Courtesy: Anandakesavan, Thrissur

Large Head with A. Prominent occiput B. CT scan showing cerebellar hypoplasia and cyst in posterior fossa. Shape of the head may give clue to the diagnosis as in this case. Other examples are square or box-shaped head (subdural hygroma), frontal prominence (aqueductal stenosis) and uniform enlargement Chiari malformation with, communicating type hydrocephalus.

Shunting (Ventriculo-peritoneal or cystoperitoneal) for hydrocephalus, physical therapy, speech therapy or specialized education for those with associated handicaps.




### Facioscapulohumeral Muscular Dystrophy-1


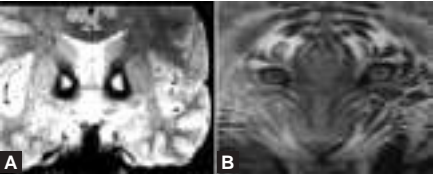






**Figure 5.2.3:** Facioscapulohumeral muscular Dystrophy  
Photo Courtesy: PAM Kunju, Trivandrum


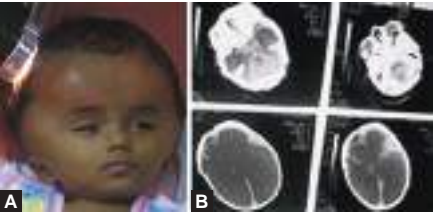

The typical appearance of the shoulders, the downward-sloping clavicles, and the bulge in the region of the trapezius muscle, due to the scapula being displaced upward. Facial weakness shown by pouting mouth—"bucche de tapir" The biceps and triceps are weak and forearm muscles are less involved (leading to a 'Popeye' appearance).

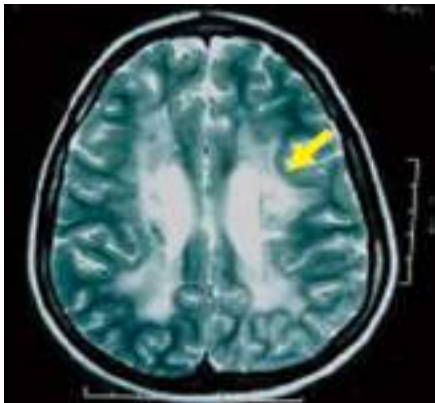
Supportive; Regular physiotherapy. Scapular stabilization, forearm orthosis or ball-bearing feeder device to be useful.

Picture	Note	Management
<b>Facioscapulohumeral Muscular Dystrophy-2</b>		
 <p data-bbox="138 664 557 741"><b>Figure 5.2.4:</b> Facioscapulohumeral muscular dystrophy Photo Courtesy: PAM Kunju, Trivandrum</p>	<p data-bbox="602 271 1019 527">Same patient as in Figure 5.2.3, the typical appearance of the shoulders and the bulge in the region of the trapezius muscle, due to the scapula being displaced upward. The biceps and triceps are weak and forearm muscles are less involved (leading to a 'Popeye' appearance)</p>	<p data-bbox="1045 271 1438 363">Supportive; Scapular stabilization, forearm orthosis or ball-bearing feeder device to be useful.</p>
<b>Glutaric Acidemia Type I</b>		
 <p data-bbox="138 1246 516 1304"><b>Figure 5.2.5:</b> Glutaric acidemia type I Photo Courtesy: PAM Kunju, Trivandrum</p>	<p data-bbox="602 848 992 1165">Deficiency of glutaryl-coenzyme A dehydrogenase; Infant with megalencephaly, an acute encephalopathy regression of development, and progressive choreoathetosis. Cerebral palsy is a misdiagnosis; acidosis, urinary glutaric, 3-hydroxyglutaric, 3-hydroxybutyric, and acetoacetic acids are detectable.</p>	<p data-bbox="1045 848 1393 970">Oral carnitine, Riboflavin supplementation GCDH gene mutation (<i>Chr 19p13.2</i>) can be detected antenatally.</p>
<b>Glutaric Acidemia Type I—MRI</b>		
 <p data-bbox="138 1829 516 1886"><b>Figure 5.2.6:</b> Glutaric acidemia type I Photo Courtesy: PAM Kunju, Trivandrum</p>	<p data-bbox="602 1408 1011 1602">Cerebral atrophy, most marked in the frontal and temporal lobes. wide sylvian fissure (yellow arrow), decreased signal intensity of lentiform nucleus, bifrontal subdural hematoma (green arrow).</p>	<ul data-bbox="1045 1408 1414 1704" style="list-style-type: none"> <li>• Low protein diet (restrict tryptophan and lysine) Oral carnitine, Riboflavin supplementation.</li> <li>• Intrauterine diagnosis by fetal sonography for dilated sylvian fissure in 3<sup>rd</sup> trimester or DNA analysis in end of 1<sup>st</sup> or 2<sup>nd</sup> trimester.</li> </ul>


Picture	Note	Management
<b>Hallervorden-Spatz Disease</b>		
 <p data-bbox="164 697 565 772"><b>Figures 5.2.7A and B:</b> Hallervorden—Spatz disease Photo Courtesy: PAM Kunju, Trivendrum</p>	<p data-bbox="626 275 1036 705">Pantothenate kinase-associated neurodegeneration (PKAN)—Progressive rigidity, first in the foot. (Fig. 5.2.7A) Then in the hand with severe dystonia and spastic immobility (Fig. 5.2.7B) Other features are choreoathetosis and dysarthria. Death within 5 to 10 years. Caused due to iron deposition in brain. Now grouped under neurodegeneration with brain iron accumulation (NIBA).</p>	<p data-bbox="1070 275 1446 363">Treatment for dystonia, baclofen pump, oral trihexyphenidyl, and deep brain stimulation.</p>
<b>Hallervorden-Spatz Disease—MRI</b>		
 <p data-bbox="164 1091 565 1146"><b>Figures 5.2.8A and B:</b> 'Eye of the tiger' sign Photo Courtesy: PAM Kunju, Trivendrum</p>	<p data-bbox="626 903 1036 1173">Coronal T2W MRI—'Eye of the tiger' sign: MRI hyperintensity surrounded by hypointensity in the globus pallidus (GP). <i>Diagnosis:</i> The MRI features + genetic study showing abnormal pank 2 gene; locus is 20p13.</p>	<ul data-bbox="1070 903 1479 1289" style="list-style-type: none"> <li>• Differentiate from other T2 low signal GP—neuronal ceroid lipofuscinosis, fucosidosis and high signal GP—methyl malonic acidemia Kern-Sayre syndrome and anoxic encephalopathy.</li> <li>• <i>Treatment:</i> In PKAN, though iron deposition in GP, iron chelation ineffective. A potential for pantothenate replacement. Stereotactic pallidotomy in severe cases.</li> </ul>
<b>Hemimegalencephaly—Linear Nevus Sebaceous Syndrome—MRI</b>		
 <p data-bbox="164 1821 537 1876"><b>Figure 5.2.9:</b> Hemimegalencephaly MRI Photo Courtesy: PAM Kunju, Trivendrum</p>	<p data-bbox="626 1420 1036 1712">MRI shows abnormal gyration, ventriculomegaly, colpocephaly, an "occipital sign" (displacement of the occipital lobe across the midline), and increased volume and T signal of white matter, in addition to the overall increased size of the involved hemisphere. Clinical features (Fig. 5.2.10)</p>	<ul data-bbox="1070 1420 1479 1786" style="list-style-type: none"> <li>• Look for Associations:</li> <li>• NF 1</li> <li>• Tuberous sclerosis</li> <li>• Klippel-Trenaunay-Weber Proteus syndrome</li> <li>• Hemihypomelanosis of Ito</li> <li>• Epidermal nevus syndrome</li> <li>• Seizure may require multiple anticonvulsants and if intractable surgical hemispherectomy.</li> </ul>

Picture	Note	Management
<b>Hemimegalencephaly—Linear Nevus Sebaceous Syndrome</b>		
 <p data-bbox="138 615 516 690"><b>Figure 5.2.10:</b> Linear nevus sebaceous syndrome <i>Photo Courtesy:</i> PAM Kunju, Trivandrum</p>	<p data-bbox="602 273 1013 396">Linear sebaceous nevus (a hairless plaque on the right scalp and face, eye abnormalities, skeletal deformities and CHD)</p> <p data-bbox="602 410 1013 690">Hemimegalencephaly—MRI shows abnormal gyration, ventriculomegaly, colpocephaly, an “occipital sign” (displacement of the occipital lobe across the midline), and increased volume and T signal of white matter, in addition to the overall increased size of the involved hemisphere.</p>	<ul data-bbox="1045 273 1455 635" style="list-style-type: none"> <li>• Look for Associations:</li> <li>• NF 1</li> <li>• Tuberous sclerosis</li> <li>• Klippel-Trenaunay-Weber Proteus syndrome</li> <li>• Hemihypomelanosis of Ito</li> <li>• Epidermal nevus syndrome</li> <li>• Seizure may require multiple anticonvulsants and if intractable surgical hemispherectomy.</li> </ul>
<b>Heterotopia</b>		
 <p data-bbox="138 1242 516 1289"><b>Figure 5.2.11:</b> Subcortical heterotopia <i>Photo Courtesy:</i> PAM Kunju, Trivandrum</p>	<p data-bbox="602 799 1013 1304">Gray Matter Heterotopia: Clumps of grey matter being located in white matter area, caused by arrested migration of neurons to the cortex. Divided into three: subcortical, subependymal, and band heterotopia (also called double cortex). MRI shows heterotopia as areas of gray matter intensity. They may be identified anywhere in the white matter or protruding into the lateral ventricle from the immediate periventricular region. Symptoms vary from normal to severe developmental delay, seizure or mental retardation.</p>	<p data-bbox="1045 799 1455 921">Management is by antiepileptic drug. No surgery is indicated except corpus callosotomy if seizures are intractable.</p>
<b>Periventricular Nodular Heterotopia</b>		
 <p data-bbox="138 1849 516 1917"><b>Figure 5.2.12:</b> Periventricular nodular heterotopia <i>Photo Courtesy:</i> PAM Kunju, Trivandrum</p>	<p data-bbox="602 1412 1013 1917">Periventricular nodular heterotopia. Axial T1W MR image shows confluent nodules of gray matter lining the walls of the lateral ventricles. Disorders of Neuronal Migration 1. Neuroblasts never having begun migration from the periventricular region produce periventricular nodular heterotopia, 2. Migration, arrested in the subcortical white matter, produces subcortical laminar heterotopia and 3. Neuroblasts reached the cortical plate but lack correct layering, leads to abnormalities of gyration, such as lissencephaly or pachygyria.</p>	<p data-bbox="1045 1412 1455 1494">Management is by antiepileptic drug. No surgery is indicated except corpus callosotomy.</p>


Picture	Note	Management
<b>Schizencephaly</b>		
 <p data-bbox="164 748 548 799"><b>Figure 5.2.13:</b> Schizencephaly Photo Courtesy: PAM Kunju, Trivandrum</p>	<p data-bbox="626 277 1037 748">This picture shows unilateral CSF-filled cleft extending from the ventricle to the periphery. A case of Schizencephaly it is a disorder of neuronal migration characterized by a CSF-filled cleft, which is lined by gray matter. The cleft extends, from the ventricle (ependyma) to the periphery (pia) of the brain. The clefts may be unilateral or bilateral and may be closed (fused lips), or separated (open lips). In porencephaly, scar tissue and white matter are apparent, but in cleft, it is lined with brain tissue.</p>	<p data-bbox="1070 277 1471 369">Presently, there is no cure, but the goal of treatment is to manage the symptoms.</p> <p data-bbox="1070 380 1344 410">Treatment may include:</p> <ul data-bbox="1070 421 1471 625" style="list-style-type: none"> <li>• Anticonvulsants</li> <li>• Surgical shunt in the brain to drain the fluid</li> <li>• Surgical excision of the offending brain tissue that surrounds the cleft.</li> </ul>
<b>Hydranencephaly</b>		
 <p data-bbox="164 1177 548 1228"><b>Figures 5.2.14A and B:</b> Hydranencephaly Photo Courtesy: PAM Kunju, Trivandrum</p>	<p data-bbox="626 952 992 1013">(Fig. 5.2.14A) Transillumination with typical facies.</p> <p data-bbox="626 1024 1037 1218">(Fig. 5.2.14B) CT scan showing absent cerebral hemispheres (due to intrauterine occlusion of bilateral internal carotid arteries). Note the retained brainstem and cerebellum supplied by posterior circulation.</p>	<p data-bbox="1070 952 1484 1075">Ventriculoperitoneal shunt prevents massive enlargement of the cranium. Seizures to be managed with AEDs.</p>
<b>Lissencephaly</b>		
 <p data-bbox="164 1810 548 1862"><b>Figure 5.2.15:</b> Lissencephaly Photo Courtesy: PAM Kunju, Trivandrum</p>	<p data-bbox="626 1391 1037 1627"><i>Lissencephaly:</i> Smooth brain caused by defective neuronal migration during the 12<sup>th</sup> to 24<sup>th</sup> weeks of gestation. 'Agyria' (no gyri) or 'pachygyria' (broad gyri), thick cortex, and transversely placed sylvian fissure gives Figure of 8 appearance.</p>	<p data-bbox="1070 1391 1484 1688">Early stimulation and intervention with OT and PT. Intractable seizures may be controlled with ACTH and multiple medication. If hydrocephalus shunting. Frequent respiratory infection and systemic complications to be addressed. If feeding becomes difficult, a gastrostomy tube may be considered.</p>

Picture	Note	Management
<b>Metachromatic Leukodystrophy (MLD)</b>		
	<p>MLD-T2 W MRI showing Symmetric peri ventricular hyper intensity (demyelination) that spares the subcortical U fibers.</p> <p>MLD presents as Late infantile, Juvenile (incoordination of gait, spasticity, incontinence, dysarthria and peripheral neuropathy), and adult MLD (memory and psychiatric disturbances).</p>	<p>Supportive, physio, antispastic drugs. Bone marrow transplantation and enzyme (arylsulfatase) Replacement were tried.</p>
<p><b>Figure 5.2.16:</b> Metachromatic leukodystrophy Photo Courtesy: PAM Kunju, Trivandrum</p>		




### Myopathic Facies

	<p>Myopathic facies (ptosis, attenuated facial expression, open mouth, tired look) seen in congenital myopathies, congenital muscular dystrophies. Myotonic dystrophy, mitochondrial myopathies and facioscapular humeral muscular dystrophy. Diagnosed by CK, EMG, muscle biopsy and genetic analysis.</p>	<p>The goal is to prevent contracture and skeletal deformity and to keep the patient able to be ambulant as long as possible. Trial of carnitine.</p>
<p><b>Figure 5.2.17:</b> Myopathic facies Photo Courtesy: PAM Kunju, Trivandrum</p>		



Picture	Note	Management
 <p><b>Figure 5.2.18:</b> Schwannoma from radial nerve with wristdrop Photo Courtesy: PAM Kunju, Trivandrum</p>	<p>Schwannoma from radial nerve with wrist drop. Following situations may result in wrist drop: Stab wounds to the chest at or below the clavicle or birth injury damaging the posterior cord of brachial plexus; fracture humerus; lead poisoning; prolonged use of crutches, injection injury, Schwannoma of radial nerve (very rare tumor).</p> <p>Note these points:</p> <ol style="list-style-type: none"> <li>1. Weakness of brachioradialis, wrist extension and finger flexion = radial nerve lesion;</li> <li>2. Weakness of finger extension and radial deviation of the wrist on extension = posterior interosseous nerve lesion;</li> <li>3. Weakness of triceps, finger extensors and flexors = C7,8 lesion;</li> <li>4. Generalized weakness of upper limb marked in deltoid, triceps, wrist extension and finger extension = corticospinal lesion.</li> </ol>	<ul style="list-style-type: none"> <li>• <b>Diagnosis:</b> Nerve conduction velocity, Plain films can help identify bone spurs and fractures; MRI in selected cases</li> <li>• <b>Management:</b> Intracapsular tumor removal and nerve reconstruction. General management in nerve palsy—Physio and cockup splint (a splint used to immobilize the wrist and leave the fingers free) will prevent long-term contracture.</li> </ul>

### Wilson's Disease—Neurologic

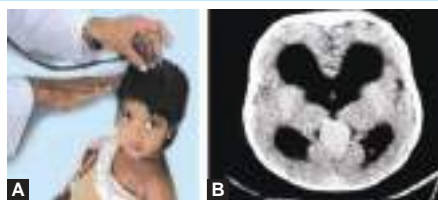  	<p>(Fig. 5.2.19A) Wilson's Disease; sardonic smile, facial grimacing, and dystonia of upper limb.</p> <p>(Fig. 5.2.19B) The Kayser-Fleischer ring, a yellow-brown deposition of copper in the Descemet's membrane of the cornea.</p> <p>(Fig. 5.2.19C) MRI increased signal intensity on putamen and caudate nucleus of the basal ganglia.</p> <p>Neurologic symptoms can be alterations in speech, drooling, and motor dysfunction, and mental changes. Tremor chorea, dystonia, and cerebellar impairment are the earliest manifestations. Other MRI findings—"face of the panda", in the midbrain and "bright caudatum" sign.</p>	<p>Diagnosis by serum ceruloplasmin (reduced), quantification of 24 hours urine copper (elevated, typically exceeds 100 mg/24 hours), slit-lamp examination for the Kayser-Fleischer ring and liver biopsy for histologic and copper content. Management. divided into acute (with Penicillamine) and lifelong maintenance therapy (with Trientine and Zinc). Ceruloplasmin oxidase activity and serum-free copper should be monitored to prevent iatrogenic copper deficiency.</p>
---	--	---

**Figures 5.2.19A to C:** Wilson's disease  
Photo Courtesy: PAM Kunju, Trivandrum

### 5.3 NEUROLOGIC EMERGENCIES

Picture	Note	Management
---------	------	------------

#### Cranial Auscultation—Vein of Galen Malformation (VGM)



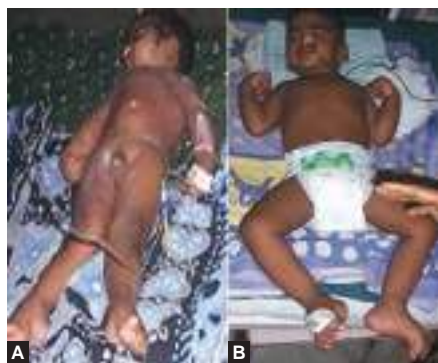**Figures 5.3.1A and B:** Vein of Galen malformation with cranial bruit

*Photo Courtesy:* Anandakesavan, Thrissur

(Fig. 5.3.1A) Cranial auscultation: Cranial bruit can be heard at anterior fontanels, temporal region and over orbit; seen in AVM, vein of Galen malformation, (Fig. 5.3.1B) Hemangioma and Increased ICP. Typically, in the neonatal period, VGM presents with congestive heart failure, and a cranial bruit. Hydrocephalus may be the presenting feature in older infants.

If CCF ventilatory support and institution of aggressive management of heart failure. Acute hydrocephalus —VP shunt. Vaso-occlusive therapy, including selective catheterization and therapeutic embolization of feeding arteries with embolic glue or microcoils.

#### Decerebrate Rigidity and Decorticate Rigidity



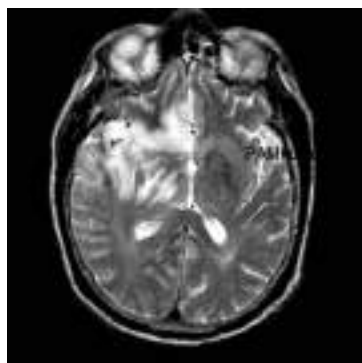
**Figures 5.3.2A and B:** Decerebrate rigidity and decorticate rigidity

*Photo Courtesy:* PAM Kunju, Trivandrum

The terms describe stereotyped arm and leg movements occurring spontaneously or elicited by sensory stimulation in a comatose child extension of the elbows and wrists with pronation (decerebration, Fig. 5.3.2A) indicates damage to motor tracts in the midbrain or caudal diencephalon. Flexion of the elbows and wrists and supination of the arm (decortication, Fig. 5.3.2B) suggests bilateral damage rostral to the midbrain.

Coma demands immediate attention. So the physician must employ an organized approach. ABC should be attended to prior to neurologic assessment. Then establish the severity and nature of coma. If the cause of coma is evident Institute appropriate treatment. The immediate goal is prevention of further CNS damage. Hypotension, hypoglycemia, hypercalcemia, hypoxia, hypercapnia, and hyperthermia should be corrected rapidly.

#### Imaging in Herpes Encephalitis


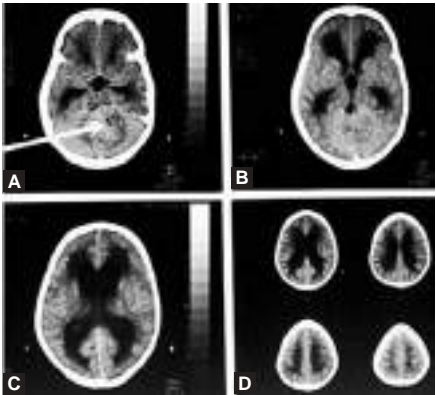



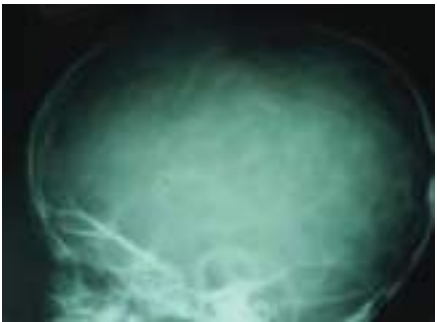
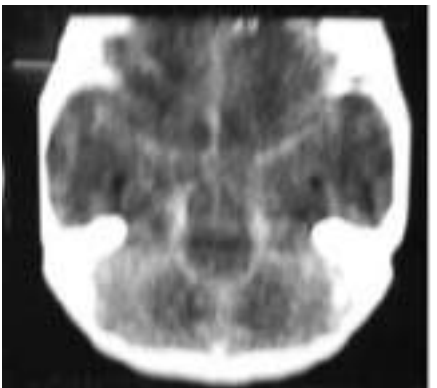

**Figure 5.3.3:** Herpes Encephalitis

*Photo Courtesy:* PAM Kunju, Trivandrum


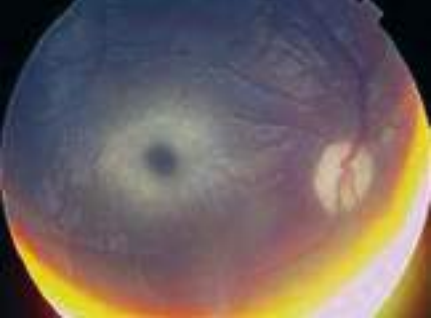

T2-weighted MRI reveals hyperintensity corresponding to edematous changes in the temporal lobes, inferior frontal lobes. Other MRI findings are: Patchy parenchymal or gyral enhancement, restricted diffusion and reduction of the N-acetyl aspartate (NAA)-to-choline ratio are other supportive features.




- Start empiric acyclovir therapy (preferably within 24 hours) in suspected HSE.
- Acyclovir in doses of 10 mg/kg IV every 8 hours in children and 20 mg/kg (60 mg/kg/d) in neonates is currently recommended for HSE.
- Management of increased intracranial pressure, seizure, etc. to be initiated.



Picture	Note	Management
<p><b>Japanese Encephalitis</b></p>  <p><b>Figures 5.3.4A and B:</b> Japanese Encephalitis Photo Courtesy: PAM Kunju, Trivandrum</p>	<p>(Fig. 5.3.4A) Patient with fever, altered sensorium, dystonia and chorea (Fig. 5.3.4B) CT showing basal ganglia hypo-density—“Giant Panda” sign. Japanese Encephalitis-Arthropod-borne (mosquito-borne) Flavivirus causes acute encephalitis; prodrome of nonspecific constitutional symptoms, progresses to disorientation and coma. Tremors, convulsions and focal signs occur. CT and MRI may be normal or show diffuse edema. Bilateral thalamic lesions that have often been hemorrhagic if seen is diagnostic of JE. CSF and lab studies to define the viral etiology helps in diagnosis.</p>	<p>Treatment is mainly supportive. Preventive measures are vector management, vaccination and personal protection.</p>
<p><b>Medulloblastoma with Acute Hydrocephalus</b></p>  <p><b>Figures 5.3.5A to D:</b> Myopathic facies Photo Courtesy: PAM Kunju, Trivandrum</p>	<p>Medulloblastoma (posterior fossa tumor) (arrow) with hydrocephalus, and brainstem compression.</p> <p>Solid mass in 4<sup>th</sup> ventricle, hyperdense with intratumoral necrosis, dilated lateral and 3<sup>rd</sup> ventricle.</p>	<ul style="list-style-type: none"> <li>• Emergency medical (Mannitol, Frusemide, etc.) or surgical (craniotomy) is lifesaving</li> <li>• Emergency VP shunting followed by debulking surgery.</li> <li>• Craniospinal irradiation if &gt;3 years. As intraneural seedling is possible, preoperative evaluation of entire neuraxis required.</li> </ul>
<p><b>Pseudohypoparathyroidism</b></p>  <p><b>Figures 5.3.6A and B:</b> Pseudohypoparathyroidism Photo Courtesy: Anandakesavan, Thrissur</p>	<p>(Fig. 5.3.6A) Shortening of 3<sup>rd</sup> and 4<sup>th</sup> metatarsals.</p> <p>(Fig. 5.3.6B) Basal ganglia calcification</p> <p>Child with tetany and generalized seizure</p> <p>History of abnormal movements</p> <p>On examination: Shortening of 3<sup>rd</sup> and 4<sup>th</sup>) metatarsals and metacaps (not shown).</p> <p>Seen in pseudo hypoparathyroidism. CT scan showing brain calcification mainly in basal ganglia.</p>	<ul style="list-style-type: none"> <li>• IV calcium, supportive treatment and vitamin D supplementation.</li> <li>• If status epilepticus manage with lorazepam and if not controlled Phenytoin followed by phenobarbitone/sodium valproate IV.</li> </ul>

Picture	Note	Management
<p><b>Silver Beaten Appearance—Increased ICP</b></p>  <p><b>Figure 5.3.7:</b> Silver beaten appearance <i>Photo Courtesy:</i> Anandakesavan, Thrissur</p>	<p>X-ray skull of a child with headache and vomiting showing silver beaten appearance and erosion of posterior clinoid process.</p> <p>Other features include sutural separation and scalloping of pituitary fossa.</p> <p>Usual causes include ICSOL , brain abscess and other cause of raised ICT.</p>	<p>Emergency medical (Mannitol, Frusemide, etc.) or surgical (craniotomy) is lifesaving.</p>
<p><b>Subarachnoid Hemorrhage</b></p>  <p><b>Figure 5.3.8:</b> Subarachnoid hemorrhage <i>Photo Courtesy:</i> PAM Kunju, Trivandrum</p>	<p>CT reveals hyperdensity (white) in the subarachnoid and perimesencephalic cisterns.</p> <p>Common cause in children is head trauma. Others include bleeding from a saccular aneurysm, arteriovenous malformation or dural arterial-venous fistula and extension from a primary intracerebral hemorrhage.</p>	<p>The medical management focuses protecting the airway, managing blood pressure before and after aneurysm treatment, preventing rebleeding, managing vasospasm, treating hydrocephalus, treating hyponatremia, and preventing pulmonary embolus. Aneurysm can be “clipped” by a neurosurgeon or “coiled” by an endovascular surgeon.</p>
<p><b>Uncal Transtentorial Herniation</b></p>  <p><b>Figure 5.3.9:</b> 3rd nerve palsy <i>Photo Courtesy:</i> Anandakesavan, Thrissur</p>	<p>A case of 3rd nerve palsy showing partial ptosis with progressive drowsiness. She also had blurred vision due to optic atrophy.</p> <p>MRI scan showing basal exudates, tuberculoma Rt and hydrocephalus with Uncal transtentorial herniation- impaction of the anterior medial temporal gyrus (the uncus) into the tentorial opening just anterior to and adjacent to the midbrain leading to 3rd nerve palsy.</p>	<ul style="list-style-type: none"> <li>• Emergency intubation and hyper ventilation ,antiedema measures (Mannitol, Frusemide,etc.) or surgical decompression (craniotomy) is life saving.</li> <li>• A case of TB Meningitis -Stage III. Supportive treatment, corticosteroid and ATT will reverse the disease to an extent, but residual lesions will be there in more than 50% cases.</li> </ul>

## 5.4 SYNDROMES

Picture	Note	Management
<b>Apert Syndrome—Facies</b>		
 <p data-bbox="164 772 545 825"><b>Figure 5.4.1:</b> Apert syndrome Photo Courtesy: Anandakesavan, Thrissur</p>	<p data-bbox="626 333 1029 584">Sporadic (rarely AD) inherited craniostenosis. Facies- asymmetric and mild proptosis. Characterized by syndactyly of 2<sup>nd</sup>, 3<sup>rd</sup> and 4<sup>th</sup> fingers (and also toes as in this case). All patients have progressive calcification and fusion of bones of hands, feet and cervical spine.</p>	<p data-bbox="1070 333 1472 390">Cosmetic surgery of craniostenosis and syndactyly.</p>
<b>Cherry Red Spot</b>		
 <p data-bbox="164 1267 545 1322"><b>Figure 5.4.2:</b> Cherry red spot Photo Courtesy: PAM Kunju, Trivandrum</p>	<p data-bbox="626 932 997 989">Cherry red spot; 2 disk diameter lateral to the optic disk.</p> <p data-bbox="626 1003 1037 1252">In this patient exaggerated startle response with no organomegaly was suggestive of Tay-Sachs disease. Other neurologic conditions include sandhof disease, GM1 gangliosidosis, and sialidosis (Cherry red spot myoclonus syndrome).</p>	<p data-bbox="1070 932 1472 1050">Depends on etiology. Generally, all the conditions can have myoclonic seizures. It can be managed by clonazepam/sodium valproate.</p>
<b>Cornelia de Lange Syndrome</b>		
 <p data-bbox="164 1763 545 1821"><b>Figure 5.4.3:</b> Cornelia de Lange syndrome Photo Courtesy: Ritesh Shah, Surat</p>	<p data-bbox="626 1428 1016 1647">This picture is of 17 years boy with has severe developmental delay and seizures having thick eyebrows which are meeting in midline(synophrys)—a characteristic feature of Cornelia de Lange syndrome.</p> <p data-bbox="626 1661 1037 1876">Heterozygous mutations in the NIPBL and SMC3 and heterozygous (in females) or hemizygous (in males) mutations in SMC1A result in Cornelia de Lange syndrome. Most cases are sporadic due to <i>de novo</i> mutations.</p>	<p data-bbox="1070 1428 1489 1582">Treatment of seizure and behavioral problems are mainstay. According to degree of developmental delay educational activity should be advised.</p>

Picture	Note	Management
<b>Cornelia de Lange Syndrome</b>		
 <p data-bbox="136 684 529 737"><b>Figure 5.4.4:</b> Cornelia de Lange syndrome Photo Courtesy: Ritesh Shah, Surat</p>	<p data-bbox="602 271 1000 396">Picture of same patient of Cornelia de Lange syndrome showing another typical feature—joining of fingers and missing fingers.</p>	<p data-bbox="1045 271 1459 425">Treatment of seizure and behavioral problems are mainstay. According to degree of developmental delay educational activity should be advised.</p>
<b>Fundus—Choroid Tubercles</b>		
 <p data-bbox="136 1244 521 1299"><b>Figure 5.4.5:</b> Fundus—Choroid tubercles Photo Courtesy: Anandakesavan, Thrissur</p>	<p data-bbox="602 852 989 977">Shows choroid tubercles, the only tuberculosis condition which can be diagnosed without any investigation.</p>	<p data-bbox="1045 852 1239 878">For tuberculosis.</p>
<b>Hypomelanosis of Ito</b>		
 <p data-bbox="136 1831 488 1884"><b>Figure 5.4.6:</b> Hypomelanosis of Ito Photo Courtesy: Anoop Verma, Raipur</p>	<p data-bbox="602 1404 997 1688">Hypomelanosis of Ito (Incontinentia Pigmenti achromians) is characterized by presence of whorled hypochromic skin lesions often associated with seizures, mental retardation, hearing abnormalities, visual problems and orthopedic problems.</p>	<ul data-bbox="1045 1404 1443 1535" style="list-style-type: none"> <li>• Look for hemimegalencephaly/malformations</li> <li>• Treat seizures and institute early infantile stimulation program.</li> </ul>

Picture	Note	Management
<b>Incontinentia Pigmenti</b>		
 <p data-bbox="164 819 513 870"><b>Figure 5.4.7:</b> Incontinentia Pigmenti Photo Courtesy: Anoop Verma, Raipur</p>	<p data-bbox="626 277 959 329">Caused by a genetic defect in X chromosome</p> <ul data-bbox="626 339 1045 880" style="list-style-type: none"> <li>• <i>Clinical manifestations:</i> Infants with IP are born with streaky, blistering areas. When the areas heal, they turn into rough bumps. Eventually, these bumps go away, but leave behind darkened skin, called hyperpigmentation. After several years, the skin returns to normal. In some adults, there may be areas of lighter colored skin (hypopigmentation).</li> <li>• CNS features</li> <li>• Delayed development</li> <li>• Loss of movement (paralysis)</li> <li>• Mental retardation</li> <li>• Muscle spasms</li> <li>• Seizures.</li> </ul>	<p data-bbox="1070 277 1484 369">No specific treatment for IP. Treatment is aimed at the individual symptoms</p>
<b>Miller-Dieker Syndrome</b>		
 <p data-bbox="164 1299 540 1351"><b>Figure 5.4.8:</b> Miller-Dieker syndrome Photo Courtesy: PAM Kunju, Trivandrum</p>	<p data-bbox="626 987 1045 1181">Miller-Dieker syndrome—facial features. Prominent forehead, small, upturned nose, narrowing at the temples, eyes widely spaced Associated with lissencephaly (Fig. 5.2.15).</p>	<p data-bbox="1070 987 1484 1304">Early stimulation and intervention with OT and PT. Intractable seizures may be controlled with ACTH and multiple medication. If hydrocephalus shunting. Frequent respiratory infection and systemic complications to be addressed. If feeding becomes difficult, a gastrostomy tube may be considered.</p>
<b>Xeroderma Pigmentosum</b>		
 <p data-bbox="164 1831 545 1882"><b>Figure 5.4.9:</b> Xeroderma pigmentosum Photo Courtesy: Anandakesavan, Thrissur</p>	<p data-bbox="626 1457 922 1488"><i>Xeroderma pigmentosum:</i></p> <p data-bbox="626 1498 1045 1692">Rare autosomal disorder Skin changes noted during infancy on sun exposed area—erythema, scaling, bullae, crusting, epithelides, telangiectasia, keratosis and basal or squamous cell carcinoma.</p> <p data-bbox="626 1702 1045 1866"><i>Neurological manifestations:</i> mental retardation, microcephaly, sensory-neural deafness, ataxia and choreoathetosis (De Sanctis-Cacchione syndrome).</p>	<ul data-bbox="1070 1457 1484 1763" style="list-style-type: none"> <li>• Protection from sunlight by clothing, eyeglass or opaque sunscreen.</li> <li>• Early detection and removal of malignancy.</li> <li>• Antenatal detection by amniotic fluid culture possible. Affected families should have.</li> <li>• Genetic counseling.</li> </ul>

## Section 6

---

# Cardiology

***Section Editor***  
M Zulfikar Ahamed

***Photo Courtesy***  
Babu George, Balu Vaidyanathan, C Indrani, Lalitha Kailas,  
M Zulfikar Ahamed, PN Manju, Praveen Velappan,  
S Harikrishnan, S Sankar, S Sivasankaran, VH Sankar

- 
- 6.1 History and Clinical Examination
  - 6.2 Heart Diseases Subsections
  - 6.3 Emergencies
  - 6.4 Syndromes



# SECTION OUTLINE

## 6.1 HISTORY AND CLINICAL EXAMINATION 95

- ◆ Helen Taussig 95
- ◆ Robert Gross 95
- ◆ Clubbing and Cyanosis 95
- ◆ Kawasaki Disease (KD) 96
- ◆ Bridge at Arnhem 96

## 6.2 HEART DISEASES SUBSECTIONS 96

### 6.2.1 X-rays 96

- ◆ Anomalous Left Coronary Artery from the Pulmonary Artery (ALCAPA) 96
- ◆ Coarctation of Aorta 97
- ◆ d-TGA 97
- ◆ Dextrocardia with Epicardial Pacemaker 97
- ◆ Dextrocardia with Situs Inversus 98
- ◆ Dextrocardia with Situs Solitus 98
- ◆ Dilated Cardiomyopathy (DCM) 98
- ◆ Eisenmenger Syndrome 99
- ◆ IPAH (Idiopathic PAH) 99
- ◆ Levocardia with Situs Inversus 99
- ◆ PDA Device *in Situ* 100
- ◆ Tetralogy of Fallot (TOF) 100
- ◆ Unobstructed Supracardiac TAPVC 100

### 6.2.2 ECGs 101

- ◆ ECG Machine 101
- ◆ Alternate WPW 101
- ◆ Atrioventricular Septal Defect (AVSD) 101
- ◆ Ebstein Anomaly 102
- ◆ Ebstein Anomaly (Newborn) 102
- ◆ Long QT Syndrome 102
- ◆ Tricuspid Atresia 103
- ◆ Wenckebach Phenomenon 103
- ◆ Wolf-Parkinson-White (WPW) Syndrome 103

### 6.2.3 Echocardiography 104

- ◆ Echocardiographic Machine 104
- ◆ 3D Echo Picture of VSD 104
- ◆ Absent Pulmonary Valve Syndrome 105

- ◆ Coronary Artery Dilatation in Kawasaki Disease 105
- ◆ Device Closure of ASD 106
- ◆ Ebstein Anomaly 106
- ◆ Lutembacher Syndrome 106
- ◆ Mitral Stenosis (MS) 107
- ◆ Mitral Regurgitation—Rheumatic 107
- ◆ Ostium Secundum ASD with L → R Flow 107
- ◆ PDA with L → R Shunt 108
- ◆ Rhabdomyoma in the LV 108
- ◆ Tetralogy of Fallot 108
- ◆ Unobstructed TAPVC 109
- ◆ Vegetations on Aortic Valve 109
- ◆ Viral Myocarditis 109

### 6.2.4 Angiography/Pathological Specimen 110

- ◆ Catheterization Lab 110
- ◆ Balloon Dilatation of Pulmonary Valve (BPV) 110
- ◆ Balloon Mitral Valvotomy (BMV) 110
- ◆ Coil Occlusion of PDA 111
- ◆ Pulmonary AV Fistula (PAVF) 111
- ◆ Septal Occluder (Amplatzer Device) 111
- ◆ Pathology Specimen Showing Single Ventricle 112

## 6.3 EMERGENCIES 112


- ◆ Atrial Flutter with 4:2 and 6:3 AV Block 112
- ◆ Complete Heart Block 112
- ◆ d-TGA in the Newborn 113
- ◆ Obstructed TAPVC 113
- ◆ SVT 113

## 6.4 SYNDROMES 114

- ◆ A Teenage Girl with Turner Syndrome 114
- ◆ DiGeorge Syndrome 114
- ◆ Down Syndrome with Atrioventricular Septal Defect (AVSD) 115
- ◆ Edward Syndrome 115
- ◆ Noonan Syndrome 115

## 6.1 HISTORY AND CLINICAL EXAMINATION

Picture	Note	Management
<b>Helen Taussig</b>		
 <p data-bbox="138 731 391 782"><b>Figure 6.1.1:</b> Helen taussig Source: Web collection</p>	<p data-bbox="602 322 1013 543">Helen Taussig (1898-1986) is considered the mother of Pediatric Cardiology. She worked in John Hopkins Hospital, USA. Her seminal work is titled 'Congenital Malformations of the Heart', which was published in 1947.</p>	<p data-bbox="1045 322 1455 656">She hit upon the idea of a shunt between a systemic artery and pulmonary artery to improve saturation in a cyanotic baby. Alfred Blalock was the surgeon who applied her idea into practice and did the first ever shunt for Tetralogy of Fallot (TOF) and is rightfully called Blalock-Taussig-Thomas shunt. This was performed in a 11 months old baby in 1944.</p>
<b>Robert Gross</b>		
 <p data-bbox="138 1279 467 1330"><b>Figures 6.1.2A and B:</b> Robert Gross Source: Web collection</p>	<p data-bbox="602 962 1013 1218">Robert Gross (1905-1988) was a Pediatric Surgeon who worked in Boston Children Hospital, USA. He performed the first ever cardiac surgery in the world in 1938 by ligating a PDA of a very sick child and gave a reason for diagnosing CHD to Pediatricians.</p>	<p data-bbox="1045 962 1455 1187">This historical landmark paved way for surgical interventions in CHD. Later on BT shunt was performed in 1944. The first corrective repair using cardiopulmonary bypass (open heart) for congenital heart disease (CHD) was for ASD in 1953.</p>
<b>Clubbing and Cyanosis</b>		
 <p data-bbox="138 1825 472 1876"><b>Figure 6.1.3:</b> Clubbing and cyanosis Photo Courtesy: M Zulfikar Ahamed</p>	<p data-bbox="602 1502 1013 1851">Both hands showing significant cyanosis and clubbing. Cyanosis becomes apparent when arterial saturation comes down to 80 to 85%, normal arterial saturation being above 95%. This occurs in congenital cyanotic heart diseases. Cyanosis is often accompanied by clubbing of varying grades. Clubbing without cyanosis in heart disease occurs in infective endocarditis.</p>	<p data-bbox="1045 1502 1455 1821">All cyanotic congenital heart diseases (CCHDs) will require surgical intervention. In the newborn, stabilization is achieved by oxygen, prostaglandin E, balloon atrial septostomy and palliative shunts. Later, intracardiac repair is offered at the appropriate age. Today 90% of all CCHDs can be repaired or palliated.</p>

Picture	Note	Management
<p><b>Kawasaki Disease (KD)</b></p>  <p><b>Figures 6.1.4A to C:</b> Kawasaki disease Photo Courtesy: M Zulfikar Ahamed, Lalitha Kailas</p>	<p>Both hands and feet show peeling with edema of the feet. These are classical skin manifestations in Kawasaki disease (KD). Edema is an early feature. Peeling occurs later—10 to 14 days. KD is characterized by fever lasting for more than 5 days, mucus membrane changes, non-purulent conjunctivitis, cervical lymphadenopathy along with limb changes. It can produce coronary artery lesion (CAL) in 20 to 25% if not treated early.</p>	<p>The treatment of choice for KD is intravenous immunoglobulin (IVIG) 2 gm/kg as an infusion for 12 hours. IVIG reduces the incidence of CAL to 5% from 25%. In addition, high dose aspirin (60–100 mg/kg/day) is given initially, followed by low dose aspirin (5 mg/kg) for a variable period of time. KD is slowly emerging as the second most common cause of acquired cardiac illness in children in India, next only to rheumatic fever (RF).</p>

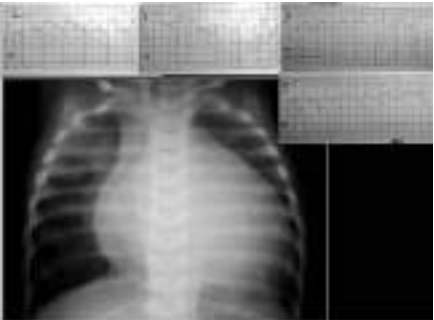
### Bridge at Arnhem




 <p><b>Figure 6.1.5:</b> Bridge at Arnhem Source: Web collection</p>	<p>The bridge at Arnhem, Netherlands is very famous on two counts. The siege of the Western Netherlands by Germans during world war II near Arnhem resulted in the infamous Dutch famine. Allied forces unsuccessfully tried to capture the bridge, among other places, towards the end of the war. The Dutch famine gave an opportunity to study the ill effects of a famine on a long-term basis. The Dutch Famine Birth Cohort Study was a landmark one to give epidemiological proof for Barker Hypothesis.</p>	<p>Barker's hypothesis states that babies born LBW are likely to develop obesity, insulin resistance, hypertension and are at higher risk for developing CAD in adulthood. Hence, the preventive cardiology services should aim also at reducing LBW.</p>
--	---	---




## 6.2 HEART DISEASES SUBSECTIONS




### 6.2.1 X-rays

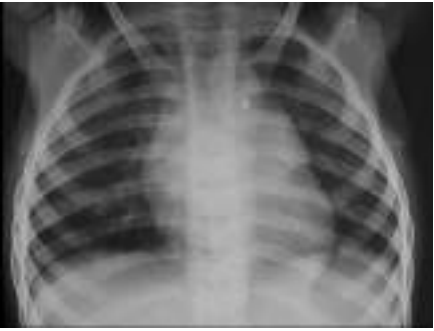


#### Anomalous Left Coronary Artery from the Pulmonary Artery (ALCAPA)


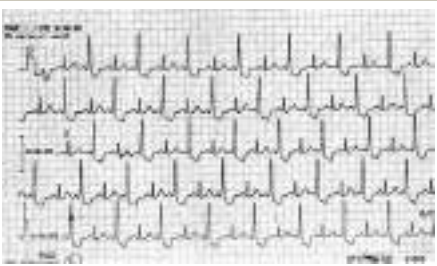
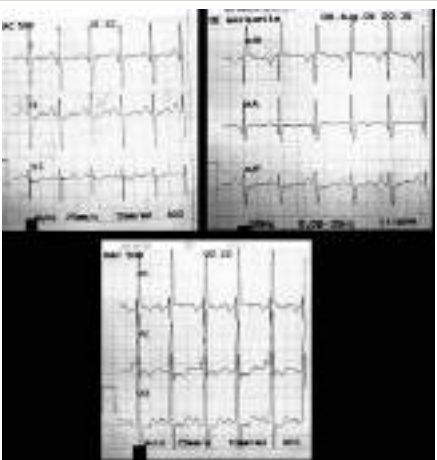
 <p><b>Figure 6.2.1.1:</b> ALCAPA Photo Courtesy: M Zulfikar Ahamed</p>	<p>The X-ray shows gross cardiomegaly, globular heart and bi atrial enlargement suggesting dilated cardiomyopathy (DCM). However, the ECG shows ST elevation in V2-V5 (anterior wall infarction), which is quite characteristic of ALCAPA. It is a remediable cause of 'DCM'. Other remediable causes of LV dysfunction mimicking DCM are Coarctation of Aorta, AS, Carnitine dependent DCM and tachycardiomyopathy.</p>	<p>ALCAPA is now managed with coronary translocation. LCA is translocated from Pulmonary Artery to Aortic root. Previously a procedure known as Takeuchi surgery was adopted.</p>
--	--	---

Picture	Note	Management
<b>Coarctation of Aorta</b>		
	<p>There is minimal cardiomegaly with normal lung vascularity. Ascending aorta and knuckle are dilated. The most striking finding is rib notching from 3<sup>rd</sup> rib onwards, particularly prominent on left. Rib notching is due to dilated intercostal arteries forming collaterals. Rib notching occurs usually beyond 4 to 6 years of age. Careful observation in this X-ray will reveal a 3 sign.</p>	<p>Coarctation with significant gradient should be corrected. It is usually done by surgical resection and anastomosis. Balloon dilatation with stenting can be offered to children above 12 years.</p>
<p><b>Figure 6.2.1.2:</b> Coarctation of aorta <i>Photo Courtesy:</i> M Zulfikar Ahamed</p>		
<b>d-TGA</b>		
	<p>The egg on side appearance. The appearance takes a few weeks to develop and is due to mild cardiomegaly, RV apex, RA enlargement, narrow base and pulmonary plethora. Newborn in the first week will not show egg on side appearance.</p>	<p>Management includes PGE 1, oxygen, and improving saturation by BAS. Ideal surgery is arterial switch operation (ASO) where aorta is translocated to LV and PA to RV with coronary transfer.</p>
<p><b>Figure 6.2.1.3:</b> d-TGA <i>Photo Courtesy:</i> M Zulfikar Ahamed</p>		
<b>Dextrocardia with Epicardial Pacemaker</b>		
	<p>There is dextrocardia with situs solitus. The most common CHD in the situation is L-TGA (congenitally corrected transposition of great vessels). We can see the pacemaker lead attached by epicardial route.</p>	<p>The L-TGA is associated with complete heart block which requires pacemaker insertion (PPI). Treatment of L-TGA include double switch if feasible, correction of intracardiac defects and PPI if required.</p>
<p><b>Figure 6.2.1.4:</b> Dextrocardia with epicardial pacemaker <i>Photo Courtesy:</i> Praveen Velappan</p>		



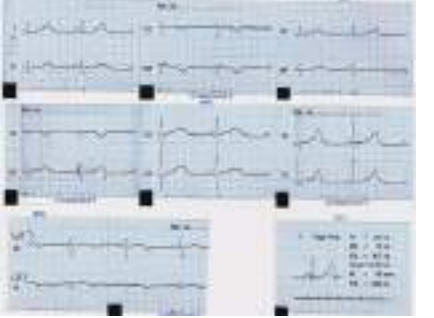
Picture	Note	Management
<p data-bbox="152 212 589 247"><b>Dextrocardia with Situs Inversus</b></p>  <p data-bbox="160 684 597 733"><b>Figure 6.2.1.5:</b> Dextrocardia with situs inversus <i>Photo Courtesy: M Zulfikar Ahamed</i></p>	<p data-bbox="626 273 1039 400">Also called mirror image dextrocardia. Has lower incidence of CHD (5%). It can be associated with Kartagener's syndrome.</p>	<p data-bbox="1070 273 1463 335">CHDs are less complex and are managed according to their merit.</p>
<p data-bbox="152 737 589 772"><b>Dextrocardia with Situs Solitus</b></p>  <p data-bbox="160 1295 597 1344"><b>Figure 6.2.1.6:</b> Dextrocardia with situs solitus <i>Photo Courtesy: M Zulfikar Ahamed</i></p>	<p data-bbox="626 885 1031 1038">Also called isolated dextrocardia or dextroversion. Ninety percent of them will have CHD. Almost half of them will be L-TGA with/without VSD/PS or both.</p>	<p data-bbox="1070 885 1474 1071">As most of these children will have CHD, surgery or interventions are required. There may be technical difficulties encountered in such surgeries owing to malposition and rare CHD.</p>
<p data-bbox="152 1344 589 1379"><b>Dilated Cardiomyopathy (DCM)</b></p>  <p data-bbox="160 1835 597 1884"><b>Figure 6.2.1.7:</b> Dilated cardiomyopathy <i>Photo Courtesy: M Zulfikar Ahamed</i></p>	<p data-bbox="626 1473 1011 1659">There is huge cardiomegaly with globular cardiac shadow. Cardiophrenic angles are clear. There is biatrial enlargement and near normal lung vascularity. The base is narrow.</p>	<p data-bbox="1070 1473 1474 1729">DCM is managed with ACE inhibitors, digoxin, diuretics and <math>\beta</math>-Blockers. The natural history is rather dismal. Children fare better than adults and spontaneous improvement has been reported. In end stage DCM, heart transplant may have to be done.</p>

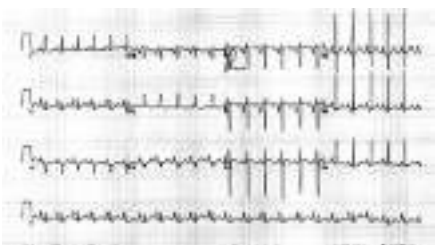
Picture	Note	Management
<b>Eisenmenger Syndrome</b>		
 <p data-bbox="139 641 573 690"><b>Figure 6.2.1.8:</b> Eisenmenger syndrome <i>Photo Courtesy: M Zulfikar Ahamed</i></p>	<p data-bbox="602 273 1013 396">The minimal cardiomegaly, hugely dilated MPA, LPA and RDPA and peripheral pruning of lung blood vessels.</p> <p data-bbox="602 408 1013 662">Eisenmenger syndrome is severe PVOD due to a L→R shunt which causes either bidirectional shunt or R→L shunt. The primary shunt could be ASD, VSD, PDA, AP window or AVSD. The defect is inoperable. However the 10 years survival is 80%.</p>	<p data-bbox="1045 273 1456 457">Treatment is nonsurgical and supportive, warfarin, sildenafil, calcium channel blockers and bosentan have been tried. Heart lung transplantation is the only definitive answer.</p>
<b>IPAH (Idiopathic PAH)</b>		
 <p data-bbox="139 1246 573 1295"><b>Figure 6.2.1.9:</b> IPAH (Idiopathic PAH) <i>Photo Courtesy: M Zulfikar Ahamed</i></p>	<p data-bbox="602 907 1013 1193">There is no cardiomegaly, with dilated MPA, LPA and RDPA and peripheral pruning. It is difficult to distinguish the X-ray picture from that of Eisenmenger syndrome. IPAH is a rare but very sinister disease which can affect young children also. Five years survival is only 20%.</p>	<p data-bbox="1045 907 1456 1091">Treatment consists of high dose calcium channel blockers, warfarin, sildenafil and bosentan. Inhaled or intravenous prostacyclins will improve survival. Home O<sub>2</sub> therapy is also useful.</p>
<b>Levocardia with Situs Inversus</b>		
 <p data-bbox="139 1827 573 1876"><b>Figure 6.2.1.10:</b> Levocardia with situs inversus <i>Photo Courtesy: M Zulfikar Ahamed</i></p>	<p data-bbox="602 1492 1013 1614">This is quite rare. This is also called isolated levocardia. This situation has 99% incidence of CHD, mostly L-TGA.</p>	<p data-bbox="1045 1492 1456 1582">Almost all CHDs are complex. Some may need 2 staged surgery and pacemaker also.</p>

Picture	Note	Management
<b>PDA Device <i>in Situ</i></b>		
 <p data-bbox="164 619 493 670"><b>Figure 6.2.1.11:</b> PDA device <i>in situ</i> Photo Courtesy: M Zulfikar Ahamed</p>	<p data-bbox="626 273 997 363">The device is seen as circular structure near pulmonary artery (PA) shadow.</p>	<p data-bbox="1070 273 1474 558">Currently the procedure of choice for all moderate and large PDAs is device closure. Various devices are present in the market—Amplatzer, Cocoon, etc. The success rate is 97 to 99% and mortality nil. The patient should be put on low dose aspirin for six months following the procedure.</p>
<b>Tetralogy of Fallot (TOF)</b>		
 <p data-bbox="164 1263 493 1316"><b>Figure 6.2.1.12:</b> Tetralogy of fallot Photo Courtesy: M Zulfikar Ahamed</p>	<p data-bbox="626 835 1016 1054">Note the minimal cardiomegaly, RV apex, pulmonary oligemia and relative broad base—possibly due to right arch. The typical <i>Coer en sabot</i> appearance is seen. Similar findings are also seen in TOF with pulmonary atresia.</p>	<p data-bbox="1070 835 1463 1024">Medical management of TOF will include IE prophylaxis, iron, hydration, treating and preventing spells and treating complications like cerebral abscess and thrombosis.</p>
<b>Unobstructed Supracardiac TAPVC</b>		
 <p data-bbox="164 1808 570 1882"><b>Figure 6.2.1.13:</b> Unobstructed supracardiac TAPVC Photo Courtesy: M Zulfikar Ahamed</p>	<p data-bbox="626 1463 1036 1651">There is mild cardiomegaly and the classical <i>Figure-of-8</i> appearance. Upper half of '8' is due to SVC dilatation on right and vertical vein on left. Lower half of '8' is due to RA on right and LV on left.</p> <p data-bbox="626 1663 1036 1821">The Figure-of-8 appears late in infancy. The appearance can be mimicked by thymic enlargement. Majority of TAPVCs do not have the classic appearance.</p>	<p data-bbox="1070 1463 1468 1553">The standard surgery for supracardiac TAPVC is Schumaker procedure.</p>

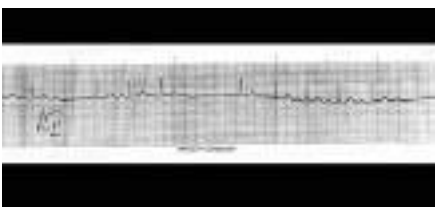
Picture	Note	Management
<h2>6.2.2 ECGs</h2>		
<h3>ECG Machine</h3>		
 <p data-bbox="138 588 469 635"><b>Figure 6.2.2.1:</b> ECG machine <i>Photo Courtesy: M Zulfikar Ahamed</i></p>	<p data-bbox="602 322 1013 478">The original ancient ECG machine weighing 220 lbs has been replaced by the modern elegant digital machine which weighs less than 4 lbs.</p>	<p data-bbox="1045 322 1455 451">Electrocardiography is quite useful in diagnosis of CHD and also of use in acquired heart disease. It is most often diagnostic in arrhythmias.</p>
<h3>Alternate WPW</h3>		
 <p data-bbox="138 1109 469 1156"><b>Figure 6.2.2.2:</b> Alternate WPW <i>Photo Courtesy: M Zulfikar Ahamed</i></p>	<p data-bbox="602 833 1013 989">This is a very curious ECG showing alternate WPW—one normal beat and one pre-excited beat. Note the short PR and delta wave. WPW can be sometimes intermittent.</p>	<p data-bbox="1045 833 1455 927">Alternate or intermittent WPW are relatively benign and usually do not cause sudden cardiac death.</p>
<h3>Atrioventricular Septal Defect (AVSD)</h3>		
 <p data-bbox="138 1831 550 1878"><b>Figure 6.2.2.3:</b> Atrioventricular septal defect <i>Photo Courtesy: M Zulfikar Ahamed</i></p>	<p data-bbox="602 1359 1013 1582">The ECG shows right atrial enlargement, left axis deviation and rSR in V1, which is quite diagnostic. AVSD is a common CHD (2–5%), which can cause cyanosis, heart failure or both. AVSD is particularly common in Down's syndrome.</p>	<p data-bbox="1045 1359 1455 1514">Complete AVSD is to be repaired between 3 and 6 months. Left alone, more than 30% will develop pulmonary vascular obstructive disease (PVOD) by 1 year.</p>




Picture	Note	Management
<b>Ebstein Anomaly</b>		
 <p data-bbox="164 609 493 656"><b>Figure 6.2.2.4:</b> Ebstein anomaly Photo Courtesy: M Zulfikar Ahamed</p>	<p data-bbox="626 282 1037 533">It shows a tall P wave , prolonged PR interval, right axis deviation and wide, bizarre QRS in V1-V2 and V3R and V4R (RBBB). The whole picture is strongly suggestive of Ebstein anomaly. Short PR interval can occur in Ebstein due to WPW syndrome (15-20%).</p>	<p data-bbox="1070 282 1451 369">Treatment of Ebstein will depend on the atrialization of RV and arrhythmias.</p>
<b>Ebstein Anomaly (Newborn)</b>		
 <p data-bbox="164 1187 561 1234"><b>Figure 6.2.2.5:</b> Ebstein anomaly (newborn) Photo Courtesy: M Zulfikar Ahamed</p>	<p data-bbox="626 833 1040 1079">Newborn with huge cardiomegaly. It is most likely having Ebstein anomaly. The cardiomegaly is called 'wall to wall' cardiac enlargement. The differential diagnosis are critical PS and pulmonary atresia with intact septum. ECG shows P wave taller than QRS - Himalayan P wave.</p>	<p data-bbox="1070 833 1468 948">Newborn with Ebstein may require O<sub>2</sub>, PGE1 and occasionally BT shunt. In very sick babies, Starnes operation is done.</p>
<b>Long QT Syndrome</b>		
 <p data-bbox="164 1749 493 1796"><b>Figure 6.2.2.6:</b> Long QT syndrome Photo Courtesy: M Zulfikar Ahamed</p>	<p data-bbox="626 1416 1040 1694">ECG shows bradycardia. The striking feature is prolonged QT interval, More than 600 msec. Normal QTc is &lt;440 msec. Borderline is between 440-460 msec. LQTS is mostly genetically determined and can predispose to malignant ventricular arrhythmia and sudden cardiac death.</p>	<p data-bbox="1070 1416 1468 1602">The standard medical treatment is by <math>\beta</math>-blockers-propranolol. In nonresponsive situations, implantable cardioverter-defibrillator (ICD) implantation or stellate ganglionectomy is done.</p>

Picture	Note	Management
<b>Tricuspid Atresia</b>		
	<p>ECG shows right atrial enlargement, left axis deviation, poor RV forces in V1 V2 and good LV forces which are diagnostic of tricuspid atresia (TA). TA is an important CCHD which usually presents in the newborn period with severe cyanosis. Survival at 1 year without surgery is 10 to 15% only.</p>	<p>The surgery of choice is TCPC (Total cavopulmonary connection), where both SVC and IVC are connected to pulmonary artery bypassing right atrium and ventricle. Sometimes palliation is achieved by either BT shunt or Glenn shunt.</p>
<p><b>Figure 6.2.2.7:</b> Tricuspid atresia <i>Photo Courtesy: M Zulfikar Ahamed</i></p>		

**Wenckebach Phenomenon**

	<p>This shows type I Mobitz AV block (2<sup>nd</sup> degree). Initially there is 4:3 AV Block (2<sup>nd</sup> degree) and then 6:5 block. The PR interval gradually gets prolonged and one QRS is dropped.</p>	<p>It may not progress to CHB. If so, it may need pacing.</p>
<p><b>Figure 6.2.2.8:</b> Wenckebach phenomenon <i>Photo Courtesy: M Zulfikar Ahamed</i></p>		

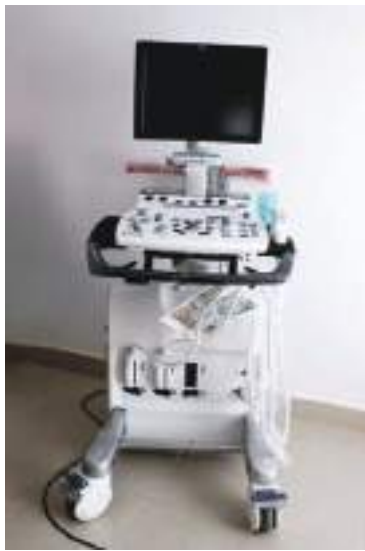**Wolf-Parkinson-White (WPW) Syndrome**

	<p>The ECG shows short PR interval, delta wave, wide QRS and some ST-T changes. The direction of QRS and delta wave in V1 is downward-right sided pathway. If in V1 delta wave and QRS are up, pathway is situated on the left side. Majority of WPW are without CHD. The CHD associated with WPW are L-TGA and Ebstein.</p>	<p>Treatment of choice for symptomatic WPW is RF ablation.</p>
<p><b>Figure 6.2.2.9:</b> WPW syndrome <i>Photo Courtesy: M Zulfikar Ahamed</i></p>		

Picture	Note	Management
---------	------	------------

### 6.2.3 Echocardiography

#### Echocardiographic Machine

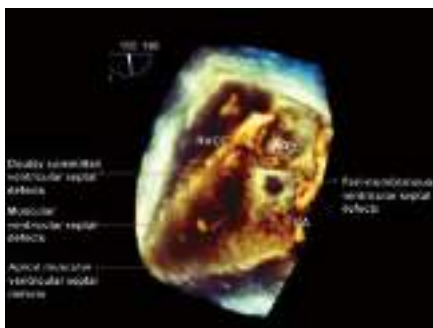


**Figure 6.2.3.1:** Echocardiographic machine  
 Photo Courtesy: M Zulfikar Ahamed,  
 Babu George

A modern echocardiographic machine is shown which has a digital platform and phased array probes. It has M Mode, 2D, Doppler and Color Doppler. Currently 3D echo is also increasingly being used in CHD and valve diseases.

The invention of echo machine has revolutionized the diagnosis of CHD. Echo came into being in the late 1970s and is now the most popular diagnostic tool in CHD. In CHD > 95% of diagnostic information can be made from a carefully performed echo.


#### 3D Echo Picture of VSD



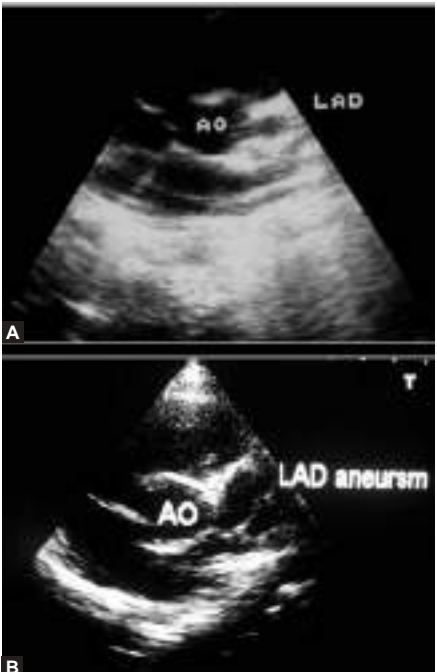
**Figure 6.2.3.2:** 3D echo picture of VSD  
 Photo Courtesy: S Sivasankaran



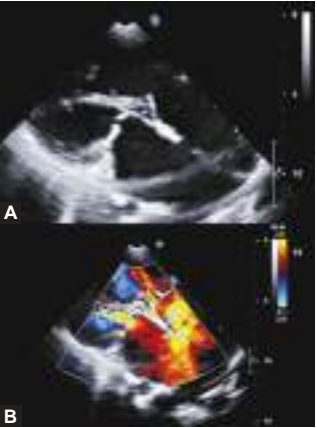
This is a transesophageal echocardiogram (TEE) 3D echo picture showing a perimembranous VSD visualized from the LV side. The other potential locations of VSD—subpulmonic (doubly committed), muscular and apical are also shown. The fourth variety is inlet VSD.

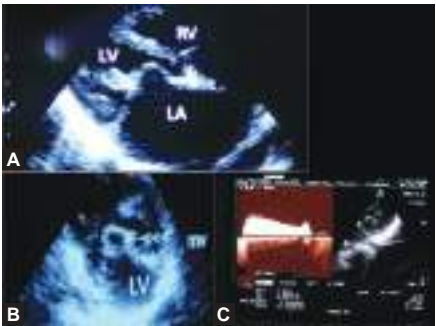

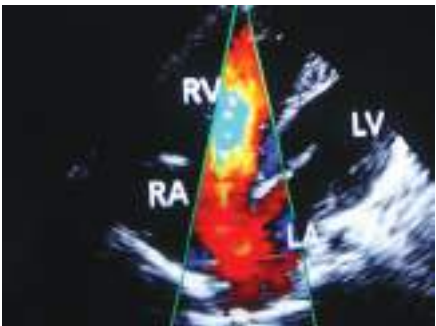
All significant VSDs (shunt >1.8:1) should be closed around 2 to 3 years and much earlier if the defect is larger. Inlet and subpulmonic VSDs do not close spontaneously and will require surgical closure. Muscular VSDs can be closed by device.

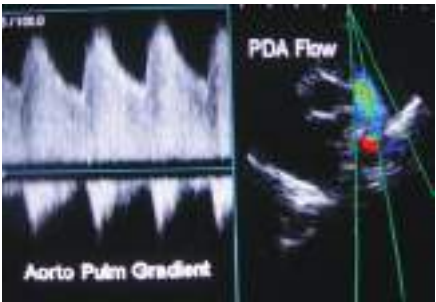

Picture	Note	Management
<p><b>Absent Pulmonary Valve Syndrome</b></p>  <p><b>Figure 6.2.3.3:</b> Absent pulmonary valve syndrome Photo Courtesy: M Zulfikar Ahamed</p>	<p>Absent pulmonary valve syndrome is a rare variant of TOF. It has characteristically, rudimentary pulmonary valve and dilated PA and branches. It can present in the newborn with cyanosis, RDS, stridor and a loud systolodiastolic murmur. The picture shows the presence of PS and PR, both in color and continuous wave (CW) Doppler.</p>	<p>The course in the newborn may be stormy. Maximum mortality occurs in newborn period due to CHF, respiratory distress and hypoxemia. Once the neonatal period is over, the baby stabilizes usually and is a candidate for intracardiac repair (ICR) with transannular patch.</p>




### Coronary Artery Dilatation in Kawasaki Disease

 <p><b>Figures 6.2.3.4A and B:</b> Coronary artery dilatation in KD Photo Courtesy: M Zulfikar Ahamed</p>	<p>Both frames show coronary artery dilatation (CAL) of left anterior descending artery in Kawasaki disease. CAL can be classified as mild (&lt;4 mm), moderate (4–8 mm) and giant (&gt;8 mm). Fifty percent of CAL regress in one year. Giant aneurisms do not usually regress.</p>	<p>Low dose aspirin is given indefinitely (5 mg/kg). Larger aneurisms may require addition of clopidogrel (1 mg/kg) along with low dose aspirin. Giant aneurism may be managed with oral anticoagulant to keep INR between 1.5 and 2.</p>
---	--	---



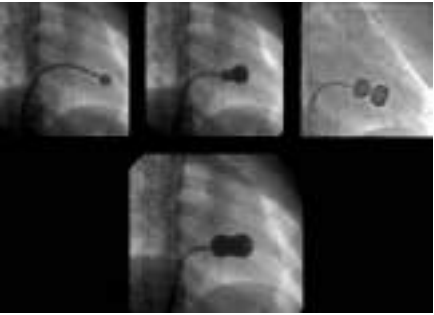
Picture	Note	Management
<b>Device Closure of ASD</b>		
 <p data-bbox="164 609 509 656"><b>Figure 6.2.3.5:</b> Device closure of ASD <i>Photo Courtesy: S Sivasankaran</i></p>	<p data-bbox="630 271 1032 394">Top film shows placement of the device for ASD closure. The bottom is a 3D echo of an ASD closed by device.</p>	<p data-bbox="1073 271 1482 394">Sixty percent of OS ASDs are closed by device. Ostium primum ASD and sinus venosus ASD are closed by surgery only.</p>
<b>Ebstein Anomaly</b>		
 <p data-bbox="164 1167 493 1214"><b>Figure 6.2.3.6:</b> Ebstein anomaly <i>Photo Courtesy: M Zulfikar Ahamed</i></p>	<p data-bbox="630 835 1044 1212">The apical view shows LA and LV on the left side. RA with anterior tricuspid leaflet is seen. There is a distal displacement of septal leaflet producing an atrialized RV (ARV). The true RV is relatively small. Ebstein anomaly is quite rare (0.5%), but is a fascinating CHD. It can present with shock, CHF, cyanosis or all in the newborn period. Twenty percent of Ebstein can have WPW syndrome.</p>	<p data-bbox="1073 835 1482 1089">The treatment of significant Ebstein is surgery—TV valve repair, plication of atrialized RV and closure of the ASD. Indications of this sort of surgery (Danielson's repair) are class III and IV status, deepening cyanosis, progressive cardiomegaly and refractory SVT.</p>
<b>Lutembacher Syndrome</b>		
 <p data-bbox="164 1831 602 1878"><b>Figures 6.2.3.7A and B:</b> Lutembacher syndrome <i>Photo Courtesy: S Harikrishnan</i></p>	<p data-bbox="630 1387 1032 1702">The upper panel shows rheumatic MS with moderate ostium secundum ASD. In the lower panel color jet delineates both ASD and MS. Lutembacher is extremely rare. One reason for ASD with a loud murmur is Lutembacher. MS can worsen symptoms of ASD and ASD can mitigate the hemodynamic effects of MS like PVH.</p>	<p data-bbox="1073 1387 1482 1510">Management is essentially surgical. Balloon mitral valvotomy (BMV) for MS and device closure for ASD can be attempted.</p>




Picture	Note	Management
<p><b>Mitral Stenosis (MS)</b></p>  <p><b>Figures 6.2.3.8A to C:</b> Mitral stenosis <i>Photo Courtesy: M Zulfikar Ahamed</i></p>	<p>The upper panel (PS LAX) shows the doming, thick mitral valve with a large LA. The bottom panels show the narrow mitral valve opening (very much small mitral valve area) Doppler interrogation of mitral valve indicating severe MS. Mitral valve area can be calculated by pressure half time method along with 2 D measure. Normal MV area is <math>4 \text{ cm}^2/\text{M}^2</math>. MS is said to exist when MVA is <math>&lt; 2.5 \text{ cm}^2</math>. Severe MS in the young (<math>&lt; 20</math> years) is called juvenile MS. It is almost always rheumatic. Congenital MS can occur rarely.</p>	<p>Initial management is medical—rest, diuretic and <math>\beta</math>-blockers. The standard treatment of significant MS is balloon mitral valvotomy.</p>
<p><b>Mitral Regurgitation—Rheumatic</b></p>  <p><b>Figure 6.2.3.9:</b> MR—Rheumatic <i>Photo Courtesy: M Zulfikar Ahamed</i></p>	<p>The first panel shows morphoanatomy of rheumatic MR. Other frames indicate varying degrees of MR by color—from trivial to mild to moderately severe.</p>	<p>All rheumatic MR are given rheumatic prophylaxis as well as endocarditis prophylaxis. No other drug is indicated for mild-moderate MR. Moderate-severe MR may require ACE inhibitors. Surgery for severe MR in children is preferably mitral valvuloplasty.</p>
<p><b>Ostium Secundum ASD with L→R Flow</b></p>  <p><b>Figure 6.2.3.10:</b> Ostium secundum ASD with L→R flow <i>Photo Courtesy: M Zulfikar Ahamed</i></p>	<p>The echo picture is a four chamber view showing a reasonably sized Ostium Secundum ASD with L→R flow. There is evidently RV volume overload. ASD forms 10% of all CHD. The other types of ASD are primum and sinus venosus.</p>	<p>All OS ASD except small (shunt <math>&lt; 1.5 : 1</math>) should be closed. Sixty percent of ASDs can be closed by device and rest by surgery. Surgical mortality is near zero. Thirty years survival if surgery is done before 11 years is near control population.</p>


Picture	Note	Management
<p><b>PDA with L→R Shunt</b></p>  <p><b>Figure 6.2.3.11:</b> PDA with L→R shunt Photo Courtesy: M Zulfikar Ahamed</p>	<p>PDA flow is picked up at pulmonary artery by color Doppler. The continuous flow signal on the left hand side indicates the gradient across PDA between aorta and pulmonary artery in systole and diastole. It is called aorto pulmonary gradient. From this value, approximate PA pressures can be calculated.</p>	<p>All PDAs except silent, trivial PDA are to be closed. Practically all of them are closed by a coil (small &lt;3.5 mm) or device (moderate and large). Surgery is seldom required. The age of closure may vary depending on the size of the shunt and symptoms.</p>
<p><b>Rhabdomyoma in the LV</b></p>  <p><b>Figure 6.2.3.12:</b> Rhabdomyoma in the LV Photo Courtesy: M Zulfikar Ahamed</p>	<p>Rhabdomyoma are the most common benign tumors of the heart in children. They are pedunculated masses which are usually found in ventricles, while myxomas are found in atria. Rhabdomyoma can be asymptomatic and may regress. It can also produce LVOT/RVOT obstruction, CHF and ventricular arrhythmia. This is associated with tuberous sclerosis.</p>	<p>Treatment is conservative. Large persisting ones in RV are surgically removed. LV rhabdomyoma are usually left untouched as it may involve left ventriculotomy and are of high-risk.</p>
<p><b>Tetralogy of Fallot</b></p>  <p><b>Figures 6.2.3.13A and B:</b> Tetralogy of fallot Photo Courtesy: M Zulfikar Ahamed</p>	<p>The echo picture demonstrates (on parasternal long axis) a large subaortic VSD with override of aorta. The apical view clearly shows the large, malaligned VSD and nearly 50% aortic override. Aorta appears to arise from both LV and RV. Right ventricular outflow tract (RVOT) obstruction is to be assessed in parasternal short axis view and is not shown here. TOF is the most common cyanotic CHD in infants and children and accounts for 10 to 15% of all CHD.</p>	<p>The management of choice in TOF is intracardiac repair around 1 year of life. If the baby is severely cyanosed or has frequent spells early in life, one needs to do a BT shunt as a palliative measure.</p>

Picture	Note	Management
<b>Unobstructed TAPVC</b>		
 <p><b>Figure 6.2.3.14:</b> Unobstructed TAPVC Photo Courtesy: M Zulfikar Ahamed</p>	<p>Observe the very large RA and RV and the diminutive LV. LA is small and there is a posterior chamber into which pulmonary veins drain. Unobstructed supracardiac TAPVC presents in the newborn and early infancy with severe CHF and mild cyanosis. This will present like an ASD with 'cyanosis'. TAPVCs are classified into infracardiac, cardiac and supracardiac.</p>	<p>Management consists of early stabilization with inotropes, diuretics, oxygen and urgent surgical repair. Mortality is around 5 to 10%. However, the survivor will have a near normal life.</p>
<b>Vegetations on Aortic Valve</b>		
 <p><b>Figure 6.2.3.15:</b> Vegetation on aortic valve Photo Courtesy: S Sivasankaran</p>	<p>This is a parasternal long axis view (LAX) showing echodense nodule on aortic valve. Mitral valve is normal. In real time the vegetations are freely mobile. Infective endocarditis (IE) of the aortic valve usually occurs on bicuspid aortic valve or rheumatic aortic valve disease.</p>	<p>Infective endocarditis has a fairly high mortality - 30%. It needs aggressive antimicrobial treatment at least for 4 weeks. The usual organisms are <i>S. viridans</i> and <i>S. aureus</i>.</p>
<b>Viral Myocarditis</b>		
 <p><b>Figure 6.2.3.16:</b> Dilated cardiomyopathy Photo Courtesy: M Zulfikar Ahamed</p>	<p>2 D picture shows a grossly dilated LV with thin walls. There is globularity of LV with LV enlargement. In real time, the contractility will be poor and there will be significant MR.</p>	<p>Standard management of viral myocarditis includes use of IV inotropes, ACE inhibitors, digoxin and diuretics. IVIG could be useful in children with myocarditis.</p>




Picture	Note	Management
<b>6.2.4 Angiography/Pathological Specimen</b>		
<b>Catheterization Lab</b>		
 <p data-bbox="164 641 493 697"><b>Figure 6.2.4.1:</b> Catheterization lab <i>Photo Courtesy: M Zulfikar Ahamed</i></p>	<p data-bbox="626 329 1037 390">The photograph shows a diagnostic catheterization lab.</p>	<ul data-bbox="1073 329 1484 778" style="list-style-type: none"> <li>• Diagnostic catheterization in CHD has given way to catheter interventions. Almost all PDAs, more than half of ASDs, a small percent of VSDs and a few AP windows are closed by device. Balloon valvotomy is the treatment of choice in PS, AS, MS and TS. A significant proportion of CoA is managed with Balloon and stent.</li> <li>• Other uses of catheterization are stenting of PDA, closure of CAVF, MAPCA, Balloon septostomy, etc.</li> </ul>
<b>Balloon Dilatation of Pulmonary Valve (BPV)</b>		
 <p data-bbox="164 1281 597 1361"><b>Figure 6.2.4.2:</b> Balloon dilatation of pulmonary valve <i>Photo Courtesy: S Sivasankaran</i></p>	<p data-bbox="626 891 1037 1054">Angio picture shows the process of dilatation of stenotic pulmonary valve by a balloon. The waist is seen, which will be completely abolished once successful dilatation is over.</p>	<p data-bbox="1073 891 1484 1054">BPV is quite safe and offers an excellent result in &gt;95% and the result is long lasting. The mortality is near zero. BPV is offered when PS gradient is more than 50 mm Hg.</p>
<b>Balloon Mitral Valvotomy (BMV)</b>		
 <p data-bbox="164 1819 537 1872"><b>Figure 6.2.4.3:</b> Balloon mitral valvotomy <i>Photo Courtesy: S Harikrishnan</i></p>	<p data-bbox="626 1490 1037 1653">Angio pictures of progressive dilatation of stenosed mitral valve orifice. The classical dumbbell appearance of the balloon across mitral valve is also seen.</p>	<p data-bbox="1073 1490 1484 1653">BMV is the procedure of choice in MS in all ages. It has supplanted CMV. The valve area doubles with a minimal risk of MR and the good result lasts for at least 10 years.</p>

Picture	Note	Management
<p><b>Coil Occlusion of PDA</b></p>  <p><b>Figure 6.2.4.4:</b> Coil occlusion of PDA Photo Courtesy: S Sivasankaran</p>	<p>Coils are seen (Gianturco or Cook), which are deployed via catheter to close a smaller PDA. Coil closure of PDA is much less expensive than device closure. Occasionally larger PDA is also closed by multiple coils delivered through a biptome.</p>	<p>Coils are also used in closing collaterals, CAVF, PAVF and other unwanted channels.</p>
<p><b>Pulmonary AV Fistula (PAVF)</b></p>  <p><b>Figure 6.2.4.5:</b> Pulmonary AV fistula Photo Courtesy: S Harikrishnan</p>	<p>Angiogram shows LPA injection opacifying a fistula located at left lower lobe of lung and draining back to LA through pulmonary vein. The characteristic angio picture is quite diagnostic. PAVF causes central cyanosis with no murmur, normal ECG and near normal X-ray. Echo anatomy of the heart also will be reported as normal. Rarely it may cause a continuous murmur and may cast a definite shadow in the lung.</p>	<p>Treatment is either by resection of fistula, resection of the particular lung lobe, tying off the feeder vessel or coil embolization of feeding vessel.</p>
<p><b>Septal Occluder (Amplatzer Device)</b></p>  <p><b>Figure 6.2.4.6:</b> Septal occluder (Amplatzer Device) Photo Courtesy: S Sivasankaran</p>	<p>Both ASD and VSD can be closed nonsurgically by the septal occluder device. It is made of Nitinol, which is a metal with a memory so that when introduced through a catheter over a defect, it will assume its original shape and close the defect appropriately.</p>	<p>Devices can be used to close ASD, VSD (muscular), PDA, AP window, etc. There is recently a device introduced for closing perimembranous VSD also.</p>

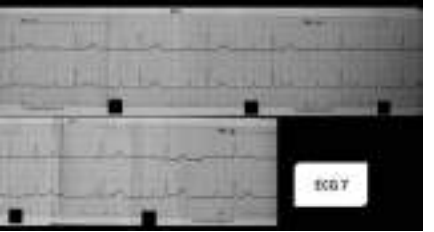
Picture	Note	Management
<b>Pathology Specimen Showing Single Ventricle</b>		
 <p data-bbox="164 621 597 697"><b>Figure 6.2.4.7:</b> Pathology specimen showing single ventricle <i>Photo Courtesy:</i> S Sankar, PN Manju, C Indrani</p>	<p data-bbox="626 277 1037 466">There is only one ventricle without any intervening septum. Single ventricle is an admixture lesion at ventricular level. This can exist with PAH or PS. Single ventricle with PS will behave like TOF.</p>	<p data-bbox="1070 277 1468 560">Single ventricle is an uncommon but very important CCHD. Single ventricle with PAH will present with CHF and mild cyanosis and is managed by PA banding followed by Fontan operation. SV with PS will present with cyanosis and is managed with Fontan with or without prior Glenn shunt.</p>



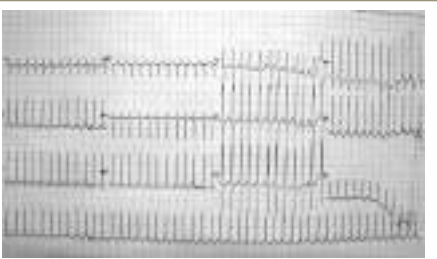
## 6.3 EMERGENCIES

### Atrial Flutter with 4:2 and 6:3 AV Block


 <p data-bbox="164 1064 597 1140"><b>Figure 6.3.1:</b> Atrial flutter with 4:2 and 6:2 AV Block <i>Photo Courtesy:</i> M Zulfikar Ahamed</p>	<p data-bbox="626 983 1037 1228">The saw-toothed appearance with varying AV block. It can cause irregularly irregular pulse. This was found in a newborn. Atrial flutter in newborn or infants can be associated with Ebstein anomaly. It can be idiopathic also, as was in this case.</p>	<p data-bbox="1070 983 1468 1105">Treatment is by IV <math>\beta</math>-Blocker, IV amiodarone or DC version. Adenosine does not work in atrial flutter.</p>
--	--	--

### Complete Heart Block

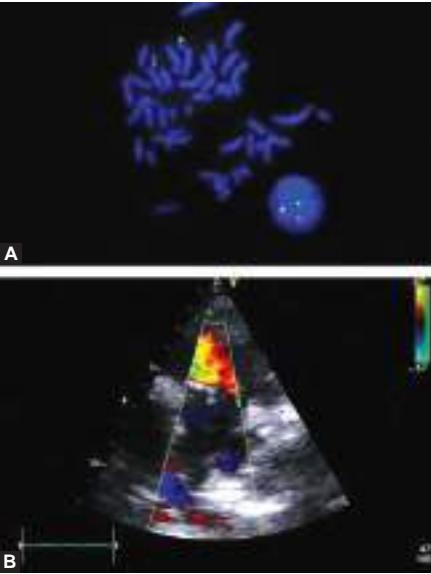
 <p data-bbox="164 1747 597 1798"><b>Figure 6.3.2:</b> Complete heart block <i>Photo Courtesy:</i> M Zulfikar Ahamed</p>	<p data-bbox="626 1500 1037 1719">There is AV dissociation (varying PR intervals—there is no regular relationship between P and QRS), atrial rate of 75/mt and ventricular rate of 45/mt and narrow QRS complex. Most likely it is suprahisian block.</p>	<p data-bbox="1070 1500 1468 1657">CHB can be a medical emergency. If so IV isoprenaline infusion can be tried. One may require temporary pacing. PPI is offered based on specific indications.</p>
---	---	---




Picture	Note	Management
<b>d-TGA in the Newborn</b>		
 <p data-bbox="138 619 472 670"><b>Figure 6.3.3:</b> d-TGA in the newborn <i>Photo Courtesy:</i> Balu Vaidyanathan</p>	<p>In the echo, note that the posterior left ventricle gives rise to a branching, broad vessel—the pulmonary artery. RV is large and gives rise to aorta. d-TGA is the most common CCHD in the newborn and survival at 1 year without surgery is only 10%. d-TGA usually presents in the first week of newborn period with deep cyanosis and mild CHF.</p>	<p>Immediate management is by oxygen, prostaglandin E1 (PGE1) and balloon atrial septostomy (BAS). BAS is also called Rashkind procedure and is a life-saving procedure. Arterial switch operation (ASO) is offered as early as possible, at least before 4 weeks. Late presentation of TGA will require Senning operation.</p>
<b>Obstructed TAPVC</b>		
 <p data-bbox="138 1212 472 1263"><b>Figure 6.3.4:</b> Obstructed TAPVC <i>Photo Courtesy:</i> M Zulfikar Ahamed</p>	<p>This is the classical appearance of 'white washed' lung and is a very important differential diagnosis of HMD. By CXR it is very difficult to differentiate between the two. White washed lung is due to severe PVH.</p>	<p>Obstructed TAPVC is a genuine cardiac emergency. Obstructed TAPVC with cyanosis becomes bad on PGE 1. Emergency surgery should be done for all obstructed TAPVC.</p>
<b>SVT</b>		
 <p data-bbox="138 1743 472 1794"><b>Figure 6.3.5:</b> SVT <i>Photo Courtesy:</i> M Zulfikar Ahamed</p>	<p>Regular tachycardia with a rate of 300/mt in a newborn. QRS is narrow and there are retrograde P waves in II, III AVF. Most likely SVT is due to AVRT—due to an accessory pathway. In newborn, SVT can present with CHF, shock and extreme irritability.</p>	<p>Termination is by IV adenosine. Nonresponsive SVT can be terminated by IV amiodarone. In an unstable baby, cardio version is employed (0.5–1.0 J/kg).</p>

## 6.4 SYNDROMES

Picture	Note	Management
 <p data-bbox="164 676 532 752"><b>Figure 6.4.1:</b> A Teenage girl with Turner syndrome Photo Courtesy: VH Sankar</p>	<p data-bbox="626 335 1024 682">Webbing of neck is quite characteristic in Turner syndrome. Karyotyping shows XO chromosomal pattern. Turner syndrome is the most common chromosomal disorder in girls. It can have CHD in 30 to 40%. The characteristic lesion is Coarctation of Aorta. Bicuspid aortic valve and diffuse aortopathy are also common.</p>	<p data-bbox="1070 335 1468 652">Coarctation will require surgical correction. Patients with Turner syndrome usually present with short stature or primary amenorrhea. Height can be improved marginally by growth hormone administration. Assisted reproductive technology can offer a chance of pregnancy for the affected girl.</p>

## DiGeorge Syndrome

 <p data-bbox="164 1533 589 1584"><b>Figures 6.4.2A and B:</b> DiGeorge syndrome Photo Courtesy: VH Sankar, M Zulfikar Ahamed</p>	<p data-bbox="626 942 1024 1324">Fluorescence <i>in situ</i> hybridization (FISH) showing 22q deletion and echo showing Truncus arteriosus. DiGeorge syndrome (Catch 22) is a syndrome inherited in autosomal recessive manner. There is a 22q deletion. It is associated with conotruncal anomalies—Truncus arteriosus, interrupted aortic arch, TOF and DORV. In fact, up to 10 to 15% of TOF will have DiGeorge syndrome by FISH.</p>	<p data-bbox="1070 942 1468 1259">The syndrome will have associated hypocalcemia and immunodeficiency and hence all conotruncal anomalies of the heart require testing for DiGeorge syndrome. Preoperative work-up is needed for CHD undergoing surgery. Counseling is also offered to mothers, who were operated for TOF, when they become pregnant.</p>
---	--	---

Picture	Note	Management
<b>Down Syndrome with Atrioventricular Septal Defect (AVSD)</b>		
	<p>A case of Down syndrome featuring clinodactyly of little finger and increased space between big toe and 2<sup>nd</sup> toe (Sandal sign) with accompanying karyotyping and echocardiography of AVSD. This syndrome is characterized by mental retardation, microcephaly, dysmorphism and in addition, coronary heart disease (CHD), which occurs in 40%. The most common CHD is AVSD, followed by ventricular septal defect (VSD), atrial septal defect (ASD) and tetralogy of fallot (TOF).</p>	<p>Needs multidisciplinary approach to manage Down syndrome including genetic counseling. Recurrence is only 1% in Trisomy 21 due to nondisjunction but is as high as 10% in translocation.</p>
<p><b>Figures 6.4.3A to D:</b> Down syndrome with AVSD  <i>Photo Courtesy:</i> VH Sankar</p>		
<b>Edward Syndrome</b>		
	<p>A baby showing 18 trisomy in karyotyping and the characteristic overriding of fingers. 18 trisomy has the highest incidence of CHD among chromosomal anomalies, virtually 100%. They include both simple and complex CHD. The child will have, curiously, hypertonia.</p>	<p>Survival is rare beyond two years, because of complex CHD, isomerism and pneumonias. Genetic counseling can be offered.</p>
<p><b>Figures 6.4.4A to C:</b> Edward syndrome  <i>Photo Courtesy:</i> VH Sankar</p>		
<b>Noonan Syndrome</b>		
	<p>A teenage boy with webbed neck. This is Noonan syndrome with PS. ECG is showing RUQ axis and RVH due to dysplastic PS. Noonan syndrome can have phenotypical features of Turner syndrome and is inherited in an autosomal dominant fashion. CHD is present in 40%. They include dysplastic pulmonary valve with PS and HCM. Significant PS will have characteristically RUQ axis in ECG with RVH.</p>	<p>Significant valvar PS will be offered balloon valvotomy, though it may give suboptimal result. In such cases, surgical valvotomy will relieve the obstruction. HCM is managed medically. The person also needs multidisciplinary management.</p>
<p><b>Figure 6.4.5:</b> Noonan syndrome  <i>Photo Courtesy:</i> VH Sankar, M Zulfikar Ahamed</p>		



## Section 7

---

# Pulmonology

### ***Section Editors***

TU Sukumaran, Devaraj Raichur

### ***Photo Courtesy***

Devaraj Raichur, HS Surendra, JK Lakhani, KE Elizabeth,  
NK Kalappanavar, Pushpa Panigatti, S Kavya, S Nagabhushana,  
TA Shepur, TU Sukumaran, Vijay Yewale, Vinod Ratageri

- 
- 7.1 Common Conditions
  - 7.2 Uncommon Conditions but not Rare
  - 7.3 Emergency Situations
  - 7.4 Syndrome
  - 7.5 Miscellaneous



## SECTION OUTLINE

### 7.1 COMMON CONDITIONS 119

- ◆ Acute Follicular Tonsillitis 119
- ◆ Acute Laryngotracheobronchitis (ALTB) 119
- ◆ Acute Otitis Media (AOM) 119
- ◆ Acute Respiratory Distress Syndrome (ARDS) 120
- ◆ Adenoid Facies 120
- ◆ Allergic Rhinitis 120
- ◆ Asthma 121
- ◆ Barrel-Chest in a Ventilated Baby 121
- ◆ Bronchiectasis 121
- ◆ Bronchiolitis 122
- ◆ Cellulitis in the Dangerous Area of Face 122
- ◆ Empyema 122
- ◆ Hydropneumothorax/Pyopneumothorax 123
- ◆ *Klebsiella* Pneumonia 123
- ◆ *Klebsiella* Pneumonia—'Bulging Fissure Sign' 123
- ◆ Lung Abscess 124
- ◆ Measles Bronchopneumonia 124
- ◆ Meconium Aspiration Syndrome (MAS) 124
- ◆ Miliary Tuberculosis of the Lungs 125
- ◆ Pleural Effusion 125
- ◆ Pleural Effusion/Emphyema 125
- ◆ *Pneumocystis jiroveci* (*carinii*) Pneumonia 126
- ◆ Pneumococcal Pneumonia 126
- ◆ Primary Complex 126
- ◆ Respiratory Distress 127
- ◆ Respiratory Distress Syndrome (RDS) 127
- ◆ Retropharyngeal Abscess 127
- ◆ Cavitory Tuberculosis with Necrotizing Bronchopneumonia 128
- ◆ Staphylococcal Pneumonia 128
- ◆ Tuberculoma of Right Lung 129
- ◆ Tuberculoma of Right Lung—CT Scan 129
- ◆ Tuberculosis—Right Middle Lobe Collapse Consolidation 129
- ◆ Tuberculosis—Bilateral Paratracheal Lymphadenopathy 130
- ◆ Tuberculosis—Hilar Lymphadenopathy 130

- ◆ Tuberculous Pleural Effusion—Right Side with Hilar Lymphadenopathy 130

### 7.2 UNCOMMON CONDITIONS BUT NOT RARE 131

- ◆ Acute Epiglottitis 131
- ◆ Bronchiolitis Obliterans Organizing Pneumonia (BOOP) 131
- ◆ Bronchogenic Cyst 132
- ◆ Castleman's Disease 132
- ◆ Congenital Cystic Adenomatoid Malformation (CCAM) 133
- ◆ Congenital Diaphragmatic Hernia 133
- ◆ Congenital Lobar Emphysema 134
- ◆ Esophageal Atresia with Tracheoesophageal Fistula 134
- ◆ Eventration of the Diaphragm 134
- ◆ Hypoplasia of the Right Lung 135
- ◆ Interstitial Lung Disease (ILD) 135
- ◆ Neuroblastoma (Secondary) with Right Pleural Effusion and 7th Rib Erosion 136
- ◆ Pulmonary Agenesis 136
- ◆ Tumors 136

### 7.3 EMERGENCY SITUATIONS 137

- ◆ Closed Pneumothorax 137
- ◆ False Foreign Body in the Chest 137
- ◆ Foreign Body Aspiration 138
- ◆ Foreign Body Right Bronchus 138
- ◆ Pneumothorax 139
- ◆ RDS on Ventilator—Tension Pneumothorax 139




### 7.4 SYNDROME 140




- ◆ Swyer-James MacLeod Syndrome (SJMS) 140




### 7.5 MISCELLANEOUS 140



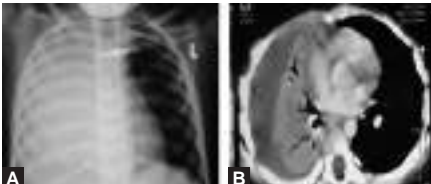
- ◆ Equipment for Asthma Therapy 140
- ◆ Hydatid Cyst—X-ray Chest 140
- ◆ Nebulizer 141
- ◆ Equipment for Resuscitation and O<sub>2</sub> Therapy 141
- ◆ Paraesophageal Hiatus Hernia (PEHH) 142
- ◆ Falling Percentiles: Is it Abnormal? 142
- ◆ Thymus—Sail Sign 143

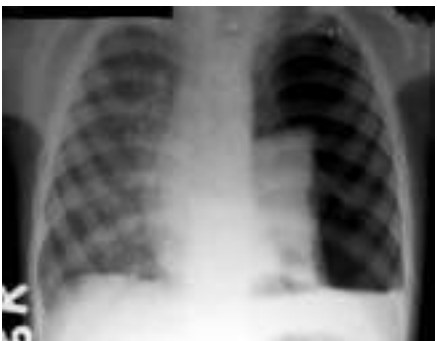
## 7.1 COMMON CONDITIONS

Picture	Note	Management
<p data-bbox="128 267 477 294"><b>Acute Follicular Tonsillitis</b></p>  <p data-bbox="138 660 548 707"><b>Figure 7.1.1:</b> Acute follicular tonsillitis Photo Courtesy: S Nagabhushana, Bengaluru</p>	<p data-bbox="605 322 1008 349">Erythematous tonsils with exudate.</p> <p data-bbox="605 363 987 519"><i>Symptoms:</i> Painful swallowing, dry throat, malaise, fever and chills, dysphagia, referred otalgia, headache, muscular aches, and enlarged cervical nodes.</p> <p data-bbox="605 533 976 717"><i>Signs:</i> Dry tongue, erythematous enlarged tonsils, tonsillar or pharyngeal exudate, palatine petechiae, and enlargement and tenderness of the jugulodigastric lymph nodes.</p>	<p data-bbox="1049 322 1435 414">Penicillin is the drug of choice. Cephalosporins or clindamycin in chronic infections.</p> <p data-bbox="1049 429 1295 455"><i>Tonsillectomy if (any):</i></p> <ul data-bbox="1049 470 1425 649" style="list-style-type: none"> <li>• 7 or more episodes in 1 year</li> <li>• 5 or more episodes over 2 years</li> <li>• Tonsillitis causing upper respiratory obstruction</li> <li>• Tonsillar abscess</li> </ul> <p data-bbox="1049 664 1455 717">Cautery with silver nitrate: For chronically infected tonsillar crypts.</p>
<p data-bbox="128 778 659 805"><b>Acute Laryngotracheobronchitis (ALTB)</b></p>  <p data-bbox="138 1377 578 1424"><b>Figure 7.1.2:</b> ALTB—“Steeple sign” Photo Courtesy: TU Sukumaran, PIMS, Thiruvalla</p>	<p data-bbox="605 833 980 925">Narrowing of subglottic region of the upper airway (steeple sign) is seen.</p> <p data-bbox="605 940 984 1032">ALTB is mainly caused by various viruses; the most common is parainfluenza virus type B.</p> <p data-bbox="605 1046 1016 1101">It is the most common form of acute upper airway obstruction.</p> <p data-bbox="605 1116 1000 1238"><i>Symptoms:</i> 1 to 3 days history of upper respiratory tract infection followed by barking cough, hoarseness and inspiratory stridor.</p> <p data-bbox="605 1252 1013 1344"><i>Signs:</i> Hoarse voice, coryza, normal to moderately inflamed pharynx and tachypnea.</p> <p data-bbox="605 1359 938 1414">The most common site of obstruction is subglottic area.</p>	<ul data-bbox="1049 833 1435 1199" style="list-style-type: none"> <li>• Airway management.</li> <li>• Humidified O<sub>2</sub>.</li> <li>• Nebulized racemic/nonracemic epinephrine.</li> <li>• Oral/nebulized corticosteroids are effective.</li> <li>• Heliox—helpful in severe croup.</li> <li>• Other supportive therapy.</li> <li>• Antibiotics are not indicated in croup.</li> </ul>
<p data-bbox="128 1483 464 1510"><b>Acute Otitis Media (AOM)</b></p>  <p data-bbox="138 1851 548 1923"><b>Figure 7.1.3:</b> Acute suppurative otitis media (ASOM) Photo Courtesy: S Nagabhushana, Bengaluru</p>	<p data-bbox="605 1535 971 1590">The hyperemic bulging eardrum with loss of cone of light.</p> <p data-bbox="605 1604 1019 1823">AOM can be nonsuppurative or suppurative; both produce middle ear effusion. Bulging, angry-red eardrum (as seen in Fig. 7.1.3) associated with pain and immobility is characteristic of acute suppurative otitis media (ASOM).</p>	<p data-bbox="1049 1535 1455 1913"><i>Antibiotics:</i> In patients, &lt;6 months of age, even presumed AOM should be treated. For &lt;2 years of age treat all confirmed cases of AOM. In children &gt;2 years of age, treat confirmed, severe episodes. First line—Amoxicillin. Second line—co-amoxiclav, cefuroxime axetil, or IM ceftriaxone. The duration of treatment—10 days for &lt;2 years and 3 to 5 days for older children. Rarely myringotomy is necessary.</p>


Picture	Note	Management
<b>Acute Respiratory Distress Syndrome (ARDS)</b>		
 <p><b>Figure 7.1.4:</b> ARDS in dengue hemorrhagic fever Photo Courtesy: NK Kalappanavar, S Kavya, Davangere</p>	<p>X-ray showing areas of relatively normal lung interspersed with atelectatic and consolidated regions that are concentrated towards the dependent zones.</p> <p>ARDS, the noncardiogenic pulmonary edema, is defined, by the presence of an acute onset respiratory distress with PaO<sub>2</sub>/FiO<sub>2</sub> ratio ≤300 mm Hg, bilateral infiltrates on chest radiograph, absence of left heart failure.</p> <p><i>Causes:</i> Sepsis, pneumonia, near drowning, pulmonary embolism, lung contusion, shock, SIRS, etc.</p>	<ul style="list-style-type: none"> <li>• Eliminate the initiating factor.</li> <li>• Mechanical ventilation with high PEEP and low tidal volume is the main stay of treatment.</li> <li>• Other treatment modalities: <ul style="list-style-type: none"> <li>- Recruitment maneuver: initial high PEEP (sec to min)</li> <li>- Inverse ratio ventilation: IT&gt;ET</li> <li>- Permissive hypercapnea</li> <li>- Diuretics</li> <li>- Prone positioning (“Proning”)</li> <li>- NO (Nitric Oxide).</li> <li>- Reduce metabolic rate (sedation, treat fever)</li> <li>- Extracorporeal membrane oxygenation (ECMO) in newborns and small infants, who are unresponsive to mechanical ventilation</li> <li>- Exogenous surfactant.</li> </ul> </li> </ul>
<b>Adenoid Facies</b>		
 <p><b>Figures 7.1.5A and B:</b> (A) Adenoid facies; (B) X-ray showing adenoid hypertrophy Photo Courtesy: S Nagabhushana, Bengaluru and Vijay Yewale, Navi Mumbai</p>	<p>Typical facies with prominent upper lips, protruded maxillary teeth, suggestive of adenoidal hypertrophy (Fig. 7.1.5A).</p> <p>Other features could be: high arched palate, snoring, sleep apnea/hypopnea. Important trigger for posterior nasal drip and asthma.</p> <p>Group A streptococci are the causative agents. X-ray adenoid (Fig. 7.1.5B) shows soft tissue bulge (adenoids) narrowing the nasopharynx.</p>	<ul style="list-style-type: none"> <li>• Penicillin—the drug of choice cephalosporins or clindamycin may be more efficacious in chronic infections.</li> <li>• Adenoidectomy—in chronic adenoiditis.</li> </ul>
<b>Allergic Rhinitis</b>		
 <p><b>Figure 7.1.6:</b> Allergic rhinitis Photo Courtesy: S Nagabhushana, Bengaluru and Devaraj Raichur, Hubli</p>	<p>“Allergic Salute” of allergic rhinitis is demonstrated.</p> <p>Dennie Morgan Line (nasal crease) is seen.</p>	<ul style="list-style-type: none"> <li>• Avoidance of known allergens.</li> <li>• Oral antihistamines.</li> <li>• Intranasal steroids.</li> <li>• Oral/nasal alpha-agonists.</li> <li>• Specific allergen immunotherapy.</li> <li>• Monoclonal recombinant humanized anti-IgE.</li> </ul>

Picture	Note	Management
 <p><b>Figure 7.1.7:</b> Asthma-hyperinflated lungs Photo Courtesy: Devaraj Raichur, KIMS, Hubli</p>	<p>Hyperinflated lungs, indicating air-trapping, are seen.</p> <p>Asthma is a chronic inflammatory condition of the lung airways resulting in episodic airflow obstruction.</p> <p>Intermittent dry coughing and/or expiratory wheezing are the most common chronic symptoms of asthma.</p> <p>Respiratory symptoms can be worse at night, especially during prolonged exacerbations triggered by respiratory infections or inhalant allergens.</p>	<ul style="list-style-type: none"> <li>• Eliminating and reducing problematic environmental exposures.</li> <li>• Treat co-morbid conditions</li> <li>• Management in acute exacerbation: <ul style="list-style-type: none"> <li>- Oxygen and inhaled short-acting <math>\beta</math>-agonists.</li> <li>- Systemic corticosteroids</li> <li>- Nebulized anticholinergic (Ipratropium bromide).</li> <li>- IV Magnesium sulfate infusion</li> <li>- IV Aminophylline.</li> <li>- Epinephrine 0.01 mg/kg SC or IM</li> <li>- Terbutaline IV infusion.</li> </ul> </li> <li>• Home treatment: Depends on severity of the chronic symptoms.</li> </ul>
 <p><b>Figure 7.1.8:</b> Barrel-chest in a ventilated baby Photo Courtesy: Devaraj Raichur, KIMS, Hubli</p>	<p>Increased AP diameter of the chest is evident.</p> <p>This could be due to MAS but in a ventilated baby, hyperinflation of the lungs due to unduly high positive end-expiratory pressure (PEEP) in an improving lung disease can also result in such a picture.</p>	<ul style="list-style-type: none"> <li>• Keep PEEP low.</li> <li>• Avoid generation of significant auto-PEEP.</li> <li>• Allow enough expiratory time.</li> </ul>
 <p><b>Figure 7.1.9:</b> Bronchiectasis Photo Courtesy: TA Shepur, KIMS, Hubli</p>	<p>Bilateral dilatation of the bronchi at various levels is visible; left &gt; right.</p> <p>Bronchiectasis: Irreversible abnormal dilatation of the bronchial tree.</p> <p><i>Symptoms:</i> Cough and copious purulent sputum; Others: Hemoptysis, fever, anorexia and poor weight gain.</p> <p><i>Signs:</i> Crackles localized to the affected area, wheezing, and digital clubbing.</p>	<ul style="list-style-type: none"> <li>• The initial therapy is to decrease airway obstruction and control infection.</li> <li>• Chest physiotherapy.</li> <li>• Bronchodilators 2 to 4 weeks of antibiotics.</li> <li>• Chronic prophylaxis: Oral macrolide or nebulized antibiotics.</li> <li>• Underlying disorder should be addressed.</li> <li>• Sometimes segmental or lobar resection is done in localized bronchiectasis.</li> <li>• Rarely lung transplantation.</li> </ul>


Picture	Note	Management
 <p><b>Figure 7.1.10:</b> Bronchiolitis Photo Courtesy: Devaraj Raichur, KIMS, Hubli</p>	<p>Hyperinflated lungs are seen. Common age: 2 months to 2 years. Predominantly a viral disease. Respiratory syncytial virus (RSV) is the most common cause. Other agents include parainfluenza and adenoviruses, <i>Mycoplasma</i>, and other viruses.</p> <p>Starts as mild upper respiratory tract infection (URTI) followed by respiratory distress with wheezy cough, dyspnea and irritability.</p>	<ul style="list-style-type: none"> <li>• Mainly supportive.</li> <li>• Cool humidified O<sub>2</sub>.</li> <li>• Bronchodilators.</li> <li>• Corticosteroids are not recommended in previously healthy children.</li> <li>• In children with congenital heart or lung disease, ribavirin may be administered by aerosol.</li> <li>• Antibiotics only in secondary bacterial pneumonia.</li> </ul>
 <p><b>Figure 7.1.11:</b> Cellulitis of the nose—dangerous area of the face Photo Courtesy: S Nagabhushana, Bengaluru</p>	<p>Swelling, redness and tenderness of the tip of the nose are present. Infections in the “Dangerous area of the face” can lead to cavernous sinus thrombosis.</p>	<ul style="list-style-type: none"> <li>• Antibiotics covering Streptococci, <i>Staphylococcus aureus</i>, and <i>H. influenzae</i>. (e.g. Co-amoxycylav).</li> <li>• Symptomatic therapy.</li> </ul>
 <p><b>Figures 7.1.12A and B:</b> (A) Right Empyema; (B) Right Empyema—CT scan Photo Courtesy: NK Kalappanavar, S Kavya, Davangere</p>	<p>Empyema, collection of pus in pleural space, is usually a complication of untreated or inadequately treated pneumonia. <i>Symptoms:</i> Cough, dyspnea, retractions, tachypnea, orthopnea, or cyanosis. <i>Physical findings:</i> Signs suggestive of pleural effusion.</p> <p>Empyema is usually differentiated from serofibrinous pleurisy by thoracentesis.</p> <p>Cross-section CT thorax showing pleural collection with collapsed right lung (Fig. 7.1.12B).</p>	<ul style="list-style-type: none"> <li>• Antibiotics.</li> <li>• Thoracentesis and chest tube drainage with or without a fibrinolytic agent.</li> <li>• Video-assisted thoracoscopic surgery (VATS) or open decortications.</li> </ul>




Picture	Note	Management
<p><b>Hydropneumothorax/Pyopneumothorax</b></p>  <p><b>Figure 7.1.13:</b> Hydropneumothorax—left side Photo Courtesy: TU Sukumaran, PIMS, Thiruvalla</p>	<p>Air-fluid level indicates presence of gas and liquid in the pleural space.</p>	<p>Treatment: as in pleural effusion/empyema.</p>



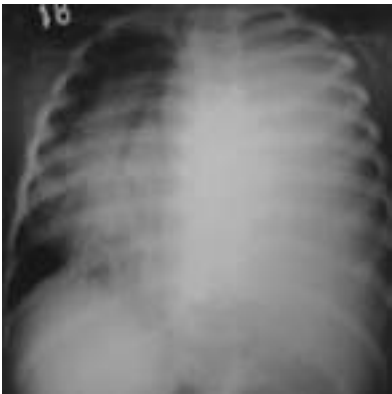
### ***Klebsiella* Pneumonia**

 <p><b>Figure 7.1.14:</b> <i>Klebsiella</i> pneumonia Photo Courtesy: TU Sukumaran, PIMS, Thiruvalla</p>	<p>Upper lobe involvement with pneumatoceles and loculated empyema is suggestive of <i>Klebsiella</i> pneumonia.</p> <p><i>Klebsiella</i> pneumonia is common in newborns. Sputum appears like ‘Red Currant Jelly’. X-ray may show ‘Bulging fissure sign’.</p>	<p>Antibiotics effective against <i>Klebsiella</i>:</p> <ul style="list-style-type: none"> <li>• Amoxicillin-clavulanate (20–45 mg/kg /24 hr divided q 8–12 hr PO).</li> <li>• Ceftriaxone (50–75 mg/kg q 24 hr IV or IM).</li> <li>• Amikacin (15–25 mg/kg/24 hr divided q 8–12 hr IV or IM).</li> </ul>
--	--	---

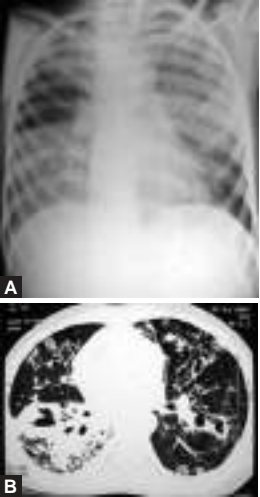


### ***Klebsiella* Pneumonia—‘Bulging Fissure Sign’**




 <p><b>Figure 7.1.15:</b> <i>Klebsiella</i> pneumonia—Bulging fissure sign Photo Courtesy: Devaraj Raichur, KIMS, Hubli</p>	<p>Bulging lower border of consolidated right upper lobe is suggestive of <i>Klebsiella</i> pneumonia.</p>	<p>Antibiotics effective against <i>Klebsiella</i>:</p> <ul style="list-style-type: none"> <li>• Amoxicillin-clavulanate (20–45 mg/kg /24 hr divided q 8–12 hr PO).</li> <li>• Ceftriaxone (50–75 mg/kg q 24 hr IV or IM).</li> <li>• Amikacin (15–25 mg/kg/24 hr divided q 8–12 hr IV or IM).</li> </ul>
--	--	---


Picture	Note	Management
 <p><b>Figure 7.1.16:</b> Lung abscess Photo Courtesy: TU Sukumaran, PIMS, Thiruvalla</p>	<p>Localized area of thick-walled cavity is seen in the right mid-zone. Etiologic agents: Anaerobic and aerobic bacteria. Fungi in immunocompromised patients. <i>Symptoms:</i> Cough, fever, dyspnea, chest pain, vomiting, sputum production, weight loss, and hemoptysis. <i>Signs:</i> Tachypnea, retractions with accessory muscle use, decreased breath sounds, and dullness to percussion in the affected area.</p>	<ul style="list-style-type: none"> <li>• For uncomplicated cases, antibiotics for 4 to 6 weeks, covering <i>S. aureus</i>, anaerobes and gram-negative bacteria.</li> <li>• For severely ill patients who fail to improve after 7 to 10 days of antimicrobial therapy, surgical interventions like percutaneous aspiration techniques, and rarely thoracotomy with lobectomy and/or decortication may be necessary.</li> </ul>
 <p><b>Figure 7.1.17:</b> Measles bronchopneumonia Photo Courtesy: Devaraj Raichur, KIMS, Hubli</p>	<p>Fine, reticular interstitial opacities are evident in the radiograph of a child having measles with respiratory distress. Measles bronchopneumonia (Giant cell pneumonia) is caused directly by measles virus. It should be differentiated from superimposed bacterial infections, which are also common.</p>	<ul style="list-style-type: none"> <li>• Airway humidification and supplemental oxygen.</li> <li>• Ventilator support—in case of respiratory failure.</li> <li>• Prophylactic antimicrobial therapy is not indicated. Antimicrobials are used if bacterial pneumonia cannot be ruled out.</li> <li>• Vitamin A supplementation.</li> </ul>
 <p><b>Figure 7.1.18:</b> Barrel-chest in MAS Photo Courtesy: Devaraj Raichur, KIMS, Hubli</p>	<p>Increased anteroposterior (AP) diameter of chest is seen in a neonate with MAS. Meconium staining of the skin and the umbilical cord are commonly seen. Normally, infants have relatively higher AP diameter than older children and adults, but the ball-valve mechanism of the aspirated meconium increases the AP diameter further.</p>	<ul style="list-style-type: none"> <li>• Supportive care and standard management of respiratory distress.</li> <li>• Exogenous surfactant in severe cases.</li> <li>• Continuous positive airway pressure (CPAP) and mechanical ventilation in moderate-to-severe MAS.</li> <li>• High frequency ventilation (HFV).</li> <li>• inhaled nitric oxide (iNO).</li> <li>• Extracorporeal membrane oxygenation (ECMO).</li> </ul>

Picture	Note	Management
<p><b>Miliary Tuberculosis of the Lungs</b></p>  <p><b>Figure 7.1.19:</b> Miliary tuberculosis of the lungs Photo Courtesy: Devaraj Raichur, HS Surendra, KIMS, Hubli</p>	<p>The fine, round, millet-like opacities in both lung fields (miliary mottling) with right paratracheal lymphadenopathy.</p> <p>Miliary tuberculosis is the most clinically significant form of disseminated tuberculosis.</p> <p>More common in infants, malnourished and immunocompromised children.</p>	<ul style="list-style-type: none"> <li>• Antitubercular therapy (ATT)—2HRZE<sub>3</sub> + 4HR<sub>3</sub> (DOTS regimen) given for 6 months.</li> <li>• Fever usually declines within 2 to 3 weeks of starting ATT.</li> <li>• Corticosteroids relieve symptoms faster.</li> </ul>
<p><b>Pleural Effusion</b></p>  <p><b>Figure 7.1.20:</b> Bilateral pleural effusion in congenital Chikungunya Photo Courtesy: Devaraj Raichur, KIMS, Hubli</p>	<p>Bilateral thin layer of opacity separating the rib-cage from the lungs.</p>	<ul style="list-style-type: none"> <li>• Supportive therapy.</li> <li>• Therapeutic pleural tap if severe respiratory distress occurs.</li> </ul>
<p><b>Pleural Effusion/Empyema</b></p>  <p><b>Figure 7.1.21:</b> Left pleural effusion with left lung collapse-consolidation Photo Courtesy: Devaraj Raichur, KIMS, Hubli</p>	<p>Homogeneous opacity obliterating left costophrenic angle with mediastinal shift to right is seen.</p> <p>Pleural effusion could be a transudate or an exudate.</p> <p>Commonest cause—bacterial pneumonia. Large effusions produce cough and respiratory distress.</p> <p><i>Signs:</i> Mediastinal shift to opposite side, fullness of the intercostal spaces, reduced tactile fremitus, stony dullness, decreased or absent breath sounds.</p>	<ul style="list-style-type: none"> <li>• Treat the underlying disease.</li> <li>• Therapeutic thorocentesis.</li> <li>• Chest tube drainage—when fluid reaccumulates to cause respiratory embarrassment or if fluid is purulent.</li> <li>• In parapneumonic effusion with pleural fluid pH &lt;7.20 or glucose level &lt;50 mg/dl, tube thoracostomy is done.</li> </ul>






Picture	Note	Management
<b><i>Pneumocystis jiroveci</i> (carinii) Pneumonia</b>		
 <p data-bbox="164 788 581 887"><b>Figures 7.1.22A and B:</b> <i>Pneumocystis jiroveci</i> (<i>carinii</i>) pneumonia Photo Courtesy: Vinod Ratageri, TA Shepur KIMS, Hubli</p>	<p data-bbox="626 273 1036 461">(Fig. 7.1.22A) Right upper zone and lower zone consolidation; Left upper zone and middle zone consolidation; Sparing of right middle zone suggesting <i>Pneumocystis jiroveci</i> pneumonia:</p> <p data-bbox="626 474 1036 694">It is a life-threatening infection in the immunocompromised children without prophylaxis, ~40% of children with AIDS, 12% of children with leukemia, and 10% of patients with organ transplant recipients experience <i>P. carinii</i> pneumonia.</p> <p data-bbox="626 707 1036 956">(Fig. 7.1.22B) Bilateral extensive poorly defined nodular shadows seen mainly in the right lobe. Thick walled cavitary lesion seen in right lower lobe apical segment. Thickening of the bronchovascular interstitium seen in bilateral parahilar region.</p>	<ul data-bbox="1070 273 1479 887" style="list-style-type: none"> <li>• (A and B) Trimethprim-sulfamethoxazole (TMP-SMZ) (15–20 mg TMP/kg/day divided qid).</li> <li>• Duration: 3 weeks in AIDS and 2 weeks for others.</li> <li>• Alternatively, pentamidine isethionate (4 mg/kg as a single daily dose IV).</li> <li>• Atovaquone (750 mg <i>bid</i> with food, for &gt;13 years of age).</li> <li>• Other effective therapies include trimetrexate glucuronate or combinations of trimethoprim plus dapsone, or clindamycin plus primaquine.</li> <li>• Corticosteroids (Prednisolone) are used for moderate to severe cases.</li> </ul>
<b>Pneumococcal Pneumonia</b>		
 <p data-bbox="164 1351 602 1422"><b>Figure 7.1.23:</b> Collapse—consolidation of right upper lobe Photo Courtesy: TU Sukumaran, PIMS, Thiruvalla</p>	<p data-bbox="626 1054 1036 1150">Lobar/segmental distribution of pneumonia. Commonly seen with pneumococcal pneumonia.</p> <p data-bbox="626 1163 1036 1351">Pneumococcal pneumonia manifests as tachypnea, increased work of breathing, cyanosis and respiratory fatigue. Chest auscultation - crackles and wheezing.</p>	<ul data-bbox="1070 1054 1479 1426" style="list-style-type: none"> <li>• Multidrug resistant (MDR) strains of have been reported.</li> <li>• Penicillin-G—drug of choice for sensitive organisms.</li> <li>• High-dose cefotaxime and ceftriaxone are effective, even in cephalosporin-resistant strains.</li> <li>• For MDR pneumococci: Vancomycin (resistance has not been seen to date). Linezolid is an alternative.</li> </ul>
<b>Primary Complex</b>		
 <p data-bbox="164 1837 492 1909"><b>Figure 7.1.24:</b> Primary complex Photo Courtesy: KE Elizabeth, GMC Thiruvananthapuram</p>	<p data-bbox="626 1530 1036 1627">Spindle shaped effusion into the minor fissure in a child with strongly positive Mantoux test.</p>	<p data-bbox="1070 1530 1455 1592">2HRZE<sub>3</sub> + 4HR<sub>3</sub> as per the revised category I of RNTCP (2011).</p>

Picture	Note	Management
<p><b>Respiratory Distress</b></p>  <p><b>Figure 7.1.25:</b> Respiratory distress in a neonate Photo Courtesy: Devaraj Raichur, KIMS, Hubli</p>	<p>Respiratory distress manifested as: Chest retractions (subcostal retractions) and intercostal retractions.</p> <p>Other manifestations could be acting alae nasi, and accessory muscles of respiration, cyanosis.</p> <p>Various airway and pulmonary parenchymal conditions can produce chest retractions.</p>	<ul style="list-style-type: none"> <li>• Assess ABCs</li> <li>• O<sub>2</sub> therapy</li> <li>• Maintain PaCO<sub>2</sub></li> <li>• CPAP</li> <li>• IMV</li> <li>• Treat the underlying disorder.</li> </ul>
<p><b>Respiratory Distress Syndrome (RDS)</b></p>  <p><b>Figure 7.1.26:</b> RDS in a neonate Photo Courtesy: Devaraj Raichur, KIMS, Hubli</p>	<p>Ground-glass appearance of lungs with air-bronchogram.</p> <p>Borders of the heart are ill-defined.</p> <p><i>Clinical manifestations:</i> Primarily premature infants, tachypnea, grunting, intercostal and subcostal retractions, nasal flaring, and duskiness/cyanosis. Later shock ensues.</p> <p><i>Breath sounds:</i> Normal or diminished ± fine rales.</p>	<ul style="list-style-type: none"> <li>• Most are self-limited.</li> <li>• Avoid hypothermia.</li> <li>• Warm humidified O<sub>2</sub> to maintain PaO<sub>2</sub> 50 to 70 mm Hg.</li> <li>• Surfactant therapy in moderate to severe cases of RDS.</li> <li>• CPAP/IMV if PaO<sub>2</sub> cannot be maintained above 50 mm Hg.</li> <li>• Other modalities of treatment are high frequency ventilation, ECMO and inhaled nitric oxide (iNO).</li> </ul>
<p><b>Retropharyngeal Abscess</b></p>  <p><b>Figures 7.1.27A and B:</b> (A) Retropharyngeal abscess; (B) Lateral X-ray of retropharyngeal abscess Photo Courtesy: JK Lakhani, Gadag</p>	<p>(Fig. 7.1.27A) The swelling of face, and the torticollis produced by a retropharyngeal abscess.</p> <p><i>Symptoms:</i> Fever, irritability, decreased oral intake and drooling. Neck stiffness, torticollis and refusal to move the neck.</p> <p><i>Signs:</i> Muffled voice, stridor, and respiratory distress. Physical examination- Bulging of the posterior pharyngeal wall, cervical lymphadenopathy may be present.</p> <p>(Fig. 7.1.27B) Lateral X-ray of neck of the above patient clearly shows the increased space between the pharyngeal air shadow and the vertebrae.</p> <p>Posterior pharyngeal wall is bulging.</p>	<ul style="list-style-type: none"> <li>• Intravenous antibiotics with or without surgical drainage.</li> <li>• A third generation cephalosporin with ampicillin-sulbactam or clindamycin to provide anaerobic coverage is effective.</li> <li>• Patients who have respiratory distress or who fail to improve with intravenous antibiotics can be treated with surgical drainage.</li> </ul>


Picture	Note	Management
<p data-bbox="154 214 609 255"><b>Cavitary Tuberculosis with Necrotizing Bronchopneumonia</b></p>  <p data-bbox="162 470 592 572"><b>Figures 7.1.28A and B:</b> Cavitory tuberculosis with necrotizing bronchopneumonia: (A) X-ray and (B) CT scan Photo Courtesy: Devaraj Raichur, KIMS, Hubli</p>	<p data-bbox="625 275 1031 398">(Fig. 7.1.28A) Cavitory lesions in the right lung with extensive infiltrates in left lung in a child with sputum positive tuberculosis.</p> <p data-bbox="625 408 1031 500">Cavitory pulmonary tuberculosis is uncommon in children, but may be seen, as in this instance.</p> <p data-bbox="625 511 1031 602">(Fig. 7.1.28B) CT scan of the same child as above, clearly depicting the necrotizing nature of the lesions.</p>	<p data-bbox="1068 275 1474 398">Drug regimen for revised categories under Rural National Tuberculosis Control Programme (RNTCP) (2011) are:</p> <ul data-bbox="1068 408 1474 511" style="list-style-type: none"> <li>• Cat I (New): 2HRZE<sub>3</sub> + 4HR<sub>3</sub></li> <li>• Cat II (Previously treated): 2HRZES<sub>3</sub> + 1HRZE<sub>3</sub> + 5HRE<sub>3</sub></li> </ul> <p data-bbox="1068 521 1474 602">Steroids—in bronchial obstruction, massive pleural effusion and miliary tuberculosis.</p>

### Staphylococcal Pneumonia


 <p data-bbox="162 1124 592 1175"><b>Figure 7.1.29:</b> Staphylococcal pneumonia Photo Courtesy: TU Sukumaran, PIMS, Thiruvalla</p>	<p data-bbox="625 797 1031 950">Extensive destruction of lung parenchyma with formation of cavities bilaterally is visible indicating staphylococcal pneumonia.</p> <p data-bbox="625 960 1031 1022"><i>S. aureus</i> produces confluent bronchopneumonia.</p> <p data-bbox="625 1032 1031 1246">Characterized by the presence of extensive areas of hemorrhagic necrosis and irregular areas of cavitation of the lung parenchyma, ending in pneumatoceles, empyema or at times, bronchopulmonary fistulas.</p>	<ul data-bbox="1068 797 1474 1154" style="list-style-type: none"> <li>• Cloxacillin or cefazolin- Initial antibacterial for serious infections thought to be due to methicillin-susceptible <i>S. aureus</i> (MSSA).</li> <li>• Vancomycin for the initial treatment for penicillin-allergic individuals and for suspected serious <i>S. aureus</i> infections that might be due to MRSA (Alternatives: linezolid or teicoplanin).</li> </ul>
 <p data-bbox="162 1727 592 1778"><b>Figure 7.1.30:</b> Staphylococcal pneumonia Photo Courtesy: Devaraj Raichur, KIMS, Hubli</p>	<p data-bbox="625 1318 1031 1379">Bilateral consolidation with cavities is seen.</p>	<ul data-bbox="1068 1318 1474 1676" style="list-style-type: none"> <li>• Cloxacillin or cefazolin- Initial antibacterial for serious infections thought to be due to methicillin-susceptible <i>S. aureus</i> (MSSA).</li> <li>• Vancomycin- for the initial treatment for penicillin-allergic individuals and for suspected serious <i>S. aureus</i> infections that might be due to MRSA (Alternatives: linezolid or teicoplanin).</li> </ul>




Picture	Note	Management
<p><b>Tuberculoma of Right Lung</b></p>  <p><b>Figure 7.1.31:</b> Tuberculoma of right lung Photo Courtesy: Vinod Ratageri, TA Shepur KIMS, Hubli</p>	<p>Calcified nodular (round) lesion involving middle and lower lobe of right lung is clearly visible.</p>	<p>Drug regimen for revised categories under RNTCP (2011) are:</p> <ul style="list-style-type: none"> <li>• Cat I (New): 2HRZE<sub>3</sub> + 4HR<sub>3</sub></li> <li>• Cat II (Previously treated): 2HRZES<sub>3</sub> + 1HRZE<sub>3</sub> + 5HRE<sub>3</sub></li> </ul> <p>Steroids—in bronchial obstruction, massive pleural effusion and miliary tuberculosis.</p>

### Tuberculoma of Right Lung—CT Scan


 <p><b>Figure 7.1.32:</b> Tuberculoma of right lung—CT scan Photo Courtesy: TA Shepur, KIMS, Hubli</p>	<p>CT scan depicting the calcified lesion in the right middle lobe region.</p>	<p>Drug regimen for revised categories under RNTCP (2011) are:</p> <ul style="list-style-type: none"> <li>• Cat I (New): 2HRZE<sub>3</sub> + 4HR<sub>3</sub></li> <li>• Cat II (Previously treated): 2HRZES<sub>3</sub> + 1HRZE<sub>3</sub> + 5HRE<sub>3</sub></li> </ul> <p>Steroids—in bronchial obstruction, massive pleural effusion and miliary tuberculosis.</p>
--	--	--

### Tuberculosis—Right Middle Lobe Collapse Consolidation

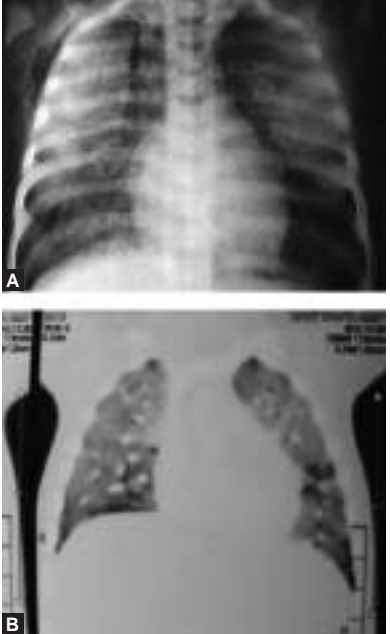
 <p><b>Figure 7.1.33:</b> Tuberculosis-right middle lobe collapse consolidation Photo Courtesy: Devaraj Raichur and Pushpa Panigatti, KIMS, Hubli</p>	<p>Collapse consolidation of middle lobe of right lung is evident. Cardiac Silhouette's sign (obliteration of the right margin of the heart) is present.</p>	<p>Drug regimen for revised categories under RNTCP (2011) are:</p> <ul style="list-style-type: none"> <li>• Cat I (New): 2HRZE<sub>3</sub> + 4HR<sub>3</sub></li> <li>• Cat II (Previously treated): 2HRZES<sub>3</sub> + 1HRZE<sub>3</sub> + 5HRE<sub>3</sub></li> </ul> <p>Steroids—in bronchial obstruction, massive pleural effusion and miliary tuberculosis.</p>
--	--	--


Picture	Note	Management
<b>Tuberculosis—Bilateral Paratracheal Lymphadenopathy</b>		
 <p data-bbox="164 639 529 715"><b>Figure 7.1.34:</b> Tuberculosis—bilateral paratracheal lymphadenopathy <i>Photo Courtesy:</i> TA Shepur, KIMS, Hubli</p>	<p data-bbox="626 273 1023 333">The oval opacities on both sides of the lower trachea.</p>	<p data-bbox="1070 273 1477 333">Drug regimen for revised categories under RNTCP (2011) are:</p> <ul data-bbox="1070 345 1430 445" style="list-style-type: none"> <li>• Cat I (New): 2HRZE3 + 4HR3</li> <li>• Cat II (Previously treated): 2HRZES3 + 1HRZE3 + 5HRE3</li> </ul> <p data-bbox="1070 457 1487 547">Steroids—in bronchial obstruction, massive pleural effusion and miliary tuberculosis.</p>
<b>Tuberculosis—Hilar Lymphadenopathy</b>		
 <p data-bbox="164 1214 602 1289"><b>Figure 7.1.35:</b> Tuberculosis—Hilar lymphadenopathy <i>Photo Courtesy:</i> TU Sukumaran, PIMS, Thiruvalla</p>	<p data-bbox="626 901 1000 960">The lymph node prominences in hilar regions.</p> <p data-bbox="626 972 1037 1093">Lungs are the most common site for tuberculosis. The disease in lungs varies from a small parenchymal lesion to disseminated disease.</p> <p data-bbox="626 1105 1027 1165">The clinical manifestations depend on underlying pulmonary lesion.</p> <p data-bbox="626 1177 898 1236">TB in children is mostly paucibacillary.</p>	<p data-bbox="1070 901 1477 960">Drug regimen for revised categories under RNTCP (2011) are:</p> <ul data-bbox="1070 972 1430 1073" style="list-style-type: none"> <li>• Cat I (New): 2HRZE3 + 4HR3</li> <li>• Cat II (Previously treated): 2HRZES3 + 1HRZE3 + 5HRE3</li> </ul> <p data-bbox="1070 1085 1487 1175">Steroids—in bronchial obstruction, massive pleural effusion and miliary tuberculosis.</p>
<b>Tuberculous Pleural Effusion—Right Side with Hilar Lymphadenopathy</b>		
 <p data-bbox="164 1786 602 1862"><b>Figure 7.1.36:</b> Tuberculous pleural effusion—right side with hilar lymphadenopathy <i>Photo Courtesy:</i> TU Sukumaran, PIMS, Thiruvalla</p>	<p data-bbox="626 1473 1019 1594">Small pleural collection with obliteration of costophrenic angle on right side associated with right hilar lymphadenopathy is evident.</p>	<p data-bbox="1070 1473 1477 1533">Drug regimen for revised categories under RNTCP (2011) are:</p> <ul data-bbox="1070 1545 1430 1645" style="list-style-type: none"> <li>• Cat I (New): 2HRZE3 + 4HR3</li> <li>• Cat II (Previously treated): 2HRZES3 + 1HRZE3 + 5HRE3</li> </ul> <p data-bbox="1070 1657 1487 1747">Steroids—in bronchial obstruction, massive pleural effusion and miliary tuberculosis.</p>


## 7.2 UNCOMMON CONDITIONS BUT NOT RARE

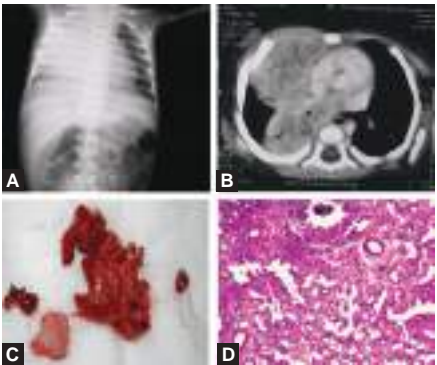
Picture	Note	Management
 <p><b>Figure 7.2.1:</b> Acute epiglottitis—thumb sign Photo Courtesy: TU Sukumaran, PIMS, Thiruvalla</p>	<p>Potentially lethal condition. May present with high fever, sore throat, dyspnea, and rapidly progressing respiratory obstruction.</p> <p><i>Etiology:</i> <i>H. influenzae</i> type b Other agents, <i>Streptococcus pyogenes</i>, pneumococci, and <i>Staphylococcus aureus</i>.</p> <p><i>Diagnosis:</i> Laryngoscopy—a large, “cherry red” swollen epiglottis. <i>X-ray neck (lateral view):</i> “thumb sign” of swollen epiglottis.</p>	<ul style="list-style-type: none"> <li>- Artificial airway-under controlled conditions.</li> <li>-O<sub>2</sub>.</li> <li>- Antibiotics for 7 to 10 days:             <ul style="list-style-type: none"> <li>• Ceftriaxone,</li> <li>• Cefotaxime, or</li> <li>• Ampicillin + sulbactam.</li> </ul> </li> <li>- Indications for rifampin prophylaxis: (1) any contact &lt;4 years of age who is incompletely immunized; (2) any contact &lt;12 months who has not received the primary vaccination series; or (3) an immunocompromised child in the household.</li> </ul>

## Bronchiolitis Obliterans Organizing Pneumonia (BOOP)


 <p><b>Figures 7.2.2A and B:</b> (A) Bronchiolitis obliterans organizing pneumonia (BOOP); (B) BOOP on CT Chest Photo Courtesy: NK Kalappanavar and S Kavya, Davangere</p>	<p>BOOP is a fibrosing interstitial lung disease of unknown etiology and includes the histologic features of bronchiolitis obliterans. Also called cryptogenic organizing pneumonia. Overall incidence in general population is 0.01%. Less occurrence in children. Presents like pneumonia, bronchitis or bronchiolitis.</p> <p><i>Etiology:</i> is unknown. Thought to be precipitated by adenovirus, measles, influenza, Pertussis, <i>Legionella</i>, <i>Mycoplasma</i>.</p> <p><i>Other causes:</i> JRA, SLE, scleroderma, etc. Chest CT demonstrates patchy areas of hyperlucency and bronchiectasis (Figs 7.2.2A and B). BOOP is best diagnosed by open lung biopsy or transbronchial biopsy.</p>	<ul style="list-style-type: none"> <li>• Asymptomatic or nonprogressive BOOP—only observation.</li> <li>• Symptomatic and progressive disease—oral corticosteroids for up to 1 year.</li> <li>• <i>Prognosis:</i> Total recovery in 60 to 80%.</li> <li>• Acute respiratory distress syndrome (ARDS) occurs rarely.</li> </ul>
---	--	--

Picture	Note	Management
<p><b>Bronchogenic Cyst</b></p>  <p><b>Figure 7.2.3:</b> Bronchogenic cyst Photo Courtesy: JK Lakhani, Gadag</p>	<p>The cystic lesion in right mid-lower zone. Bronchogenic cyst is an abnormal budding of the tracheal diverticulum of the foregut before the 16<sup>th</sup> week of gestation. Most common site—right side and near a midline structure (trachea, esophagus, carina) symptoms—Fever, chest pain, productive cough, and dysphagia chest X-ray—cyst, which may contain an air-fluid level.</p>	<p><i>Symptomatic cysts:</i></p> <ul style="list-style-type: none"> <li>• Appropriate antibiotic for infection</li> <li>• Surgical excision.</li> </ul> <p><i>Asymptomatic cysts:</i> Excised in view of the high rate of infection.</p>




<p><b>Castleman's Disease</b></p>  <p><b>Figure 7.2.4:</b> Castleman's disease Photo Courtesy: KE Elizabeth, GMC, Thiruvananthapuram</p>	<p>Mediastinal/Hilar lymphadenopathy proved as Castleman's disease (giant or angiofollicular lymph node hyperplasia, lymphoid hamartoma, angiofollicular lymph node hyperplasia) on biopsy as it was persisting after antitubercular treatment.</p> <p>It is an uncommon noncancerous lymphoproliferative disorder that can involve single lymph node stations or can be systemic.</p>	<p>Unicentric disease: surgical resection is curative.</p> <p>Multicentric disease:</p> <ul style="list-style-type: none"> <li>• No standard therapy available</li> <li>• Ganciclovir</li> <li>• Anti CD20 B-cell monoclonal antibody, rituximab</li> <li>• Tocilizumab.</li> </ul> <p>Other treatments for multicentric Castleman disease include the following:</p> <ul style="list-style-type: none"> <li>• Corticosteroids</li> <li>• Chemotherapy</li> <li>• Thalidomide.</li> </ul>
---	--	---


Picture	Note	Management
<p data-bbox="126 212 586 255"><b>Congenital Cystic Adenomatoid Malformation (CCAM)</b></p>  <p data-bbox="138 649 557 778"><b>Figures 7.2.5A to D:</b> Congenital cystic adenomatoid malformation (CCAM) of right lung—(A) X-ray; (B) CT scan; (C) Specimen at surgical resection and (D) Histopathology <i>Photo Courtesy:</i> JK Lakhani, Gadag</p>	<p data-bbox="586 271 1029 363">(Fig. 7.2.5A) The large opacity occupying upper and midzone of the right lung. Incidence—4/100000.</p> <p data-bbox="586 376 1029 911"><i>Presentation:</i> In early infancy—respiratory distress, recurrent respiratory infection and pneumothorax. In midchildhood—recurrent or persistent pulmonary infection, relatively acute chest pain. Breath sounds may be decreased, with mediastinal shift away from the lesion. (Fig. 7.2.5B) CT scan reveals the fluid filled lesion in right anterolateral aspect of the chest cavity. (Fig. 7.2.5C) Macroscopic view of the CCAM depicting the cystic nature of the specimen at surgical excision. (Fig. 7.2.5D) The cystic spaces in this histopathologic specimen.</p>	<ul data-bbox="1045 271 1458 568" style="list-style-type: none"> <li>• Antenatal intervention in affected infants is controversial but may include excision of the affected lobe for microcystic lesions, aspiration of macrocystic lesions, and open fetal surgery.</li> <li>• In the postnatal period, surgery is indicated for all symptomatic patients.</li> </ul>

### Congenital Diaphragmatic Hernia


 <p data-bbox="138 1582 557 1659"><b>Figure 7.2.6:</b> Congenital diaphragmatic hernia—left posterolateral <i>Photo Courtesy:</i> Devaraj Raichur, KIMS, Hubli</p>	<p data-bbox="586 1069 1029 1289">Bowel loops in the left hemithorax in a neonate with scaphoid abdomen. Diaphragmatic hernia is a communication between the abdominal and thoracic cavities with or without abdominal contents in the thorax. Types:</p> <ul data-bbox="586 1302 1029 1432" style="list-style-type: none"> <li>• Bochdalek (posterolateral, left side) 90% of cases.</li> <li>• Morgagni (anteriorly and right side).</li> </ul> <p data-bbox="586 1445 1029 1637">Presents as respiratory distress at birth, scaphoid abdomen, bowel sounds in the chest on auscultation. Most common associated anomaly is pulmonary hypoplasia (the limiting factor for survival).</p>	<ul data-bbox="1045 1069 1458 1232" style="list-style-type: none"> <li>• Mechanical ventilation and oxygen may be required to support gas exchange.</li> <li>• Surgical correction of hernia is required.</li> </ul>
---	--	--

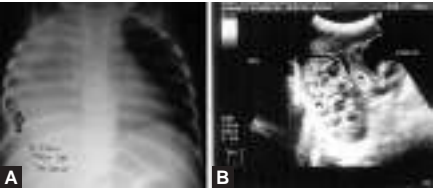




Picture	Note	Management
<h3 data-bbox="154 214 609 255">Congenital Lobar Emphysema</h3>  <p data-bbox="162 602 544 684"><b>Figure 7.2.7:</b> Congenital lobar emphysema—right lower lobe Photo Courtesy: TU Sukumaran, PIMS, Thiruvalla</p>	<p data-bbox="625 275 1031 367">The hyperlucency of the lung on right hemithorax with mediastinal shift to the left.</p> <p data-bbox="625 378 1031 470"><i>Age of presentation:</i> Usually in neonatal period, and in 5% may present up to 5 to 6 months.</p> <p data-bbox="625 480 1031 551"><i>Signs:</i> Mild tachypnea and wheeze to severe dyspnea with cyanosis.</p> <p data-bbox="625 562 1031 592"><i>Most common site:</i> Left upper lobe.</p> <p data-bbox="625 602 1031 684"><i>Pathology:</i> Overdistension of affected side and atelectasis of ipsilateral normal lung may ensue.</p>	<ul data-bbox="1071 275 1477 643" style="list-style-type: none"> <li>• In children who are less than 2 months of age without severe symptoms can be observed.</li> <li>• Some patients respond to medical management.</li> <li>• Immediate surgery and excision of the lobe may be life saving when cyanosis and severe respiratory distress are present.</li> <li>• Selective intubation of the unaffected lung may be of value.</li> </ul>
<h3 data-bbox="154 725 609 766">Esophageal Atresia with Tracheoesophageal Fistula</h3>  <p data-bbox="162 1246 576 1328"><b>Figure 7.2.8:</b> Esophageal atresia with tracheoesophageal fistula Photo Courtesy: Devaraj Raichur, KIMS, Hubli</p>	<p data-bbox="625 807 1031 991">Feeding tube looping in the blunt pouch in the upper esophagus is evident. Presence of gas in stomach suggests fistula between trachea and the lower part of the esophagus (most common type of esophageal atresia).</p> <p data-bbox="625 1001 1031 1093"><i>Esophageal atresia:</i> Most common congenital anomaly of the esophagus.</p> <p data-bbox="625 1103 1031 1267"><i>Symptoms:</i> Frothing and bubbling from mouth and nose after birth, episodes of coughing, cyanosis, and respiratory distress, aspiration pneumonitis</p> <p data-bbox="625 1277 1031 1338">H-type fistulas presents later with chronic respiratory problems.</p>	<ul data-bbox="1071 807 1477 1144" style="list-style-type: none"> <li>• Maintain patent airway.</li> <li>• Prevent aspiration by prone position and continuous suctioning.</li> <li>• Surgical ligation of the fistula and primary end-to-end anastomosis of the esophagus.</li> <li>• Primary repair cannot be done if gap between the atretic ends of the esophagus is &gt;3 to 4 cm.</li> </ul>
<h3 data-bbox="154 1369 609 1410">Eventration of the Diaphragm</h3>  <p data-bbox="162 1798 576 1880"><b>Figure 7.2.9:</b> Eventration of the left dome of diaphragm Photo Courtesy: TU Sukumaran, PIMS, Thiruvalla</p>	<p data-bbox="625 1461 1031 1614">Eventration of the diaphragm—an abnormal elevation, consisting of a thinned diaphragmatic muscle producing elevation of the left hemidiaphragm is seen.</p> <p data-bbox="625 1624 1031 1747"><i>Causes:</i> Congenital eventration (incomplete development of diaphragm), diaphragmatic paralysis, traction injury, iatrogenic injury.</p> <p data-bbox="625 1757 1031 1880"><i>Association:</i> Pulmonary sequestration, congenital heart disease, and chromosomal trisomies.</p>	<ul data-bbox="1071 1461 1477 1655" style="list-style-type: none"> <li>• Most eventrations are asymptomatic; they do not require repair.</li> <li>• Symptomatic eventrations—repaired by plication through an abdominal or thoracic approach.</li> </ul>

Picture	Note	Management
<p><b>Hypoplasia of the Right Lung</b></p>  <p><b>Figure 7.2.10:</b> Hypoplasia of the right lung Photo Courtesy: NK Kalappanavar S Kavya, Davangere</p>	<p>This 3 years old child was treated repeatedly for persistent pneumonia without radiological improvement. A reduction in volume of right hemithorax with reduced vascularity and mediastinal shift to right is seen. Usually presents as pulmonary hypertension of newborn (PPHN) in neonatal period and is associated with intrathoracic SOL, oligohydramnios, thoracic anomalies and deficient fetal movement due to neuromuscular disorders. Milder cases present later with respiratory infections.</p>	<ul style="list-style-type: none"> <li>• Oxygen.</li> <li>• Mechanical ventilation.</li> <li>• Inhaled nitric oxide for PPHN.</li> <li>• Extracorporeal membrane oxygenation (ECMO) may help for a critical period of time to permit survival.</li> <li>• Rib expanding devices in thoracic dystrophies.</li> </ul>

### Interstitial Lung Disease (ILD)

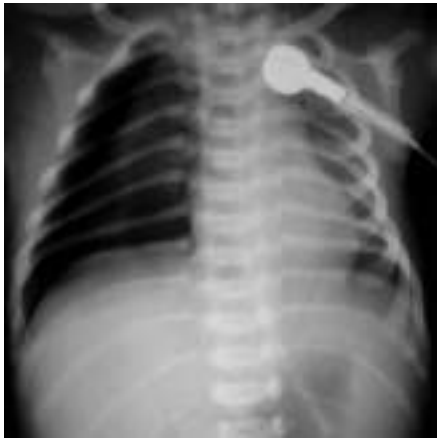 <p><b>Figures 7.2.11A and B:</b> (A) Interstitial lung disease; (B) Interstitial lung disease Photo Courtesy: NK Kalappanavar, S Kavya, Davangere</p>	<p>(Fig. 7.2.11A) Chest X-ray of interstitial lung disease (ILD) showing B/L patchy homogeneous opacities.</p> <p>Children with ILD present with dyspnea, tachypnea, cough, exercise limitation, and frequent respiratory infections.</p> <p>(Fig. 7.2.11B) High-resolution computed tomography (HRCT): It shows the extent and distribution of the parenchymal disease. Diffuse involvement of the most of the lung parenchyma with ground-glass opacities, or “fibrotic” changes with cystic lung disease.</p> <p><i>Other investigations:</i> Serology, genetic studies, BAL and lung biopsy, and immunological workup.</p>	<p>Supportive care (O<sub>2</sub>, adequate nutrition, and antimicrobial treatment for infections). Anti-inflammatory treatment with corticosteroids—the initial treatment of choice. Other treatments are hydroxychloroquine, azathioprine, cyclophosphamide, cyclosporine, methotrexate, intravenous immunoglobulin, and pulsed high-dose steroids. Lung transplantation for progressive or end-stage ILD. Preventive measures are avoidance of all inhalation irritants such as tobacco smoke, molds and bird antigens.</p>
--	--	--

Picture	Note	Management
<p data-bbox="152 212 1170 247"><b>Neuroblastoma (Secondary) with Right Pleural Effusion and 7th Rib Erosion</b></p>  <p data-bbox="164 476 574 609"><b>Figure 7.2.12:</b> Neuroblastoma (secondary) with right pleural effusion: (A) X-ray showing erosion of the right 7<sup>th</sup> rib (arrow) and (B) Ultrasound image Photo Courtesy: JK Lakhani, Gadag</p>	<p data-bbox="630 273 1036 363">In this case, FNAC confirmed the diagnosis. Primary was found in the right adrenal.</p> <p data-bbox="630 374 1040 854">Neuroblastoma (NB), the 3<sup>rd</sup> most common pediatric cancer, is an embryonal cancer of the peripheral sympathetic nervous system. Usually arises in the adrenal gland or in retroperitoneal sympathetic ganglia. Histologically, it may resemble other small round cell tumors. NB can present as a paraneoplastic syndrome—ataxia or opsomyoclonus (dancing eyes and dancing feet). Most common sites of metastasis are long bones and skull, bone marrow, liver, lymph nodes, and skin.</p>	<p data-bbox="1070 273 1481 686">Treatment for low-risk (stages 1 and 2) neuroblastoma is surgery. Observation for stage 4S. Treatment with chemotherapy or radiotherapy for the rare child with recurrence can be curative. Treatment for intermediate risk neuroblastoma are surgery, chemotherapy and in some cases radiotherapy. Treatment of high-risk neuroblastoma is induction chemotherapy with or without resection followed by focal radiation.</p>
<p data-bbox="152 887 428 921"><b>Pulmonary Agenesis</b></p>  <p data-bbox="164 1304 602 1357"><b>Figure 7.2.13:</b> Pulmonary agenesis left side Photo Courtesy: TU Sukumaran, PIMS, Thiruvalla</p>	<p data-bbox="630 948 1019 1038">Complete absence of left lung, left bronchus, mediastinal shift to the left are evident.</p> <p data-bbox="630 1048 1013 1109">Pulmonary agenesis is likely to be autosomal recessive.</p> <p data-bbox="630 1120 1040 1210"><i>Symptoms:</i> Related to central airway complications of stenosis and/or tracheobronchomalacia.</p> <p data-bbox="630 1220 1029 1357"><i>Associations:</i> VACTERL sequence, ipsilateral facial and skeletal malformations, central nervous system and cardiac malformations.</p>	<ul data-bbox="1070 948 1476 1046" style="list-style-type: none"> <li>• Conservative treatment is usually recommended.</li> <li>• Surgery in selected cases.</li> </ul>
<p data-bbox="152 1383 258 1418"><b>Tumors</b></p>  <p data-bbox="164 1800 578 1905"><b>Figure 7.2.14:</b> Pleuroblastoma, left side, with erosion of right 9<sup>th</sup> rib (arrow) Photo Courtesy: Devaraj Raichur, HS Surendra, KIMS, Hubli</p>	<p data-bbox="630 1445 1029 1561">Pleuroblastoma is a malignant tumor arising from pleura. Non-specific respiratory symptoms occur.</p> <p data-bbox="630 1571 935 1606">Three pathologic subtypes:</p> <ul data-bbox="630 1616 927 1723" style="list-style-type: none"> <li>• Type I: Purely cystic</li> <li>• Type II: Cystic and solid</li> <li>• Type III: Solid.</li> </ul> <p data-bbox="630 1733 1036 1823">Imaging (X-ray, CT, MRI) helps to determine the presence and precise location of the tumor.</p>	<ul data-bbox="1070 1445 1459 1606" style="list-style-type: none"> <li>• Type I treated with surgery with or without chemotherapy.</li> <li>• Type II and III treated with surgery and chemotherapy with or without radiotherapy.</li> </ul>

### 7.3 EMERGENCY SITUATIONS

Picture	Note	Management
---------	------	------------

#### Closed Pneumothorax

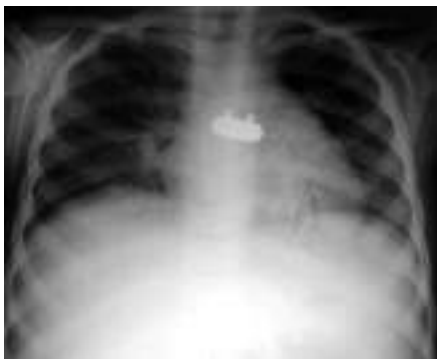

**Figure 7.3.1:** Right sided closed pneumothorax in a neonate  
*Photo Courtesy:* Devaraj Raichur, KIMS, Hubli

Pneumothorax is present but is not under tension.  
Mediastinal shift is absent.  
*Cardiovascular status:* Stable.

- Conservative management with O<sub>2</sub>, and other supportive measures usually resolves the pneumothorax.
- Close monitoring to detect the progression to tension pneumothorax at the earliest is essential.

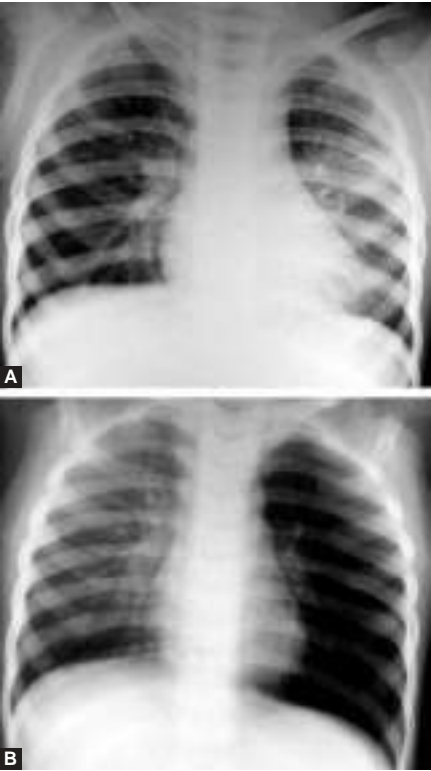
#### False Foreign Body in the Chest




**Figure 7.3.2:** False foreign body in the chest  
*Photo Courtesy:* Devaraj Raichur, KIMS, Hubli


Radiopaque substances outside the chest wall can sometimes be mistaken for a “foreign body”.

Proper history of conditions during the shooting of the X-ray and a thorough examination of the patient’s attire and ornaments can clarify the issue.


Picture	Note	Management
<p><b>Foreign Body Aspiration</b></p>  <p><b>Figures 7.3.3A and B:</b> Foreign body aspiration: (A) With pneumonia on admission and (B) Hyperinflated left lung during hospital stay <i>Photo Courtesy:</i> S Nagabushana, Bengaluru</p>	<p>A. This case initially presented with left lower lobe consolidation. Usual sequence of events of a foreign body are:</p> <ul style="list-style-type: none"> <li>• Initial event (1<sup>st</sup> stage)—violent paroxysms of coughing, choking, gagging, and possibly airway obstruction occur immediately.</li> <li>• Asymptomatic interval (2<sup>nd</sup> stage)—the foreign body becomes lodged, reflexes fatigue, and the immediate irritating symptoms subside. This stage is most deceitful and results in delayed diagnoses.</li> <li>• Complications (3<sup>rd</sup> stage)—obstruction, erosion, pneumonia, and atelectasis.</li> </ul> <p>It is the important cause of recurrent and persistent pneumonia.</p> <p>B. After admission hyperinflation of left lung developed; expiration pronounced the air-trapping, indicating a foreign body obstruction.</p>	<ul style="list-style-type: none"> <li>• Prompt endoscopic removal with rigid instruments (Bronchoscopy is both diagnostic and therapeutic).</li> <li>• Adequate hydration and empty stomach before bronchoscopy.</li> <li>• Airway foreign bodies are usually removed at the earliest after diagnosis.</li> </ul>

### Foreign Body Right Bronchus


 <p><b>Figure 7.3.4:</b> Foreign body right bronchus <i>Photo Courtesy:</i> Vinod Ratageri, TA Shepur KIMS, Hubli</p>	<p>Right lung collapse with herniation of left upper lobe with compensatory emphysema of right upper lobe.</p>	<ul style="list-style-type: none"> <li>• Prompt endoscopic removal with rigid instruments (Bronchoscopy is both diagnostic and therapeutic).</li> <li>• Adequate hydration and empty stomach before bronchoscopy.</li> <li>• Airway foreign bodies are usually removed at the earliest after diagnosis.</li> </ul>
--	--	--

Picture	Note	Management
<p><b>Pneumothorax</b></p>  <p><b>Figure 7.3.5:</b> Tension pneumothorax—left side Photo Courtesy: Vinod Ratageri, TA Shepur, KIMS, Hubli</p>	<p>Left lung is collapsed with massive pneumothorax. Heart and mediastinum shifted to the right.</p> <p>Pneumothorax is presence of air within the pleural space.</p> <p><i>Types:</i> Primary or secondary and can be spontaneous, traumatic, iatrogenic, or catamenial</p> <p><i>Primary spontaneous:</i> Pneumothorax without trauma or underlying lung disease.</p> <p><i>Secondary spontaneous:</i> Complication of an underlying lung disorder but without trauma.</p>	<ul style="list-style-type: none"> <li>• <i>In emergency:</i> Needle thoracostomy</li> <li>• Conservative management—small to moderate sized pneumothorax</li> <li>• Chest tube drainage—tension or recurrent pneumothorax</li> <li>• Chemical pleurodesis or open thoracotomy—pneumothorax complicating malignancy</li> <li>• Open thoracotomy and plication of blebs, closure of fistula, stripping of the pleura, and basilar pleural abrasion</li> <li>• Video-assisted thoracoscopic surgery.</li> <li>• Treatment of the underlying pulmonary disease.</li> </ul>

### RDS on Ventilator—Tension Pneumothorax


 <p><b>Figure 7.3.6:</b> RDS on ventilator-tension pneumothorax on right side Photo Courtesy: Devaraj Raichur, KIMS, Hubli</p>	<p>The air in pleural space with collapse of right lung with mediastinal shift to the left.</p> <p>Right dome of diaphragm is flattened.</p> <p>High pressure exerted on the open alveoli during an attempt to open/recruit the atelectatic alveoli results in air-leak.</p>	<ul style="list-style-type: none"> <li>• Initial needle drainage followed by intercostal tube drainage of the pneumothorax.</li> <li>• Low mean airway pressure, lower inspiratory time and O<sub>2</sub> help early resolution of the pneumothorax.</li> </ul>
---	--	---

## 7.4 SYNDROME

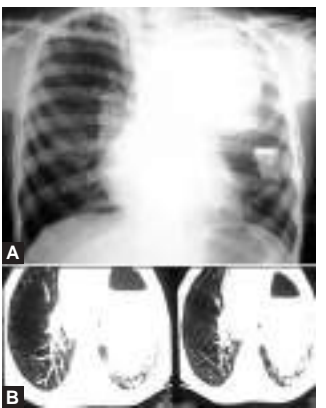
Picture	Note	Management
 <p><b>Figure 7.4.1:</b> Swyer-James MacLeod syndrome (SJMS) Photo Courtesy: KE Elizabeth, GMC, Thiruvananthapuram</p>	<p>This X-ray shows the right lung not growing normally and is slightly smaller than the opposite lung.</p> <p>Diagnostic features are pulmonary hyperlucency, caused by overdistention of the alveoli in conjunction with diminished arterial flow, often a manifestation of postinfectious obliterative bronchiolitis.</p>	<p>No specific treatment is known; it may become less symptomatic with time.</p>





## 7.5 MISCELLANEOUS

### Equipment for Asthma Therapy

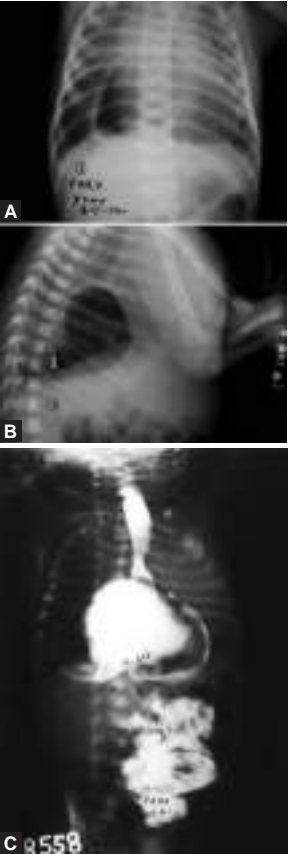
 <p><b>Figure 7.5.1:</b> Some of the equipment used in asthma therapy Photo Courtesy: Devaraj Raichur, KIMS, Hubli</p>	<p>Equipment shown are:</p> <ul style="list-style-type: none"> <li>PEFR-meter (peak-flow-meter)</li> <li>MDIs (metered dose inhalers)</li> <li>DPIs (dry powder inhalers)</li> <li>Breath actuated MDIs</li> <li>Spacer</li> <li>Baby mask.</li> </ul>	<p>With MDIs, use of a spacer device is advisable irrespective of the age for a better drug delivery.</p>
--	--	---

### Hydatid Cyst—X-ray Chest

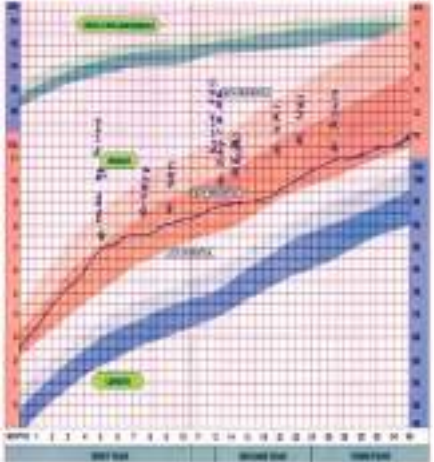
 <p><b>Figures 7.5.2A and B:</b> (A) Hydatid cyst—X-ray chest; (B) Hydatid cyst—CT scan chest Photo Courtesy: NK Kalappanavar, S Kavya, Davangere</p>	<p>This is the chest X-Ray of 8 years old child showing a well defined homogenous opacity in left upper zone suggestive of cystic lesion (Fig. 7.5.2A).</p> <p>A cross section in CT shows intra-parenchymal cyst.</p> <p>On surgery hydatid cyst was confirmed (Fig. 7.5.2B).</p>	<ul style="list-style-type: none"> <li>Albendazole -15 mg/kg/day divided bid PO for 1 to 6 months (28 days on, 14 days off), maximum 800 mg/day. For simple, accessible cysts, ultrasound- or CT-guided percutaneous aspiration, instillation of hypertonic saline or another scolicalidal agent, and reaspiration (PAIR) is the preferred therapy.</li> <li>Surgical removal.</li> </ul>
--	--	---


Picture	Note	Management
<p><b>Nebulizer</b></p>   <p><b>Figures 7.5.3A and B:</b> (A) Nebulizer; (B) Nebulizer-chamber Photo Courtesy: Devaraj Raichur, KIMS, Hubli</p>	<p>Nebulizer shown here is of compressor variety.</p> <p>Other types are:</p> <ul style="list-style-type: none"> <li>• Ultrasonic</li> <li>• Oxygen driven</li> </ul> <p>Nebulizers are used to produce mist out of respirator solutions.</p>	<p>Oxygen 6 to 8 liters/min flow is required or compressed air can be used. In acute conditions, nebulization may be given every 20 min in the first hour; 8 to 10 min per procedure.</p>
<p><b>Equipment for Resuscitation and O<sub>2</sub> Therapy</b></p>   <p><b>Figures 7.5.4A and B:</b> (A) Some of the equipment used in resuscitation and O<sub>2</sub> therapy, (B) Non-rebreathing O<sub>2</sub> mask Photo Courtesy: Devaraj Raichur, KIMS, Hubli</p>	<p>Equipment shown here are:</p> <p>O<sub>2</sub> mask.</p> <p>O<sub>2</sub> hood.</p> <p>Nasal cannula.</p> <p>Oxygen tube.</p> <p>Self inflating manual resuscitator.</p> <p>Facemask.</p> <p>Laryngoscope with straight and curved blades.</p> <p>Endotracheal tubes.</p> <p>Non-rebreathing O<sub>2</sub> mask—is a high-flow oxygen delivery system (Fig. 7.5.4B); by virtue of its valve system, it can deliver nearly 100% O<sub>2</sub>.</p>	<p>While O<sub>2</sub> mask and nasal cannula are low-flow O<sub>2</sub>-delivery systems, others are high-flow systems. In emergencies, high-flow O<sub>2</sub>-delivery systems should be used.</p>



Picture	Note	Management
<p><b>Paraesophageal Hiatus Hernia (PEHH)</b></p>  <p><b>Figures 7.5.5A to C:</b> Paraesophageal hiatus hernia: (A) Plain X-ray; (B) X-ray chest, lateral view with Ryle's tube in the intrathoracic stomach and (C) Barium study</p> <p><i>Photo Courtesy:</i> JK Lakhani, Gadag</p>	<p>(Fig. 7.5.5A) X-ray of a 7-day-old baby with tachypnea since birth, showing stomach in the thorax. The gastroesophageal junction was in the abdomen.</p> <p><i>Hiatus hernia:</i> Herniation of the stomach through the esophageal hiatus. Two types:</p> <ul style="list-style-type: none"> <li>• Sliding hernia—The gastroesophageal junction slides into the thorax</li> <li>• PEHH—Portion of the stomach is insinuated next to the esophagus inside the gastroesophageal junction in the hiatus.</li> <li>• Position of the feeding tube is suggestive of the diagnosis.</li> </ul> <p>(Fig. 7.5.5B) PEHH consists of displacement of stomach into thoracic cavity along side of esophagus, which remains in its normal position without any derangement of gastroesophageal sphincter. PEHH seen at all ages, rarer in children, but rarely presents in the neonatal period.</p> <p>(Fig. 7.5.5C) The upper GI tract contrast study is diagnostic.</p>	<p>Surgical repair with Nissen fundoplication and gastropexy.</p>

### Falling Percentiles: Is it Abnormal?

 <p><b>Figure 7.5.6:</b> Repeated ARIs: Falling percentiles</p> <p><i>Photo Courtesy:</i> S Nagabhushana, Bengaluru</p>	<p>When repeated respiratory infections occur in an otherwise healthy child, the fall in the growth percentiles usually will not be below 80% of the expected for the child.</p>	<p>If the growth percentiles fall below 80% of the expected, one should investigate for other associated problems.</p>
--	--	--

Picture	Note	Management
<p><b>Thymus—Sail Sign</b></p>  <p><b>Figure 7.5.7:</b> Thymus—Sail Sign Photo Courtesy: TU Sukumaran, PIMS, Thiruvalla</p>	<p>Imaging characteristics of normal thymus are:</p> <ul style="list-style-type: none"> <li>• Soft, molds to rib (wave sign of Mulvey)</li> <li>• Does not displace trachea or vessels</li> <li>• Sharp, smooth, slightly convex borders</li> <li>• Homogeneous appearance</li> <li>• Variability in size.</li> </ul> <p>Stress, sickness, and steroids reduce the thymic size.</p> <p>In DiGeorge's syndrome, thymus is absent.</p> <p>On Chest X-ray, thymus is most prominent in infancy; it involutes from 1<sup>st</sup> year of life only, and becomes less prominent in childhood; after puberty, it is usually.</p>	<ul style="list-style-type: none"> <li>• No treatment is necessary; misinterpretation as an abnormal mediastinal mass should be avoided.</li> <li>• During recovery from lymphoma chemotherapy, a shrunken (due to stress) thymus may start enlarging giving a false impression of residual lymphoma or its recurrence.</li> </ul>



## Section 8

---

# Gastrointestinal System and Hepatology

### *Section Editors*

Malathi Sathiyasekaran, A Riyaz

### *Photo Courtesy*

Malathi Sathiyasekaran, A Riyaz, B Sumathi, S Srinivas, VS Sankaranarayanan

---

- 8.1 Common Conditions
- 8.2 Uncommon Conditions but not Rare
- 8.3 GI Emergencies
- 8.4 Syndromes

## SECTION OUTLINE

### 8.1 COMMON CONDITIONS 147

- ◆ Acute Pancreatitis 147
- ◆ Biliary Atresia 147
- ◆ Budd-Chiari Syndrome (BCS) 147
- ◆ Cholestasis with Pruritus 148
- ◆ Clubbing of Fingers 148
- ◆ Corrosive Stricture Esophagus 148
- ◆ Crohn's Disease: Colonic 149
- ◆ Decompensated Liver Disease 149
- ◆ Duodenal Ulcer, *Helicobacter Pylori* Rapid Urease Positive 149
- ◆ Esophageal Varices 150
- ◆ Fissure in Ano 150
- ◆ Foreign Body Stomach 150
- ◆ Gastric Ulcer 151
- ◆ Glycogen Storage Disorder (GSD) 151
- ◆ Gross Thickening and Lichenification of Skin in Low GTP Cholestasis 151
- ◆ Habitual Constipation 152
- ◆ Hirschsprung's Disease 152
- ◆ Ileocolonic Tuberculosis 152
- ◆ Juvenile Polyp (JP): Sigmoid Colon 153
- ◆ Kayser Fleischer (KF) Ring 153
- ◆ Lymphonodular Hyperplasia: Colon 153
- ◆ Malrotation with Midgut Volvulus 154
- ◆ Massive Splenomegaly 154
- ◆ Neonatal Cholestasis Syndrome 154
- ◆ Oral Aphthous Ulcers 155
- ◆ Palmar Erythema 155
- ◆ Pancreatic Calcification 155
- ◆ Perianal Excoriation 156
- ◆ Pseudocyst Pancreas 156
- ◆ Reflux Esophagitis 156
- ◆ Scalloped Duodenal Mucosa 157
- ◆ Scleral Icterus 157
- ◆ Series of Children with EHPVO 157

- ◆ Solitary Rectal Ulcer 158
- ◆ Tense Ascites with Engorged Anterior Abdominal Veins 158
- ◆ Ulcerative Colitis 158
- ◆ US Showing Choledochal Cyst 159
- ◆ US Showing Cholelithiasis 159
- ◆ Villous Atrophy in Celiac Disease 159
- ◆ Vitamin A Deficiency in Cholestasis 160

### 8.2 UNCOMMON CONDITIONS BUT NOT RARE 160

- ◆ Acanthosis Nigricans in Non-Alcoholic Fatty Liver Disease (NALFD) 160
- ◆ Achalasia Cardia 160
- ◆ Acrodermatitis Enteropathica 161
- ◆ Congenital Esophageal Stenosis 161
- ◆ Congenital Hepatic Fibrosis 161
- ◆ Multiple Infantile Hemangioma Liver—CT Angio 162
- ◆ Pseudoaneurysm Communicating with Hematoma and Bile Duct 162
- ◆ Umbilical and Ventral Herniae in Child with Chronic Liver Disease (CLD) 162




### 8.3 GI EMERGENCIES 163




- ◆ Biliary Ascariasis 163
- ◆ Button-Battery Ingestion 163
- ◆ Coagulopathy in Acute Liver Failure 163
- ◆ Food Impaction in Esophagus 164
- ◆ Intussusception 164
- ◆ Scalp Hematoma in Neonatal Cholestasis Syndrome 164
- ◆ Variceal Bleeding 165

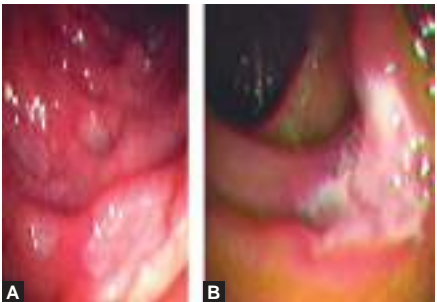


### 8.4 SYNDROMES 165

- ◆ Alagille Syndrome 165
- ◆ Hennekam's Syndrome 165
- ◆ Peutz-Jeghers Syndrome 166
- ◆ Verner-Morrison Syndrome 166
- ◆ Wolman's Syndrome 166

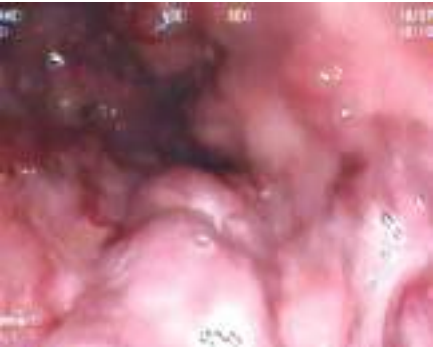


## 8.1 COMMON CONDITIONS




Picture	Note	Management
 <p><b>Figure 8.1.1:</b> CT scan showing edematous pancreas with areas of necrosis Photo Courtesy: Malathi Sathiyasekaran</p>	<p>Acute pancreatitis in children can be due to trauma, infection, biliary causes, drugs, metabolic, pancreas divisum, autoimmune.</p> <p>Elevated amylase and or lipase &gt; 3 UL/N along with ultrasound findings of acute pancreatitis helps in diagnosis. Contrast enhanced computerized tomography (CECT) abdomen is useful to confirm diagnosis and in assessing severity.</p>	<p>Management of acute pancreatitis depends on the severity. The majority are categorized as mild. Severe acute pancreatitis requires intensive care. IV fluids, oxygen and early nutrition help in recovery. Specific therapy is reserved for those with choledochal cyst, CBD stones, biliary ascariasis.</p>
 <p><b>Figures 8.1.2A and B:</b> Biliary atresia/post kasai Photo Courtesy: Malathi Sathiyasekaran</p>	<p>Biliary atresia is an important surgical cause of prolonged cholestasis of infancy. Presents with high colored urine, pale stools and direct hyperbilirubinemia. Infant is initially fairly well preserved. Perioperative cholangiogram with liver biopsy is diagnostic.</p>	<p>Kasai surgery should be done as soon as diagnosis is made preferably before 60 days of age. Biliary cirrhosis with PHT and end stage liver disease occurs in all children who do not undergo surgery or with failed Kasai. Liver transplant is the best option.</p>
 <p><b>Figures 8.1.3A and B:</b> Budd-Chiari syndrome Photo Courtesy: Malathi Sathiyasekaran</p>	<p>Classical BCS is hepatic venous outflow obstruction characterized by involvement of the main hepatic veins with or without IVC obstruction resulting in postsinusoidal portal HT. Massive ascites, prominent anterior abdominal veins and back veins are the clues to diagnosis. Ultrasound and Doppler are useful in detecting site of obstruction.</p>	<p>Definite therapeutic interventional radiology and stenting the site of obstruction is effective. Surgery if shunt is not possible. Prothrombotic causes need to be managed with anticoagulants.</p>


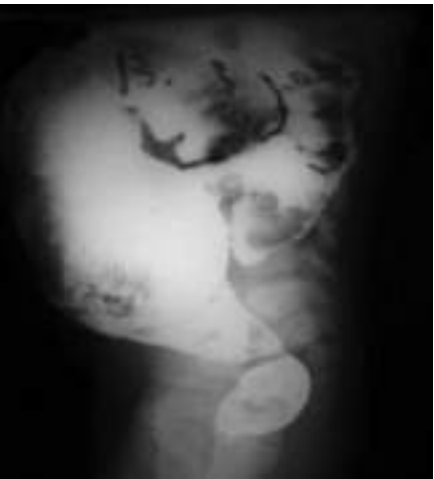

Picture	Note	Management
<p><b>Cholestasis with Pruritus</b></p>  <p><b>Figure 8.1.4:</b> Cholestasis with intense pruritus <i>Photo Courtesy: Malathi Sathiyasekaran</i></p>	<p>Pruritus is an important symptom of chronic cholestasis. Possibly due to deposition of substances normally excreted in bile in skin. Symptoms usually start by the age of 7<sup>th</sup> months. Child is irritable. Elevated direct bilirubin and high alkaline phosphatase (ALP) are the two important biochemical findings.</p>	<ul style="list-style-type: none"> <li>• Control of pruritus may be tried with urso deoxycholic acid, ondansetron, naloxone, rifampicin.</li> <li>• Partial biliary diversion offers relief in some children.</li> <li>• Liver transplant is recommended when itching is intractant.</li> </ul>
<p><b>Clubbing of Fingers</b></p>  <p><b>Figure 8.1.5:</b> Clubbing of fingers <i>Photo Courtesy: Malathi Sathiyasekaran</i></p>	<p>Pan clubbing of fingers is a characteristic feature of chronic liver disease such as cirrhosis. Helps to differentiate acute from acute on chronic liver disease.</p>	<ul style="list-style-type: none"> <li>• No specific treatment for clubbing.</li> <li>• It is seen in chronic liver disease and even regresses after liver transplantation.</li> </ul>
<p><b>Corrosive Stricture Esophagus</b></p>  <p><b>Figure 8.1.6:</b> Corrosive injury esophagus <i>Photo Courtesy: Malathi Sathiyasekaran</i></p>	<p>Accidental corrosive ingestion is the most common yet preventable cause of esophageal stricture. Child presents with GI bleed, chest pain and dysphagia. Both acid and alkali can cause stricture.</p>	<ul style="list-style-type: none"> <li>• Steroids have no role unless there is aerodigestive tract involvement.</li> <li>• Nutritional support is very essential.</li> <li>• Endoscopic dilatation can be started after 6 weeks.</li> </ul>


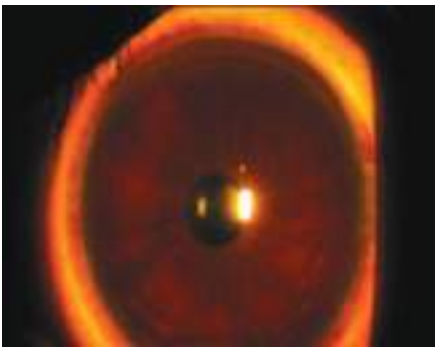
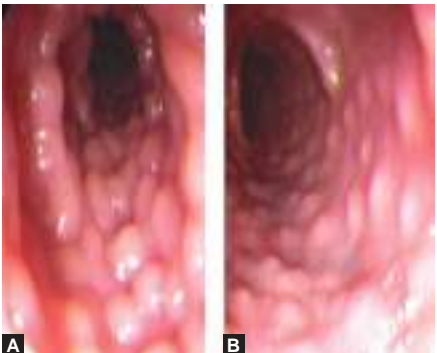
Picture	Note	Management
<p><b>Crohn's Disease: Colonic</b></p>  <p><b>Figures 8.1.7A and B:</b> Irregular ulcers skip lesions Photo Courtesy: Malathi Sathiyasekaran</p>	<p>Crohn's disease is a chronic inflammatory bowel disease involving the GIT from oral cavity to anus with associated extraintestinal manifestations. Presents with bleeding PR, abdominal pain, fever and extraintestinal manifestations. Skip lesions on colonoscopy with transmural ulcers and granuloma on histopathology is diagnostic.</p>	<ul style="list-style-type: none"> <li>• Treatment depends on the site and severity of involvement.</li> <li>• 5-Aminosaticylic acid (ASA), steroids, immunosuppressives are the main medications used in therapy.</li> <li>• Biologic therapy such as infliximab helps in rapid mucosal healing and is useful in fistulae.</li> </ul>
<p><b>Decompensated Liver Disease</b></p>  <p><b>Figure 8.1.8:</b> Cirrhosis liver Photo Courtesy: VS Sankaranarayanan</p>	<p>Decompensated liver disease is characterized by firm liver, ascites pedal edema, splenomegaly and dilated abdominal veins. May be due to HBV, HCV, metabolic, autoimmune or vascular causes.</p> <p>May present with GI bleed, hepatic encephalopathy, resistant ascites, spontaneous bacterial peritonitis, hepatorenal syndrome.</p>	<p>Supportive salt restricted diet. Diuretics, therapeutic paracentesis, Albumin transfusion. Third generation cephalosporins for bacterial peritonitis.</p>
<p><b>Duodenal Ulcer, <i>Helicobacter Pylori</i> Rapid Urease Positive</b></p>  <p><b>Figures 8.1.9A and B:</b> Duodenal ulcer and positive rapid urease test Photo Courtesy: Malathi Sathiyasekaran</p>	<p><i>H. pylori</i> resides in the antral mucosa producing urease which helps in its survival and also in diagnosis. Urease changes the pH of the medium from yellow to pink when urea is converted to ammonia (rapid urease test). <i>H. pylori</i> is classified as class I carcinogen and can cause chronic gastritis, gastric ulcer, duodenal ulcer, maltoma and gastric cancer.</p>	<ul style="list-style-type: none"> <li>• Treatment is recommended with in children with endoscopic changes and showing <i>H. pylori</i> on biopsy.</li> <li>• Triple therapy with PPI and 2 antibiotics amoxicillin and clarithromycin or PPI, amoxicillin with metronidazole twice a day for 10 days.</li> </ul>

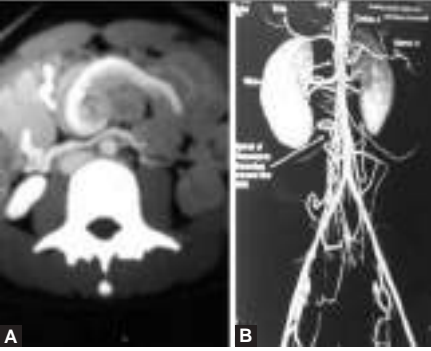




Picture	Note	Management
<b>Esophageal Varices</b>		
 <p data-bbox="164 635 529 682"><b>Figure 8.1.10:</b> Esophageal varices Photo Courtesy: Malathi Sathiyasekaran</p>	<p data-bbox="626 271 1037 333">Esophageal varices is seen in all the three types of Portal HT .</p> <p data-bbox="626 343 1024 404">Endoscopy helps both in diagnosis and therapy.</p> <p data-bbox="626 414 1003 476">Cherry spots, red wale sign, large varices may predict UGI bleed.</p>	<ul data-bbox="1070 271 1468 404" style="list-style-type: none"> <li>• Varices are managed endoscopically.</li> <li>• In presinusoidal PHT surgical shunts may be beneficial.</li> </ul>
<b>Fissure in Ano</b>		
 <p data-bbox="164 1222 529 1269"><b>Figure 8.1.11:</b> Fissure in ano Photo Courtesy: Malathi Sathiyasekaran</p>	<p data-bbox="626 858 1037 981">Fissure in ano is the most common cause of painful defecation and chronic intermittent minor bleed in all age groups.</p> <p data-bbox="626 991 997 1052">Usually is initiated by passage of hard stools.</p> <p data-bbox="626 1062 1003 1124">Multiple fissures in ano may be a sign of sexual abuse.</p>	<ul data-bbox="1070 858 1479 1093" style="list-style-type: none"> <li>• Treatment is primarily to avoid constipation and straining during defecation.</li> <li>• High fiber diet is beneficial.</li> <li>• Short course of antibiotics with analgesic is helpful during the painful episode.</li> </ul>
<b>Foreign Body Stomach</b>		
 <p data-bbox="164 1794 529 1841"><b>Figure 8.1.12:</b> Coin in stomach Photo Courtesy: Malathi Sathiyasekaran</p>	<p data-bbox="626 1430 1037 1492">Coins are the most common foreign bodies swallowed by children.</p> <p data-bbox="626 1502 1037 1563">Coins in the stomach will usually be passed naturally.</p> <p data-bbox="626 1573 1037 1635">If the coin is present for more than 1 week it is unlikely to pass naturally.</p>	<p data-bbox="1070 1430 1468 1522">Coins if need to be removed can be done using FB removing basket or rat tooth forceps.</p>




Picture	Note	Management
<p><b>Gastric Ulcer</b></p>  <p><b>Figure 8.1.13:</b> Endoscopy showing gastric ulcer Photo Courtesy: Malathi Sathiyasekaran</p>	<p>In children gastric ulcer are usually secondary to NSAIDs.</p> <p>They can present with abdominal pain, vomiting or gastrointestinal bleed.</p> <p>Endoscopy helps in diagnosis.</p> <p>Biopsy may be taken for histopathology and for <i>H. pylori</i>.</p>	<ul style="list-style-type: none"> <li>• NSAIDs are stopped and proton pump inhibitors (PPIs) are started.</li> <li>• IV PPIs, if there is a bleed.</li> <li>• Sucralfate also helps in healing of ulcer.</li> </ul>
<p><b>Glycogen Storage Disorder (GSD)</b></p>  <p><b>Figure 8.1.14:</b> Massive hepatomegaly in GSD I Photo Courtesy: A Riyaz</p>	<p>GSD most common metabolic liver disease, AR, due to specific enzyme deficiency resulting in accumulation of glycogen in liver, muscle, heart, kidneys. Type I and III common.</p> <p><i>Features:</i> Doll like facies, massive hepatomegaly, hypoglycemia, voracious appetite, early morning seizures.</p>	<p>Avoid hypoglycemia. Encourage day and night feeds. Uncooked corn starch 1 to 2 gm/kg 4 to 5 times/day. Avoid simple sugars.</p>
<p><b>Gross Thickening and Lichenification of Skin in Low GTP Cholestasis</b></p>  <p><b>Figure 8.1.15:</b> Gross thickening of skin Photo Courtesy: Malathi Sathiyasekaran</p>	<p>Gross thickening and lichenification of the skin is a feature seen in cholestasis with low glutamyl transpeptidase (GTP) cholestasis especially progressive familial intrahepatic cholestasis (PFIC) 1 and 2.</p> <p>Low GTP is the clue to the diagnosis. Liver disease is progressive. PFIC 1 is associated with additional pancreatic and intestinal involvement.</p>	<ul style="list-style-type: none"> <li>• Partial biliary diversion relieves itching to some extent.</li> <li>• The dermatological findings also improve with surgery.</li> </ul>




Picture	Note	Management
<b>Habitual Constipation</b>		
 <p data-bbox="164 641 561 717"><b>Figure 8.1.16:</b> BE showing features of habit constipation <i>Photo Courtesy:</i> B Sumathi</p>	<p data-bbox="626 271 1040 621">Habitual or functional constipation is the most common cause of chronic constipation. A vicious cycle is triggered by a painful defecation, voluntary withholding of stools, retention in rectum, megarectum, painful stretch of anal canal and further retention. Barium enema shows dilated colon up to anal verge. Rectoanal inhibitory reflex (RAIR) is present.</p>	<ul data-bbox="1070 271 1484 574" style="list-style-type: none"> <li>• Effective therapy is a combination of bowel training, dietary changes and medication with stool softeners and laxatives.</li> <li>• Parents should be patient and understand that therapy may be prolonged.</li> <li>• Polyethylene glycol and lactulose are two very effective drugs.</li> </ul>
<b>Hirschsprung's Disease</b>		
 <p data-bbox="164 1326 586 1402"><b>Figure 8.1.17:</b> BE showing the transition zone with proximal dilatation <i>Photo Courtesy:</i> B Sumathi</p>	<p data-bbox="626 833 1019 989">Hirschsprung's disease is a congenital disorder of intestinal aganglionosis due to arrested fetal development of the myenteric nervous system.</p> <p data-bbox="626 1003 1040 1158">Presents with delay in the passage of meconium and constipation. There is no voluntary withholding or fecal soiling which is a feature of habit constipation.</p>	<p data-bbox="1070 833 1459 864">Surgery is the treatment of choice.</p>
<b>Ileocolonic Tuberculosis</b>		
 <p data-bbox="164 1806 570 1882"><b>Figures 8.1.18A and B:</b> Ileocolonic irregular ulcers on colonoscopy <i>Photo Courtesy:</i> Malathi Sathiyasekaran</p>	<p data-bbox="626 1514 1040 1831">Abdominal tuberculosis has various forms of presentations. Luminal tuberculosis presents as diarrhea, bleeding PR or obstruction. Ileum is the most common site of involvement. Biopsy of the lesions identified during colonoscopy helps in diagnosis. Presence of caseating granuloma with AFB is confirmatory.</p>	<ul data-bbox="1070 1514 1484 1712" style="list-style-type: none"> <li>• Anti TB treatment with 4 drugs R/H/E/Z for 2 months followed by RH for 5 to 7 months is the recommendation.</li> <li>• Surgery is offered only for those with stricture and obstruction.</li> </ul>

Picture	Note	Management
<p><b>Juvenile Polyp (JP): Sigmoid Colon</b></p>  <p><b>Figure 8.1.19:</b> Cherry red polyp Photo Courtesy: S Srinivas</p>	<p>Juvenile polyp is a common cause of bleeding per rectum in children. JPs are cherry red, smooth pedunculated hamartomatous polyps usually seen in the rectum. Single polyps do not have a malignant potential.</p>	<ul style="list-style-type: none"> <li>• Treatment is by polypectomy using a diathermy snare and electro-surgical unit connected to a colonoscope.</li> <li>• Polyp should be retrieved for HPE.</li> <li>• When there are multiple polyps child needs surveillance since juvenile polyposis coli has a malignant potential but less than familial adenomatous polyposis.</li> </ul>
<p><b>Kayser Fleicher (KF) Ring</b></p>  <p><b>Figure 8.1.20:</b> Slit lamp showing KF ring Photo Courtesy: Malathi Sathiyasekaran</p>	<p>KF ring is a pigmented sclero corneal ring seen in Wilson's disease. WD is an inherited disorder of Cu metabolism with accumulation of copper in various tissues. Phenotypes: hepatic, neurological or mixed. Low ceruloplasmin, KF ring and high urine copper help in diagnosis.</p>	<ul style="list-style-type: none"> <li>• <i>Diet:</i> Avoid copper containing food like nuts, chocolates, shell fish. Chelation is done with D penicillamine, trientine.</li> <li>• Oral Zinc is prescribed along with penicillamine as metallothionein. Liver transplant is recommended in acute liver failure.</li> </ul>
<p><b>Lymphonodular Hyperplasia: Colon</b></p>  <p><b>Figures 8.1.21A and B:</b> Lymphonodular hyperplasia colon Photo Courtesy: Malathi Sathiyasekaran</p>	<p>Lymphonodular hyperplasia is a common finding in children and may be a manifestation of cow's milk protein allergy. On endoscopy they appear as small sago like granules or nodules with a central dot. May present with bleeding PR. Biopsy shows lymphoid aggregates. If eosinophilic colitis is present a diagnosis of Cow's milk protein allergy (CMPA) may be considered.</p>	<ul style="list-style-type: none"> <li>• If CMPA is diagnosed all animal milk protein in the form of milk and milk products is avoided till the age of 1 year.</li> <li>• Majority will be able to tolerate milk protein after the age of 1 year. In some it may take 3 years for recovery.</li> </ul>




Picture	Note	Management
<b>Malrotation with Midgut Volvulus</b>		
 <p><b>Figures 8.1.22A and B:</b> CT with whirlpool sign Photo Courtesy: Malathi Sathiyasekaran</p>	<p>Malrotation of gut is a common rotational congenital anomaly of the gut seen in children. When it occurs with midgut volvulus the characteristic “whirlpool sign” formed by the SMV along with the mesentery wrapping around the SMA in a clock wise pattern is seen. Presents as abdominal pain and bilious vomiting.</p>	<p>Surgery is the only treatment once diagnosed.</p>
<b>Massive Splenomegaly</b>		
 <p><b>Figures 8.1.23:</b> Massive splenomegaly Photo Courtesy: B Sumathi</p>	<p>Massive splenomegaly could be due to tropical splenomegaly syndrome, Kala-azar, HIV, presinusoidal portal hypertension, hemolytic anemia, Juvenile myeloid leukemia, hairy cell leukemia, Gaucher’s disease, Niemann Pick disease and tumours of spleen. CBC, Peripheral smear, Bone marrow, UGIE and US of abdomen help in diagnosis.</p>	<ul style="list-style-type: none"> <li>• Biopsy and histopathology of the scalloped mucosa will reveal the degree of villous atrophy.</li> <li>• Management depends on the underlying disease.</li> <li>• Treat the underlying cause. Splenectomy indicated only if there is hypersplenism, tumors or SOL of spleen.</li> </ul>
<b>Neonatal Cholestasis Syndrome</b>		
 <p><b>Figures 8.1.24A and B:</b> Infants with NCS pale stools and high colored urine Photo Courtesy: A Riyaz</p>	<p>Neonatal cholestasis syndrome (NCS) is a heterogenous disorder characterized by high colored urine, pale stools and direct hyperbilirubinemia.</p> <p>Sixty percent of NCS are due to intrahepatic causes which could be idiopathic, infective, metabolic, chromosomal, endocrine or anatomical.</p>	<ul style="list-style-type: none"> <li>• Awareness to recognize infants with high colored urine and direct bilirubin more than 20% of total is very crucial.</li> <li>• BA should be identified and referred to surgeon at the earliest. Treatable causes of NCS should be identified and managed appropriately.</li> </ul>



Picture	Note	Management
<p><b>Oral Aphthous Ulcers</b></p>  <p><b>Figure 8.1.25:</b> Aphthous ulcers Photo Courtesy: VS Sankaranarayanan</p>	<p>Recurrent aphthous ulcers is usually idiopathic however it may be an extraintestinal manifestation of Crohn's disease. Various theories including <i>H. pylori</i> have been implicated in its etiopathogenesis. These ulcers are discrete, punched out may be single or multiple and painful.</p>	<ul style="list-style-type: none"> <li>• Local application of anesthetic gel.</li> <li>• Gargling with antibiotics, administration of probiotics and anti <i>H. pylori</i> therapy have all been tried for the recurrent aphthous ulcers without any identifiable cause.</li> </ul>
<p><b>Palmar Erythema</b></p>  <p><b>Figure 8.1.26:</b> Palmar erythema Photo Courtesy: Malathi Sathiyasekaran</p>	<p>Palmar erythema or liver palms is an important stigmata of chronic liver disease.</p> <p>Palms are warm with bright red color over the thenar, hypothenar prominences and pulp of fingers.</p>	<ul style="list-style-type: none"> <li>• No specific treatment is necessary for the liver palms.</li> <li>• It helps in suspecting chronic liver disease.</li> </ul>
<p><b>Pancreatic Calcification</b></p>  <p><b>Figure 8.1.27:</b> Pancreatic calcification Photo Courtesy: Malathi Sathiyasekaran</p>	<p>Chronic calcific pancreatitis (CCP) may be due to tropical, hereditary or idiopathic pancreatitis.</p> <p>Stones may be intraductal or acinar.</p> <p>Abdominal pain, diabetes and steatorrhea are the main features of CCP.</p> <p>Complications such as pancreatic ascites and pseudocyst are common.</p>	<ul style="list-style-type: none"> <li>• Pain due to pancreatic stone may be managed with endotherapy.</li> <li>• Extracorporeal short wave lithotripsy (ESWL) followed by stone removal is recommended for large intraductal stones.</li> </ul>


Picture	Note	Management
<b>Perianal Excoriation</b>		
	<p>Perianal excoriation in infants is due to the frequent passage of acidic stools as seen in lactose intolerance.</p> <p>Congenital lactose intolerance is very rare. Transient and secondary lactose intolerance are common.</p> <p>Low pH, positive reducing substance in stools is diagnostic.</p>	<ul style="list-style-type: none"> <li>• Infants on exclusive breast milk should be supervised and hind milk given.</li> <li>• Those on artificial feeds may be switched over to low or non-lactose formulae.</li> </ul>
<p><b>Figure 8.1.28:</b> Severe perianal excoriation  <i>Photo Courtesy:</i> Malathi Sathiyasekaran</p>		
<b>Pseudocyst Pancreas</b>		
	<p>Pseudocyst of the pancreas is usually a local sequel of acute or chronic pancreatitis. These cysts consist of fluid collections in the lesser sac of the peritoneum or anywhere in the vicinity of the pancreas.</p> <p>Presents as pain, mass, jaundice and vomiting. Infection, hemorrhage and rupture are common complications of pseudocyst.</p>	<p>Therapeutic intervention can be either endoscopic or surgical depending on the position and relation to surrounding vessels.</p>
<p><b>Figure 8.1.29:</b> CT scan: Pseudocyst of pancreas  <i>Photo Courtesy:</i> Malathi Sathiyasekaran</p>		
<b>Reflux Esophagitis</b>		
	<p>Gastroesophageal reflux is physiological whereas gastroesophageal reflux disease (GERD) is pathological and manifests either with esophageal or extraesophageal symptoms such as asthma, recurrent cough. Endoscopy helps in differentiating erosive from nonerosive esophagitis.</p>	<ul style="list-style-type: none"> <li>• Proton pump inhibitors are very useful in controlling the symptoms of reflux disease.</li> <li>• Fundoplication is reserved for those who do not respond to medical therapy.</li> </ul>
<p><b>Figure 8.1.30:</b> Endoscopy showing grade A erosive esophagitis  <i>Photo Courtesy:</i> Malathi Sathiyasekaran</p>		

Picture	Note	Management
<p><b>Scalloped Duodenal Mucosa</b></p>  <p><b>Figure 8.1.31:</b> Scalloped duodenal mucosa Photo Courtesy: Malathi Sathiyasekaran</p>	<p>Scalloping of duodenal mucosa seen on endoscopy indicates villous atrophy.</p> <p>The most common cause of villous atrophy in India is celiac disease. Other causes of scalloping are tropical enteropathy, malnutrition and parasitic infestations.</p>	<ul style="list-style-type: none"> <li>• Biopsy and histopathology of the scalloped mucosa will reveal the degree of villous atrophy.</li> <li>• Management depends on the underlying disease.</li> </ul>
<p><b>Scleral Icterus</b></p>  <p><b>Figure 8.1.32:</b> Jaundice/scleral icterus Photo Courtesy: Malathi Sathiyasekaran</p>	<p>Jaundice is a symptom which can be due to a hemolytic, hepatic or obstructive cause. Most common cause of jaundice is viral hepatitis usually due to hepatitis A, E and B virus. Presence of urine bile salts, bile pigments, elevated serum bilirubin and transaminases is diagnostic of hepatitis.</p>	<p>Acute viral hepatitis requires only supportive treatment. In the presence of atypical features. Nonviral hepatitis such as typhoid hepatitis, malaria, leptospirosis should be excluded and specific treatment given.</p>
<p><b>Series of Children with EHPVO</b></p>  <p><b>Figure 8.1.33:</b> EHPVO: isolated splenomegaly, no pedal edema, no ascites or abdominal veins Photo Courtesy: Malathi Sathiyasekaran</p>	<p>Extrahepatic portal venous obstruction (EHPVO) is the most common cause of portal hypertension in India. Presents with major GI bleed and splenomegaly. Ascites, pedal edema and abdominal veins are usually not present. Upper gastrointestinal endoscopy (UGIE) and US diagnostic.</p>	<ul style="list-style-type: none"> <li>• Endoscopic management of variceal bleed and surgical correction with shunts when feasible is recommended.</li> <li>• Portal biliopathy a late complication is managed with ERCP or surgery.</li> </ul>




Picture	Note	Management
<p><b>Solitary Rectal Ulcer</b></p>  <p><b>Figure 8.1.34:</b> Solitary rectal ulcer <i>Photo Courtesy:</i> Malathi Sathiyasekaran</p>	<p>Solitary rectal ulcer syndrome is a defecation disorder characterized by mucorrhea, bleeding PR and straining during defecation. SRUS need not be single or in the rectum or simulate an ulcer on colonoscopy. Histopathology examination (HPE) shows fibromuscular obliteration of lamina propria.</p>	<ul style="list-style-type: none"> <li>• Bowel training, avoiding constipation, high fiber diet and bio feed therapy help in controlling symptoms.</li> <li>• 5-ASA, topical sucralfate, laser have all been tried. Surgery is reserved for those with major bleed not amenable to medical therapy.</li> </ul>
<p><b>Tense Ascites with Engorged Anterior Abdominal Veins</b></p>  <p><b>Figure 8.1.35:</b> Tense ascites <i>Photo Courtesy:</i> B Sumathi</p>	<p>Ascites or free fluid in the peritoneal cavity could occur secondary to cirrhosis, renal disease, congestive cardiac failure, peritoneal pathology or as pancreatic ascites.</p> <p>Diagnostic paracentesis and estimation of cells, protein, serum ascites albumin gradient (SAAG), adenosine deaminase helps in diagnosis.</p>	<ul style="list-style-type: none"> <li>• Ascites secondary to chronic liver disease is managed with fluid and salt restriction.</li> <li>• Diuretics spironolactone with or without frusemide.</li> <li>• Large volume paracentesis with albumin replacement 6 gm/L of fluid removed.</li> <li>• Transjugular intrahepatic porto systemic shunt is recommended when medical treatment fails.</li> </ul>
<p><b>Ulcerative Colitis</b></p>  <p><b>Figure 8.1.36:</b> Colitis on colonoscopy <i>Photo Courtesy:</i> Malathi Sathiyasekaran</p>	<p>Ulcerative colitis is a form of inflammatory bowel disease (IBD) seen in children though less common than in adults. Presents as bleeding PR, diarrhea, fever, abdominal pain characterized by continuous inflammation of colon but restricted to mucosa and submucosa with areas of erythema, ulcers and easy contact bleed. Histopathological examination (HPE) shows cryptitis and crypt abscess.</p>	<ul style="list-style-type: none"> <li>• Treatment depends on the site and severity of involvement.</li> <li>• ASA, steroids and immunosuppressives constitute the backbone of treatment.</li> <li>• Total colectomy is reserved for patients with toxic megacolon or severe bleeding.</li> </ul>

Picture	Note	Management
<p><b>US Showing Choledochal Cyst</b></p>  <p><b>Figure 8.1.37:</b> US showing choledochal cyst Photo Courtesy: Malathi Sathiyasekaran</p>	<p>Choledochal cyst (CC) is a congenital dilatation of the common bile duct with or without dilatation of the intrahepatic radicles. The most common is type I which is a spherical cystic dilatation of the common bile duct (CBD) distal to cystic duct. Jaundice, mass, abdominal pain is a common triad. CC is a premalignant lesion.</p>	<p>Since choledochal cyst is 100% premalignant surgery is the only option except in type III (choledochocele) which can be managed with therapeutic ERCP.</p>
<p><b>US Showing Cholelithiasis</b></p>  <p><b>Figure 8.1.38:</b> US showing gallstones Photo Courtesy: Malathi Sathiyasekaran</p>	<p>Gallstones (GS) in children are less common than in adults. They are usually pigment stones. The etiology may be idiopathic, familial, hemolytic, metabolic or secondary to liver disease. In the majority the stones are incidental finding. Child is asymptomatic or presents with pain, jaundice, cholangitis or pancreatitis.</p>	<p>Medical dissolution is not effective in pediatric pigment GS. Ursodeoxycholic can be given for dissolution of sludge, cholesterol stones and microlithiasis. Cholecystectomy is recommended only for symptomatic children or those with underlying hemolysis, large stones and contracted gall bladder.</p>
<p><b>Villous Atrophy in Celiac Disease</b></p>  <p><b>Figure 8.1.39:</b> Villous atrophy duodenal mucosa Photo Courtesy: Malathi Sathiyasekaran</p>	<p>In villous atrophy the normal long, elongated leaf like villi are replaced by blunt and flat mucosa. Villous atrophy on histopathology and presence of tissue transglutaminase antibody is diagnostic of celiac disease.</p>	<ul style="list-style-type: none"> <li>• Lifelong gluten-free diet (GFD) is the principle in management.</li> <li>• Child has to avoid foods containing wheat, rye and barley.</li> <li>• Children on GFD do well and the villi return to normal morphology.</li> </ul>


Picture	Note	Management
<b>Vitamin A Deficiency in Cholestasis</b>		
	<p>Fat soluble vitamins A, D, E and K need bile salts for absorption. Hence in cholestasis these deficiencies are prone to occur. Child may present with nyctalopia, rickets and coagulopathy.</p>	<ul style="list-style-type: none"> <li>• Parenteral vitamin A should be given at regular intervals to prevent night blindness.</li> <li>• In addition child should be administered vitamin D, E and K regularly.</li> </ul>
<p><b>Figure 8.1.40:</b> Bitot's spots <i>Photo Courtesy: A Riyaz</i></p>		




## 8.2 UNCOMMON CONDITIONS BUT NOT RARE

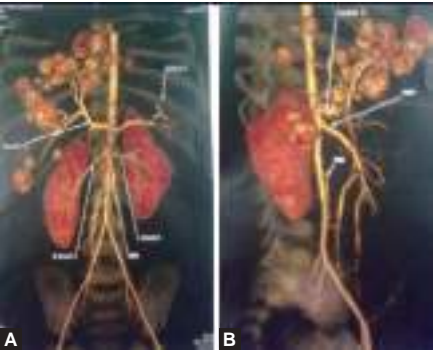


### Acanthosis Nigricans in Non-Alcoholic Fatty Liver Disease (NAFLD)

	<p>Non-alcoholic fatty liver disease occurs in 3 to 10% of obese children. Spectrum of NAFLD includes steatosis to steatohepatitis. It is the second most common cause of liver disease in adults. Acanthosis nigricans is a marker of insulin resistance which is an associated feature in NAFLD.</p>	<ul style="list-style-type: none"> <li>• Reducing weight is the best form of therapy.</li> <li>• Regular physical exercise has been reported as most rewarding.</li> </ul>
<p><b>Figure 8.2.1:</b> Acanthosis nigricans <i>Photo Courtesy: Malathi Sathiyasekaran</i></p>		

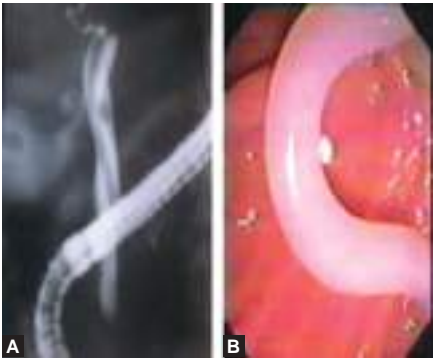
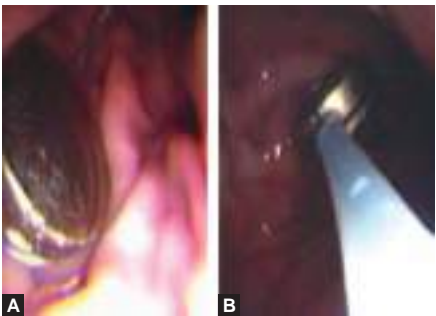

### Achalasia Cardia


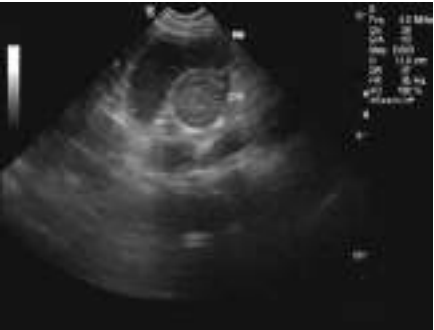

	<p>Achalasia cardia is the most recognized esophageal motility disorder. Dysphagia both for solids and liquids, aspiration, recurrent vomiting are common symptoms. Esophageal manometry documents the characteristic finding of failure of LES to relax and absence of peristalsis in body of esophagus.</p>	<ul style="list-style-type: none"> <li>• Pneumatic dilatation or Heller's surgery offer good results.</li> <li>• Oral nifedipine and botulinum toxin injection give variable results.</li> </ul>
<p><b>Figure 8.2.2:</b> BS showing achalasia cardia <i>Photo Courtesy: Malathi Sathiyasekaran</i></p>		

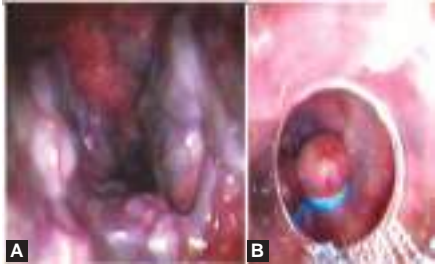
Picture	Note	Management
<p data-bbox="126 212 529 247"><b>Acrodermatitis Enteropathica</b></p>  <p data-bbox="138 527 505 609"><b>Figures 8.2.3A and B:</b> Acrodermatitis enteropathica Photo Courtesy: Malathi Sathiyasekaran</p>	<p data-bbox="602 271 969 363">Acrodermatitis enteropathica is an AR inherited disorder of zinc metabolism.</p> <p data-bbox="602 376 1019 437">Defect is in chromosome <i>8q24.3</i> due to Zip 4 metallotransfers.</p> <p data-bbox="602 449 941 541">Presents as acro-orofacial and genital ulcers, alopecia and diarrhea.</p>	<p data-bbox="1045 271 1409 333">Excellent response with lifelong treatment with oral zinc.</p>
<p data-bbox="126 727 552 762"><b>Congenital Esophageal Stenosis</b></p>  <p data-bbox="138 1195 505 1275"><b>Figure 8.2.4:</b> Endoscopy showing esophageal stenosis Photo Courtesy: Malathi Sathiyasekaran</p>	<p data-bbox="602 786 980 1103">Congenital esophageal stenosis (CES) is an important cause of recurrent vomiting in infants. The stenosis can be in the mid or lower esophagus. Bronchial elements may be present in the wall of the esophagus at the site of stenosis. Usually presents with dysphagia, choking, vomiting and food impaction.</p>	<ul data-bbox="1045 786 1437 919" style="list-style-type: none"> <li>• CES respond well to endoscopic dilatation.</li> <li>• The lesions at the lower end of esophagus may require surgery.</li> </ul>
<p data-bbox="126 1385 498 1420"><b>Congenital Hepatic Fibrosis</b></p>  <p data-bbox="138 1800 524 1882"><b>Figures 8.2.5A and B:</b> Congenital hepatic fibrosis Photo Courtesy: Malathi Sathiyasekaran</p>	<p data-bbox="602 1447 1003 1635">Congenital hepatic fibrosis (CHF) is classified under fibropolycystic disease of liver and is due to ductal plate malformations. It is usually associated with cystic disease of kidneys.</p> <p data-bbox="602 1647 1013 1835">CHF is classically an intrahepatic presinusoidal HT and presents with enlargement of left lobe of liver, splenomegaly and GI bleed. Liver Bx shows bands of fibrosis with abnormal bile ducts.</p>	<ul data-bbox="1045 1447 1458 1610" style="list-style-type: none"> <li>• PHT presenting as varices is managed medically and endoscopically.</li> <li>• The definite treatment would be liver and kidney transplant.</li> </ul>

Picture	Note	Management
<p data-bbox="154 212 797 247"><b>Multiple Infantile Hemangioma Liver—CT Angio</b></p>  <p data-bbox="164 641 537 717"><b>Figures 8.2.6A and B:</b> CT angio showing multiple hemangioma Photo Courtesy: Malathi Sathiyasekaran</p>	<p data-bbox="630 275 1036 400">Infantile hemangioendothelioma is the most common benign tumor of infancy. The majority present before 6 months of age.</p> <p data-bbox="630 412 1040 537">Presents with abdominal distension, mass, anemia, CCF, fever, jaundice, thrombocytopenia and loss of weight.</p> <p data-bbox="630 549 959 576">US, CT, MR help in diagnosis.</p>	<ul data-bbox="1073 275 1484 568" style="list-style-type: none"> <li>• Treatment depends upon the extent of symptoms. Medical management with diuretics, steroid and interferon have been reported. Surgery is advised when resectable and CCF is a presentation.</li> <li>• Arterial embolization and OLT are other options.</li> </ul>
<p data-bbox="154 854 1011 889"><b>Pseudoaneurysm Communicating with Hematoma and Bile Duct</b></p>  <p data-bbox="164 1228 553 1304"><b>Figure 8.2.7:</b> US doppler showing pseudoaneurysm of Hepatic Artery Photo Courtesy: Malathi Sathiyasekaran</p>	<p data-bbox="630 915 1003 1007">Hematuria can occur following injury or procedures such as liver aspiration or biopsy.</p> <p data-bbox="630 1019 1029 1175">Presents with GI bleed, abdominal pain and jaundice. A pseudoaneurysm communicating with a cavity as well as a bile duct is seen on Doppler US.</p>	<ul data-bbox="1073 915 1484 1181" style="list-style-type: none"> <li>• Treatment depends upon the extent of symptoms. Medical management with diuretics, steroid and interferon have been reported.</li> <li>• Surgery is advised when resectable and CCF is a presentation.</li> <li>• Arterial embolization and OLT are other options.</li> </ul>
<p data-bbox="154 1426 1114 1461"><b>Umbilical and Ventral Herniae in Child with Chronic Liver Disease (CLD)</b></p>  <p data-bbox="164 1827 516 1882"><b>Figure 8.2.8:</b> Large umbilical hernia Photo Courtesy: VS Sankaranarayanan</p>	<p data-bbox="630 1488 1040 1643">Umbilical hernia is frequent in newborns and specially preterms. They may reach significant dimensions with omentum or bowel loop as contents.</p> <p data-bbox="630 1655 987 1747">In the presence of tense ascites, these hernia cause additional problems.</p>	<p data-bbox="1073 1488 1468 1774">Majority of congenital umbilical hernia close and do not require surgical intervention. If complications occur and hernia do not close by the 3<sup>rd</sup> year surgery is essential. If ascites is present diuretics, therapeutic paracentesis with albumin replacement is advised.</p>

### 8.3 GI EMERGENCIES


Picture	Note	Management
<p><b>Biliary Ascariasis</b></p>  <p><b>Figures 8.3.1A and B:</b> Biliary ascariasis Photo Courtesy: Malathi Sathiyasekaran</p>	<p>Biliary ascariasis is a common complication of roundworm infestation. Child presents with features of cholangitis and severe abdominal pain.</p> <p>US shows the radiolucent tubular shadow in the CBD. Endoscopy may reveal the worms in the duodenum.</p>	<ul style="list-style-type: none"> <li>• Deworming is advised.</li> <li>• Therapeutic endoscopic retrograde cholangiopancreatography (ERCP) helps in removal of the worm from the CBD.</li> <li>• Sphincterotomy with stent placement helps in clearing the biliary system.</li> </ul>
<p><b>Button-Battery Ingestion</b></p>  <p><b>Figures 8.3.2A and B:</b> Button-battery in stomach endotherapy Photo Courtesy: Malathi Sathiyasekaran</p>	<p>Button-battery if swallowed can cause complications depending on the site of impaction and status of battery. The contents are alkaline and they discharge current and cause burns and perforation specially if impacted in the esophagus. In the stomach batteries discharge current into gastric fluid without damaging gastric mucosa.</p>	<ul style="list-style-type: none"> <li>• Button batteries if present in the esophagus should be removed as soon as possible.</li> <li>• In the stomach these batteries if not passed out within 24 hours or do not have a clear double rim on X-ray need to be removed endoscopically.</li> </ul>
<p><b>Coagulopathy in Acute Liver Failure</b></p>  <p><b>Figure 8.3.3:</b> Skin bleeds sign of coagulopathy in ALF Photo Courtesy: Malathi Sathiyasekaran</p>	<p>Acute liver failure (ALF) is a dreaded complication of acute liver injury requiring intensive care.</p> <p>Prolonged prothrombin time is the hallmark sign of ALF.</p> <p>Child may present with GI bleeds or bleed from other sites including IV access sites.</p>	<p>If international normalized ratio (INR) is more than 1.5 fresh frozen plasma should be given in the presence of overt bleed.</p> <p>If there is no improvement with fresh frozen plasma (FFP) recombinant activated factor VII may be required.</p>

Picture	Note	Management
<b>Food Impaction in Esophagus</b>		
 <p data-bbox="164 568 597 649"><b>Figures 8.3.4A and B:</b> Impaction of 'bengal gram' in esophageal stenosis <i>Photo Courtesy: Malathi Sathiyasekaran</i></p>	<p data-bbox="626 273 1037 594">Impaction of food in esophagus can occur in young children and requires immediate removal. Child presents with acute dysphagia, vomiting and drooling of saliva. Congenital stenosis, stricture and eosinophilic esophagitis may present with food impaction. Emergency endoscopy is both therapeutic and diagnostic.</p>	<ul data-bbox="1070 273 1482 437" style="list-style-type: none"> <li>• Endoscopic removal of food bolus offers immediate relief.</li> <li>• Underlying stenosis if present is dilated at the same sitting to avoid recurrence of impaction.</li> </ul>
<b>Intussusception</b>		
 <p data-bbox="164 1187 597 1242"><b>Figure 8.3.5:</b> US showing "donut sign" <i>Photo Courtesy: Malathi Sathiyasekaran</i></p>	<p data-bbox="626 846 1037 1116">Intussusception is a common GI emergency in young children. Presents with severe abdominal colic, incessant cry and bleeding PR (currant jelly).  Palpation of a mass with donut or target sign on US confirms the diagnosis.</p>	<ul data-bbox="1070 846 1482 1116" style="list-style-type: none"> <li>• Infants less than 1 year of age usually do not have a lead point and do well with pneumatic reduction.</li> <li>• Surgery is reserved for those with recurrence and those with underlying lesions such as tumors, Meckel's or polyps.</li> </ul>
<b>Scalp Hematoma in Neonatal Cholestasis Syndrome</b>		
 <p data-bbox="164 1821 597 1872"><b>Figure 8.3.6:</b> Hematoma scalp <i>Photo Courtesy: A Riyaz</i></p>	<p data-bbox="626 1443 1037 1733">Infants with neonatal cholestasis syndrome may present to the emergency room with incessant cry and seizures. Coagulopathy secondary to vitamin K deficiency may be missed. Scalp hematoma and intracranial hemorrhage may occur in these infants requiring prompt management.</p>	<p data-bbox="1070 1443 1482 1606">Prevention of these catastrophic incidents is by administering injection vitamin K<sub>3</sub> doses as soon as a diagnosis of cholestasis is made.</p>


Picture	Note	Management
<p><b>Variceal Bleeding</b></p>  <p><b>Figures 8.3.7A and B:</b> Grade III varices banding Photo Courtesy: Malathi Sathiyasekaran</p>	<p>Major gastrointestinal bleed is an important GI emergency.</p> <p>In children majority of major upper gastrointestinal (UGI) bleeds are variceal.</p> <p>Bleed is unprovoked with bright red blood and large clots.</p> <p>UGI endoscopy aids diagnosis and therapy.</p>	<ul style="list-style-type: none"> <li>• Endotherapy is the accepted management of variceal bleed.</li> <li>• Variceal banding is feasible in children less than 2 years of age.</li> <li>• Endoscopic sclerotherapy is preferred for young infants.</li> </ul>

## 8.4 SYNDROMES


### Alagille Syndrome

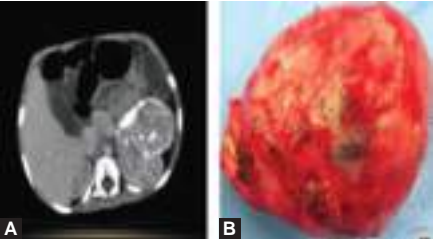
 <p><b>Figures 8.4.1A and B:</b> Alagille Syndrome Age 6 months and 9 years Photo Courtesy: Malathi Sathiyasekaran</p>	<p>Alagille syndrome is an autosomal dominant disorder of cholestasis with defect in chromosome <i>20p JAG 1</i> gene. The main feature being paucity of interlobular bile ducts. The characteristic triangular facies, pulmonary branch stenosis, butterfly vertebra, posterior embryotoxon with ductopenia on HPE is diagnostic.</p>	<p>Supportive management of cholestasis specially the disturbing pruritus. Liver transplant is beneficial if cardiac and renal abnormalities are minor.</p>
--	--	---


### Hennekam's Syndrome

 <p><b>Figures 8.4.2A and B:</b> Facial asymmetry with intestinal lymphangiectasia Photo Courtesy: Malathi Sathiyasekaran</p>	<p>Hennekam's syndrome is a rare AR disorder due to mutation in CCBE1 gene (collagen and calcium binding EGF domain containing protein1). It comprises of intestinal lymphangiectasia, facial anomalies, peripheral lymphedema and mental retardation.</p>	<p>Treatment is only supportive diet should be MCT-based. Regular albumin transfusions may be necessary to treat the hypoalbuminemia.</p>
--	--	---



Picture	Note	Management
<b>Peutz-Jeghers Syndrome</b>		
	<p>Peutz-Jeghers (PJ) syndrome is an autosomal dominant polyposis syndrome. Mucocutaneous pigmentation and hamartomatous polyps are seen through out GIT. Bleeding PR with intussusception is a common presentation. High incidence of GI and non GI malignancies.</p>	<ul style="list-style-type: none"> <li>• Polypectomy of lesions within the reach of the scope.</li> <li>• Operative enteroscopy and polypectomy of small bowel polyps is also an option.</li> </ul>
<p><b>Figures 8.4.3A and B:</b> Trilobed polyp and mucosal pigmentation  <i>Photo Courtesy:</i> Malathi Sathiyasekaran</p>		

<b>Verner-Morrison Syndrome</b>		
	<p>Verner-Morrison syndrome or VIPoma or Watery diarrhea, hypokalemia, achlorhydria syndrome is a rare cause of watery diarrhea in children due to increased secretion of vasoactive intestinal peptide. VIP is secreted by tumors of the pancreas or in children from ganglioneuroblastoma.</p>	<p>Surgical removal of the tumor is rewarding.</p>
<p><b>Figures 8.4.4A and B:</b> Lobulated mass with calcification near tail of pancreas. Tumor VIP +  <i>Photo Courtesy:</i> Malathi Sathiyasekaran</p>		

<b>Wolman's Syndrome</b>		
	<p>Wolman's syndrome is a rare fatal AR disorder due to deficiency of acid lipase and characterized by accumulation of cholesterol esters and triglycerides in the histiocytic foam cells of most visceral organs. Presents as hepatosplenomegaly, diarrhea and anemia. Bilateral adrenal calcification seen on plain X-ray is the hall-mark finding.</p>	<ul style="list-style-type: none"> <li>• There is no specific therapy for the disease.</li> <li>• Umbilical cord stem cell therapy has been advocated to replace acid lipase levels. If done early may be curative.</li> </ul>
<p><b>Figures 8.4.5A and B:</b> Adrenal calcification, liver bx with vacuoles  <i>Photo Courtesy:</i> Malathi Sathiyasekaran</p>		

## Section 9

---

# Nephrology

***Section Editor***  
Pankaj Deshpande

***Photo Courtesy***  
Fagun Shah, Pankaj Deshpande

- 
- 9.1 Common Conditions
  - 9.2 Uncommon Conditions but not Rare
  - 9.3 Syndromes

## SECTION OUTLINE

### 9.1 COMMON CONDITIONS 169

- ◆ Abdominal Striae Secondary to Steroid Therapy 169
- ◆ Adverse Effects of Steroids on Height 169
- ◆ Bilateral Dilatation of the Pelvicalyceal System 169
- ◆ Delayed Presentation of Renal Tubular Acidosis 170
- ◆ DMSA Scan done at Two Months after Urinary Tract Infection (UTI) 170
- ◆ DMSA Scan done Six Months after a UTI 170
- ◆ DMSA Scan Showing Dysplastic Left Kidney with Poor Function 171
- ◆ Hyperpigmentation of Skin on Fingers due to Cyclophosphamide 171
- ◆ Idiopathic Nephrotic Syndrome on Long-term Steroid Therapy 171
- ◆ Idiopathic Nephrotic Syndrome with Cushingoid Features 172
- ◆ MCUG Showing Bilateral Grade 4 Vesicoureteric Reflux 172
- ◆ MCUG Showing Posterior Urethral Valves and Trabeculated Bladder with Right Grade 5 Reflux 172
- ◆ Nephrotic Syndrome on Cyclosporine Looking Normal 173

- ◆ Posterior Urethral Valves 173
- ◆ Renal Tubular Acidosis—Severe Deformities of the Lower Limbs 173

### 9.2 UNCOMMON CONDITIONS BUT NOT RARE 174

- ◆ Bladder Diverticulum 174
- ◆ Chronic Kidney Disease with Genu Valgum Deformity due to Renal Osteodystrophy 174
- ◆ Enlarged Kidney—Unusual Presentation of Disease 174
- ◆ Multicystic Dysplastic Kidney 175
- ◆ Multicystic Dysplastic Kidney—Involuting 175
- ◆ Nephrocalcinosis 176
- ◆ Ostial Stenosis of Left Renal Artery on CT Angiography 176
- ◆ Severe Bowing of Legs 176
- ◆ Severe Rickets due to Vitamin D Dependency 177
- ◆ Short Stature in Patient with Chronic Kidney Disease 177
- ◆ Stenosed Renal Artery on CT Angiography 178

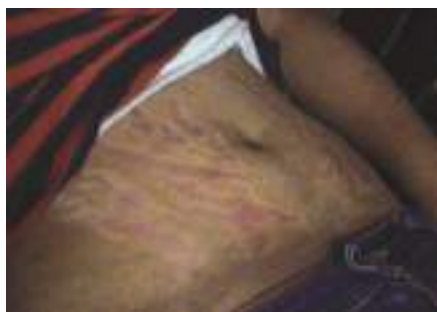### 9.3 SYNDROMES 178

- ◆ Bartter's Syndrome 178
- ◆ Bartter's Syndrome—Response to Therapy 179
- ◆ Prune-Belly Syndrome 179

## 9.1 COMMON CONDITIONS

Picture	Note	Management
---------	------	------------

### Abdominal Striae Secondary to Steroid Therapy



**Figure 9.1.1:** Abdominal striae secondary to steroid therapy  
Photo Courtesy: Pankaj Deshpande, Mumbai

This twelve years old boy had steroid sensitive nephrotic syndrome for more than 7 years. He had received multiple courses of steroids; the abdominal striae that are an adverse effect of steroids are well seen here. They can be painful to begin with and eventually leave marks that do not disappear. Occur due to stretching of skin.

Once they occur, there is very little that can be done to make them disappear. Hence, the aim should be to prevent their occurrence. Use of steroids sparingly and use of other agents to prevent steroid adverse effects is very important. Vitamin E has been used to improve the appearance of the striae.

### Adverse Effects of Steroids on Height

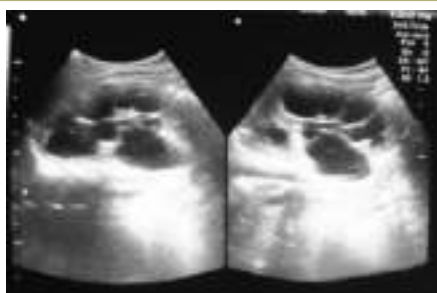


**Figure 9.1.2:** Adverse effects of steroids on height  
Photo Courtesy: Pankaj Deshpande, Mumbai

The boy has nephrotic syndrome and had multiple courses of steroids. The boy is 7 years old and the girl is his sister who was 5 years old when this photo was taken. As can be seen the boy is much shorter than her younger sister though prior to the onset of nephrotic syndrome, his height was on the 10<sup>th</sup> centile.

Monitor the height regularly on steroids. The height velocity would be more appropriate. Any effect on the height of children in nephrotic syndrome should prompt use of further agents. This boy's height at this stage was well below the third centile though his height had been on the 10<sup>th</sup> centile prior to several years of nephrotic syndrome and steroids.




### Bilateral Dilatation of the Pelvicalyceal System









**Figure 9.1.3:** Bilateral dilatation of the pelvicalyceal system  
Photo Courtesy: Pankaj Deshpande, Mumbai




Renal ultrasound showing severe bilateral dilatation of the pelvicalyceal system in a 6 months old baby. Note the “Mickey-Mouse appearance”.

Severe dilatation of the pelvicalyceal system should arouse the suspicion of pelvi-ureteric junction obstruction. A radioisotope scan—MAG3/EC/DTPA will be able to determine the drainage pattern. If the renal function in both kidneys is preserved, conservative management usually is required. If the renal function in the affected kidney is reduced, surgical intervention is required to preserve function.

Picture	Note	Management
<b>Delayed Presentation of Renal Tubular Acidosis</b>		
 <p data-bbox="164 748 574 823"><b>Figure 9.1.4:</b> Delayed presentation of renal tubular acidosis Photo Courtesy: Pankaj Deshpande, Mumbai</p>	<p data-bbox="630 277 1024 400">Twelve years old untreated patient of renal tubular acidosis. Note the severe stunting of height. Other pictures show the deformities.</p>	<p data-bbox="1073 277 1479 461">Detection has to be done early. Suspect renal tubular acidosis in patients with failure to thrive. Blood gas and serum electrolytes with normal renal function will provide a diagnosis.</p>
<b>DMSA Scan done at Two Months after Urinary Tract Infection (UTI)</b>		
 <p data-bbox="164 1310 574 1385"><b>Figure 9.1.5:</b> DMSA scan done at two months after UTI Photo Courtesy: Pankaj Deshpande, Mumbai</p>	<p data-bbox="630 972 1016 1126">DMSA scan done 2 months after a UTI. Note the reduced uptake in the upper and lower poles of the left kidney. This was reported as scarring.</p>	<p data-bbox="1073 972 1476 1248">A DMSA scan is done in UTIs to look for chronic damage. Acute changes on DMSA can last for several months. Hence, a DMSA scan should not be done for at least four months after a UTI. In fact, the later, the better. Ideally, it would be better to do the scan after six months!</p>
<b>DMSA Scan done Six Months after a UTI</b>		
 <p data-bbox="164 1800 574 1876"><b>Figure 9.1.6:</b> DMSA scan done six months after a UTI Photo Courtesy: Pankaj Deshpande, Mumbai</p>	<p data-bbox="630 1518 1040 1641">The DMSA scan of the same boy as in Figure 9.1.5, repeated after six months. Completely normal with no 'scarring'!</p>	<p data-bbox="1073 1518 1476 1794">A DMSA scan is done in UTIs to look for chronic damage. Acute changes on DMSA can last for several months. Hence, a DMSA scan should not be done for at least four months after a UTI. In fact, the later, the better. Ideally, it would be better to do the scan after six months!</p>

Picture	Note	Management
<b>DMSA Scan Showing Dysplastic Left Kidney with Poor Function</b>		
 <p data-bbox="138 562 552 637"><b>Figure 9.1.7:</b> DMSA scan showing dysplastic left kidney with poor function <i>Photo Courtesy:</i> Pankaj Deshpande, Mumbai</p>	<p data-bbox="602 275 1013 594">DMSA scan showing the presence of a dysplastic left kidney with poor function. This baby had presented with mild fever 4 months prior to the scan and was diagnosed to have a UTI that was treated. The interesting feature to note is that despite left kidney being dysplastic, the ultrasound scan showed both kidneys to be of equal size.</p>	<p data-bbox="1045 275 1456 682">DMSA scan is used in UTIs to detect chronic damage but the distinction between scarring and dysplasia has to be made on history and clinical features. Normal sized kidneys on ultrasound does not rule out dysplasia. The loss of corticomedullary differentiation is a subtle marker of dysplasia. Long-term monitoring of renal function and proteinuria is mandatory in such cases. Remember they are completely asymptomatic!</p>
<b>Hyperpigmentation of Skin on Fingers due to Cyclophosphamide</b>		
 <p data-bbox="138 1208 552 1283"><b>Figure 9.1.8:</b> Hyperpigmentation of skin on fingers due to cyclophosphamide <i>Photo Courtesy:</i> Pankaj Deshpande, Mumbai</p>	<p data-bbox="602 862 1013 1242">This girl had nephrotic syndrome and was frequently relapsing. Hence, she was given a course of cyclophosphamide. On the therapy with oral cyclophosphamide, patients can develop hyperpigmentation of the toes and fingers (darkening of skin). This can be seen in the pictures of her fingers and toes. This is a common complaint of the parents that the distal toes and fingers look darker!</p>	<p data-bbox="1045 862 1456 1017">Masterly inactivity! No medications are required! The hyperpigmentation disappears completely after the therapy of 12 weeks is completed!</p>
<b>Idiopathic Nephrotic Syndrome on Long-term Steroid Therapy</b>		
 <p data-bbox="138 1810 552 1886"><b>Figure 9.1.9:</b> Idiopathic nephrotic syndrome on long-term steroid therapy <i>Photo Courtesy:</i> Pankaj Deshpande, Mumbai</p>	<p data-bbox="602 1465 1013 1810">This one and half years old girl had nephrotic syndrome. She had received more than 3 months of daily steroids and was not clearly in remission, hence it is case of steroid resistant nephrotic syndrome. The Cushingoid features with swollen cheeks can be well seen as also the puffiness of the eyelids, indicating edema and nonresolution of the nephrotic syndrome.</p>	<p data-bbox="1045 1465 1456 1872">Even if edema resolves, ensure that the nephrotic syndrome has resolved by checking a urine protein/creatinine ratio in a spot urine sample. If the ratio is high (normally less than 0.5), it may be steroid resistant nephrotic syndrome. These children need a kidney biopsy and further medications like cyclosporine. This girl had minimal change disease on biopsy and has done very well on cyclosporine.</p>

Picture	Note	Management
<b>Idiopathic Nephrotic Syndrome with Cushingoid Features</b>		
 <p data-bbox="164 594 586 670"><b>Figure 9.1.10:</b> Idiopathic nephrotic syndrome with Cushingoid features <i>Photo Courtesy:</i> Pankaj Deshpande, Mumbai</p>	<p data-bbox="626 273 1040 588">This three and half years old boy had nephrotic syndrome but relapsed frequently. Hence, he had multiple courses of steroids. The cushingoid features are well appreciated here. The “moon-facies” that come with long courses of large doses of steroids are remarkable. Needless to say, obesity also makes its presence felt.</p>	<p data-bbox="1070 273 1484 656">Though the first episode of nephrotic syndrome may be sensitive to steroids, frequent relapsers (more than 2 relapses in 6 months) will need other medications to avoid steroid toxicity. Moon facies, obesity, risk of infections, osteoporosis, hypertension, abnormal glucose tolerance, stunting of height, cataracts are the few adverse effects to watch out for with steroids!</p>
<b>MCUG Showing Bilateral Grade 4 Vesicoureteric Reflux</b>		
 <p data-bbox="164 1201 597 1277"><b>Figure 9.1.11:</b> MCUG showing bilateral grade 4 vesicoureteric reflux <i>Photo Courtesy:</i> Fagun Shah, Surat</p>	<p data-bbox="626 815 1036 1099">This one year old baby presented with recurrent episodes of urinary tract infections and bilateral hydronephrosis on ultrasound examination. Micturating cystourethrogram done during infection free period revealed presence of bilateral grade 4 vesicoureteric reflux.</p>	<p data-bbox="1070 815 1484 1197">Children with recurrent episodes of UTI, especially below 1 year of age need special care and investigations. Apart from ultrasound, MCUG is required to diagnose and grade vesicoureteric reflux. Medical and surgical therapy has shown similar outcomes in children diagnosed with vesicoureteric reflux. Attention to local factors to prevent UTI is important along with chemoprophylaxis.</p>
<b>MCUG Showing Posterior Urethral Valves and Trabeculated Bladder with Right Grade 5 Reflux</b>		
 <p data-bbox="164 1774 570 1882"><b>Figure 9.1.12:</b> MCUG showing posterior urethral valve and trabeculated bladder with right grade 5 reflux <i>Photo Courtesy:</i> Fagun Shah, Surat</p>	<p data-bbox="626 1438 1040 1723">This three months old male child presented with recurrent episodes of UTI and poor urinary stream with visibly palpable swelling in suprapubic region. Micturating cystourethrogram shows dilated posterior urethra at bladder neck along with trabeculated bladder and right Grade 5 reflux.</p>	<p data-bbox="1070 1438 1484 1755">Posterior urethral valves have to be diagnosed early in the newborn period. Antenatal ultrasound scans usually show pelvic dilatation and/or large bladder. Posterior urethral valves are diagnosed by MCUG and need fulguration. Long-term follow-up for renal function and proteinuria is mandatory and crucial.</p>

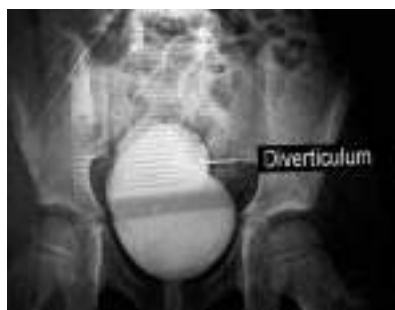Picture	Note	Management
<b>Nephrotic Syndrome on Cyclosporine Looking Normal</b>		
 <p data-bbox="138 613 552 684"><b>Figure 9.1.13:</b> Nephrotic syndrome on cyclosporine looking normal <i>Photo Courtesy:</i> Pankaj Deshpande, Mumbai</p>	<p data-bbox="602 269 1013 617">This six years old girl had frequently relapsing Nephrotic syndrome. This picture shows how well she is on cyclosporine. Often, hirsutism is considered as one of the major problems on cyclosporine for girls. As cyclosporine dose is adjusted properly, there is no evidence of hirsutism in this picture! Needless to say, she has no cushingoid features or steroid side effects.</p>	<p data-bbox="1045 269 1456 555">When used appropriately in the right doses, medications like Cyclosporine do a great job of preventing relapses in nephrotic syndrome without causing the known side effects of hirsutism or gingival hyperplasia. This girl is now off all medications and is doing very well.</p>
<b>Posterior Urethral Valves</b>		
 <p data-bbox="138 1185 552 1242"><b>Figure 9.1.14:</b> Posterior urethral valves <i>Photo Courtesy:</i> Pankaj Deshpande, Mumbai</p>	<p data-bbox="602 842 1013 964">Voiding cystourethrogram showing the presence of dilated posterior urethra indicating the presence of minor posterior urethral valves.</p>	<p data-bbox="1045 842 1456 1250">This four years old boy presented with occasional episodes of passing urine after a very long duration, sometimes even 12 hours. Otherwise, he used to void regularly and had a fairly good stream. When he had a long interval between voiding episodes, he would have to strain to void. Minor posterior urethral valves usually do not affect renal function but have to be surgically/endoscopically removed/fulgurated.</p>
<b>Renal Tubular Acidosis—Severe Deformities of the Lower Limbs</b>		
 <p data-bbox="138 1798 552 1876"><b>Figure 9.1.15:</b> Renal tubular acidosis—Severe deformities of the lower limbs <i>Photo Courtesy:</i> Pankaj Deshpande, Mumbai</p>	<p data-bbox="602 1402 1013 1823">Severe deformities of the lower limbs as in the similar type of case as mentioned in Figure 9.1.4. As florid rickets has not been treated, there is malleolar widening, severe weakness with the girl being unable to sit and severe osteomalacia on X-ray along with rickets. This picture was taken earlier than the other one and improvement in her clinical status can be seen on treatment as she was able to stand and walk independently.</p>	<p data-bbox="1045 1402 1456 1721">Normal anion gap—Metabolic acidosis with hypokalemia and hyperchloremia are the basis of diagnosis of renal tubular acidosis (RTA). Rickets in RTA is usually due to acidosis inactivating the vitamin D or uncommonly due to phosphate loss as in Fanconi's syndrome. To prevent deformity, early detection is must.</p>



## 9.2 UNCOMMON CONDITIONS BUT NOT RARE

Picture	Note	Management
---------	------	------------

### Bladder Diverticulum

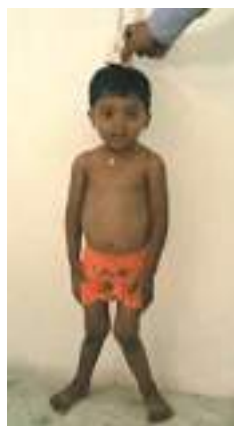

**Figure 9.2.1:** Bladder diverticulum  
Photo Courtesy: Pankaj Deshpande, Mumbai

This shows a voiding cystourethrogram with the dye in the bladder showing an outline of the diverticulum as shown.

If the child is having recurrent urine infections or if the diverticulum is large, surgical removal of the diverticulum is essential. Small diverticulum in early infancy may improve by itself and conservative management can be tried.

### Chronic Kidney Disease with Genu Valgum Deformity due to Renal Osteodystrophy

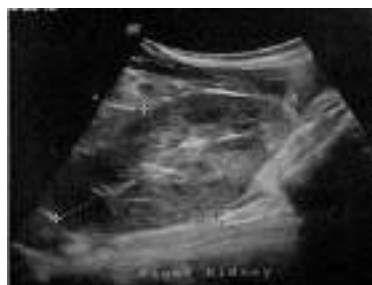

**Figure 9.2.2:** Chronic kidney disease with genu valgum deformity due to renal osteodystrophy  
Photo Courtesy: Fagun Shah, Surat

Severe deformity of the lower limbs similar to that depicted in Figure 9.1.4.

While the condition in previous child was due to renal tubular acidosis, this child on investigations had high anion gap metabolic acidosis with severely deranged renal functions. The cause for bony deformity here was renal osteodystrophy secondary to chronic kidney disease. Non-functioning kidneys disturb bone metabolism due to multiple factors. This illustration clarifies different etiologies with same clinical presentation.

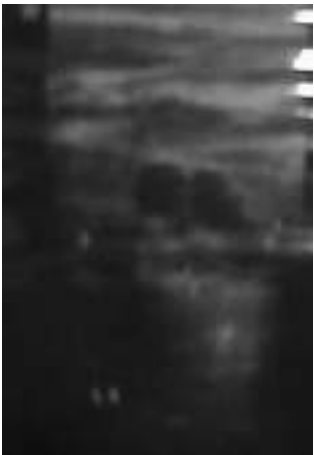
### Enlarged Kidney—Unusual Presentation of Disease





**Figure 9.2.3:** Enlarged kidney—unusual presentation of disease  
Photo Courtesy: Pankaj Deshpande, Mumbai


Enlarged kidney on abdominal ultrasound scan.  
Unusual presentation of disease. This infant presented with fever and blood tests showed a low Hb of 8, total WCC of 5200 and low platelets of 80,000/cmm. The ultrasound scan was done for abdominal distension.

This baby had acute lymphoblastic leukemia (ALL)! The enlarged kidneys were secondary to renal spread of ALL. Important to keep unusual presentations in mind!


Picture	Note	Management
 <p><b>Figure 9.2.4:</b> Multicystic dysplastic kidney <i>Photo Courtesy:</i> Pankaj Deshpande, Mumbai</p>	<p>Renal ultrasound showing many cystic structures of fairly large size. This is a case of Left multicystic dysplastic kidney in a 6 months old child.</p>	<p>Unilateral multicystic dysplastic kidneys usually need no intervention. Most will involute by eight years of age and hence surgery is not required. Monitoring of renal function and blood pressure is all that is required. Usually the other kidney is normal and hence long-term prognosis is good. Very rarely, if the MCDK does not involute but increases in size or is associated with hypertension may intervention be required.</p>

### Multicystic Dysplastic Kidney—Involuting


 <p><b>Figure 9.2.5:</b> Multicystic dysplastic kidney—involuting <i>Photo Courtesy:</i> Pankaj Deshpande, Mumbai</p>	<p>This US scan was done 3 years after the earlier one (above). Note the small size and disappearing cysts.</p>	<p>Unilateral multicystic dysplastic kidneys usually need no intervention. Most will involute by eight years of age and hence surgery is not required. Monitoring of renal function and blood pressure is all that is required. Usually the other kidney is normal and hence long-term prognosis is good. Very rarely, if the MCDK does not involute but increases in size or is associated with hypertension may intervention be required.</p>
 <p><b>Figure 9.2.6:</b> Multicystic dysplastic kidney—involuting <i>Photo Courtesy:</i> Pankaj Deshpande, Mumbai</p>	<p>This clearly shows the extremely small size of the involuting multicystic dysplastic kidney (MCDK) described above. The size is less than 1 cm!</p>	<p>Unilateral multicystic dysplastic kidneys usually need no intervention. Most will involute by eight years of age and hence surgery is not required. Monitoring of renal function and blood pressure is all that is required. Usually, the other kidney is normal and hence long-term prognosis is good. Very rarely, if the MCDK does not involute but increases in size or is associated with hypertension may intervention be required.</p>

Picture	Note	Management
<b>Nephrocalcinosis</b>		
	<p>This ultrasound scan shows severe nephrocalcinosis as can be seen by the bright triangular structures. This baby has distal renal tubular acidosis.</p>	<p>Brightness of the kidney or increased echogenicity can be due to many reasons. Nephrocalcinosis is an important cause. Investigation into the cause of nephrocalcinosis should include tests for tubular disorders, hypercalciuria, history of diuretics, etc. Metabolic acidosis with hyperchloremia, normal anion gap and hypokalemia indicate renal tubular acidosis and hypercalciuria is commonly seen in distal RTA.</p>
<p><b>Figure 9.2.7:</b> Nephrocalcinosis <i>Photo Courtesy:</i> Pankaj Deshpande, Trivandrum</p>		

### Ostial Stenosis of Left Renal Artery on CT Angiography


	<p>CT angiography in a boy with posterior urethral valves showing a small left kidney and ostial narrowing at the origin of the left renal artery. This boy had persistent hypertension.</p>	<p>Usually children with posterior urethral valves have an increased urine output and are not hypertensive till the renal function deteriorates significantly. This boy had normal renal function and persistent hypertension. Persistent hypertension in posterior urethral valves is not normal and should warrant investigations including a CT angiography.</p>
<p><b>Figure 9.2.8:</b> Ostial stenosis of left renal artery on CT angiography <i>Photo Courtesy:</i> Pankaj Deshpande, Mumbai</p>		

### Severe Bowing of Legs


	<p>Severe bowing of the legs. Note the increased intercondylar distance when the malleoli are placed together. The boy is sixty-five months old. Bowing at this age is abnormal. He also had signs of rickets and investigations revealed hypophosphatemic rickets.</p>	<p>Bowing beyond 3 years of age is not physiological and hence investigations need to be done. The hallmark of hypophosphatemic rickets is lethargy, weakness (lack of phosphate), normal calcium, very low phosphorus, high alkaline phosphatase and normal or mild elevation of PTH. Therapy with Joulie's solution, 1, 25 calcitriol and monitoring for nephrocalcinosis forms the mainstay of treatment. This condition can be X-linked dominant or autosomal dominant in inheritance.</p>
<p><b>Figure 9.2.9:</b> Severe bowing of legs <i>Photo Courtesy:</i> Pankaj Deshpande, Mumbai</p>		

Picture	Note	Management
<p data-bbox="126 214 727 247"><b>Severe Rickets due to Vitamin D Dependency</b></p>  <p data-bbox="138 1052 553 1128"><b>Figures 9.2.10A and B:</b> Severe Rickets due to vitamin D dependency <i>Photo Courtesy:</i> Fagun Shah, Surat</p>	<p data-bbox="602 269 1013 492">Classical case of severe vitamin D dependent rickets. Note the bowing of forearms with wrist widening and similar changes in lower limbs. The presence of pot belly due to muscular hypotonia as well as Harrison's sulcus is quite obvious.</p>	<p data-bbox="1045 269 1446 778">This girl due to classic clinical features and laboratory investigations suggestive of rickets was given multiple doses of 25-hydroxy vitamin D without any result. Further referral and investigations were suggestive of Vitamin D. Dependent Rickets Type 1. The child was treated with daily doses of 1,25-dihydroxy vitamin D. Nonresponsiveness to conventional treatment for rickets should prompt to investigate for other causes of rickets like RTA, vitamin D dependent rickets, hypophosphatemic rickets, etc.</p>


### Short Stature in Patient with Chronic Kidney Disease

 <p data-bbox="138 1768 537 1841"><b>Figure 9.2.11:</b> Short stature in patient with chronic kidney disease <i>Photo Courtesy:</i> Fagun Shah, Surat</p>	<p data-bbox="602 1263 1013 1391">Severe growth retardation in a child with chronic kidney disease. The girl is 8 years old studying in 2<sup>nd</sup> standard and height is just 80 cm.</p>	<p data-bbox="1045 1263 1446 1637">Growth retardation is an important consequence of chronic renal disease. It has a multifactorial basis—end organ resistance to growth hormone, acidosis, anemia, nutritional deficiency, etc. It is imperative to screen for renal functions in all patients with short stature. Treatment is multifactorial and requires multifaceted approach with correction of all contributing factors.</p>
--	---	---

Picture	Note	Management
 <p><b>Figure 9.2.12:</b> Stenosed renal artery on CT angiography Photo Courtesy: Pankaj Deshpande, Mumbai</p>	<p>CT angiography showing two renal arteries on both sides with a stenosed segment of the right lower artery.</p>	<p>See below in Figure 9.2.13.</p>
 <p><b>Figure 9.2.13:</b> Stenosed renal artery on CT angiography Photo Courtesy: Pankaj Deshpande, Mumbai</p>	<p>CT angiography showing two renal arteries on both sides with a stenosed segment of the right lower artery.</p> <p>This was an unusual case. This is a CT angiography done for an eleven years old boy with persistent hypertension after the pelvi-ureteric junction obstruction in the left kidney was treated with pyeloplasty. It shows two renal arteries on both sides. The lower one on the right shows a 7 mm segment that is completely occluded and hence causing the hypertension!</p>	<p>Hypertension in children needs to be investigated thoroughly as renovascular hypertension is one of the common causes of hypertension in children. High renin and aldosterone levels, captopril renography showing reduced renal function are some of the tests that can be used. Doppler may not always diagnose renal artery stenosis. CT angiography provides good resolution pictures. Angioplasty was done in this boy and he remains well with no medications being required.</p>
<h3>9.3 SYNDROMES</h3>		
<h4>Bartter's Syndrome</h4>		
 <p><b>Figure 9.3.1:</b> Bartter's syndrome Photo Courtesy: Pankaj Deshpande, Mumbai</p>	<p>Renal ultrasound shows severe dilatation of renal pelvis.</p>	<p>While the common causes of dilatation in the pelvicalyceal system are pelvi-ureteric junction obstruction or vesicoureteric reflux, this baby has an unusual but commonly forgotten condition. The dilatation was secondary to polyuria as seen in tubular disorders. This baby had Bartter's syndrome and the following picture will show how the dilatation improves on treatment of the condition.</p>

Picture	Note	Management
<b>Bartter's Syndrome—Response to Therapy</b>		
	<p>The dilatation seen previously is significantly reduced as the polyuria is controlled. Also, note the increased echogenicity in the kidney that indicates nephrocalcinosis, a hallmark of Bartter's syndrome.</p>	<p>Presence of polyuria, failure to thrive should lead to suspicion of Bartter's syndrome. Biochemically, there will be alkalosis, hypokalemia, low chloride and concomitant high urinary chloride and hypercalciuria. Treatment with Indomethacin and potassium supplements helps in controlling the symptoms and aids appropriate growth.</p>
<p><b>Figure 9.3.2:</b> Bartter's syndrome—response to therapy  <i>Photo Courtesy:</i> Pankaj Deshpande, Mumbai</p>		

### Prune-Belly Syndrome

	<p>The lax musculature of the abdomen and the undescended testes. The syndrome is characterized by hydronephrosis with large bladder, abdominal wall muscle deficiency, renal dysplasia and characteristic wrinkled abdominal skin.</p>	<p>Children with prune belly will have bilateral dilatation of the pelvicalyceal system with or without vesicoureteric reflux. Renal dysplasia is also common and must be looked for in such patients.</p>
<p><b>Figure 9.3.3:</b> Prune-Belly syndrome  <i>Photo Courtesy:</i> Pankaj Deshpande, Mumbai</p>		



## Section 10

---

# Hematology

### ***Section Editors***

MR Lokeshwar, Bharat Agarwal

### ***Photo Courtesy***

Anupam Sachdeva, Bharat Agarwal, Mamta Manglani,  
MR Lokeshwar, Nitin Chavan, Nitin Shah, Raj Warriar

- 
- 10.1 Common Conditions
  - 10.2 Uncommon Conditions but not Rare
  - 10.3 Hematological Emergencies
  - 10.4 Syndromes



## SECTION OUTLINE

### 10.1 COMMON CONDITIONS 183

- ◆ Anemia-Child with Pallor 183
- ◆ Anemia-Hemolytic: Dactylitis in Sickle Cell Anemia 183
- ◆ Anemia-Hemolytic: Infant with Thalassemia Major 184
- ◆ Anemia-Hemolytic: Thalassemic Child 184
- ◆ Anemia-Hemolytic: Thalassemia Intermedia 185
- ◆ Anemia-Hemolytic: Thalassemia Major 185
- ◆ Anemia-Hemolytic: Thalassemic Child—Malar Prominence 186
- ◆ Anemia-Hemolytic: Thalassemia Child—Hot Cross Bun Appearance 186
- ◆ Anemia-Hemolytic: Thalassemia with Growth Retardation 186
- ◆ Anemia-Hemolytic: Thalassemia—Peripheral Blood Smear 187
- ◆ Anemia-Hemolytic: Thalassemia—Nestof Test for Thalassemia Minor 187
- ◆ Anemia-Hemolytic: Thalassemia—Hb Electrophoresis by Paper and Cellulose Acetate 187
- ◆ Anemia-Hemolytic: Thalassemia—Hb Variant Analysis by HPLC 188
- ◆ Anemia-Hemolytic: Thalassemia—Radiological Changes in Thalassemia Major 188
- ◆ Anemia-Hemolytic: Thalassemia—Dexa Scan 189
- ◆ Anemia-Hemolytic: Thalassemia—Cold Centrifuge 189
- ◆ Anemia-Hemolytic: Thalassemia—Laminar Flow 190
- ◆ Anemia-Hemolytic: Thalassemia—Leukocyte Filter 190
- ◆ Anemia-Hemolytic: Thalassemia—Day Care Transfusion Center 190
- ◆ Anemia-Hemolytic: Thalassemia—Desferal Subcutaneous Pump 191
- ◆ Anemia-Hemolytic: Thalassemia—Oral Chelation Therapy 191
- ◆ Anemia-Hemolytic: Thalassemia—Splenectomy in Thalassemic Child 192
- ◆ Anemia-Hemolytic: Thalassemia—Stem Cell Transplantation in Thalassemia 192
- ◆ Anemia-Kala-Azar 193
- ◆ Anemia-Malaria 193
- ◆ Anemia-Bone Marrow Failure Syndrome—Aplastic Anemia 194

- ◆ Anemia-Nutritional—Iron Deficiency Anemia 194
- ◆ Anemia-Nutritional—Megaloblastic Anemia 195
- ◆ Anemia-Nutritional—Peripheral Smear in IDA 195
- ◆ Anemia-Nutritional—Reticulocyte Count 196
- ◆ Anemia-Nutritional—Bone Marrow Examination 196
- ◆ Bleeding Disorder—Fixed Drug Reaction 196
- ◆ Bleeding Disorder—Idiopathic Thrombocytopenic Purpura 197
- ◆ Bleeding Disorder—Hemophilia 197
- ◆ Bleeding Disorder—Vitamin K Deficiency 198
- ◆ Leukemia—Acute Lymphoblastic Leukemia 198

### 10.2 UNCOMMON CONDITIONS BUT NOT RARE 199

- ◆ Anemia in Newborn—Fetomaternal Transfusion 199
- ◆ Autoimmune Hemolytic Anemia on Steroid Therapy 199
- ◆ Gaucher's Disease 200
- ◆ Hereditary Elliptocytosis 200
- ◆ Hereditary Spherocytosis 201
- ◆ Hereditary Spherocytosis in a Family—Icterus in Both Mother and Child 201
- ◆ Hypothyroidism with Anemia 202
- ◆ Lead Poisoning Presenting as Anemia 202
- ◆ Persistent Anemia in Celiac Disease 203
- ◆ Protein C Deficiency (Homozygous) 203
- ◆ Purpura Fulminans 203


### 10.3 HEMATOLOGICAL EMERGENCIES 204

- ◆ Disseminated Intravascular Coagulation 204
- ◆ G6PD Deficiency 204
- ◆ Hemolytic Uremic Syndrome 205



### 10.4 SYNDROMES 205


- ◆ Battered Baby Syndrome 205
- ◆ Diamond Blackfan Syndrome 205
- ◆ Dyskeratosis Congenita 206
- ◆ Fanconi's Anemia 206
- ◆ Glanzmann's Thrombasthenia 207
- ◆ Henoch's Schönlein Purpura 207
- ◆ Kasabach-Merritt Syndrome 207
- ◆ Wiscott-Aldrich Syndrome 208

## 10.1 COMMON CONDITIONS


Picture	Note	Management
<p><b>Anemia-Child with Pallor</b></p>  <p><b>Figure 10.1.1:</b> Anemia-child with pallor Photo Courtesy: MR Lokeshwar, Mamta Manglani, Mumbai</p>	<p>Pallor is important common symptom of anemia.</p> <p>Most common cause of anemia is due to nutritional deficiencies like iron deficiency, B<sub>12</sub>, folic acid deficiencies, deficiency of micronutrients particularly when not associated with generalized lymphadenitis or hepatosplenomegaly, petechiae, purpura.</p> <p>When child does not respond to deficient nutrients, other causes should be considered.</p>	<ul style="list-style-type: none"> <li>• All anemic patients are not necessarily pale and all pale looking children may not necessarily be anemic. Pallor depends on hemoglobin content, state of skin capillaries, skin pigmentation and thickness.</li> <li>• Children with hypothyroidism, nephrotic syndrome, CCF look pale without being anemic. Jaundice, cyanosis may interfere with appreciation of pallor and interfere with evaluation of anemia. Treat underlying cause. Symptoms of anemia not only depend on hemoglobin concentration but also on rate of fall of hemoglobin.</li> </ul>


### Anemia-Hemolytic: Dactylitis in Sickle Cell Anemia

 <p><b>A</b></p>  <p><b>B</b></p> <p><b>Figures 10.1.2A and B:</b> Dactylitis in sickle cell anemia Photo Courtesy: MR Lokeshwar, Nitin Shah</p>	<p>Hand foot syndrome (dactylitis) presents with:</p> <ul style="list-style-type: none"> <li>• Swelling over the hand-?cellulitis.</li> <li>• X-ray hand shows osteomyelitis.</li> <li>• CBC shows: Anemia, High WBC count.</li> <li>• Peripheral smear shows sickle cell on peripheral smear confirms the diagnosis of sickle cell anemia.</li> <li>• Sickling test positive.</li> <li>• HPLC (High-performance liquid chromatography) confirms the diagnosis.</li> </ul>	<p>Hand foot syndrome (dactylitis) presents with:</p> <ul style="list-style-type: none"> <li>• Pain control and hydration.</li> <li>• If associated with infection proper antibiotics.</li> <li>• Blood transfusion may be helpful if HbS is high.</li> <li>• No surgery is required.</li> <li>• Hydroxyurea is useful for prevention.</li> </ul>
--	--	---


Picture	Note	Management
<p data-bbox="149 214 828 245"><b>Anemia-Hemolytic: Infant with Thalassemia Major</b></p>  <p data-bbox="162 551 576 633"><b>Figure 10.1.3:</b> Infant with thalassemia major Photo Courtesy: MR Lokeshwar, Mamta Manglani, Mumbai</p>	<p data-bbox="625 265 1031 715">Pale child from Mahar community. No history of consanguinity. Received blood transfusion twice in the past. On examination, marked pallor, prominent forehead, mild hepatosplenomegaly. Peripheral smear examination showed increased normoblasts, HbF 10%, HbA<sub>2</sub> 3.2%, Sr. Ferritin 120 ng/dl. Diagnosis- ?? Thalassemia, but HbF not much increased. Parenteral study—mother and father both thalassemia minor with HbA<sub>2</sub> increased 4.2 and 5.1% respectively.</p>	<p data-bbox="1068 265 1477 490">After repeated blood transfusions there may not be high level of HbF in the affected child. Parental study and chain synthesis, gene study useful for confirming the diagnosis of thalassemia major. Thalassemia is common in following communities:</p> <ul data-bbox="1068 500 1469 786" style="list-style-type: none"> <li>• <i>Sindhis and Punjabis, Khatris, Kukrejas</i></li> <li>• <i>Bhanushalis, Kutchis, Lohanas</i></li> <li>• <i>Mahars, Chamars, Buddhas and Navabudhas</i></li> <li>• <i>Kolies, Agris and Kunbies</i></li> <li>• <i>Reddies, Gowdas and Lingayats, Kurgs and Gaud Saraswats.</i></li> </ul>




### Anemia-Hemolytic: Thalassemic Child

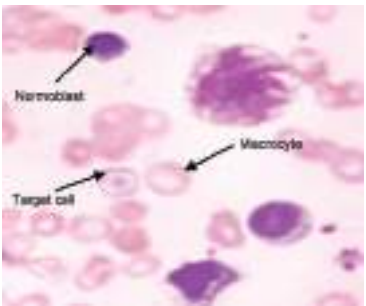
 <p data-bbox="162 1328 568 1430"><b>Figures 10.1.4A and B:</b> Anemia-hemolytic: Thalassemic child Photo Courtesy: MR Lokeshwar, Mamta Manglani, Mumbai</p>	<p data-bbox="625 1073 1031 1297">Frontal bossing and parietal bossing are indicators of most poor management of a child with thalassemia major. It is mainly due to marked increase in medullary erythropoiesis in the flat bones of the skull.</p>	<ul data-bbox="1068 1073 1477 1236" style="list-style-type: none"> <li>• Treated by hypertransfusion. Pretransfusion Hb should not be less than 10 to 11gm%.</li> <li>• Posttransfusion Hb should not be less than 12 gm%.</li> </ul>
---	--	---

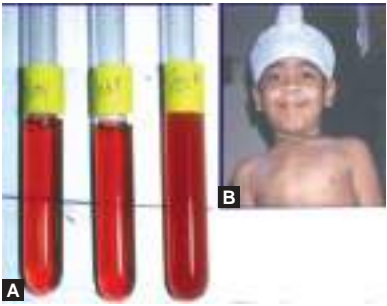
Picture	Note	Management
<p data-bbox="126 214 722 245"><b>Anemia-Hemolytic: Thalassemia Intermedia</b></p>  <p data-bbox="138 833 500 903"><b>Figure 10.1.5:</b> Thalassemia intermedia Photo Courtesy: MR Lokeshwar, Mamta Manglani, Mumbai</p>	<p data-bbox="602 271 1019 878">HbF elevated, homozygous states or double heterozygous may be present. Associated with pallor and hepatosplenomegaly. Hemolytic face with frontal bossing, parietal bossing, malar prominence, malocclusion of teeth. This syndrome has extreme variability, ranging from as severe as thalassemia major to those as mild <math>\beta</math>-thalassemia trait with minimum or no symptoms. Presentation can be as early as 2 years to adolescent or adult life. Growth and development may be normal with normal puberty and fertility depending upon the severity. They may be associated with progressive osteoporosis with pathological fractures, leg ulcers, anemia and hypersplenism.</p>	<ul data-bbox="1045 271 1450 582" style="list-style-type: none"> <li>• Moderate anemia.</li> <li>• Not dependent on blood transfusion for their survival.</li> <li>• Transfusion requirement vary depending upon the severity of their phenotype. As the child grows may need regular blood transfusion.</li> <li>• Administration of folic acid.</li> </ul>

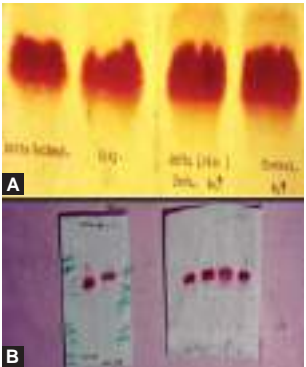
### Anemia-Hemolytic: Thalassemia Major

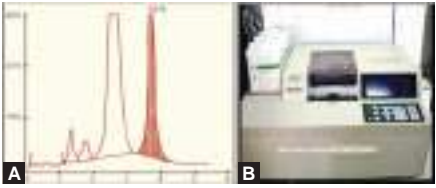
 <p data-bbox="138 1453 451 1530"><b>Figure 10.1.6:</b> Thalassemia major Photo Courtesy: MR Lokeshwar, Mamta Manglani, Mumbai</p>	<p data-bbox="602 1093 1019 1475">HbF-markedly elevated, homozygous state. Both parents heterozygous (thalassemia minors). Inadequate treatment leads to growth retardation, pallor, hepatosplenomegaly and organ dysfunction. Dependent on blood transfusion for their survival. Requires regular transfusion every 3 to 6 weeks. Chelation therapy to prevent iron overload. Treatment of organ dysfunction.</p>	<p data-bbox="1045 1093 1450 1539">Thalassemia belt stretches across African continent, Mediterranean regions, Middle East, Indian subcontinent, Southeast Asia, Thailand, Cambodia, Laos, Vietnam, Malaysia, Singapore, Southern China, and Melanesia. Approximately about 100,000 - children with Thalassemia major are born all over the world. In India with the birth rate of 22.8 per 1000, it is estimated that, 8 to 10,000 children born with thalassemia major and added every year.</p>
---	--	--

Picture	Note	Management
<p><b>Anemia-Hemolytic: Thalassemic Child—Malar Prominence</b></p>  <p><b>Figure 10.1.7:</b> Thalassemic child—Malar prominence Photo Courtesy: MR Lokeshwar, Nitin Shah, Mumbai</p>	<p>Malar prominence in case of thalassemia major indicate improper transfusion therapy. It is due to expansion of bone marrow space mainly in flat bones and is due to increased intramedullary erythropoiesis.</p>	<ul style="list-style-type: none"> <li>• Hypertransfusion suppresses bone marrow expansion.</li> <li>• Hence regular saline washed packed red blood transfusion prevents hemolytic face. Child lives on borrowed blood and does not produce his/her own blood.</li> </ul>
<p><b>Anemia-Hemolytic: Thalassemia Child—Hot Cross Bun Appearance</b></p>  <p><b>Figure 10.1.8:</b> Hot cross bun appearance Photo Courtesy: MR Lokeshwar, Nitin Shah</p>	<p>Hot cross bun appearance of the skull indicates most poor management of a child with thalassemia major. It is mainly due to marked increase in erythropoiesis in the flat bones of the skull.</p>	<p>Treated by hypertransfusion. Pretransfusion Hb should not be less than 10 to 11 gm% and post-transfusion Hb should not be less than 12 gm%. This will not permit production of defective cells in the marrow and hence expansion of marrow does not take place.</p>
<p><b>Anemia-Hemolytic: Thalassemia with Growth Retardation</b></p>  <p><b>Figure 10.1.9:</b> Thalassemia with growth retardation Photo Courtesy: MR Lokeshwar, Mamta Manglani, Mumbai</p>	<p>Comparison of thalassemia children receiving:</p> <ul style="list-style-type: none"> <li>• Proper adequate therapy.</li> <li>• Improper, irregular therapy.</li> <li>• Normal nonthalassemic healthy child.</li> </ul> <p>All are of same age.</p>	<p>Proper transfusion therapy, chelating therapy and adequate management of complications allows the child to have near normal growth and development.</p>


Picture	Note	Management
<p><b>Anemia-Hemolytic: Thalassemia—Peripheral Blood Smear</b></p>  <p><b>Figure 10.1.10:</b> Peripheral blood smear of thalassemia major Photo Courtesy: MR Lokeshwar, Nitin Chavan, Mumbai</p>	<p>Peripheral blood smear in thalassemia is diagnostic with characteristic bizarre picture of red cells, which are microcytic, macrocytic, hypochromic, associated with poikilocytosis, polychromasia moderate basophilic stippling and fragmented erythrocytes, target cells, Cabot's ring and large number of normoblasts.</p>	<p>Diagnosis of thalassemia major can be suspected on peripheral smear examination.</p>

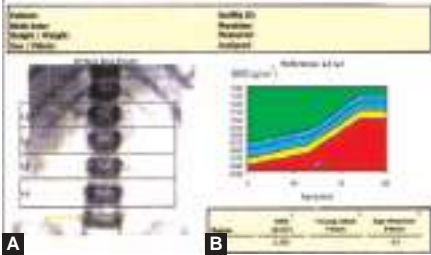
<p><b>Anemia-Hemolytic: Thalassemia—Nestrof Test for Thalassemia Minor</b></p>  <p><b>Figures 10.1.11A and B:</b> Nestrof test for thalassemia minor Photo Courtesy: MR Lokeshwar, Mamta Manglani, Mumbai</p>	<p>Nestrof test is naked eye single tube red cell osmotic fragility. A positive nestroft test is seen in several other conditions besides <math>\beta</math>-thal trait also seen like <math>\alpha</math>-thalassemia trait, HbE, HbS and hereditary persistence of fetal hemoglobin. It is only screening test and hence should be followed by evaluation of Hb A<sub>2</sub>.</p>	<p>Good screening test. Nestrof negative rules out thalassemia minor. Nestrof test has been found to have a high sensitivity (80.7–100%) and high negative predictive value (96–100%). But, it's poor precision, inter technician variability and low specificity has precluded it from becoming a routine procedure. With availability of cell counter various RBC parameters can be obtained like RDW, MCV, etc. which will help in suspecting thalassemia minor and differentiating from iron deficiency anemia.</p>
---	--	---

<p><b>Anemia-Hemolytic: Thalassemia—Hb Electrophoresis by Paper and Cellulose Acetate</b></p>  <p><b>Figures 10.1.12A and B:</b> Hb electrophoresis by paper cellulose acetate Photo Courtesy: MR Lokeshwar, Mamta Manglani, Mumbai</p>	<p>Paper electrophoresis (Fig. 10.1.12A).</p> <p>Cellulose acetate electrophoresis (Fig. 10.1.12B).</p>	<ul style="list-style-type: none"> <li>• With the availability of HPLC, Hb electrophoresis is not much used.</li> <li>• However, cellulose acetate electrophoresis is still used where HPLC is not available.</li> <li>• Paper electrophoresis is out dated.</li> </ul>
--	---	---


Picture	Note	Management
<p data-bbox="152 212 998 247"><b>Anemia-Hemolytic: Thalassemia—Hb Variant Analysis by HPLC</b></p>  <p data-bbox="162 472 571 547"><b>Figures 10.1.13A and B:</b> Hb variant analysis by HPLC <i>Photo Courtesy:</i> Biorad</p>	<p data-bbox="626 271 987 396">High performance liquid chromatography (HPLC) has become popular and applied to identify Hb variant.</p> <p data-bbox="626 408 1040 566">Hemoglobins are separated graphically and quantified by spectrophotometry utilizing a sophisticated computer software. The test is accurate, precise and fast.</p> <p data-bbox="626 578 943 637">It identifies various types of hemoglobinopathies.</p>	<p data-bbox="1070 271 1458 429">Very useful for quantification of HbA2 in <math>\beta</math>-thalassemia, screening as well as for identification and quantification of other hemoglobins.</p>

### Anemia-Hemolytic: Thalassemia—Radiological Changes in Thalassemia Major




 <p data-bbox="162 1406 591 1508"><b>Figures 10.1.14A and B:</b> Radiological changes in thalassemia major <i>Photo Courtesy:</i> MR Lokeshwar, Nitin Shah, Mumbai</p>	<p data-bbox="626 1005 1032 1387">“Hair on end” appearance. Expansion of the bone marrow and demineralization in the bones lead to trabeculae in the skull bones become prominent giving “Hair on end” appearance. Osteoporosis is a progressive systemic skeletal disease characterized by low bone mass and microarchitectural deterioration of bone tissue leading to increase in bone fragility and susceptibility to fracture.</p> <p data-bbox="626 1400 1000 1494">Osteopenia and osteoporosis are major causes of morbidity in the older thalassemia population.</p>	<ul data-bbox="1070 1005 1468 1306" style="list-style-type: none"> <li>• Regular transfusion to keep Hb more than 11 gm% is a must for proper growth and development of thalassemic child.</li> <li>• Oral calcium and vitamin D should be given to all children routinely.</li> <li>• Chelation therapy is equally important.</li> </ul>
---	--	---


Picture	Note	Management
<p><b>Anemia-Hemolytic: Thalassemia—Dexa Scan</b></p>  <p><b>Figures 10.1.15A and B:</b> Dexa scan in thalassemic child  <i>Photo Courtesy:</i> MR Lokeshwar, Nitin Shah, Mumbai</p>	<p>With increasing life expectancy, thalassemia bone disease including osteopenia, osteoporosis syndrome (OOS) have evolved as major cause of debility resulting in fracture of the bones particularly lumbar spine and the long bones. These bone changes are more severe in males than females, in those with diabetes mellitus and hypogonadism.</p>	<ul style="list-style-type: none"> <li>• Adolescent and adult thalassemia children should get calcium and vitamin D supplementation.</li> <li>• Administration of hydroxyurea, biphosphonate and intravenous pamidronate are other useful modalities.</li> <li>• Pamidronate may be given in a monthly dose of 30 mg.</li> <li>• Hormone replacement therapy with estrogen in female and HCG for males improves bone density parameters.</li> <li>• Calcitonin and inhibitor of osteoclasts can reduce osteoporosis and increase cortical thickness in the thalassemic children.</li> </ul>

### Anemia-Hemolytic: Thalassemia—Cold Centrifuge


 <p><b>Figure 10.1.16:</b> Cold centrifuge  <i>Photo Courtesy:</i> Mamta Manglani, MR Lokeshwar, Mumbai</p>	<p>Cold centrifuge required for the preparation of blood components, and costs few lakhs rupees. Cold centrifuge is used for washing the red cells.</p>	<p>Every blood bank associated with outdoor thalassemia center must have cold centrifuge which is required to prepare saline washed packed cells which helps in preventing the complications like febrile reaction, hemolytic transfusion reaction.</p>
--	---	---




Picture	Note	Management
<p data-bbox="152 212 802 247"><b>Anemia-Hemolytic: Thalassemia—Laminar Flow</b></p>  <p data-bbox="164 533 456 609"><b>Figure 10.1.17:</b> Laminar flow Photo Courtesy: MR Lokeshwar, Mamta Manglani, Mumbai</p>	<p data-bbox="626 271 1037 363">Laminar flow is required for preparation of blood products in an aseptic way.</p>	<p data-bbox="1070 271 1471 363">All blood banks must have laminar flow for the preparation of blood components.</p>
<p data-bbox="152 670 834 705"><b>Anemia-Hemolytic: Thalassemia—Leukocyte Filter</b></p>  <p data-bbox="164 1232 537 1308"><b>Figures 10.1.18A and B:</b> Leukocyte filter Photo Courtesy: MR Lokeshwar, Anupam Sachdeva</p>	<p data-bbox="626 727 984 854">It is ideal to use leukodepleting filters at bedside; however, this is not affordable to most of our patients</p>	<p data-bbox="1070 727 1471 788">Leukodepletion by bedside filters is more efficient than saline washing.</p>
<p data-bbox="152 1369 1000 1404"><b>Anemia-Hemolytic: Thalassemia—Day Care Transfusion Center</b></p>  <p data-bbox="164 1616 565 1692"><b>Figure 10.1.19:</b> Day care transfusion center Photo Courtesy: MR Lokeshwar, Mamta Manglani, Mumbai</p>	<p data-bbox="626 1426 1000 1549">In the past, thalassemic children had to be admitted for blood transfusion along side other sick children of the ward.</p> <p data-bbox="626 1565 1011 1723">Prolonged hospital stay, cross infections, increased cost, both to the parents and the institution as well as psychological trauma was the brunt of such therapy.</p>	<ul data-bbox="1070 1426 1487 1913" style="list-style-type: none"> <li>• Advances in the present management of transfusion therapy in thalassemic children is day care transfusion center which has made the treatment more compliant. With the advent of outdoor transfusion centers, transfusion can be well planned causing minimal psychological trauma to the child and parents as transfusion is given in a cordial compliant surrounding with other thalassemic children.</li> <li>• There are few out door transfusion centers in our country.</li> </ul>


Picture	Note	Management
<p data-bbox="126 214 586 245"><b>Anemia-Hemolytic: Thalassemia—Desferal Subcutaneous Pump</b></p>  <p data-bbox="138 582 560 684"><b>Figures 10.1.20A to C:</b> Desferal subcutaneous pump and Slit lamp examination Photo Courtesy: MR Lokeshwar, Mamta Manglani, Mumbai</p>	<p data-bbox="586 214 1029 245">Desferrioxamine (DFO) was introduced in early sixties. Though ideal, administration with the help of desferal subcutaneous pump, over 6 to 8 hours, it is high cost has resulted in noncompliance especially in the developing world.</p>	<p data-bbox="1029 214 1466 245">Desferal must be given subcutaneously with the help of subcutaneous desferal pump over 4 to 6 hours, 5 to 6 days in a week. The dose is 20 to 40 mg/kg body wt/day. Adverse effects include:</p> <ul data-bbox="1029 275 1466 623" style="list-style-type: none"> <li>• Local reactions</li> <li>• Auditory and visual toxicity</li> <li>• Growth retardation.</li> <li>• <i>Yersinia spp.</i>/infection.</li> </ul> <p data-bbox="1029 643 1466 766">Regular auditory and visual evaluation by audiometry and slit lamp examination should be done every 6 months.</p>


### Anemia-Hemolytic: Thalassemia—Oral Chelation Therapy

 <p data-bbox="138 1195 535 1246"><b>Figure 10.1.21:</b> Oral chelation therapy Photo Courtesy: MR Lokeshwar, Mumbai</p>	<ul data-bbox="586 909 1029 1441" style="list-style-type: none"> <li>• Deferiprone (L1 or 1,2 dimethyl 1, 3 hydroxy pyridin-4-one (L1 or Kelfer) developed in Hiders laboratory, London.</li> <li>• It is bidentate chelator.</li> <li>• It was 1<sup>st</sup> licensed for use in India since 1995.</li> <li>• It is given orally and less expensive.</li> <li>• It mobilizes iron from Transferin, Ferritin and Hemosiderin.</li> <li>• It is 70 to 100% as effective as desferrioxamine.</li> <li>• It has no toxicity for the ear or eye.</li> <li>• Urinary excretion of Ca, Cu, Mn, and Mg was not affected.</li> </ul>	<p data-bbox="1029 909 1466 940">Dose: 75 to 100 mg/kg/ body wt.</p> <p data-bbox="1029 950 1466 981">Toxicity:</p> <ul data-bbox="1029 991 1466 1226" style="list-style-type: none"> <li>• Nausea, vomiting, pain in abdomen and diarrhea.</li> <li>• 20 to 30% children had arthropathy which is reduced after reducing the dose or stopping the dose.</li> <li>• Absolute neutropenia and thrombocytopenia have been reported.</li> </ul>
--	---	--


Picture	Note	Management
<b>Anemia-Hemolytic: Thalassemia—Splenectomy in Thalassemic Child</b>		
 <p data-bbox="164 645 456 748"><b>Figure 10.1.22:</b> Splenectomy in thalassemia child <i>Photo Courtesy:</i> MR Lokeshwar, Mamta Manglani, Mumbai</p>	<p data-bbox="630 271 1036 492">Hypersplenism may occur in thalassemic children due to inadequate transfusion, allo-immunization and rarely auto-immune hemolysis complicating thalassemia major and chronic liver disease.</p>	<ul data-bbox="1073 271 1479 840" style="list-style-type: none"> <li>• Splenectomy is recommended when the transfusion requirement exceeds 200 to 250 ml/kg/yr of packed red cell.</li> <li>• Splenectomy should be deferred till the age of 5 years.</li> <li>• Prior to splenectomy pneumococcal vaccine, H influenza vaccine, meningococcal vaccine must be given at least 2 to 4 weeks prior to the procedure.</li> <li>• Routine vaccines like Hepatitis B, Hepatitis A should be given as scheduled.</li> <li>• After the operation life long penicillin prophylaxis should be advised.</li> </ul>


### Anemia-Hemolytic: Thalassemia—Stem Cell Transplantation in Thalassemia

 <p data-bbox="164 1479 570 1582"><b>Figures 10.1.23A and B:</b> Anemia-hemolytic thalassemia: Stem cell transplantation in thalassemia <i>Photo Courtesy:</i> MR Lokeshwar, Mumbai</p>	<p data-bbox="630 1013 1036 1234">The credit of first bone marrow transplantation in thalassemia major goes to E Donald Thomas. The first BMT in India in thalassemia was done by Dr M Chandy at Christian Medical College, Vellore. Sources of stem cells:</p> <ul data-bbox="630 1244 846 1391" style="list-style-type: none"> <li>• Bone marrow</li> <li>• Peripheral blood</li> <li>• Cord blood</li> <li>• Fetal liver.</li> </ul> <p data-bbox="630 1406 1036 1535">Though expensive, it is cost-effective as compared to yearly cost of regular blood transfusion and chelation therapy.</p>	<p data-bbox="1073 1013 1463 1105">The three most important adverse prognostic factors for survival and event-free survival are:</p> <ul data-bbox="1073 1116 1463 1289" style="list-style-type: none"> <li>• Presence of hepatomegaly (liver more than 2 cm below costal margin)</li> <li>• Portal fibrosis</li> <li>• Irregular chelation.</li> </ul> <p data-bbox="1073 1299 1463 1422">The cost of BMT in India is around ₹5 to 8 lakhs. Child wearing the cap is the recipient as he has lost the hair due to radiation.</p>
--	---	---

Picture	Note	Management
<p><b>Anemia-Kala-Azar</b></p>  <p><b>Figures 10.1.24A and B:</b> Kala-azar Photo Courtesy: MR Lokeshwar, Mamta Manglani, Mumbai</p>	<p>Child is from Darbhanga district. Presents with fever off and on since long duration, pallor++ no koilonychia, platynachia, moderate hepatosplenomegaly. pancytopenia, anemia, leukopenia, thrombocytopenia. Peripheral smear for malarial parasite-negative. Aldehyde test +ve. Total protein 6.5 gm%, Globulin 3.5%, Albumin 3%.</p> <p>Bone marrow examination: LD bodies present. Also seen in splenic puncture and liver biopsy.</p>	<p>Treatment includes:</p> <ul style="list-style-type: none"> <li>• Pentavalent antimonials—Sodium stibogluconate, 20 mg/kg/day of antimony base for 3 to 4 weeks.</li> <li>• Amphotericin B 1 mg/kg/day IV × 20 days.</li> <li>• Pentamidine isothionate 4 mg/kg by IM route on alternate day for 5 to 52 weeks.</li> </ul>


### Anemia-Malaria

 <p><b>Figures 10.1.25A and B:</b> Malaria Photo Courtesy: MR Lokeshwar, Nitin Shah</p>	<p>Progressive anemia with enlarged liver and spleen in newborn.</p> <ul style="list-style-type: none"> <li>• Mother may have history of fever with chills and rigor during pregnancy and misdiagnosed as urinary tract infection.</li> </ul> <p>Investigations:</p> <ul style="list-style-type: none"> <li>• WBC nonspecific</li> <li>• Platelet count low</li> </ul> <p>Coomb's test:</p> <p>Direct and indirect -ve,</p> <ul style="list-style-type: none"> <li>• G6PD: Normal activity</li> <li>• Microcytic, hypochromic anemia</li> <li>• PS examination—<i>P. Vivax</i>.</li> </ul>	<ul style="list-style-type: none"> <li>• PS examination is a key to diagnosis.</li> <li>• Neonatal malaria may not have typical symptoms like high fever, chills and rigor, but may present with fever, irritability, pallor, diarrhea, vomiting and nonspecific symptoms and may have mild hepatosplenomegaly. Treat malaria and if severely anemic blood transfusion may be required.</li> <li>• Folic acid useful.</li> </ul>
---	--	--

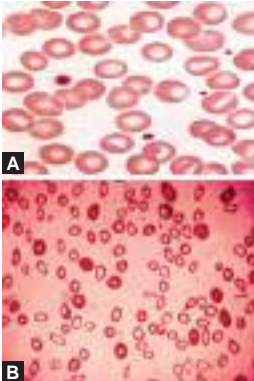
Picture	Note	Management
<b>Anemia-Bone Marrow Failure Syndrome—Aplastic Anemia</b>		
 <p data-bbox="164 533 578 609"><b>Figure 10.1.26:</b> Anemia-bone marrow failure syndrome—Aplastic anemia <i>Photo Courtesy:</i> Nitin Shah, Mumbai</p>	<ul data-bbox="630 273 1036 915" style="list-style-type: none"> <li>• Petechiae and ecchymosis in a pale sick looking child without any signs like lymphadenopathy, hepatosplenomegaly and bony tenderness is more likely to be due to aplastic anemia.</li> <li>• It is characterized by thrombocytopenia, neutropenia, anemia. Anemia disproportionate to amount of bleeding.</li> <li>• Reticulocyte count markedly suppressed.</li> <li>• Stressed erythropoiesis is evident —HbF and I antigen.</li> <li>• Flow cytometric analysis for CD48 and CD59 to rule out PNH.</li> <li>• Bone marrow examination and trephine biopsy confirm the diagnosis.</li> </ul>	<p data-bbox="1068 273 1300 302">Treatment includes:</p> <ul data-bbox="1068 314 1458 656" style="list-style-type: none"> <li>• Supportive therapy</li> <li>• Bone marrow transplantation—stem cell transplantation</li> <li>• Immunomodulation</li> <li>• ATG, ALG</li> <li>• Cyclosporin A</li> <li>• Cyclophosphamide</li> <li>• Methylprednisolone</li> <li>• Androgen</li> </ul>

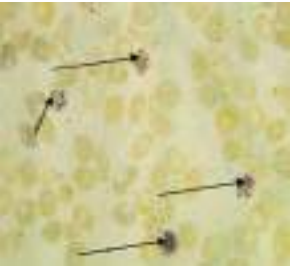
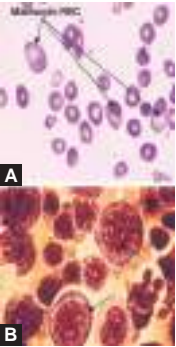

### Anemia-Nutritional—Iron Deficiency Anemia

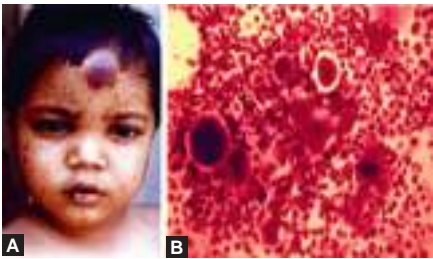
 <p data-bbox="164 1512 532 1616"><b>Figure 10.1.27:</b> Anemia-nutritional iron deficiency anemia <i>Photo Courtesy:</i> MR Lokeshwar, Bharat Agarwal, Mumbai</p>	<p data-bbox="630 1087 1016 1208">Thirty percent of the world population suffer from nutritional anemia. Of these, 90% are in the developing countries.</p>	<p data-bbox="1068 1087 1479 1657">Common symptoms seen in adults or in older children like stomatitis, bald tongue and loss of papillae, glossitis, angular chelosis, koilonychia, platynychia, Plummer-Winson's syndrome, Paterson Kelly's syndrome are uncommon in infants and children. In infants and children symptoms are mainly due to affection of cognitive functions like irritability, lack of concentration, not doing well in the school, etc. Pica- like geophagia (eating mud), amylophagia (eating starch or raw rice) pagopagia (eating ice) are also common symptoms. All these symptoms respond to iron therapy.</p>
---	---	--

Picture	Note	Management
<p><b>Anemia-Nutritional—Megaloblastic Anemia</b></p>  <p><b>Figure 10.1.28:</b> Megaloblastic anemia Photo Courtesy: MR Lokeshwar, Mamta Manglani, Mumbai</p>	<p>Pallor, anemia, blackish discoloration of knuckles, hyperpigmentation around the mouth, jaundice, and may present with golden yellow skin, edema feet, no lymphadenopathy, liver/spleen. Macrocytes on PS, high MCV, polysegmented neutrophils on PS, indirect hyperbilirubinemia, high LDH—helps in early diagnosis of megaloblastic anemia.</p>	<p>Oral folic acid and vitamin B<sub>12</sub> is the main stay of treatment.</p>


### Anemia-Nutritional—Peripheral Smear in IDA

 <p><b>Figures 10.1.29A and B:</b> (A) Normal RBC; (B) Hypochromic microcytic anemia Photo Courtesy: MR Lokeshwar, Nitin Chavan, Mumbai</p>	<p>Microcytic hypochromic. RBC are typical of iron deficiency anemia. Types of anemia:</p> <ul style="list-style-type: none"> <li>• Normocytic hypochromic—MCV 80–94 m<sup>3</sup></li> <li>• Microcytic hypochromic—MCV &lt; 80 m<sup>3</sup> MCH &lt; 27</li> <li>• Macrocytic hypochromic—MCV &gt; 94 u<sup>3</sup>, MCHC &lt; 32%.</li> </ul>	<p>Iron deficiency anemia is treated with oral iron in the dose of 3 to 5 mg/kg/body wt (elemental iron) till Hb level reaches to normal and then continue for at least 3 to 6 months to replenish the stores.</p>
---	---	--

Picture	Note	Management
<b>Anemia-Nutritional—Reticulocyte Count</b>		
 <p><b>Figure 10.1.30:</b> Anemia-nutritional: reticulocyte count Photo Courtesy: MR Lokeshwar, Nitin Chavan, Mumbai</p>	<p>Count 500 cells—supravital staining Normal: 1 to 2%.</p> <p>Low count:</p> <ul style="list-style-type: none"> <li>• Bone marrow failure syndrome like</li> <li>• Aplastic anemia</li> <li>• Fanconi's syndrome</li> <li>• BM infiltration</li> <li>• PRCA.</li> </ul> <p>High count: Increased BM response</p> <ul style="list-style-type: none"> <li>• Hemolysis</li> <li>• Hemorrhage</li> <li>• Post-treatment</li> </ul>	<p>Reticulocyte count is a very important screening test in anemia and reflects the bone marrow status.</p> <ul style="list-style-type: none"> <li>• Decreased reticulocyte count is an indication for bone marrow aspiration study, to rule out hypoplastic marrow or infiltration.</li> <li>• Where as increase reticulocyte count does not justify this invasive procedure routinely.</li> </ul>
<b>Anemia-Nutritional—Bone Marrow Examination</b>		
 <p><b>Figures 10.1.31A and B:</b> Anemia-nutritional—bone marrow examination Photo Courtesy: MR Lokeshwar, Nitin Chavan, Mumbai</p>	<ul style="list-style-type: none"> <li>• Macrocytic hypochromic RBC MCV &gt; 94 <math>\mu^3</math>, MCHC—normal</li> <li>• Hypersegmented neutrophils on PS examination is an early indicator to suspect the diagnosis.</li> <li>• Decreased serum B<sub>12</sub> and folic acid levels.</li> <li>• Bone marrow shows increased megaloblasts confirms the diagnosis.</li> </ul>	<p>Folic acid can be given:</p> <ul style="list-style-type: none"> <li>• Less than 6 months—15 mcg/kg or 50 mcg/day.</li> <li>• Seven months to 13 years—1 mg/day <math>\times</math> 2–3 weeks then 0.1 to 0.5 mg/day.</li> <li>• More than 13 years—1 mg/day <math>\times</math> 2–3 weeks, then 0.5 mg/day.</li> <li>• Cobalamin given in the dose of 500 to 1000 mcg/day orally <math>\times</math> 4–6 weeks then 25–50 mcg/day or 100 mcg/day. IM for 2 weeks, followed by 100–250 mcg/dose every month till complete correction.</li> </ul>
<b>Bleeding Disorder—Fixed Drug Reaction</b>		
 <p><b>Figure 10.1.32:</b> Fixed drug reaction Photo Courtesy: MR Lokeshwar, Nitin Shah</p>	<p>Fixed drug eruptions (FDEs) recur in the same site or sites each time a particular drug is taken; with each exposure however, the number of involved sites may increase. Fixed drug eruption is a type of allergic reaction to a medicine. Usually just one drug is involved, although independent lesions (patches) from more than one drug have been described. Lesions are more common on the limbs than the trunk; the hands and feet, genitalia (glans penis) and perianal areas and around the mouth or the eyes.</p>	<p>Drugs causing fixed drug eruptions:</p> <ul style="list-style-type: none"> <li>• Paracetamol</li> <li>• Sulphonamide antibiotics including cotrimoxazole/phenacetin</li> <li>• Nonsteroidal anti-inflammatories (NSAIDs)</li> <li>• Sedatives including barbiturates, benzodiazepines</li> <li>• Chlordiazepoxide</li> <li>• Quinine</li> <li>• Dapsone</li> <li>• Fluconazole</li> <li>• Doxycycline</li> <li>• Clarithromycin</li> <li>• Ciprofloxacin.</li> </ul>

Picture	Note	Management
<p data-bbox="126 210 586 251"><b>Bleeding Disorder—Idiopathic Thrombocytopenic Purpura</b></p>  <p data-bbox="138 541 570 643"><b>Figures 10.1.33A and B:</b> Idiopathic thrombocytopenic purpura <i>Photo Courtesy:</i> MR Lokeshwar, Nitin Chavan, Mumbai</p>	<ul data-bbox="602 271 1013 1079" style="list-style-type: none"> <li>• Most common cause of acute thrombocytopenia and bleeding in otherwise well child.</li> <li>• History of viral infections—like Epstein barr virus, HIV.</li> <li>• Sudden onset of generalized petechiae, purpura and bruises classic presentation in previously healthy child, age group 1 to 4 years. Often there may be bleeding from the gums, mucus membrane and rarely associated with CNS bleeds.</li> <li>• Bone marrow aspiration is other wise normal except increased megakaryocytes.</li> <li>• Presence of obvious spleno-hepatomegaly should lead to the suspicion of sinister diseases like leukemia.</li> <li>• Bleeding disproportionate to platelet count, with pancytopenia may be suggestive of aplastic anemia or leukemia.</li> </ul>	<ul data-bbox="1045 271 1455 823" style="list-style-type: none"> <li>• “Treat the child and not the platelet count.” “Nonfrantic watchful waiting”. Treat the child if there is severe thrombocytopenia less than 10 to 20,000 platelet count, associated with mucosal bleed. No therapy other than education and counselling of the family for mild ITP. IVIG at a dose of 0.8 to 1.0 gm kg/day for 1 to 2 days. Intravenous anti D globulin 50 to 75 mcg/kg for children with ITP who are not splenectomized or not Rh negative.</li> <li>• Steroid 1 to 4 mg/kg/4 days, followed by 2 mg/kg/day × 2 to 3 weeks; then taper.</li> </ul>

### Bleeding Disorder—Hemophilia

 <p data-bbox="138 1774 570 1825"><b>Figure 10.1.34:</b> Bleeding disorder—hemophilia <i>Photo Courtesy:</i> Anupam Sachdeva</p>	<p data-bbox="602 1201 1013 1416">Hemophilia A (Factor VIII deficiency) and Hemophilia B (Factor IX) are the most common and serious congenital coagulation factor deficiencies. Hemophilia C is the bleeding disorder with reduced level of factor XI.</p> <p data-bbox="602 1432 1013 1878">They are associated with prolongation of activated partial thromboplastin time (APTT or PTT). The symptoms of above conditions are common and are inherited. Obvious symptoms are bruising intramuscular hematoma, hemarthrosis, bleeding from the minor traumatic lacerations particularly of the mouth. Diagnosed by increased PTT and normal PT and normal platelet count, bleeding time, thrombin time and reduced factor levels.</p>	<ul data-bbox="1045 1201 1455 1878" style="list-style-type: none"> <li>• Treatment includes prompt correction of the factors involved. In hemophilia A factor VIII is introduced 20 to 40 IU/kg/day for minor bleeds or hemarthrosis and major bleeds 50 to 100 Iu/kg for 7 to 10 days. Initially continuous infusion 2 to 3 Iu/kg/hour continuously may be given and then may be by IV bolus. Desmopressin acetate may be given to increase endogenously produced factor VIII.</li> <li>• Bed rest, deep pressure for 15 to 20 minutes, ice pack or pack with petrolatum gauze are supportive line of treatment. Hemophilia B prothrombin complex concentrate 60 to 80 Iu/kg on day 1 then 40 Iu/kg on every other day for 7 to 10 days.</li> </ul>
---	---	--




Picture	Note	Management
 <p><b>Figure 10.1.35:</b> Bleeding disorder—Vitamin K deficiency Photo Courtesy: MR Lokeshwar, Mamta Manglani, Mumbai</p>	<p>Among the most common hemostatic disorder in the newborn is hemorrhagic disease of the newborn and termed as vitamin K deficiency bleeding. It may be of early onset occurring in less than 24 hours after birth and may be associated with maternal medications that interfere with vitamin K. The classic onset of VKDB is 2 to 7 days after birth in breastfed infants. Late onset is unexpected bleeding attributable to severe vitamin K deficiency in infants 2 to 12 weeks of age occurs primarily in exclusively breastfed infants who had received no vitamin K prophylaxis. May also be seen in infants who have intestinal malabsorption, cholestatic jaundice, cystic fibrosis, and alpha 1 antitrypsin deficiency.</p>	<p>Single dose of vitamin K is sufficient to stop the bleeding and return the PT values to the reference range. Treatment of vitamin K (1 mg) subcutaneously or IV may be given. Observe for jaundice and kernicterus especially in full-term infant. FFP may be given for moderate to severe bleeding. Prothrombin complex concentrate in life threatening bleeding. Vitamin K1 should be given to all newborn as single, intramuscular/ intravenous dose of 0.5 to 1 mg and 0.5 mg for infants less than 34 weeks. Oral administration of vitamin K have efficacy similar to that of parenteral administration.</p>
 <p><b>Figures 10.1.36A and B:</b> Leukemia-acute lymphoblastic leukemia Photo Courtesy: Nitin Shah, Mumbai</p>	<p>Suspect leukemia when associated with persistent fever, pallor, bleeding tendency, generalized lymphadenopathy with pancytopenia and abnormal cells on peripheral smear with thrombocytopenia. Various types of leukemia seen in children includes acute lymphatic anemia, acute myeloid leukemia, chronic myeloid leukemia. Smear shows lymphoblasts.</p>	<ul style="list-style-type: none"> <li>• Bone marrow aspiration and evaluation, immunophenotyping, cytogenetics are required for diagnosis. Treatment includes:</li> <li>• Supportive therapy, chemotherapy</li> <li>• Radiation therapy whenever required.</li> </ul>
 <p><b>Figures 10.1.37A and B:</b> Leukemia-acute lymphoblastic Leukemia Photo Courtesy: MR Lokeshwar, Mamta Manglani, Mumbai</p>	<ul style="list-style-type: none"> <li>• When associated with persistent fever, pallor, bleeding tendency, generalized lymphadenopathy with pancytopenia and abnormal cells on peripheral smear and thrombocytopenia suspect leukemia. Various types of leukemia seen in children includes:</li> <li>• Acute lymphoblastic leukemia</li> <li>• Acute myeloid leukemia</li> <li>• Chronic myeloid leukemia. Smear shows lymphoblasts L<sub>1</sub> type.</li> </ul>	<p>With current management protocol the cure rate for ALL has significantly improved and more than 70% can be cured.</p>


## 10.2 UNCOMMON CONDITIONS BUT NOT RARE

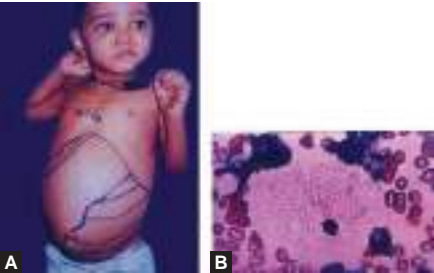
Picture	Note	Management
---------	------	------------

### Anemia in Newborn—Fetomaternal Transfusion

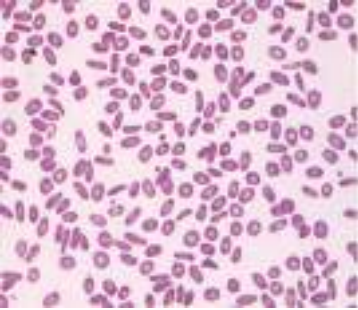
 <p><b>Figures 10.2.1A and B:</b> Anemia in newborn—Fetomaternal transfusion Photo Courtesy: MR Lokeshwar, Mumbai</p>	<p>Fetomaternal hemorrhage is one of most important cause of neonatal microcytic, hypochromic anemia. Retic count may be increased.</p> <p>G6PD screening test: Normal activity, Coomb's test both direct indirect are negative. Kleihauer-Betke test done on mother's smear show acid resistance pink colored fetal cells.</p> <p><i>Diagnosis:</i> Fetomaternal hemorrhage.</p>	<ul style="list-style-type: none"> <li>• When you evaluate newborn, you have to evaluate two patients—child and mother.</li> <li>• When no cause of etiopathology seen in the child, look for the cause in the mother.</li> <li>• Attending pediatrician at the time of delivery should not only examine newborn, but also examine the placenta.</li> </ul>
--	---	---


### Autoimmune Hemolytic Anemia on Steroid Therapy

 <p><b>Figures 10.2.2A and B:</b> Autoimmune hemolytic anemia on steroid therapy Photo Courtesy: MR Lokeshwar, Bharat Agarwal, Mumbai</p>	<p>Autoimmune hemolytic anemia results from interaction of red cell and immune systems and is characterized by shortened red cell life span, hemolysis and anemia. It is caused by autoantibodies to red cell antigen which includes:</p> <ul style="list-style-type: none"> <li>• Warm reactive antibodies</li> <li>• Cold agglutinin disease</li> <li>• Drug induced or</li> <li>• May be secondary to immune deficiency, HIV and drug induced or autoimmune disorder or following infections like mycoplasma or malignancies.</li> </ul>	<p>Management depends upon severity of intravascular hemolysis and renal involvement:</p> <ul style="list-style-type: none"> <li>• Maintain good urine out put.</li> <li>• Folic acid supplementation.</li> <li>• Pack red cell transfusion with cross matched, least in compatible blood.</li> <li>• Cortical steroids are the first line and mainstay in the therapy of AIHA.</li> <li>• IV methylprednisolone in the dose of 1 to 2 mg/kg 6 to 8 hours and then oral prednisolone 2 mg/kg/day/2 to 4 weeks and then taper over three months.</li> <li>• IV IgG have been tried in AIHA used in high dose 2 gm/kg divided in 2 doses. Other modalities tried are exchange transfusion.</li> <li>• Splenectomy and cytotoxic drugs.</li> </ul>
---	---	---


Picture	Note	Management
 <p><b>Figures 10.2.3A and B:</b> Gaucher's disease Photo Courtesy: MR Lokeshwar, Mamta Manglani, Mumbai</p>	<p>Lipid disorder characterized by hematological problems, organomegaly, skeletal involvement manifesting as bone pain and pathological fractures.</p> <p>It is most common lysosomal storage disorder. Gaucher's disease results from deficient activity of lysosomal hydrolase—acid beta glucosidase. Enzyme defect results in accumulation of undegraded glycolipid substrate—glucosyl ceramide. This results in infiltration of bone marrow, progressive hepatosplenomegaly and skeletal complication.</p>	<ul style="list-style-type: none"> <li>• Treatment includes: Enzyme replacement therapy with recombinant acid beta glucosidase.</li> <li>• Most extraskeletal symptom organomegaly, hematologic indices are reversed by an initial debulking dose of enzyme (60 Iu/kg) administered by intravenous infusion every other week.</li> <li>• Bone marrow transplantation have been tried but results in significant morbidity and mortality.</li> </ul>


### Hereditary Elliptocytosis

 <p><b>Figure 10.2.4:</b> Hereditary elliptocytosis Photo Courtesy: MR Lokeshwar, Nitin Chavan, Mumbai</p>	<p>Hereditary elliptocytosis are genetically transmitted autosomal dominant or recessive, uncommon RBC disorder with wide spectrum— asymptomatic and often discovered accidentally during routine peripheral blood smear examination which shows 15 to 20% elliptocytosis to mild hemolytic anemia with splenomegaly and gallstones and may manifest with moderate or even severe hemolysis. In neonatal period rarely symptomatic and may have severe hemolytic anemia with red blood cell fragmentation, poikilocytosis, elliptocytosis and microspherocytes.</p>	<p>Treatment rarely indicated for patients with mild elliptocytosis. However in severe cases red blood cell transfusion may be required.</p> <ul style="list-style-type: none"> <li>• Daily folate.</li> <li>• Phototherapy and exchange transfusion are warranted in case of severe anemia and hyperbilirubinemia in newborn period.</li> <li>• Gallstones detection usually done in patients older than six years and hence should undergo abdominal sonography.</li> <li>• Special attention is needed during viral infection (parvo virus) particularly when there is sudden precipitous drop in Hb.</li> <li>• Splenectomy should be considered when there is growth failure, skeletal changes, leg ulcers, etc.</li> </ul>
--	---	--

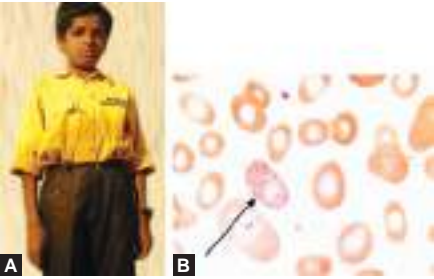
Picture	Note	Management
 <p><b>Figures 10.2.5A and B:</b> Hereditary spherocytosis Photo Courtesy: MR Lokeshwar, Nitin Chavan, Mumbai</p>	<p>Pallor off and on : Recurrent jaundice, mild hepatosplenomegaly. history of recurrent jaundice in parents or family members, history of pain in abdomen with history of splenectomy or cholecystectomy or gallstone in any members of family will help in the early diagnosis of spherocytosis. Investigations show increased retic count. Smear examination confirms the diagnosis. More than 15% RBC are spherocytes. Increased osmotic fragility.</p>	<p>Treatment consist of:</p> <ul style="list-style-type: none"> <li>• Regular follow-up.</li> <li>• Immunization with pneumococcal vaccine, meningococcal vaccine, HIB vaccine in addition to routine vaccines.</li> <li>• Splenectomy may have to be considered if anemia is persistent, progressive and recurrent.</li> <li>• Surgery may be indicated if child develops severe cholecystitis, gallstones with recurrent abdominal pain.</li> <li>• Severe anemia may need blood transfusion.</li> </ul>


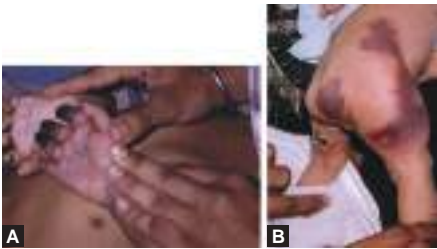

### Hereditary Spherocytosis in a Family—Icterus in Both Mother and Child

 <p><b>Figure 10.2.6:</b> Hereditary spherocytosis in a family—Icterus in both mother and child Photo Courtesy: MR Lokeshwar, Mamta Manglani, Mumbai</p>	<p>Spherocytosis has wide spectrum of symptoms ranging from jaundice in neonatal period needing exchange transfusion to silent disease detected in 80 years old man as grand child had spherocytosis. In between range of symptoms includes—pain in abdomen, recurrent jaundice, gallstone, aplastic crisis, hemolytic crisis, etc. High index of suspicion and good clinical evaluation is the key to the diagnosis.</p>	<ul style="list-style-type: none"> <li>• Not only child should be examined but also proper family history particularly for splenectomy, cholecystectomy and physical evaluation of the parents mainly for enlarged spleen should be done.</li> <li>• Peripheral smear examination and osmotic fragility are initial tests to be done. Treatment depends upon the severity of the disease and hence ranges from mere follow-up to recurrent blood transfusion as and when needed and splenectomy and cholecystectomy whenever required.</li> </ul>
---	---	---


Picture	Note	Management
<p><b>Hypothyroidism with Anemia</b></p>  <p><b>Figure 10.2.7:</b> Hypothyroidism with anemia Photo Courtesy: MR Lokeshwar, Mamta Manglani, Mumbai</p>	<p>Persistent anemia, growth retardation, history of prolonged physiological jaundice, persistent constipation, not doing well in school. On exam: pallor ++, macroglossia, wide fontanelle, hoarse cry, hypotonia++, distended abdomen, umbilical hernia. Hb ranging 6 to 8 gm. Multiple courses of oral iron therapy—no improvement. TS, TIBC, serum ferritin-N. HbF HbA2-N, Coomb's-neg. B<sub>12</sub> and Folic acid—normal. Normal T3, T4 decreased, TSH increased. Diagnosis—hypothyroidism.</p>	<ul style="list-style-type: none"> <li>• Supportive therapy,</li> <li>• Newborn—Eltroxin 10 mcg/kg daily</li> <li>• Older children—initially 50 to 100 ug increased by 25 to 50 ug at 3 to 4 weeks interval as required. Maintenance 100 mcg to 200 ug daily.</li> </ul>

### Lead Poisoning Presenting as Anemia


 <p><b>Figures 10.2.8A and B:</b> Lead poisoning presenting as anemia Photo Courtesy: MR Lokeshwar, Nitin Chavan, Mumbai</p>	<p>Iron deficiency child initially responding and then later not responding to oral iron therapy should lead to possibility of associated conditions like:</p> <ul style="list-style-type: none"> <li>• Lead poisoning.</li> <li>• Associated folic acid or B<sub>12</sub> deficiency.</li> <li>• Thalassemia minor.</li> </ul> <p>Look for:</p> <ul style="list-style-type: none"> <li>• Basophilic stippling. It is one of early indicators.</li> <li>• History of any members of the family working for car battery or lead factory.</li> <li>• Lead level diagnostic.</li> </ul>	<p>Treat for lead poisoning. The treatment with BAL 10 mcg/d is specific treatment.</p>
--	--	---

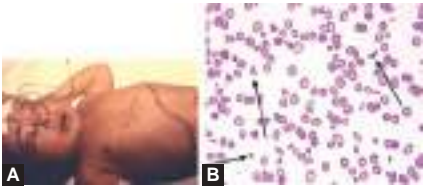
Picture	Note	Management
<p><b>Persistent Anemia in Celiac Disease</b></p>  <p><b>Figure 10.2.9:</b> Persistent anemia in celiac disease Photo Courtesy: MR Lokeshwar, Mamta Manglani, Mumbai</p>	<p>History of loose motions off and on large bulky stools. Distention of abdomen ++ History of persistent anemia—not responding to oral iron therapy. Hb 7 gm% (low), MCV 60 u<sup>3</sup> (low), RBC 3.4 m. TS 6% (low), serum ferritin 12 ng/dl (low), HbF 0.8%, HbA2 2.8% (N) Coomb's test negative. Antigliadin antibodies: +ve. Further investigations confirmed the diagnosis of 'Gluten induced enteropathy with malabsorption syndrome.'</p>	<p>Child was given parenteral iron correction of the diet, avoid wheat, and wheat products. Child responded well and growth improved.</p>
<p><b>Protein C Deficiency (Homozygous)</b></p>  <p><b>Figures 10.2.10A and B:</b> Protein C deficiency (Homozygous) Photo Courtesy: MR Lokeshwar, Bharat Agarwal, Mumbai</p>	<p>Protein C, protein S, antithrombin III play important role in the control of hemostasis, by inhibiting activated factor Va and factor VIIIa which converts prothrombin to thrombin. And inhibits the complex of factor IX a, factor VIIIa, and phospholipids which converts factor X to factor Xa.</p>	<p>Anticoagulant therapy initiated with appropriate dose of heparin or low molecular weight heparin for 5 to 10 days and then warfarin is begun within 24 hours to produce INR of 2 to 3.</p>
<p><b>Purpura Fulminans</b></p>  <p><b>Figures 10.2.11A and B:</b> Purpura fulminans Photo Courtesy: MR Lokeshwar, Bharat Agarwal, Mumbai</p>	<p>Potentially fatal disorder that follows infection with <i>meningococcus</i>, <i>Streptococcus</i>, varicella, and rubella. Thrombosis of small arterioles leads to infarction and hemorrhage of the skin, subcutaneous tissue and muscles. It begin with purpuric lesion on the skin that coalesces and then become necrotic.</p>	<ul style="list-style-type: none"> <li>• Neither heparin therapy, nor antiplatelet drugs have been shown to be effective.</li> <li>• Fresh frozen plasma used successfully to treat these infants.</li> <li>• A highly purified concentrate of protein C is now available and is efficacious in the treatment.</li> <li>• Liver transplantation have been found to be successful, and has resolved thrombosis episodes.</li> </ul>

### 10.3 HEMATOLOGICAL EMERGENCIES

Picture	Note	Management
 <p><b>Figure 10.3.1:</b> Disseminated intravascular coagulation Photo Courtesy: MR Lokeshwar, Anupam Sachdeva, Mumbai</p>	<p>Disseminated intravascular coagulation is characterized by activation of coagulation system resulting in generation of uncontrolled formation of fibrin within the blood vessels leading to microvascular thrombosis and consumption of platelets and coagulation proteins resulting in variable bleeding symptom. Patients with acute DIC are critically ill and diagnosis is based upon platelet count PT, APTT, clotting factors and inhibitors and presence of D Dimers. Fragmented red cells, helmet cells are seen in the peripheral smear with reduced platelet count.</p>	<p>Corner stone of the management is the prompt diagnosis of underlying condition and initiation of the specific treatment of the underlying disorder.</p> <p>Replacement therapy: Aim is to correct the consumption of the platelet, coagulation factors and inhibitors in order to prevent or arrest the hemorrhagic episode.</p> <ul style="list-style-type: none"> <li>• Platelet transfusion—1 to 2 unit/10 kg of body wt when platelet count is less than 20,000/mm<sup>3</sup> or in presence of major bleeding if the platelet count is less than 50,000/mm<sup>3</sup>.</li> <li>• Fresh frozen plasma (FFP—15-20 ml/kg) or</li> <li>• Fibrinogen concentrate or cryoprecipitate 1 bag/10 kg/body wt.</li> </ul>

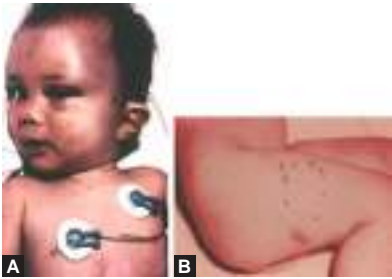
### G6PD Deficiency

 <p><b>Figures 10.3.2A and B:</b> G6PD deficiency Photo Courtesy: MR Lokeshwar, Mamta Manglani, Mumbai</p>	<p>Sudden onset of severe pallor since 24 hours, preceded by fever, cold and cough. Child treated by family physician. Clinically NAD except severe pallor? Mild icterus. Low Hb, increased reticulocyte count, WBC normal. On detailed enquiry –</p> <ul style="list-style-type: none"> <li>• History of aspirin given for high fever</li> <li>• Child is from Khoja community</li> <li>• G6PD—Decolorization time 25 min.</li> <li>• Coomb's direct and indirect—Negative.</li> <li>• Treated with packed cell transfusion</li> <li>• G6PD repeated after 6 weeks decolorization time &gt; 120 m.</li> </ul>	<p>A normal G6PD deficiency screening test during hemolysis does not rule out G6PD deficiency. Young reticulocytes have high G6PD enzyme. Repeat the test after three months. Clinical presentation: Newborn period—jaundice needing phototherapy, exchange transfusion. Acute hemolytic episodes—self limited—stop offending drug. May need packed red blood transfusion. Chronic hemolytic anemia—rare. Common drugs to be avoided:</p> <ul style="list-style-type: none"> <li>• Antimalarial drugs</li> <li>• Antipyretics like aspirin</li> <li>• Sulpha group of drugs</li> <li>• Nitrofurantoin</li> <li>• Ascorbic acid</li> <li>• Vitamin K.</li> </ul>
---	--	---


Picture	Note	Management
<p><b>Hemolytic Uremic Syndrome</b></p>  <p><b>Figures 10.3.3A and B:</b> Hemolytic uremic syndrome Photo Courtesy: MR Lokeshwar, Nitin Chavan,, Mumbai</p>	<p>Sick child presenting with history of loose motions, toxic look, purpuric spots, mild hepatosplenomegaly, progressive pallor not passing urine for &gt;8 to 12 hours suspect HUS. Investigations show altered renal function, electrolytes—increased potassium. Peripheral smear examination shows broken cells, crenated cells, hamlet cells, burr cells.</p>	<ul style="list-style-type: none"> <li>• Treat aggressively, with antibiotics as required.</li> <li>• Correct electrolyte imbalance.</li> <li>• Dialysis may be required.</li> </ul>

## 10.4 SYNDROMES



### Battered Baby Syndrome


 <p><b>Figures 10.4.1A and B:</b> Battered baby syndrome Photo Courtesy: Raj Warriar</p>	<p>Recurrent hematoma over the forehead, fracture of the clavicle, punch marks over the thigh in a newborn child suggested possibility of “Battered baby syndrome”. All screening tests for bleeding disorder—CBC, bleeding time, clot retraction, PT, PTT, platelet count are normal.</p>	<p>More common in female children. High index of suspicion is key to early diagnosis.</p>
--	--	---

### Diamond Blackfan Syndrome


 <p><b>Figures 10.4.2A and B:</b> Diamond blackfan syndrome Photo Courtesy: MR Lokeshwar, Nitin Chavan, Mumbai</p>	<p>Diamond blackfan syndrome is a constitutional chronic pure red cell aplasia. Inheritance is autosomal dominant or recessive. Associated abnormalities:</p> <ul style="list-style-type: none"> <li>• Strabismus, webbed neck, abnormality of fingers, ribs and thumb.</li> <li>• Congenital renal anomalies like double ureter with hydronephrosis, ectopic kidney.</li> <li>• Reticulocytopenia.</li> <li>• Bone marrow with profound erythroid hypoplasia with markedly increased M:E ratio.</li> <li>• Fetal hemoglobin elevated.</li> <li>• I antigen on the red cell surface increased.</li> <li>• Hypogammaglobulinemia.</li> </ul>	<p>Main stay of treatment is:</p> <ul style="list-style-type: none"> <li>• Packed red cell transfusion.</li> <li>• Steroids—1 to 2 mg of prednisolone for 4 to 6 weeks and then to maintain minimal required dose. Initially daily then on alternate day for months.</li> <li>• Methylprednisolone may be tried.</li> <li>• Chelation may be required for iron over load.</li> <li>• IV IgG have been tried.</li> <li>• Successful bone marrow transplantation have been reported.</li> </ul>
---	---	---




Picture	Note	Management
 <p><b>Figure 10.4.3:</b> Dyskeratosis congenita Photo Courtesy: MR Lokeshwar, Mamta Manglani, Mumbai</p>	<p>Rare disorder characterized by:</p> <ul style="list-style-type: none"> <li>• Skin hyperpigmentation.</li> <li>• Dystrophy of nail.</li> <li>• Abnormality in the teeth.</li> <li>• Hair changes.</li> <li>• Leukoplakia.</li> <li>• Risk of malignancy.</li> <li>• Ocular abnormalities.</li> </ul> <p>Blepharitis and cataract:</p> <ul style="list-style-type: none"> <li>• Growth retardation.</li> <li>• May develop initially single cytopenia, severe diminution in megakaryocytes.</li> <li>• No abnormal chromosome fragility.</li> <li>• 80% evolve into aplastic anemia.</li> </ul>	<p>No specific treatment. Supportive line of treatment and treat the complications.</p>
 <p><b>Figures 10.4.4A and B:</b> Fanconi's anemia Photo Courtesy: MR Lokeshwar, Bharat Agarwal, Mumbai</p>	<p><i>Inherited aplastic anemia characterized by:</i></p> <ul style="list-style-type: none"> <li>• Perioral hyperpigmentation.</li> <li>• Café-au-lait spots.</li> <li>• Short stature, microcephaly, mental subnormality, skeletal abnormality.</li> <li>• Renal anomalies, hypogonadism</li> <li>• Deafness, ear malformation</li> <li>• GI anomalies</li> <li>• Cardiopulmonary anomalies</li> </ul> <p><i>Laboratory diagnosis:</i></p> <ul style="list-style-type: none"> <li>• Progressive anemia with pancytopenia, low retic count</li> <li>• Increased HbF and presence of I antigen.</li> </ul> <p>Bone marrow and trephine biopsy documents hypoplasia. Cytogenetics show chromosomal changes like break, condensation, gaps, re-arrangement, etc.</p>	<p>Without therapy 80% die before the age of 16 years or 2 to 4 years following aplasia:</p> <ul style="list-style-type: none"> <li>• Bone marrow transplantation is only the hope of long-term survival.</li> <li>• Traditional therapy is steroids, androgens—oxymethalone, nandralane alone or in combination.</li> <li>• Colony, stimulating factors like GCSF, erythropoietin, IL3, IL6.</li> </ul>


Picture	Note	Management
<p><b>Glanzmann's Thrombasthenia</b></p>  <p><b>Figure 10.4.5:</b> Glanzmann's thrombasthenia Photo Courtesy: MR Lokeshwar, Nitin Shah, Mumbai</p>	<p>It is one of the congenital platelet functional disorder associated with severe platelet dysfunction leading to prolonged bleeding time and normal platelet count. Aggregation studies shows abnormal or absent aggregation with all agonist except ristocetin. The disorder is caused by deficiency of platelet fibrinogen receptor GP2B-IIIa.</p>	<ul style="list-style-type: none"> <li>• In all but severe platelet function defects desmopresin 0.3 mcg/kg IV may be used for mild to moderate bleeding episodes.</li> <li>• Platelet transfusion—1 unit/5 to 10 kg corrects the defect in hemostasis and may be life-saving.</li> <li>• In severe cases recombinant factor VII A is effective.</li> <li>• Stem cell transplantation may be curative.</li> </ul>

### Henoch's Schönlein Purpura

 <p><b>Figure 10.4.6:</b> Henoch's schonlein purpura Photo Courtesy: MR Lokeshwar, Nitin Shah, Mumbai</p>	<p>It is a systemic vasculitis involving the small vessels capillaries, arterioles and venules with IgA-dominant immune deposits typically involve in skin, gut and glomeruli.</p> <p>It is characterized diffused abdominal pain, arthritis or arthralgia and renal involvement (hematuria/ proteinuria) in the presence palpable purpura.</p> <p>Biopsy showing predominant IgA deposition. This may be triggered by infections <i>Streptococcus</i>, <i>Yersinia</i>, <i>Mycoplasma</i>, <i>Toxoplasma</i>, <i>Varicella</i>, measles, HIV.</p>	<p>Treatment is essentially:</p> <ul style="list-style-type: none"> <li>• Symptomatic in mild cases, analgesics like paracetamol for the pain and antispasmodic for relief of abdominal pain.</li> <li>• When abdominal pain is severe small dose of steroid is useful.</li> </ul>
---	--	--

### Kasabach-Merritt Syndrome

 <p><b>Figures 10.4.7A and B:</b> Kasabach-Merritt syndrome Photo Courtesy: MR Lokeshwar, Nitin Shah, Mumbai</p>	<p>Association of giant hemangioma with localized intravascular coagulation causing thrombocytopenia and hypofibrinogenemia is called Kasabach-Merritt syndrome. Peripheral blood smear shows microangiopathic changes.</p>	<p>Multiple modalities have been tried such as:</p> <ul style="list-style-type: none"> <li>• High dose cortical steroids.</li> <li>• Local radiation therapy</li> <li>• Antiangiogenic agents: Interferon, laser photo coagulation.</li> <li>• Surgical excision.</li> </ul>
---	---	--

Picture	Note	Management
<p data-bbox="154 216 506 247"><b>Wiscott-Aldrich Syndrome</b></p>  <p data-bbox="164 833 540 909"><b>Figure 10.4.8:</b> Wiscott-Aldrich syndrome Photo Courtesy: MR Lokeshwar, Bharat Agarwal, Mumbai</p>	<p data-bbox="630 275 992 335">An X linked recessive syndrome characterized by:</p> <ul data-bbox="630 349 1040 560" style="list-style-type: none"> <li>• Atopic dermatitis.</li> <li>• Thrombocytopenic purpura. Small defective platelets with normal appearing megakaryocyte.</li> <li>• Undue susceptibility to infection.</li> <li>• Prolonged bleeding.</li> </ul> <p data-bbox="630 574 821 600">May manifest as:</p> <ul data-bbox="630 615 1036 860" style="list-style-type: none"> <li>• Bloody diarrhea during infancy.</li> <li>• Atopic dermatitis.</li> <li>• Recurrent infection.</li> <li>• The predominant immunoglobulin pattern is low level of IgM, elevated IgA and IgE and normal or slightly low IgG concentration.</li> </ul>	<ul data-bbox="1073 275 1446 560" style="list-style-type: none"> <li>• The patient should be given monthly infusion of IVIG.</li> <li>• Appropriate nutrition.</li> <li>• Use only killed vaccine.</li> <li>• Platelet transfusion for serious bleeding.</li> <li>• Bone marrow transplantation treatment of choice.</li> </ul>

# Section 11

---

# Oncology

## ***Section Editors***

Purna Kurkure, Anupama S Borker

## ***Photo Courtesy***

Purna Kurkure, Anupama S Borker, Leni Mathew, Sajid Qureshi, Sumeet Gujral

- 
- 11.1 Common Conditions
  - 11.2 Uncommon Conditions but not Rare
  - 11.3 Oncologic Emergencies
  - 11.4 Syndromes

## SECTION OUTLINE

### 11.1 COMMON CONDITIONS 211

- ◆ Abdominal Lump 211
- ◆ Askin Rosai Tumor 211
- ◆ Ependymoma 212
- ◆ Ewing's Sarcoma of Left Ulna 212
- ◆ Ewing's Sarcoma of Scapula 212
- ◆ Langerhans' Cell Histiocytosis—Proptosis 213
- ◆ Leukemia—Aspergillous Cavity in Lung 213
- ◆ Leukemia—Chickenpox in Acute Lymphoblastic Leukemia (ALL) Patient 213
- ◆ Leukemia—Extensive Thrush during Chemotherapy 214
- ◆ Leukemia—Gum Hypertrophy of AML M4 214
- ◆ Leukemia—Ichthyma Gangrenosum with Pneumonia 214
- ◆ Lymphoma—Burkitt's Lymphoma 215
- ◆ Lymphoma—Cervical Lymphadenopathy of Hodgkin's Lymphoma 215
- ◆ Lymphoma—Lymphoblastic Lymphoma 215
- ◆ Neuroblastoma—Adrenal—CT Scan 216
- ◆ Neuroblastoma—Proptosis at Diagnosis and after Treatment 216
- ◆ Neuroblastoma Stage IVs 216
- ◆ Neuroblastoma—Bone Marrow Infiltration 217
- ◆ Neuroblastoma—Bony Metastases 217
- ◆ Neuroblastoma—Pelvic Neuroblastoma 217
- ◆ Osteosarcoma of Lower End of Left Femur 218
- ◆ Osteosarcoma of Upper End of Left Humerus 218
- ◆ Retinoblastoma on CT Scan 218
- ◆ Retinoblastoma with Orbital Implant 219
- ◆ Retinoblastoma—Advanced Stage 219
- ◆ Retinoblastoma—Early Stage 219
- ◆ Retinoblastoma—Postenucleation Syndrome 220
- ◆ Rhabdomyosarcoma after Multiple Attempts at Surgery 220
- ◆ Rhabdomyosarcoma of Chest Wall 220
- ◆ Rhabdomyosarcoma of Left Parotid Region 221
- ◆ Rhabdomyosarcoma of Middle Ear Presenting as Facial Nerve Palsy 221

- ◆ Rhabdomyosarcoma—Bone Scan Showing Multiple Bony Metastases 221
- ◆ Rhabdomyosarcoma—Lung Metastases 222
- ◆ Rhabdomyosarcoma—Orbital 222
- ◆ Rhabdomyosarcoma—Vaginal Botryoid 222
- ◆ Sacrococcygeal Teratoma 223
- ◆ Therapeutics—Hickman Catheter for Leukemia Therapy 223
- ◆ Therapeutics—Necrotic Ulceration Following Vincristine Extravasation 223
- ◆ Therapeutics—Peripherally Inserted Central Catheters 224
- ◆ Therapeutics—Port-a-Cath 224
- ◆ Wilms' Tumor 224

### 11.2 UNCOMMON CONDITIONS BUT NOT RARE 225

- ◆ Atypical Teratoid Rhabdoid Tumor of the Brain 225
- ◆ Congenital Fibrosarcoma of the Foot 225
- ◆ Cystic Hygroma 225
- ◆ Desmoid Fibromatosis 226
- ◆ Hepatoblastoma 226
- ◆ Leukemia Cutis 226
- ◆ Leukemia—Bony Lesion in ALL 227
- ◆ Leukemia—Chloroma 227
- ◆ Lymphoma—Subcutaneous Nodules of Anaplastic Large Cell Lymphoma 227
- ◆ Lymphoma—Cutaneous T-Cell Lymphoma 228
- ◆ Lymphoma—Tonsillar Lymphoma 228
- ◆ Rhabdomyosarcoma of Right Cheek in a Patient with Microcephaly 228
- ◆ Thyroid Carcinoma in an Adolescent Female 229

### 11.3 ONCOLOGIC EMERGENCIES 229

- ◆ Acute Raised Intracranial Pressure 229
- ◆ Massive Pleural Effusion 229
- ◆ Mediastinal Lymphadenopathy 230

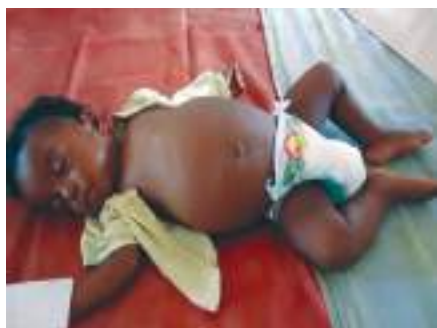### 11.4 SYNDROMES 230

- ◆ Down's Syndrome—AML M7 230
- ◆ Neurofibromatosis Type I with Malignant Peripheral Nerve Sheath Tumor 230

## 11.1 COMMON CONDITIONS

Picture	Note	Management
---------	------	------------

### Abdominal Lump

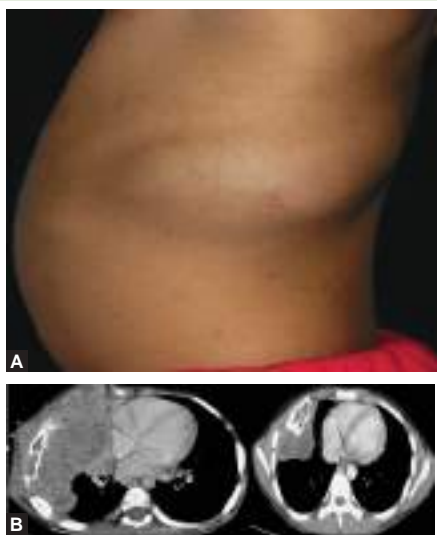


**Figure 11.1.1:** Abdominal lump  
Photo Courtesy: Anupama S Borker, Manipal

Malignant abdominal tumors are usually firm to hard. Wilms' tumor and neuroblastoma are common in younger patients; lymphomas predominate in older children. Pelvic masses extending into the abdomen are likely to be germ cell tumors or rhabdomyosarcoma.

Imaging with CT scan followed by biopsy or exploratory laprotomy to ascertain the diagnosis.

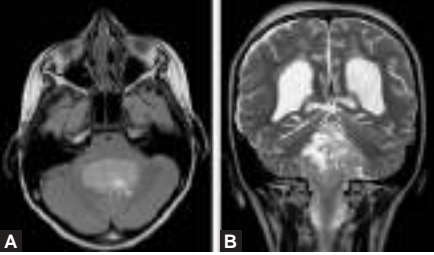

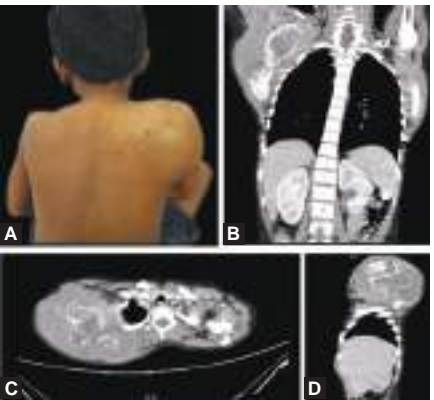
### Askin Rosai Tumor






**Figures 11.1.2A and B:** (A) Askin Rosai tumor;  
(B) Askin Rosai tumor: CT scan  
Photo Courtesy: Purna Kurkure, Mumbai




A 10 years old girl presented with cough and breathlessness. CT scan revealed soft tissue mass with rib erosion. Biopsy confirmed primitive neuroectodermal tumor of the chest wall (Askin Rosai Tumor).  
CT scan showing right chest wall mass with rib erosion.

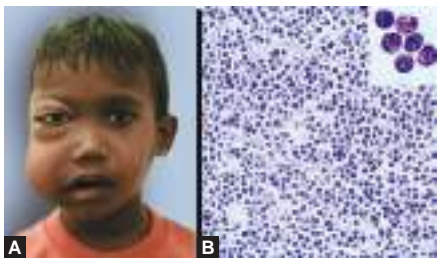

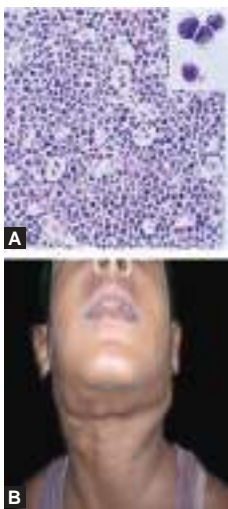
Chemotherapy with vincristine, ifosfamide and etoposide; alternating with vincristine, cyclophosphamide and doxorubicin leads to response enabling surgical resection followed by radiotherapy and maintenance chemotherapy.

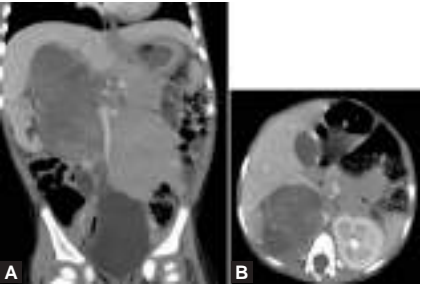

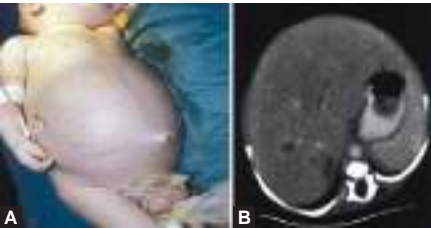
Picture	Note	Management
<b>Ependymoma</b>		
 <p data-bbox="164 547 570 600"><b>Figures 11.1.3A and B:</b> Ependymoma Photo Courtesy: Anupama S Borker, Manipal</p>	<p data-bbox="626 277 1037 431">A 12 year old girl presented with headache and vomiting. MRI brain showed a heterogeneously enhancing lesion filling the whole 4<sup>th</sup> ventricle with hydrocephalous.</p>	<p data-bbox="1070 277 1481 461">Craniotomy with excision. Histopathology revealed ependymoma. Adjuvant radiotherapy is recommended to the tumor bed. There is no defined role for chemotherapy.</p>
<b>Ewing's Sarcoma of Left Ulna</b>		
 <p data-bbox="164 1113 570 1193"><b>Figures 11.1.4A and B:</b> Ewing's sarcoma of left ulna Photo Courtesy: Anupama S Borker, Manipal</p>	<p data-bbox="626 850 1037 1160">A 16 years old girl presented with painless swelling of the forearm of two months duration. X-ray revealed a soft tissue mass with destruction of the underlying shaft of the ulna. Biopsy confirmed Ewing's sarcoma. Metastatic work-up with CT scan of the chest, bone scan and bone marrow aspiration and biopsy did not reveal any evidence of disease.</p>	<p data-bbox="1070 850 1481 1034">Neoadjuvant chemotherapy for 9 to 12 weeks followed by response evaluation; local therapy with surgery and/or radiation therapy followed by adjuvant maintenance chemotherapy.</p>
<b>Ewing's Sarcoma of Scapula</b>		
 <p data-bbox="164 1815 570 1894"><b>Figures 11.1.5A to D:</b> Scapular Ewing's Sarcoma Photo Courtesy: Anupama S Borker, Manipal</p>	<p data-bbox="626 1402 1037 1586">A 14 years boy with painless swelling of right shoulder and back. Biopsy revealed Ewing's sarcoma. CT chest, bone scan and bone marrow aspiration and biopsy did not reveal any evidence of spread.</p>	<p data-bbox="1070 1402 1481 1586">Neoadjuvant chemotherapy for 9 to 12 weeks followed by response evaluation followed by surgery and/or radiation therapy followed by adjuvant maintenance chemotherapy.</p>

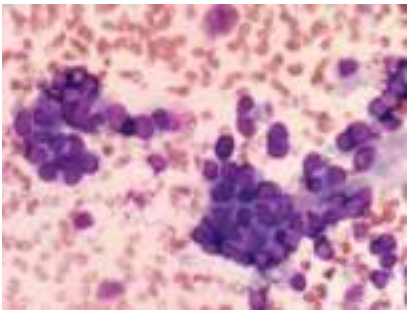
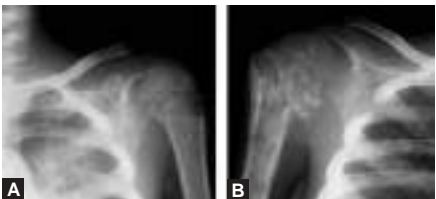

Picture	Note	Management
<b>Langerhans' Cell Histiocytosis—Proptosis</b>		
 <p data-bbox="138 629 542 701"><b>Figure 11.1.6:</b> Proptosis in Langerhans' cell histiocytosis <i>Photo Courtesy:</i> Purna Kurkure, Mumbai</p>	<p data-bbox="602 273 997 396">A 4 year old child with proptosis of left eye, biopsy of retro-orbital swelling revealed Langerhans' cell histiocytosis</p>	<p data-bbox="1045 273 1456 588">Staging investigations with skeletal survey, bone scan, CT scan of chest, abdomen and pelvis and bone marrow aspiration and biopsy will ascertain the extent of the disease. This disorder of immune dysregulation mimics malignancy and responds dramatically to chemotherapy with vinblastine and prednisone.</p>
<b>Leukemia—Aspergillous Cavity in Lung</b>		
 <p data-bbox="138 1205 558 1277"><b>Figures 11.1.7A and B:</b> Aspergillous cavity of the lung <i>Photo Courtesy:</i> Anupama S Borker, Manipal</p>	<p data-bbox="602 936 1013 1150">A 4 years old boy with acute lymphoblastic leukemia, completed induction chemotherapy, and developed cough, rhonchi and hypotension. Chest X-ray revealed left upper zone cavity, which was confirmed on CT scan.</p>	<p data-bbox="1045 936 1382 1028">Six week treatment with voriconazole led to complete resolution of the cavity.</p>
<b>Leukemia—Chickenpox in Acute Lymphoblastic Leukemia (ALL) Patient</b>		
 <p data-bbox="138 1835 542 1886"><b>Figure 11.1.8:</b> Chickenpox in ALL patient <i>Photo Courtesy:</i> Anupama S Borker, Manipal</p>	<p data-bbox="602 1492 1013 1604">Extensive chickenpox in immunocompromised child with acute lymphoblastic leukemia (ALL) during maintenance therapy.</p>	<p data-bbox="1045 1492 1456 1604">Immediate initiation of therapy with intravenous acyclovir at the onset helps curtail the crop of pox lesions and the risk of dissemination.</p>



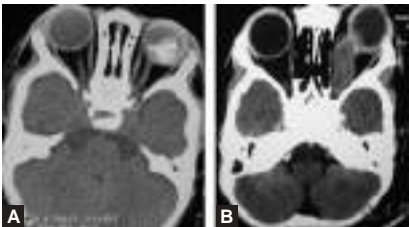


Picture	Note	Management
<b>Leukemia—Extensive Thrush during Chemotherapy</b>		
 <p data-bbox="164 588 537 660"><b>Figure 11.1.9:</b> Extensive thrush during leukemia chemotherapy <i>Photo Courtesy:</i> Purna Kurkure, Mumbai</p>	<p data-bbox="626 273 1013 492">Candida infection of the oral cavity is common in patients with leukemia. The risk factors for invasive fungal infection are prior colonization/infection, state of immunosuppression and organ dysfunction.</p>	<p data-bbox="1070 273 1403 363">Prevention of oral candidiasis by daily prophylactic use of clotrimazole.</p>
<b>Leukemia—Gum Hypertrophy of AML M4</b>		
 <p data-bbox="164 1156 581 1208"><b>Figure 11.1.10:</b> Gum hypertrophy of AML M4 <i>Photo Courtesy:</i> Anupama S Borker, Manipal</p>	<p data-bbox="626 842 1024 1091">A 12 years old girl presented with painful swelling and bleeding of gums of 3 weeks duration. CBC revealed Hb = 8 gm/dl, WBC count = 56,000/cmm, Platelet count = 48,000/cmm. Bone marrow aspiration revealed acute myeloid leukemia M4 type.</p>	<p data-bbox="1070 842 1463 932">Induction chemotherapy followed by 3 to 5 cycles of consolidation chemotherapy.</p>
<b>Leukemia—Ichthya Gangrenosum with Pneumonia</b>		
 <p data-bbox="164 1794 581 1866"><b>Figures 11.1.11A to D:</b> Ichthya gangrenosum with pneumonia <i>Photo Courtesy:</i> Anupama S Borker, Manipal</p>	<p data-bbox="626 1381 1040 1602">A 6 years old girl with acute lymphoblastic leukemia, on induction chemotherapy, developed necrotic lesion over the dorsum of the hand which then spread to the face and the hard palate. X-ray chest showed a right-sided pneumonia.</p>	<p data-bbox="1070 1381 1468 1504">Aggressive antibiotics with specific antipseudomonal coverage and debridement after neutropenia recovers.</p>

Picture	Note	Management
<p><b>Lymphoma—Burkitt's Lymphoma</b></p>  <p><b>Figures 11.1.12A and B:</b> Burkitt's lymphoma  <i>Photo Courtesy:</i> Purna Kurkure, Sumeet Gujral, Mumbai</p>	<p>A 7 years old boy presented with swelling of the right cheek of 2 months duration. Biopsy revealed Burkitt's lymphoma.</p>	<p>Bone marrow aspiration and biopsy and lumbar puncture is required for staging. Short duration intensive chemotherapy with good supportive care results in good survival.</p>
<p><b>Lymphoma—Cervical Lymphadenopathy of Hodgkin's Lymphoma</b></p>  <p><b>Figure 11.1.13:</b> Cervical lymphadenopathy of Hodgkin's lymphoma  <i>Photo Courtesy:</i> Purna Kurkure, Mumbai</p>	<p>Large cervical lymph node mass, growing slowly over 4 to 6 months, without constitutional symptoms like fever or weight loss. Biopsy revealed Hodgkin's lymphoma.</p>	<p>CT scan of neck, chest, abdomen and pelvis along with bone marrow biopsy for complete staging. Treatment with chemotherapy with or without radiotherapy depending on stage.</p>
<p><b>Lymphoma—Lymphoblastic Lymphoma</b></p>  <p><b>Figures 11.1.14A and B:</b> Lymphoblastic lymphoma  <i>Photo Courtesy:</i> Anupama S Borker, Manipal Sumeet Gujral, Mumbai</p>	<p>A 5 years old boy presented with generalized lymphadenopathy, with fever and weight loss. The differential diagnosis was leukemia and lymphoma. Biopsy revealed lymphoblastic lymphoma.</p>	<p>Bone marrow aspiration to ascertain marrow involvement, if present to treat as acute lymphoblastic leukemia.</p>


Picture	Note	Management
<b>Neuroblastoma—Adrenal—CT Scan</b>		
 <p data-bbox="164 574 599 649"><b>Figures 11.1.15A and B:</b> CT scan showing right adrenal neuroblastoma <i>Photo Courtesy:</i> Anupama S Borker, Manipal</p>	<p data-bbox="626 273 1037 717">A 2 years old boy presented with irritability, anorexia, pallor and abdominal distention. CT scan showed large tumor above the right kidney with corresponding uptake on MIBG scan. Biopsy confirmed neuroblastoma. Urine VMA was elevated. Bone scan and bone marrow were uninvolved. N-myc amplification by FISH on pretreatment biopsy paraffin block is crucial for optimal risk stratification as it dictates treatment protocol.</p>	<p data-bbox="1070 273 1481 527">Four cycles of multiagent chemotherapy with cyclophosphamide, doxorubicin, cisplatin and etoposide followed by response evaluation and complete excision of the mass with lymph node sampling; which is important milestone in the total management.</p>
<b>Neuroblastoma—Proptosis at Diagnosis and after Treatment</b>		
 <p data-bbox="164 1381 537 1481"><b>Figures 11.1.16A and B:</b> Proptosis in Neuroblastoma; at diagnosis and after starting treatment <i>Photo Courtesy:</i> Purna Kurkure, Mumbai</p>	<p data-bbox="626 835 967 921">Proptosis secondary to retro-orbital deposits is common in neuroblastoma.</p>	<p data-bbox="1070 835 1411 956">Initiation of chemotherapy after biopsy and staging leads to complete resolution of the proptosis.</p>
<b>Neuroblastoma Stage IVs</b>		
 <p data-bbox="164 1841 589 1909"><b>Figures 11.1.17A and B:</b> Neuroblastoma stage IVs <i>Photo Courtesy:</i> Purna Kurkure, Mumbai</p>	<p data-bbox="626 1592 1037 1815">Massive liver enlargement due to metastatic involvement in infantile neuroblastoma. This is stage IVs disease. If <i>Nmyc</i> amplification is absent, it falls in low-risk category because of favorable age and carries a very good prognosis.</p>	<p data-bbox="1070 1592 1411 1712">Minimal chemotherapy with oral cyclophosphamide and IV adriamycin or vincristine is sufficient.</p>

Picture	Note	Management
<b>Neuroblastoma—Bone Marrow Infiltration</b>		
 <p data-bbox="138 594 561 670"><b>Figure 11.1.18:</b> Bone marrow infiltration with neuroblastoma cells <i>Photo Courtesy:</i> Sumeet Gujral, Mumbai</p>	<p data-bbox="602 271 992 363">Bone marrow showing rosettes of abnormal cell infiltrates in patient with neuroblastoma.</p>	<p data-bbox="1045 271 1446 461">Management of stage IV neuroblastoma with chemotherapy leads to good early response which needs to be consolidated with high dose chemotherapy with stem cell rescue.</p>
<b>Neuroblastoma—Bony Metastases</b>		
 <p data-bbox="138 1146 561 1222"><b>Figures 11.1.19A and B:</b> Bony metastases in neuroblastoma <i>Photo Courtesy:</i> Purna Kurkure, Mumbai</p>	<p data-bbox="602 932 1019 1058">Bones and bone marrow are the most common sites of metastases in neuroblastoma. X-ray showing bony metastasis in humerus.</p>	<p data-bbox="1045 932 1458 1091">Prompt initiation of chemotherapy is advised after diagnosis and staging. Local radiotherapy is advised in painful bony lesion along with bisphosphonates.</p>
<b>Neuroblastoma—Pelvic Neuroblastoma</b>		
 <p data-bbox="138 1849 513 1905"><b>Figure 11.1.20:</b> Pelvic neuroblastoma <i>Photo Courtesy:</i> Purna Kurkure, Mumbai</p>	<p data-bbox="602 1490 1003 1549">Calcified mass in the pelvis. Biopsy confirmed neuroblastoma.</p>	<p data-bbox="1045 1490 1398 1582">If non-metastatic, surgical excision should be followed by chemotherapy.</p>


Picture	Note	Management
<p><b>Osteosarcoma of Lower End of Left Femur</b></p>  <p><b>Figures 11.1.21A and B:</b> Osteosarcoma of lower end of left femur Photo Courtesy: Purna Kurkure, Mumbai</p>	<p>A 12 years old boy presented with progressively enlarging swelling of left leg of 3 months duration. X-ray revealed typical “sunburst” or “sunray” appearance of the lower end of left femur with erosion of the underlying bone.</p>	<p>A carefully planned biopsy to confirm the histology should be followed by a metastatic work-up including CT scan of the chest and a bone scan. Neoadjuvant chemotherapy allows reduction in tumor volume along with control of micrometastases followed by definitive surgery followed by adjuvant chemotherapy.</p>
<p><b>Osteosarcoma of Upper End of Left Humerus</b></p>  <p><b>Figures 11.1.22A and B:</b> Osteosarcoma of upper end of left humerus Photo Courtesy: Anupama S Borker, Manipal</p>	<p>A 12 years old girl presented with painful swelling of left shoulder of 4 months duration. X-ray revealed new bone formation in and around the head of the humerus. Biopsy confirmed osteosarcoma. CT scan of the chest revealed multiple lung metastases.</p>	<p>Four cycles of chemotherapy followed by re-evaluation to assess the response of the primary tumor and the lung metastases.</p>
<p><b>Retinoblastoma on CT Scan</b></p>  <p><b>Figures 11.1.23A and B:</b> Retinoblastoma on CT scan Photo Courtesy: Purna Kurkure, Mumbai</p>	<p>CT scan showing retinoblastoma lesions within the globe and behind the globe.</p>	<p>For retinoblastoma lesions confined to the globe, chemotherapy offers the option of saving vision. For extensive lesions enucleation with radiotherapy and chemotherapy can control the disease and save life.</p>

Picture	Note	Management
---------	------	------------


### Retinoblastoma with Orbital Implant



 <p><b>Figures 11.1.24A and B:</b> Retinoblastoma with orbital implant <i>Photo Courtesy:</i> Sajid Qureshi, Mumbai</p>	<p>Baby with right eye retinoblastoma at diagnosis and a year later with orbital implant.</p>	<p>Orbital implants of various types are available and maybe free-floating, attached to the muscles or pegged within the socket.</p>
--	---	--




### Retinoblastoma—Advanced Stage

 <p><b>Figures 11.1.25A and B:</b> Advanced stage retinoblastoma <i>Photo Courtesy:</i> Sajid Qureshi, Mumbai</p>	<p>Loss of vision and exophytic growth mark the late stages of retinoblastoma.</p>	<p>Chemotherapy helps in regression of the tumor but the response is short lived and prognosis is poor.</p>
---	--	---

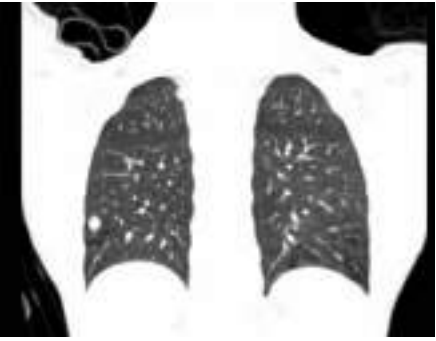


### Retinoblastoma—Early Stage

 <p><b>Figures 11.1.26A and B:</b> Early stage retinoblastoma <i>Photo Courtesy:</i> Sajid Qureshi, Mumbai</p>	<p>Leukocoria or white eye reflex is the most common presentation of retinoblastoma in its early stage.</p>	<p>Chemoreduction using neoadjuvant chemotherapy and local ophthalmic therapies to eradicate local disease help to maintain vision and have good prognosis.</p>
---	---	---




Picture	Note	Management
<b>Retinoblastoma—Postenucleation Syndrome</b>		
 <p data-bbox="164 598 537 670"><b>Figure 11.1.27:</b> Retinoblastoma—Postenucleation syndrome <i>Photo Courtesy:</i> Purna Kurkure, Mumbai</p>	<p data-bbox="626 273 1016 492">Enucleation is recommended for retinoblastoma when the disease is extensive and there is no useful vision. Enucleation without prosthesis for cosmesis, results in poor growth of the orbit and facial asymmetry.</p>	<p data-bbox="1070 273 1471 335">Prompt insertion of orbital implant can prevent such complications.</p>
<b>Rhabdomyosarcoma after Multiple Attempts at Surgery</b>		
 <p data-bbox="164 1154 573 1226"><b>Figure 11.1.28:</b> Rhabdomyosarcoma after multiple attempts at surgery <i>Photo Courtesy:</i> Anupama S Borker, Manipal</p>	<p data-bbox="626 829 1032 1017">A 14 years boy with painful swelling of the right arm, biopsy revealed alveolar rhabdomyosarcoma. He received 4 cycles of chemotherapy followed by multiple attempts at surgery.</p>	<p data-bbox="1070 829 1455 891">Noncross resistant chemotherapy and palliative radiotherapy.</p>
<b>Rhabdomyosarcoma of Chest Wall</b>		
 <p data-bbox="164 1800 597 1872"><b>Figures 11.1.29A to C:</b> Alveolar rhabdomyosarcoma of chest wall <i>Photo Courtesy:</i> Anupama S Borker, Manipal</p>	<p data-bbox="626 1375 1016 1692">A 12 years girl with swelling over the right anterior chest wall which was excised and has recurred within four weeks. Review of the excision biopsy revealed alveolar rhabdomyosarcoma. CT scan revealed 9 × 7 cm swelling arising from the pectoralis major muscle encasing the right subclavian vessels.</p>	<p data-bbox="1070 1375 1471 1631">Chemotherapy for 9 to 12 weeks followed by response evaluation followed by surgery and/or radiation therapy, further followed by maintenance chemotherapy. Prognosis will be guarded in view of prior surgical violation and unfavorable histology.</p>

Picture	Note	Management
<b>Rhabdomyosarcoma of Left Parotid Region</b>		
 <p data-bbox="138 609 548 684"><b>Figure 11.1.30:</b> Rhabdomyosarcoma of left parotid region <i>Photo Courtesy:</i> Anupama S Borker, Manipal</p>	<p data-bbox="602 271 1013 619">A 3 years girl with painless swelling of left parotid region of 4 weeks duration. CT scan revealed tumor arising from left parotid region with destruction of the underlying mandible. Biopsy revealed embryonal rhabdomyosarcoma. Metastatic work-up with CT chest, bone scan and bone marrow biopsy revealed multiple lung and bony metastases.</p>	<p data-bbox="1045 271 1445 527">Chemotherapy for 9 to 12 weeks followed by radiation therapy to all involved sites. Intent of therapy is palliative and not curative. Counseling of the family by pediatric oncologist and palliative care specialist before starting treatment is very essential.</p>
<b>Rhabdomyosarcoma of Middle Ear Presenting as Facial Nerve Palsy</b>		
 <p data-bbox="138 1167 578 1242"><b>Figure 11.1.31:</b> Facial nerve palsy as a presentation of rhabdomyosarcoma of middle ear <i>Photo Courtesy:</i> Anupama S Borker, Manipal</p>	<p data-bbox="602 803 1013 1089">A 5 years old girl presented with right lower motor neuron facial nerve palsy preceded by right ear pain of one week duration. CT scan revealed mass in the right middle ear extending into the mastoid cavity. Biopsy confirmed embryonal rhabdomyosarcoma. This is parameningeal site ERMS.</p>	<p data-bbox="1045 803 1445 1089">Metastatic work-up with CT scan chest, bone scan, bone marrow biopsy and diagnostic lumbar puncture. Neoadjuvant chemotherapy and early start of radiotherapy (ideally on day 1) followed by maintenance chemotherapy. Prognosis will depend on CSF involvement.</p>
<b>Rhabdomyosarcoma—Bone Scan Showing Multiple Bony Metastases</b>		
 <p data-bbox="138 1794 548 1870"><b>Figure 11.1.32:</b> Bone scan showing multiple bony metastases in rhabdomyosarcoma <i>Photo Courtesy:</i> Anupama S Borker, Manipal</p>	<p data-bbox="602 1361 1013 1483">Posterior view showing increased radiotracer uptake is in right sacroiliac joint, left distal femur and left proximal tibia.</p>	<p data-bbox="1045 1361 1445 1443">Systemic chemotherapy along with radiotherapy to painful bony metastases.</p>



Picture	Note	Management
<b>Rhabdomyosarcoma—Lung Metastases</b>		
 <p data-bbox="164 629 573 701"><b>Figure 11.1.33:</b> Lung metastases in rhabdomyosarcoma <i>Photo Courtesy:</i> Anupama S Borker, Manipal</p>	<p data-bbox="630 273 1040 400">Metastatic lesion from rhabdomyosarcoma of the middle ear. Lung metastases in solid tumors are generally subpleural in location.</p>	<p data-bbox="1073 273 1474 333">Lung only metastases respond well to chemotherapy.</p>
<b>Rhabdomyosarcoma—Orbital</b>		
 <p data-bbox="164 1242 573 1293"><b>Figure 11.1.34:</b> Orbital rhabdomyosarcoma <i>Photo Courtesy:</i> Anupama S Borker, Manipal</p>	<p data-bbox="630 862 1003 1116">Fleshy bulbous firm mass arising from lower eyelid, with rapid growth over three weeks. No constitutional symptoms. The swelling was minimally tender with erythematous overlying skin. Biopsy revealed alveolar rhabdomyosarcoma.</p>	<p data-bbox="1073 862 1442 1177">Staging work-up with CT scan of the chest, bone scan and bone marrow biopsy to determine extent of spread. Treatment with neoadjuvant chemotherapy followed by response evaluation and local therapy with surgery and/or radiotherapy. This is followed by maintenance chemotherapy.</p>
<b>Rhabdomyosarcoma—Vaginal Botryoid</b>		
 <p data-bbox="164 1798 537 1870"><b>Figure 11.1.35:</b> Vaginal botryoid rhabdomyosarcoma <i>Photo Courtesy:</i> Purna Kurkure, Mumbai</p>	<p data-bbox="630 1451 1003 1577">A 8 months old baby with typical grape like lesion at the vaginal orifice. Biopsy confirmed it to be botryoid rhabdomyosarcoma.</p>	<p data-bbox="1073 1451 1458 1671">Staging work-up with CT scan of chest and abdomen, with bone scan and bone marrow aspiration and biopsy. Chemotherapy causes shrinkage of the tumor mass enabling definitive surgery after a few cycles with good prognosis.</p>

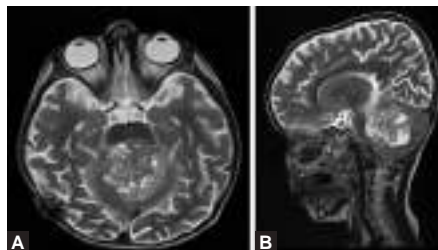
Picture	Note	Management
<p data-bbox="126 212 467 247"><b>Sacroccygeal Teratoma</b></p>  <p data-bbox="138 660 568 737"><b>Figure 11.1.36:</b> Sacroccygeal teratoma in an infant Photo Courtesy: Anupama S Borker, Manipal</p>	<p data-bbox="602 275 1016 466">A 3 months baby was brought with swelling over the gluteal region progressing since birth. CT scan confirmed sacroccygeal teratoma—type I with normal alpha-fetoprotein and B-hCG levels.</p>	<p data-bbox="1045 275 1458 337">Complete surgical excision followed by close follow-up.</p>
<p data-bbox="126 793 883 827"><b>Therapeutics—Hickman Catheter for Leukemia Therapy</b></p>  <p data-bbox="138 1295 548 1375"><b>Figure 11.1.37:</b> Hickman catheter for leukemia therapy Photo Courtesy: Anupama S Borker, Manipal</p>	<p data-bbox="602 854 1008 977">A 6 years old with acute myeloid leukemia with Hickman catheter <i>in situ</i> for easy and reliable long-term venous access.</p>	<p data-bbox="1045 854 1450 1038">Hickman and Broviac are long-term venous access catheters used in oncology patients for maintaining venous access for blood collections and administration of intravenous medication.</p>
<p data-bbox="126 1438 1078 1473"><b>Therapeutics—Necrotic Ulceration Following Vincristine Extravasation</b></p>  <p data-bbox="138 1800 557 1878"><b>Figure 11.1.38:</b> Necrotic ulceration following vincristine extravasation Photo Courtesy: Purna Kurkure, Mumbai</p>	<p data-bbox="602 1500 1019 1651">Certain chemotherapy drugs like vincristine, daunorubicin and doxorubicin are potent vesicants and cause severe tissue necrosis and ulceration if extravasated.</p>	<p data-bbox="1045 1500 1433 1815">Management of vincristine extravasation: Immediate cessation of IV infusion, aspiration of as much drug as possible from the extravasated site, elevation of concerned limb, warm compresses for 1 hour, application of hydrocortisone 1% cream twice daily, early surgical consultation of extensive necrosis.</p>

Picture	Note	Management
<b>Therapeutics—Peripherally Inserted Central Catheters</b>		
 <p data-bbox="164 527 589 609"><b>Figures 11.1.39A and B:</b> Peripherally inserted central catheters (PICC) <i>Photo Courtesy:</i> Anupama S Borker, Manipal</p>	<p data-bbox="626 273 976 363">Peripherally inserted central catheters (PICC) with infusion device.</p>	<p data-bbox="1070 273 1479 431">PICCs are easier to insert and are less expensive. They offer reliable venous access over a long period without the risk of extravasation and thrombophlebitis.</p>
<b>Therapeutics—Port-a-Cath</b>		
 <p data-bbox="164 1232 573 1289"><b>Figures 11.1.40A and B:</b> Port-a-Cath <i>Photo Courtesy:</i> Anupama S Borker, Manipal</p>	<p data-bbox="626 754 984 844">Port-a-Cath: Implantable long-term venous access device for chemotherapy administration.</p>	<p data-bbox="1070 754 1487 911">“Port-a-Caths” are useful in patients with solid tumors for administration of intravenous chemotherapy. They do not need frequent flushing and maintenance at home.</p>
<b>Wilms’ Tumor</b>		
 <p data-bbox="164 1794 573 1853"><b>Figure 11.1.41:</b> Wilms’ tumor <i>Photo Courtesy:</i> Anupama S Borker, Manipal</p>	<p data-bbox="626 1418 1040 1671">A 2 years boy presented with painless abdominal distention. CT scan revealed large tumor arising from the superior pole of the right kidney. CT-guided biopsy confirmed Wilms’ tumor. Chest X-ray and CT scan were normal confirming non-metastatic disease.</p>	<p data-bbox="1070 1418 1487 1704">Neoadjuvant chemotherapy for six weeks with vincristine and actinomycin D results in brisk response enabling successful nephrectomy, avoiding the risk of rupture. This is followed by adjuvant chemotherapy. The need for radiotherapy depends on the surgical pathological stage.</p>

## 11.2 UNCOMMON CONDITIONS BUT NOT RARE

Picture	Note	Management
---------	------	------------

### Atypical Teratoid Rhabdoid Tumor of the Brain



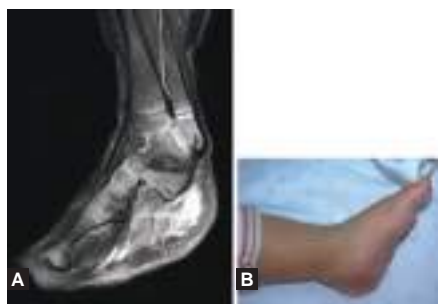**Figures 11.2.1A and B:** Atypical teratoid rhabdoid tumor of brain

*Photo Courtesy:* Anupama S Borker, Manipal

A 2 years old boy presented with unsteadiness of gait and progressive weakness of one month duration. He had truncal ataxia, hypotonia and nystagmus. MRI revealed large enhancing mass in the midline in the posterior cranial fossa.

Complete tumor resection was attempted. Histopathology revealed atypical teratoid rhabdoid tumor of the brain. It is a rare tumor with a grave prognosis. Intensive chemotherapy with radiotherapy has improved survival over the last decade.

### Congenital Fibrosarcoma of the Foot



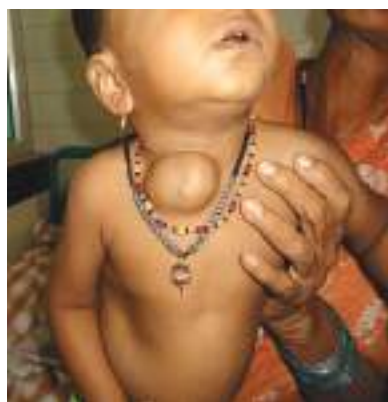**Figures 11.2.2A and B:** Congenital fibrosarcoma of the foot

*Photo Courtesy:* Anupama S Borker, Manipal

A 28 days old baby presented with painless swelling of the left foot noticed since day 8 of life and increasing in size, without any constitutional symptoms. MRI revealed soft tissue mass arising from the deep muscles of the flexor aspect of the foot. Biopsy confirmed congenital fibrosarcoma.

Chemotherapy with vincristine and actinomycin D given for 12 weeks led to complete remission and was followed by 8 more weeks of chemotherapy without the need for mutilating surgery.

### Cystic Hygroma


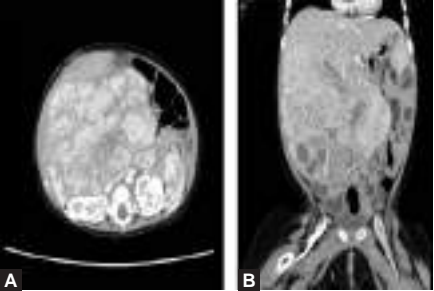




**Figure 11.2.3:** Cystic hygroma

*Photo Courtesy:* Anupama S Borker, Manipal


A 11 months old boy with a soft swelling over the upper part of the chest since birth. The swelling was soft, nontender with a positive transillumination sign.

Excision surgery was performed. Histopathology confirmed cystic hygroma.


Picture	Note	Management
<p><b>Desmoid Fibromatosis</b></p>  <p><b>Figures 11.2.4A and B:</b> Desmoid fibromatosis Photo Courtesy: Anupama S Borker, Manipal</p>	<p>A 12 years old girl with firm to hard mass on the right side of the back medial to the right scapula, growing slowly over 6 months.</p>	<p>Biopsy and imaging with MRI scan. Surgical excision if feasible with wide margins.</p>
<p><b>Hepatoblastoma</b></p>  <p><b>Figures 11.2.5A and B:</b> Hepatoblastoma Photo Courtesy: Anupama S Borker, Manipal</p>	<p>A 10 months old girl was brought with painless distention of the abdomen over four months along with failure to thrive. CT scan revealed large tumor arising from the liver. Alpha-fetoprotein level was 36000 ng/ml. Liver biopsy revealed hepatoblastoma of mixed type.</p>	<p>Neoadjuvant chemotherapy with cisplatin and doxorubicin, or cisplatin, vincristine and 5 FU leads to tumor regression enabling tumor resection.</p>
<p><b>Leukemia Cutis</b></p>  <p><b>Figure 11.2.6:</b> Leukemia cutis Photo Courtesy: Anupama S Borker, Manipal</p>	<p>A 4 years old girl presented with erythematous painless swelling anterior to the left ear, of 5 weeks duration. Biopsy of left upper cervical lymph node was consistent with lymphoblastic lymphoma. Bone marrow aspiration revealed marrow involvement with 32% blasts.</p>	<p>Initiation of chemotherapy according to acute lymphoblastic leukemia protocol resulted in clearing of the lesion within 1 week.</p>




Picture	Note	Management
<p><b>Leukemia—Bony Lesion in ALL</b></p>  <p><b>Figures 11.2.7A and B:</b> Bony lesion in ALL Photo Courtesy: Anupama S Borker, Manipal</p>	<p>A 13 months old girl with painful swelling of the left temporal region of four weeks duration, along with constitutional symptoms of anorexia, weakness and weight loss.</p>	<p>CT scan showed infiltrating lesion arising from temporal bone without breach of the underlying dura. Biopsy revealed infiltration by lymphoblasts. Bone marrow aspiration showed marrow replacement by lymphoblasts confirming the diagnosis of acute lymphoblastic leukemia.</p>


### Leukemia—Chloroma

 <p><b>Figure 11.2.8:</b> Chloroma Photo Courtesy: Anupama S Borker, Manipal</p>	<p>A rapidly growing swelling of the left eye over 3 weeks, with preservation of vision till a week prior to presentation. No constitutional symptoms.</p>	<p>CT scan showed extraocular tumor arising from eyelid with intact eyeball. Biopsy revealed extramedullary myeloid cell tumor (chloroma). Bone marrow aspiration and biopsy did not reveal any evidence of leukemia. Treatment similar to treatment of acute myeloid leukemia.</p>
--	--	---

### Lymphoma—Subcutaneous Nodules of Anaplastic Large Cell Lymphoma

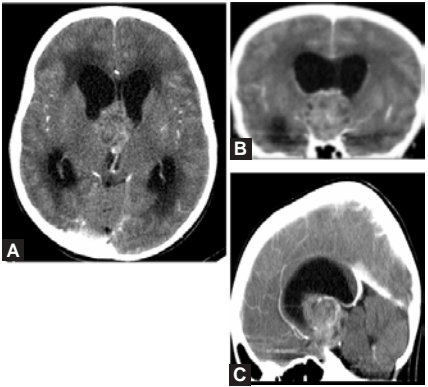
 <p><b>Figure 11.2.9:</b> Subcutaneous nodules of anaplastic large cell lymphoma Photo Courtesy: Anupama S Borker, Manipal</p>	<p>A 15 years girl presented with multiple painful swellings over the back, arms and legs of 2 weeks duration with constitutional features of fever, anorexia and weight loss. CT scan revealed multiple enlarged retroperitoneal and mesenteric lymph nodes. Biopsy revealed anaplastic large cell lymphoma.</p>	<p>Six to eight cycles of multiagent chemotherapy with intrathecal chemotherapy.</p>
---	---	--

Picture	Note	Management
<b>Lymphoma—Cutaneous T-Cell Lymphoma</b>		
 <p data-bbox="164 578 573 629"><b>Figure 11.2.10:</b> Cutaneous T-cell lymphoma Photo Courtesy: Leni Mathew, Vellore</p>	<p data-bbox="626 273 1044 431">A 10 years old girl presented with fever and multiple erythematous lesions over the abdomen and chest. Skin biopsy revealed cutaneous T-cell lymphoma.</p>	<p data-bbox="1070 273 1487 560">Localized lesions can be treated with topical corticosteroids and phototherapy, whereas systemic therapy is needed for generalized lesions. This patient was treated with 6 cycles of chemotherapy with CHOP regimen (cyclophosphamide, doxorubicin, vincristine and prednisone).</p>
<b>Lymphoma—Tonsillar Lymphoma</b>		
 <p data-bbox="164 1279 581 1330"><b>Figures 11.2.11A and B:</b> Tonsillar lymphoma Photo Courtesy: Anupama S Borker, Manipal</p>	<p data-bbox="626 784 1036 1038">A 11 years old girl presented with 2 weeks history of odynophagia. A biopsy of the mass on the left tonsillar fossa revealed non-Hodgkin's lymphoma—diffuse large B-cell type. Staging work-up did not reveal evidence of disease elsewhere.</p>	<p data-bbox="1070 784 1463 911">Intense multiagent chemotherapy for 6–8 cycles is the treatment. In case of good early response, radiation therapy is not needed.</p>
<b>Rhabdomyosarcoma of Right Cheek in a Patient with Microcephaly</b>		
 <p data-bbox="164 1784 573 1864"><b>Figure 11.2.12:</b> Rhabdomyosarcoma of right cheek in an infant with microcephaly Photo Courtesy: Anupama S Borker, Manipal</p>	<p data-bbox="626 1449 1019 1637">A 9 months old infant with microcephaly presented with painless swelling of right side of the face of four months duration. Biopsy revealed alveolar rhabdomyosarcoma.</p>	<p data-bbox="1070 1449 1398 1510">Staging work-up followed by neoadjuvant chemotherapy.</p>


Picture	Note	Management
<p><b>Thyroid Carcinoma in an Adolescent Female</b></p>  <p><b>Figure 11.2.13:</b> Thyroid carcinoma in adolescent female <i>Photo Courtesy:</i> Purna Kurkure, Mumbai</p>	<p>A 17 years old girl presented with swelling in the region of the thyroid gland of four months duration. Biopsy revealed follicular thyroid carcinoma.</p>	<p>Total thyroidectomy followed by <math>I^{131}</math> scan postsurgery to rule out residual or metastatic disease. If there is residual/metastatic disease, treatment with mega dose <math>I^{131}</math> therapy. Lifelong thyroxine supplementation and monitoring is essential part of management.</p>

### 11.3 ONCOLOGIC EMERGENCIES


#### Acute Raised Intracranial Pressure

 <p><b>Figures 11.3.1A to C:</b> Acute raised intracranial pressure <i>Photo Courtesy:</i> Anupama S Borker, Manipal</p>	<p>A 13 years old boy presented with right hemiparesis, right ptosis and diplopia of 2 days duration with history of polyphagia, polyuria and enuresis over the preceding 3 months. CT scan revealed mass in suprasellar and sellar region with calcification and necrosis with moderate hydrocephalus and periventricular lucencies.</p>	<p>Emergency tumor excision with VP shunt insertion was performed. Histopathology revealed mixed germ cell tumor. Adjuvant radiotherapy with chemotherapy leads to very good outcomes.</p>
--	---	--

#### Massive Pleural Effusion

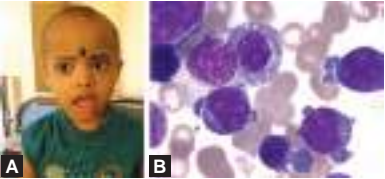
 <p><b>Figure 11.3.2:</b> Massive pleural effusion <i>Photo Courtesy:</i> Anupama S Borker, Manipal</p>	<p>A 13 years girl presented with left-sided chest pain and cough of 4 days duration. Emergency thoracocentesis revealed malignant cells. CT scan revealed large pleural effusion with large pleural-based masses, biopsy of which confirmed rhabdomyosarcoma.</p>	<p>Chemotherapy with 4–6 cycles of vincristine, cyclophosphamide, doxorubicin alternating with ifosphamide and etoposide followed by response evaluation and later followed by local therapy.</p>
--	--	---




Picture	Note	Management
<b>Mediastinal Lymphadenopathy</b>		
	<p>Mediastinal mass in a 11 years old boy who presented with cough and breathlessness of four days duration.</p>	<p>Complete blood count with peripheral smear examination and bone marrow aspiration to be done without sedation in semi-upright position to rule out leukemia. Mediastinal mass biopsy to be attempted if diagnosis still not obtained.</p>
<p><b>Figure 11.3.3:</b> Mediastinal lymphadenopathy  <i>Photo Courtesy:</i> Anupama S Borker, Manipal</p>		

## 11.4 SYNDROMES

### Down's Syndrome—AML M7

	<p>Down's syndrome predisposes to leukemia—acute myeloid leukemia AML M7 being common.</p>	<p>Chemotherapy for AML, with dose reduction as these patients are very sensitive to chemotherapy.</p>
<p><b>Figures 11.4.1A and B:</b> Down's syndrome—AML M7  <i>Photo Courtesy:</i> Anupama S Borker, Manipal Sumeet Gujral, Mumbai</p>		

### Neurofibromatosis Type I with Malignant Peripheral Nerve Sheath Tumor

	<p>A 10 years old boy with neurofibromatosis type I presented with a painful swelling on back growing over six months. Histopathology of the excised swelling revealed malignant peripheral nerve sheath tumor. Tumor recurred within weeks of excision.</p>	<p>Malignant peripheral nerve sheath tumors are treated with surgery and radiotherapy. Chemotherapy has limited role.</p>
<p><b>Figure 11.4.2:</b> Neurofibromatosis type I with malignant peripheral nerve sheath tumor  <i>Photo Courtesy:</i> Anupama S Borker, Manipal</p>		

## Section 12

---

# Endocrinology

### *Section Editors*

Vaman Khadilkar, PSN Menon

### *Photo Courtesy*

Anju Virmani, Bhanukiran Bhakhri, Sangeeta Yadav,  
Vaishakhi Rustagi, Vaman Khadilkar, Vandana Jain

- 
- 12.1 Common Conditions
  - 12.2 Uncommon Conditions but not Rare
  - 12.3 Endocrine Emergencies
  - 12.4 Syndromes

## SECTION OUTLINE

### 12.1 COMMON CONDITIONS 233

- ◆ Acanthosis 233
- ◆ Addison's Disease 233
- ◆ Atypical Genitalia, Both Gonads Palpable, Androgen Insensitivity Syndrome 233
- ◆ Atypical Genitalia, Clitoral Hypertrophy—No Palpable Gonads 234
- ◆ Atypical Genitalia—Very Ambiguous—Peroscrotal Transposition 234
- ◆ Buried Penis 234
- ◆ Congenital Adrenal Hyperplasia 235
- ◆ Craniopharyngioma 235
- ◆ Cushing—Iatrogenic 235
- ◆ Cushing Disease—Pituitary Microadenoma 236
- ◆ DI—MRI Showing Absent Postpituitary Gland in Central Diabetes Insipidus 236
- ◆ Diabetes—Microvascular Complications Small Joint Involvement 236
- ◆ Goiter—Autoimmune 237
- ◆ Goiter—Dyshormonogenesis 237
- ◆ Growth Hormone Deficiency 237
- ◆ Gynecomastia—Klinefelter Syndrome 238
- ◆ Gynecomastia—Puberty 238
- ◆ Hemihypertrophy—Beckwith-Wiedemann Syndrome 238
- ◆ Hypothyroidism—Congenital 239
- ◆ Hypothyroidism—Juvenile 239
- ◆ Lipohypertrophy due to Insulin 239
- ◆ Mauriac Syndrome 240
- ◆ Micropenis 240
- ◆ Mucopolysaccharidoses 240
- ◆ Obesity—Simple 241
- ◆ Orchidometer 241
- ◆ PHHI—Hairy Pinna 241
- ◆ Precocious Puberty—Central with Hypothalamic Hamartoma 242
- ◆ Pseudoprecocious Puberty and Hypertension in a Boy—CAH 242
- ◆ Renal Tubular Acidosis (RTA)—Failure to Thrive 242
- ◆ Skeletal Dysplasia 243
- ◆ Stadiometer and Infantometer 243
- ◆ Stretched Penile Length—Method 243
- ◆ Thelarche—Benign 244

- ◆ Vitamin D Resistant Rickets (VDRR) 244
- ◆ 2007 Growth Charts—Affluent Indian Boys Stature and Weight 245
- ◆ 2007 Growth Charts—Affluent Indian Girls Stature and Weight 246
- ◆ 2007 Growth Charts—Affluent Indian Boys BMI 247
- ◆ 2007 Growth Charts—Affluent Indian Girls BMI 248

### 12.2 UNCOMMON CONDITIONS BUT NOT RARE 249

- ◆ Adrenal Hypoplasia Congenita 249
- ◆ Cushing's Syndrome—Adrenal Tumor 249
- ◆ Graves' Disease 249
- ◆ Hypoparathyroidism Causing Carpalpedal Spasm 250
- ◆ Hypothyroidism Causing Pituitary Mass 250
- ◆ Langer Syndrome 250
- ◆ Langerhan's Cell Histiocytosis (LCH) Causing DI 251
- ◆ Macro-Orchidia in Hypothyroidism 251
- ◆ Nonclassical Congenital Adrenal Hyperplasia (CAH) 251
- ◆ Peripheral Pseudoprecocious Puberty 252
- ◆ Polycystic Ovary Syndrome (PCOS) 252
- ◆ Prolactinoma—Disappearing with Cabergoline Treatment 252
- ◆ Pseudoprecocious Puberty Caused by Hypothyroidism 253
- ◆ Thyroglossal Cyst 253


### 12.3 ENDOCRINE EMERGENCIES 253

- ◆ Congenital Adrenal Hyperplasia (CAH) Salt Wasting Crisis 253
- ◆ Disorder of Sexual Development (DSD) 254
- ◆ Persistent Hyperinsulinemic Hypoglycemia of Newborn 254


### 12.4 SYNDROMES 254

- ◆ Laron Dwarfism—Growth Hormone Insensitivity Syndrome 254
- ◆ Lawrence-Moon-Biedl (LMB) Syndrome 255
- ◆ McCune-Albright Syndrome 255
- ◆ Noonan Syndrome 255
- ◆ Prader-Willi Syndrome 256
- ◆ Russell-Silver Syndrome 256
- ◆ SHOX Gene Defect 256
- ◆ Turner Syndrome 257


## 12.1 COMMON CONDITIONS




Picture	Note	Management
<p><b>Acanthosis</b></p>  <p><b>Figure 12.1.1:</b> Acanthosis <i>Photo Courtesy:</i> Vaman Khadilkar, Pune</p>	<p>Obesity leads to a myriad of secondary effects such as insulin resistance seen here as acanthosis. This is a harbinger for type 2 diabetes which is seen at younger and younger ages now. Dyslipidemia is commonly associated with insulin resistance.</p>	<p>There is no specific treatment for acanthosis. Weight loss will reduce insulin resistance and thus acanthosis. Insulin resistance needs to be proved by fasting glucose and insulin values. HOMA index is calculated as <math>(\text{Glucose in mg} \times \text{insulin in iu/ml})/405</math>. If HOMA is higher than 2.5 before or 4.5 after puberty, Metformin is indicated.</p>

## Addison's Disease

 <p><b>Figure 12.1.2:</b> Addison's disease—Tongue and lip pigmentation <i>Photo Courtesy:</i> Vaman Khadilkar, Pune</p>	<p>Adrenal failure can be caused by a variety of congenital and acquired causes. Acquired causes are autoimmune adrenal damage, isolated or as part of polyendocrinopathy, tuberculosis, adrenoleukodystrophy and AAA syndrome. Congenital adrenal hypoplasia is caused by a variety of genetic defects such as DAX1 which is associated with hypogonadotropic hypogonadism.</p>	<p>Addison disease can present with addisonian crisis which is a medical emergency. The management of acute crisis which presents with hypoglycemia, hyponatremia and hyperkalemia is intravenous hydrocortisone in a dose of 2.5 mg/kg/dose 6 to 8 hourly, followed by oral hydrocortisone and fludrocortisone in a dose of 10 to 15 mg/m<sup>2</sup> per day.</p>
---	--	---

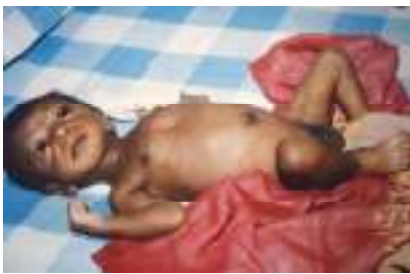## Atypical Genitalia, Both Gonads Palpable, Androgen Insensitivity Syndrome

 <p><b>Figure 12.1.3:</b> Atypical genitalia, androgen insensitivity syndrome <i>Photo Courtesy:</i> Bhanukiran Bhakhri, New Delhi</p>	<p>Atypical genitalia where both gonads are palpable usually come under the category of 46 XY DSD. There is usually a disorder of testosterone synthesis or action such as androgen insensitivity syndrome.</p>	<p>Treatment depends upon the cause. Response to androgen therapy in the first few weeks helps in gender assignment. In partial androgen insensitivity and 5 alpha reductase deficiency there is response to treatment in the form of increased phallic growth.</p>
--	---	---

Picture	Note	Management
<b>Atypical Genitalia, Clitoral Hypertrophy—No Palpable Gonads</b>		
 <p data-bbox="96 606 515 681"><b>Figure 12.1.4:</b> Clitoral hypertrophy no palpable gonads <i>Photo Courtesy:</i> Vaman Khadilkar, Pune</p>	<p data-bbox="540 304 937 479">Atypical genitalia where clitoral hypertrophy is seen but no gonads are palpable is usually seen in 46 XX DSD. The most common cause of this condition is congenital adrenal hyperplasia.</p>	<p data-bbox="962 304 1345 510">Atypical genitalia is a pediatric psychosocial emergency. Management is always multidisciplinary. Patients with DSD should be done in centers where teams are trained to look after such cases.</p>
<b>Atypical Genitalia—Very Ambiguous—Penoscrotal Transposition</b>		
 <p data-bbox="96 1191 515 1262"><b>Figure 12.1.5:</b> Atypical genitalia, penoscrotal transposition <i>Photo Courtesy:</i> Vaman Khadilkar, Pune</p>	<p data-bbox="540 885 937 1060">Atypical genitalia can be sometimes extremely ambiguous. As seen in this case there is penoscrotal transposition. Such severe abnormalities are often associated with other systemic abnormalities.</p>	<p data-bbox="962 885 1345 1090">Such severe malformations may not always be amenable to medical and surgical therapy. In severe syndromic cases with other severe systemic abnormalities fatalities are common and holistic approach to management is needed.</p>
<b>Buried Penis</b>		
 <p data-bbox="96 1735 515 1784"><b>Figure 12.1.6:</b> Buried Penis <i>Photo Courtesy:</i> Vaman Khadilkar, Pune</p>	<p data-bbox="540 1429 937 1604">The concealed buried penis is a normally developed penis that is camouflaged by the suprapubic fat pad. This is usually a result of obesity or rarely may be congenital or iatrogenic after circumcision.</p>	<p data-bbox="962 1429 1345 1634">Treatment of obesity in the form of dietary adjustments and physical exercise is needed. Surgical correction is rarely indicated for cosmetic reasons or if there is a functional abnormality with a splayed stream.</p>

Picture	Note	Management
---------	------	------------

### Congenital Adrenal Hyperplasia

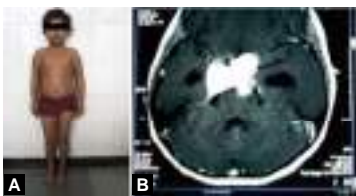


**Figure 12.1.7:** Congenital adrenal hyperplasia. Hyperpigmented nipples, umbilicus and genitals, failure to thrive  
Photo Courtesy: Vaman Khadilkar, Pune

Most common cause of 46 XX DSD. Affected females are easily identified due to atypical genitalia at birth. Males often remain undiagnosed for first few years and may present with pseudoprecocious puberty. The salt wasting variety manifests with Addisonian crisis manifested by low Na, High K and hypoglycemia, vomiting and failure to thrive. 21 Hydroxylase deficiency is the most common cause.

Oral replacement with Hydrocortisone in a dose of 10 to 15mg/m<sup>2</sup>/day in 3 divided doses. In the salt wasting variety fludrocortisone is added in a dose of 100 mg/m<sup>2</sup>/day as a daily dose. The dose of fludrocortisone is higher in the first year of life.

### Craniopharyngioma

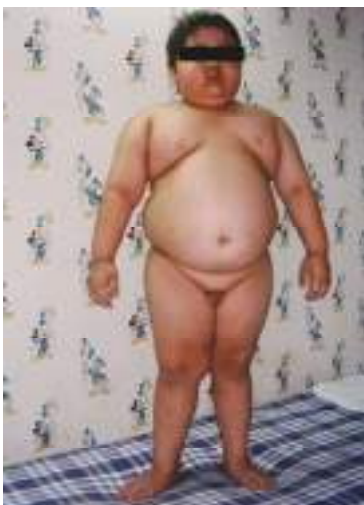

**Figures 12.1.8A and B:** (A) Craniopharyngioma in 14-year-old girl; (B) Craniopharyngioma  
Photo Courtesy: Vaman Khadilkar, Pune

Craniopharyngioma accounts for about 10% of brain tumors in childhood. It generally has a solid and cystic component. There is significant morbidity including hormonal pathologies. Common endocrinopathies are growth hormone deficiency, TSH, ACTH deficiency and DI.

There is controversy regarding relative roles of radiotherapy and surgery. Pre and postoperative hormonal replacement is important in the management. Postoperative DI should be anticipated and can be challenging.


### Cushing—Iatrogenic



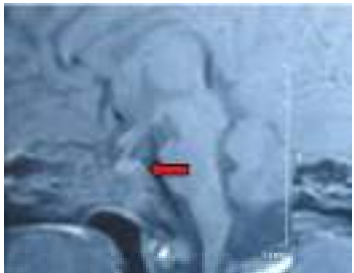
**Figure 12.1.9:** Iatrogenic Cushing  
Photo Courtesy: Vaman Khadilkar, Pune

Use of corticosteroids for conditions such as Nephrotic syndrome or juvenile chronic arthritis causes iatrogenic Cushing. This is reversible on stopping steroids. Unjustified use of steroid drops and tablets in our country is not an uncommon cause of this condition.


Careful history gives important clues to the diagnosis. Once the steroid is tapered off, signs and symptoms slowly reduce but may persist for many months.

Picture	Note	Management
<p><b>Cushing Disease—Pituitary Microadenoma</b></p>  <p><b>Figures 12.1.10A and B:</b> (A) Cushing disease; (B) Pituitary microadenoma Photo Courtesy: Vaman Khadilkar, Pune</p>	<p>The term refers to Cushing caused by pituitary-hypothalamic disorder of excess ACTH secretion leading to cortisol excess. Dusky complexion, short stature, proximal myopathy, central obesity, moon face and hypertension are common.</p>	<p>If pituitary microadenoma can be located transnasal surgery is the treatment of choice. Medical treatment by cabergoline is not very effective.</p>

### DI—MRI Showing Absent Postpituitary Gland in Central Diabetes Insipidus

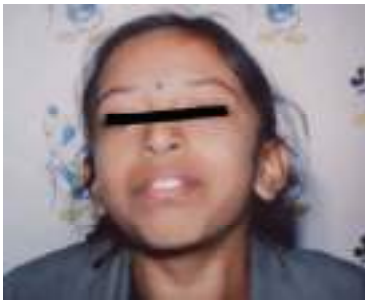 <p><b>Figure 12.1.11:</b> Absent bright postpituitary spot in central diabetes insipidus Photo Courtesy: Vaman Khadilkar, Pune</p>	<p>Central diabetes insipidus is caused by lack of antidiuretic hormone secreted from the posterior pituitary gland. This leads to pathological polyuria (<math>&gt;2L/m^2/24</math> hours). Normally posterior pituitary is seen as a bright spot on T1 weighted images. Note the absence of posterior pituitary bright spot in the picture.</p>	<p>Central diabetes is treated by long acting vasopressin analogue dDAVP (Desmopressin) either as nasal spray or oral tablets at 8 to 12 hourly interval.</p>
--	---	---

### Diabetes—Microvascular Complications Small Joint Involvement

 <p><b>Figure 12.1.12:</b> Syndrome of limited joint mobility in type 1 diabetes Photo Courtesy: Vaman Khadilkar, Vaishakhi Rustagi, Pune</p>	<p>Poor glycemic control leads to the syndrome of limited joint mobility. Note the stiffness of small joints of the hands shown in the picture. This is frequently associated with the early development of diabetic microvascular complications, such as retinopathy and nephropathy.</p>	<p>Improved diabetes control with home glucose monitoring, intensive insulin regime, proper nutrition and exercise is necessary to prevent further complications.</p>
---	--	---

Picture	Note	Management
---------	------	------------

### Goiter—Autoimmune



**Figure 12.1.13:** Goiter  
Photo Courtesy: Vaman Khadilkar, Pune

Most commonly caused by autoimmune thyroiditis. More common in girls. Uniform bosselated swelling, firm in consistency. Auto-immune thyroid disease is seen families with vertical transmission.

*Thyroid function tests and anti-thyroid antibodies must be checked before dismissing goiter as puberty goiter.*

If hypothyroid then Levothyroxine. If thyroid function tests are normal but the goiter is large, Levothyroxine can be used for 6 months to reduce the size of the goiter.

If antibody positive but euthyroid then annual assessment of thyroid function is suggested.

### Goiter—Dyshormonogenesis

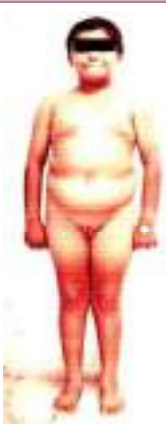

**Figure 12.1.14:** Goiter—Dyshormonogenesis  
Photo Courtesy: Vaman Khadilkar, Pune

Goiter seen within same sibship is usually due to dyshormonogenesis. These goiters are moderate in size and softer than seen in auto-immune variety. If these patients are detected by neonatal screening and treated from early age, goiter may not develop. Perchlorate discharge test is diagnostic. Hearing should be checked.

Levothyroxine in the dose of 100 mcg per meter sq. of body surface area per day is recommended.

### Growth Hormone Deficiency



**Figure 12.1.15:** Growth hormone deficiency  
Photo Courtesy: Vaman Khadilkar, Pune

Typical features are severe short stature, immature look, mid facial hypoplasia, micropenis, delayed puberty and central obesity.

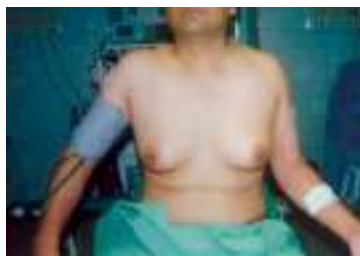Growth hormone stimulation test with insulin, clonidine, and arginine in specialized centers is recommended. A combination of IGF-1, IGF-BP3, Stimulated GH value and MRI improves the specificity of diagnostic tests.

Growth hormone therapy from diagnosis till adult stature is reached. The dose used is 20 to 30 mcg/kg/day.



Picture	Note	Management
---------	------	------------

### Gynecomastia—Klinefelter Syndrome



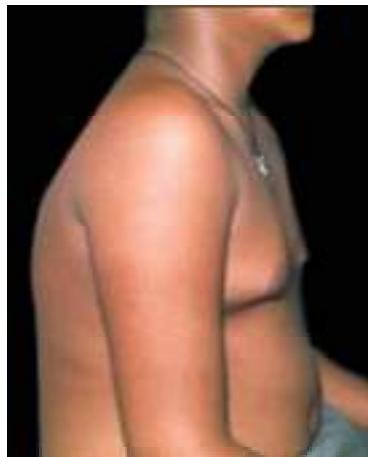**Figure 12.1.16:** Gynecomastia in klinefelter syndrome

*Photo Courtesy:* Vaman Khadilkar, Pune

Approximately 1/500 newborn males has a 47,XXY chromosome complement. Clinical features are tall stature, mental sub normality, small testes and gynecomastia.

Replacement therapy with a long-acting testosterone preparation depends on the age of the patient. It should begin at 11 to 12 years of age. Gynecomastia usually requires surgical treatment.

### Gynecomastia—Puberty



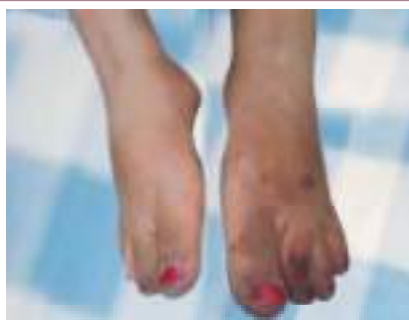**Figure 12.1.17:** Puberty gynecomastia

*Photo Courtesy:* Vaman Khadilkar, Pune

Physiologic pubertal gynecomastia may involve only one breast, and it is not unusual for both breasts to enlarge at disproportionate rates or at different times. Tenderness of the breast is common. Spontaneous regression may occur within a few months; it rarely persists longer than 2 years.

Treatment usually consists of reassuring the boy of the physiologic and transient nature of the phenomenon. When the enlargement is striking and causes serious emotional treatment can be given. Medical therapies consists of use of aromatase inhibitors, Danazol and dihydrotestosterone local application. In resistant cases surgery is necessary.

### Hemihypertrophy—Beckwith-Wiedemann Syndrome



**Figure 12.1.18:** Hemihypertrophy

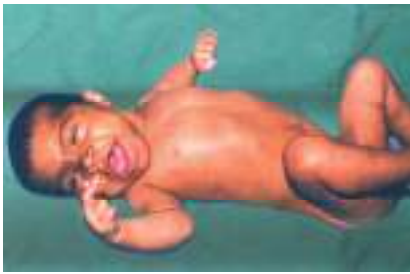*Photo Courtesy:* Vaman Khadilkar, Pune

Hemihypertrophy is associated with Beckwith-Wiedemann syndrome (BWS) or sometimes with vascular malformations of that specific body part. BWS consists of hyperinsulinism, umbilical hernia, renal tumors and overgrowth.

Management of hypoglycemia and screening for the development of renal neoplasm is the main goal of therapy.

Picture	Note	Management
---------	------	------------

### Hypothyroidism—Congenital



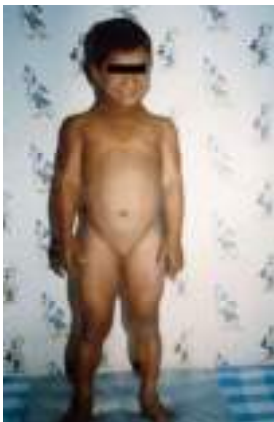**Figure 12.1.19:** Untreated congenital hypothyroidism  
Photo Courtesy: Vaman Khadilkar, Pune

Clinical signs such as large tongue, hypotonia, delayed milestone, constipation, dry skin, lid edema, etc. are late to appear. By the time they are clinically apparent it is too late as brain damage has already set in. With every week's delay in diagnosis 5 to 10 points in the IQ are lost.

Levothyroxine in the dose of 10 to 12 mcg per KG per day is needed in the first year. After 1<sup>st</sup> year it can be reduced to 100 mcg per meter square per day.

*Universal neonatal thyroid screening is an absolute must to prevent this common cause of preventable mental retardation.*

### Hypothyroidism—Juvenile



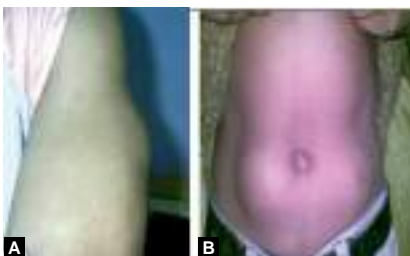**Figure 12.1.20:** Juvenile hypothyroidism  
Photo Courtesy: Vaman Khadilkar, Pune

Short stature, laziness, constipation, inactivity, facial edema, muscular pseudohypertrophy as seen here, macro-orchidia in boys are common-features. Goiter is not a consistent feature. Academic performance is usually good and deteriorates on treatment.

Levothyroxine in a dose of 2 to 5 mcg per KG per day early morning on empty stomach is recommended for best absorption. Monitoring is done by 3 to 6 monthly thyroid function tests and growth assessment.

*In long standing undiagnosed hypothyroid children final height attainment is often less than the target height.*

### Lipohypertrophy due to Insulin



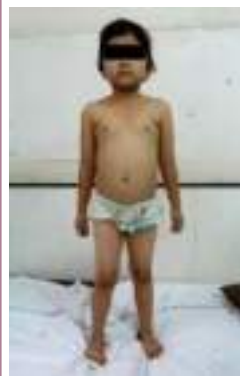**Figures 12.1.21A and B:** (A) Insulin induced Lipohypertrophy; (B) Insulin induced Lipohypertrophy  
Photo Courtesy: Anju Virmani, Sangeeta Yadav, New Delhi

Lipohypertrophy is more common with human insulin injections especially when rotation of sites is not done. Insulin absorption becomes erratic from these areas and hence glycemic control suffers.

Changing injections sites is the treatment for this condition. Patient must be educated in injection technique and site rotation to avoid this common problem.

Picture	Note	Management
---------	------	------------

### Mauriac Syndrome

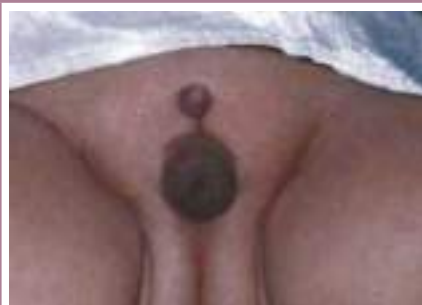

**Figure 12.1.22:** Mauriac syndrome  
Photo Courtesy: Vaman Khadilkar, Pune

Uncontrolled Type 1 diabetes leads to short stature, hepatomegaly with protruding abdomen, proximal muscle weakness. This is seen less commonly now due to availability of better insulin preparations.

Improved glycemic control is needed to prevent and treat this complication of diabetes. With improved glycemic control majority of clinical features improve.

### Micropenis



**Figure 12.1.23:** Micropenis  
Photo Courtesy: Vaman Khadilkar, Pune

Micropenis is defined as normally formed penis that is at least 2.5 z scores below the mean in length. In a full term newborn the diagnosis of micropenis is made if the stretched penile length is below 2 cm. Micropenis is a known association of many endocrine disorders such as growth hormone deficiency, hypogonadotropic hypogonadism, Prader-Willi syndrome and Lawrence-Moon-Biedl syndrome.

The treatment depends upon the cause and response to androgens is variable.

### Mucopolysaccharidoses



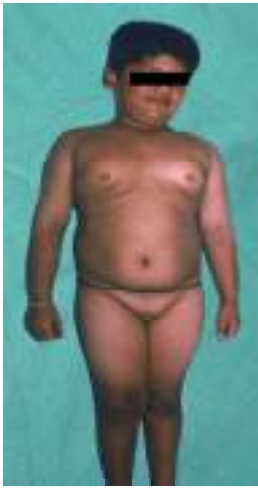**Figure 12.1.24:** Mucopolysaccharidoses  
Photo Courtesy: Vaman Khadilkar, Pune

Mucopolysaccharidoses are group of inherited, progressive diseases caused by mutations of genes coding for lysosomal enzymes needed to degrade glycosaminoglycans. Short stature is almost universal with a variety of other systemic involvement. The skeletal form resemble skeletal dysplasia.

Bone marrow transplantation or cord blood transplantation results in significant clinical improvement in Type I, II, and VI. Genetic counseling is necessary for prevention of further abnormal babies. For the affected supportive therapy remains the mainstay of management.

Picture	Note	Management
---------	------	------------

### Obesity—Simple



**Figure 12.1.25:** Simple obesity  
Photo Courtesy: Vaman Khadilkar, Pune

There is an alarming increase in the incidence of obesity in urban India in the last few decades. This is caused by excessive non-protein calorie intake and relative inactivity. Overweight and obesity is diagnosed by calculating body mass index (BMI =  $Wt \text{ in kg} / \text{Height in M}^2$ ). Cutoff values for BMI are age and sex specific and hence BMI charts should be used for early diagnosis of overweight in children.

As more than 97% of all obesity is nonhormonal, management mainly consists of lifestyle and behavioral modifications, nutritional intervention programs, reducing screen time and increasing physical activity. There is no role of pharmacotherapy in simple nutritional pediatric obesity.

### Orchidometer

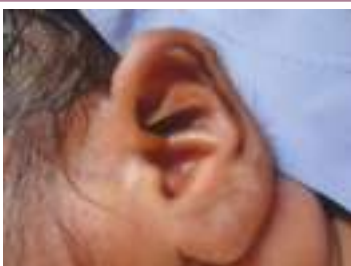

**Figure 12.1.26:** Prader Orchidometer  
Photo Courtesy: Vaman Khadilkar, Pune

Boys' sexual maturity is assessed by measuring testicular volume. Testicular volume is assessed using orchidometer.

Note that the first 3 beads that indicate 1, 2 and 3 ml volume are prepubertal. Puberty starts at 4 ml and then there is progressive increase in the testicular volume till 20 to 25 ml in the adult male.




### PHHI—Hairy Pinna



**Figure 12.1.27:** Hairy pinna in PHHI  
Photo Courtesy: Vaman Khadilkar, Pune

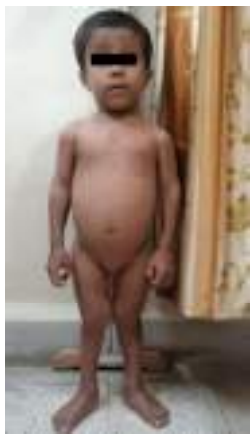Hyperinsulinism is the most common cause of persistent hypoglycemia in early neonatal period and infancy. Hyperinsulinemic babies may be macrosomic at birth, often have hairy pinna and persistent hypoglycemia. Insulin concentrations are inappropriately elevated for the blood glucose level often above 5 mIU/ml.

Treatment consists of glucose infusions, diazoxide, hydrochlorothiazide, octreotide and partial pancreas removal by surgery.

Picture	Note	Management
<p><b>Precocious Puberty—Central with Hypothalamic Hamartoma</b></p>  <p><b>Figures 12.1.28A and B:</b> (A) Central precocious puberty; (B) Central precocious puberty caused by hypothalamic hamartoma Photo Courtesy: Vaman Khadilkar, Pune</p>	<p>True precocious puberty occurs when there is activation of hypothalamo-pituitary-gonadal axis. Central precocious puberty is much more common in girls. In boys, central precocious puberty is often associated with serious neurological disorder such as SOL. Gonadotropin releasing hormone stimulation test differentiates this from peripheral precocity.</p>	<p>True precocious puberty is treated with Gonadotropin releasing analog (GnRha). These analogs work by down-regulation of the hypothalamic receptors. Early therapy with GnRha improves the final height and postpones menses.</p>
<p><b>Pseudoprecocious Puberty and Hypertension in a Boy—CAH</b></p>  <p><b>Figure 12.1.29:</b> Pseudoprecocious puberty (CAH) Photo Courtesy: Vaman Khadilkar, Pune</p>	<p>In contrast to the previous condition this is caused by the activation of the peripheral tissues such as adrenals or gonads. This is gonadotropin independent puberty and gonadotropins are suppressed. Pseudoprecocious puberty can be iso or heterosexual. Congenital adrenal hyperplasia (CAH) is the commonest cause of pseudoprecocious puberty.</p>	<p>Depends upon the cause of precocity. In CAH treatment is with oral hydrocortisone and fludrocortisones. In adrenal, ovarian and testicular tumors surgical removal along with chemotherapy may be needed.</p>
<p><b>Renal Tubular Acidosis (RTA)—Failure to Thrive</b></p>  <p><b>Figure 12.1.30:</b> Renal tubular acidosis Photo Courtesy: Vaman Khadilkar, Pune</p>	<p>The failure to thrive and costal beading due to rickets. Renal tubular acidosis (RTA) is a disorder characterized by a normal anion gap metabolic acidosis. This can be due to either impaired bicarbonate reabsorption or impaired urinary hydrogen ion excretion. Proximal, distal, hyperkalemic and mixed forms exist.</p>	<p>Mainstay of therapy is bicarbonate replacement. Proximal RTA requires much higher dose than distal RTA. Other medications include thiazide diuretics and measures to control hyperkalemia in the hyperkalemic variety.</p>

Picture	Note	Management
---------	------	------------

### Skeletal Dysplasia

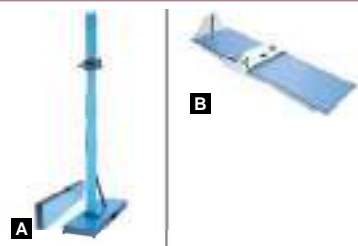


**Figure 12.1.31:** Skeletal dysplasia  
Photo Courtesy: Vaman Khadilkar, Pune

Skeletal dysplasias are genetically and clinically heterogeneous group of disorders of skeletal development and growth. The most common being Achondroplasia. Disproportionate growth is the hallmark of these disorders. The diagnosis is made by radiographic skeletal survey.

Management is mainly restricted to correction of orthopedic deformities. Improvement in the final height is achieved by limb lengthening surgical procedures. Clinical trials for the use of growth hormone to treat skeletal dysplasia are underway but the results are equivocal and growth hormone is not a standard acceptable form of therapy.

### Stadiometer and Infantometer

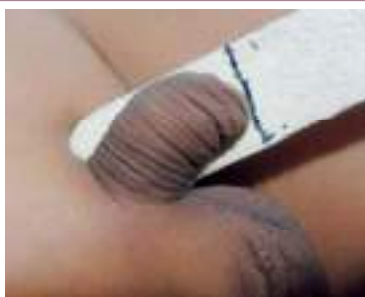

**Figures 12.1.32A and B:** (A) Stadiometer;  
(B) Infantometer  
Photo Courtesy: Vaman Khadilkar, Pune

Stadiometer is used to accurately measure height up to 1 mm accuracy. Accurate height measurement and growth monitoring using appropriate growth charts remains an invaluable tool in the assessment of pediatric and pediatric endocrine disorders.

For infants below the age of 2 years length is used instead of height. Two persons are needed to accurately measure length on an Infantometer.

### Stretched Penile Length—Method




**Figure 12.1.33:** Stretched penile length  
Photo Courtesy: Vaman Khadilkar, Pune

Stretched penile length is measured as shown with the help of a wooden spatula. Penis is rested on the spatula. Spatula is then gently pressed inside until it touches the pubic symphysis. Tip of the penis (excluding the prepuce length) is marked and measured against a scale.

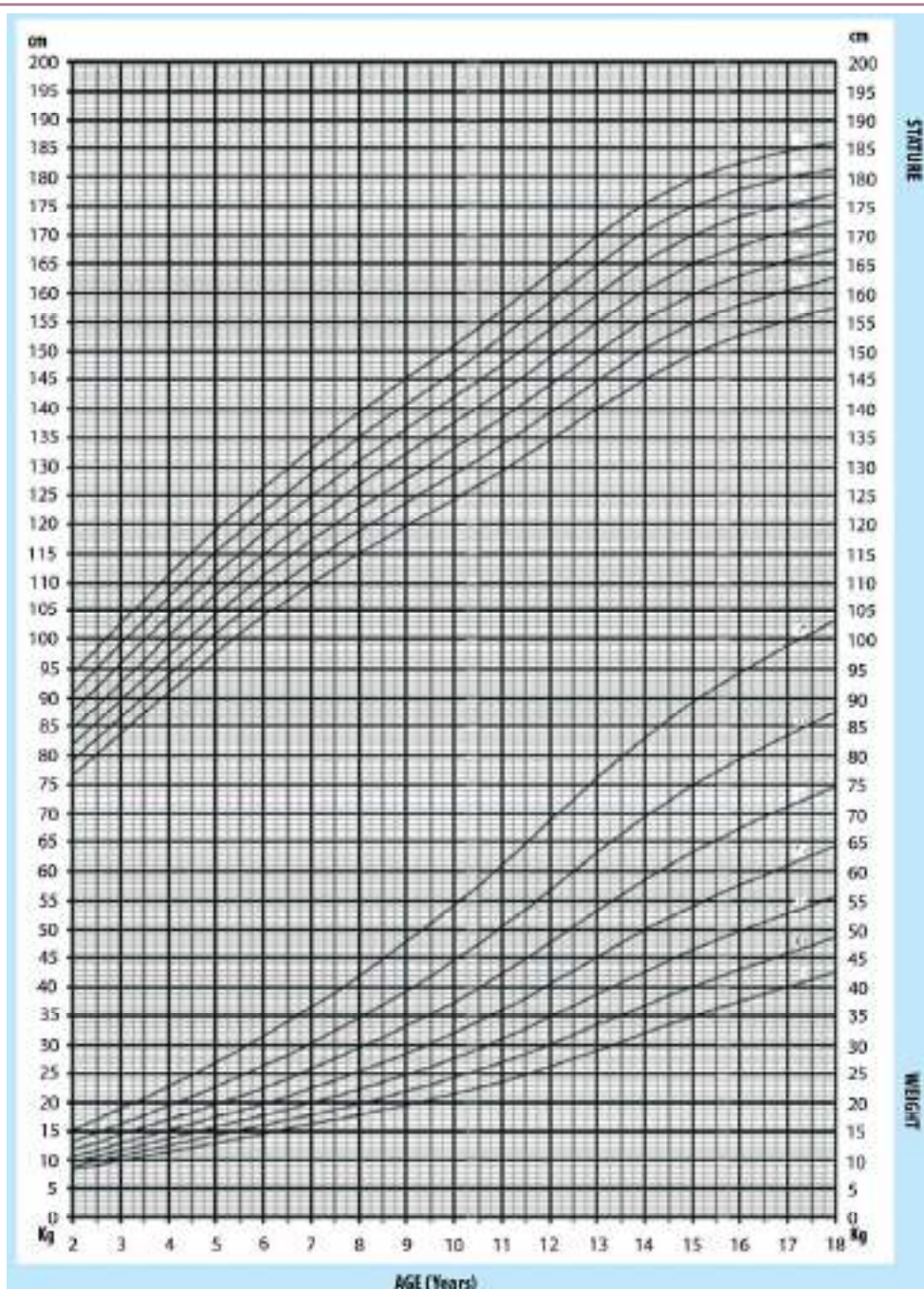
Norms of penile length are available. In a neonate at term average is 2.5 cm and length less than 2 cm is micropenis.

Picture	Note	Management
<p><b>Thelarche—Benign</b></p>  <p><b>Figure 12.1.34:</b> Benign thelarche Photo Courtesy: Vaman Khadilkar, Pune</p>	<p>Isolated breast development is often seen in the first two years of life. There are no other signs of puberty such as axillary or pubic hair development or estrogenization of the genitals. Bone age is not much advanced and condition naturally resolves within 2 to 3 years.</p>	<p>Only reassurance is needed. No specific treatment is necessary but differentiation from atypical thelarche or true precocious puberty is necessary.</p>

### Vitamin D Resistant Rickets (VDRR)

 <p><b>Figure 12.1.35:</b> Vitamin D resistant rickets Photo Courtesy: Vaman Khadilkar, Pune</p>	<p>Hypophosphatemic rickets is the most common cause of vitamin D resistant rickets. This is caused by the defective <i>PHEX</i> gene. Defects in the <i>PHEX</i> gene leads to increased phosphate excretion from the proximal renal tubules causing hypophosphatemia. There is also decreased production of 1-25 D3.</p>	<p>Treatment consists of oral phosphates in a dose of 1 to 3 gm of elemental phosphorus in 4 to 5 divided doses. Calcitriol is administered in a dose of 30 to 70 ng/kd/day in 2 divided doses.</p>
---	--	---

## 2007 Growth Charts—Affluent Indian Boys Stature and Weight



**Figure 12.1.36:** Affluent Indian Boys Height and Weight charts 2007

**Reference:** Khadilkar VV, Khadilkar AV, Cole TJ, Sayyad MG. Crosssectional growth curves for height, weight and body mass index for affluent Indian children, 2007. *Indian Pediatr.* 2009;46(6):477-89.

Khadilkar VV, Khadilkar AV, Chiplonkar SA. Growth Performance of Affluent Indian Preschool Children: A Comparison with the New WHO Growth Standard. *Indian Pediatr.* 2010;47(10):869-72.



Picture

Note

Management

## 2007 Growth Charts—Affluent Indian Girls Stature and Weight

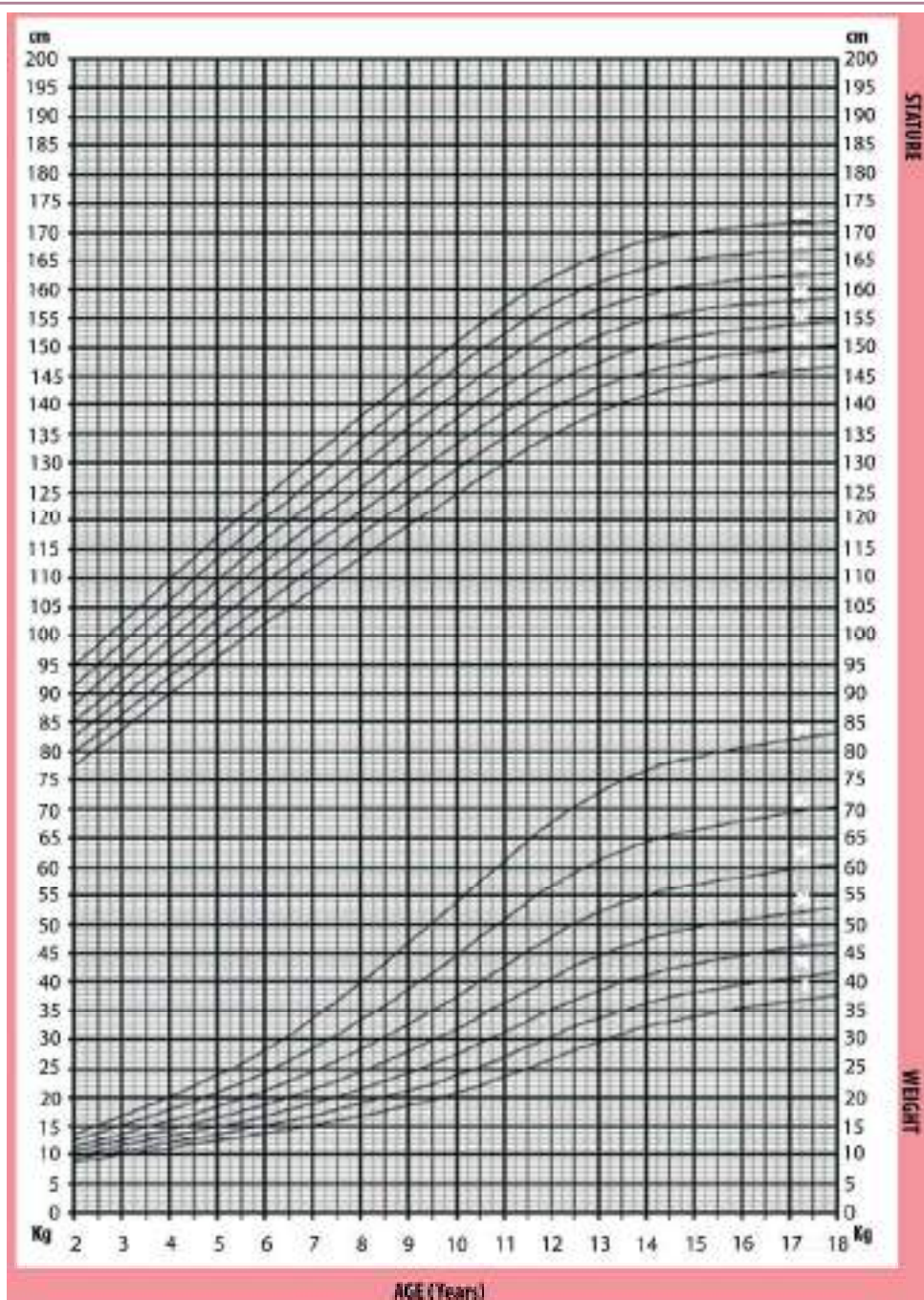
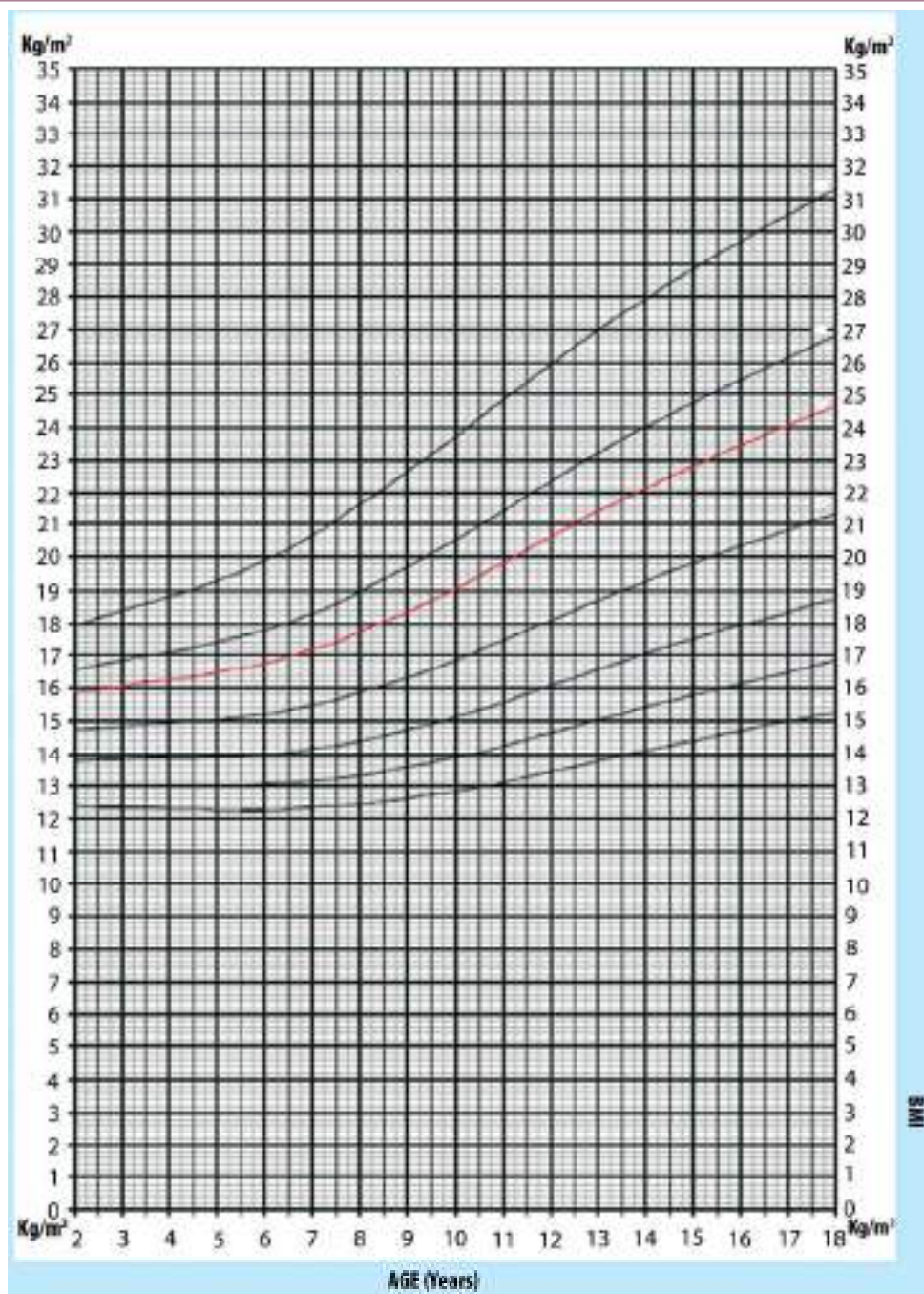


Figure 12.1.37: Affluent Indian Girls Height and Weight charts 2007

**Reference:** Khadilkar VV, Khadilkar AV, Cole TJ, Sayyad MG. Crosssectional growth curves for height, weight and body mass index for affluent Indian children, 2007. *Indian Pediatr.* 2009;46(6):477-89.

Khadilkar VV, Khadilkar AV, Chiplonkar SA. Growth Performance of Affluent Indian Preschool Children: A Comparison with the New WHO Growth Standard. *Indian Pediatr.* 2010;47(10):869-72.

## 2007 Growth Charts—Affluent Indian Boys BMI



**Figure 12.1.38:** Affluent Indian Boys BMI charts 2007

**Reference:** Khadilkar VV, Khadilkar AV, Cole TJ, Sayyad MG. Cross-sectional growth curves for height, weight and body mass index for affluent Indian children, 2007. *Indian Pediatr.* 2009;46(6):477-89.

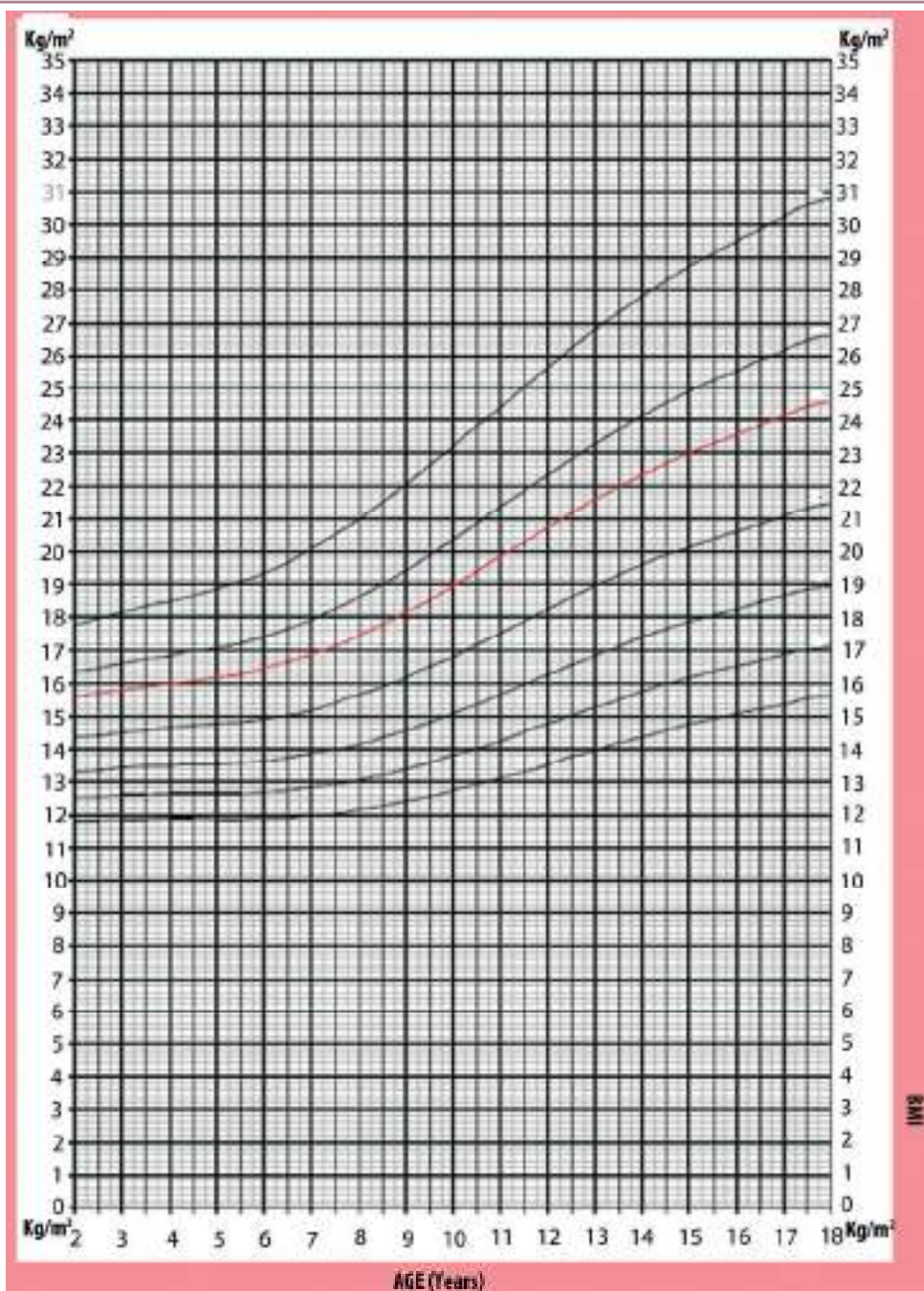
Khadilkar VV, Khadilkar AV, Chiplonkar SA. Growth Performance of Affluent Indian Preschool Children: A Comparison with the New WHO Growth Standard. *Indian Pediatr.* 2010;47(10):869-72.

Picture

Note

Management

## 2007 Growth Charts—Affluent Indian Girls BMI




**Figure 12.1.39:** Affluent Indian Girls BMI charts 2007


**Reference:** Khadilkar VV, Khadilkar AV, Cole TJ, Sayyad MG. Cross sectional growth curves for height, weight and body mass index for affluent Indian children, 2007. *Indian Pediatr.* 2009;46(6):477-89

Khadilkar VV, Khadilkar AV, Chiplonkar SA. Growth Performance of Affluent Indian Preschool Children: A Comparison with the New WHO Growth Standard. *Indian Pediatr.* 2010;47(10):869-72


## 12.2 UNCOMMON CONDITIONS BUT NOT RARE


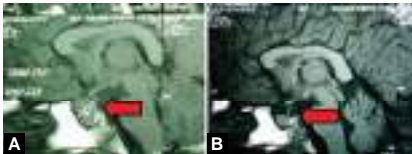

Picture	Note	Management
<p><b>Adrenal Hypoplasia Congenita</b></p>  <p><b>Figure 12.2.1:</b> Adrenal hypoplasia congenita Photo Courtesy: Vaman Khadilkar, Pune</p>	<p>Adrenal hypoplasia congenita can be caused by many genetic defects and presents with adrenal failure in the neonatal period or in later childhood if the onset is insidious. In case of <i>DAX1</i> gene defect hypogonadotropic hypogonadism is associated.</p>	<p>Glucocorticoid and mineralocorticoid replacement therapy is needed. At puberty sex steroid replacement may be needed in <i>DAX1</i> defect to treat hypogonadotropic hypogonadism.</p>

### Cushing's Syndrome—Adrenal Tumor

 <p><b>Figure 12.2.2:</b> Adrenal tumor Photo Courtesy: Vandana Jain, New Delhi</p>	<p>Cushing's syndrome in infancy is usually caused by adrenal adenoma. Clinical feature consists of obesity, growth failure, moon face, hypertension, hyperglycemia, buffalo hump and sometimes androgen excess signs such as clitoral hypertrophy and pubic hair development.</p>	<p>Biochemical tests show increased cortisol production which is not suppressed with low dose dexamethasone, androgen excess in the form of high testosterone. Localization of adrenal tumor is best done by CT scan and not by ultrasound. Removal of the mass is the treatment which results in reversal of most features.</p>
--	--	--

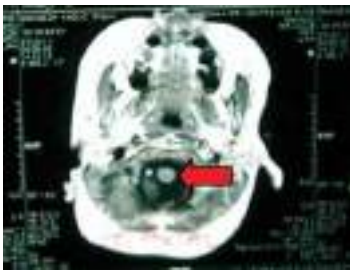### Graves' Disease

 <p><b>Figure 12.2.3:</b> Graves' Disease Photo Courtesy: Vaman Khadilkar, Pune</p>	<p>Hyperthyroidism is most commonly caused by Graves' disease in childhood. This is an autoimmune disorder caused by gain-of-function mutation of the TSH receptor. Clinical features include goiter, weight loss, clumsiness, tachycardia, exophthalmos and increased appetite.</p>	<p>Graves' is treated with beta blockers to control adrenergic symptoms and antithyroid medications such as carbimazole, methimazole and propylthiouracil (PTU). In resistant cases radio-iodine ablation or surgery is necessary.</p>
---	--	--

Picture	Note	Management
 <p><b>Figure 12.2.4:</b> Hypoparathyroidism causing Carpopedal spasm Photo Courtesy: Vaman Khadilkar, Pune</p>	<p>Hypoparathyroidism leads to hypocalcemic tetany in older children and convulsions in babies and infants. Low total and ionic calcium, elevated phosphorus along with low parathyroid hormone are diagnostic. Hypoparathyroidism is caused by a variety of causes ranging from genetic to autoimmune destruction.</p>	<p>Immediate management of hypocalcemia is by calcium infusion given IV. Hypoparathyroidism is treated by 1 to 25 dihydroxy D3 in the initial dose of is 0.25 µg/24 hours. The maintenance dosage ranges from 0.01 to 0.10 µg/kg/24 hours to a maximum of 1 to 2 µg/24 hours in 2 to 3 divided doses.</p>
 <p><b>Figures 12.2.5A and B:</b> (A) Pituitary mass- Hypothyroidism before treatment; (B) Pituitary mass has disappeared after treatment of hypothyroidism Photo Courtesy: Vaman Khadilkar, Pune</p>	<p>Chronic hypothyroidism leads to hyperplasia of the pituitary thyrotrophs. This is seen as a pituitary mass which may be inadvertently operated.</p>	<p>There is no need for surgery in these children. Replacement with levothyroxine leads to complete disappearance of the mass within few months of therapy.</p>
 <p><b>Figure 12.2.6:</b> Langer syndrome Photo Courtesy: Vaman Khadilkar, Pune</p>	<p>Langer syndrome is caused by homozygous mutations of the <i>SHOX</i> gene whereas heterozygous mutations cause Leri-Weil dyschondrosteosis. There is severe mesomelic dwarfism, bowing of the radius and ulna and Madelung deformity. Milder form of <i>SHOX</i> gene defect cause idiopathic short stature.</p>	<p>Short stature caused by <i>SHOX</i> gene defect is a now a licensed indication for growth hormone therapy.</p>

Picture	Note	Management
---------	------	------------

### Langerhan's Cell Histiocytosis (LCH) Causing DI



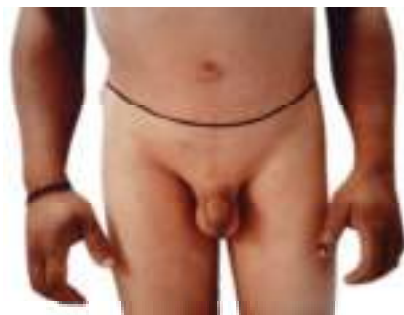**Figure 12.2.7:** LCH, MRI showing pituitary stalk involvement

*Photo Courtesy:* Vaman Khadilkar, Pune

Pituitary-hypothalamic involvement is not uncommon in histiocytosis. Note the diffuse enlargement of the pituitary stalk in the picture. Growth retardation and diabetes insipidus are common in pituitary disease caused by LCH.

Multisystem disease requires chemotherapy and has variable prognosis. Diabetes insipidus is treated with nasal or oral dDAVP.

### Macro-Orchidia in Hypothyroidism



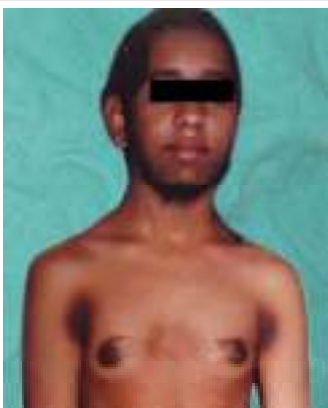**Figure 12.2.8:** Macro-orchidia in hypothyroidism

*Photo Courtesy:* Vaman Khadilkar, Pune

Long-standing untreated hypothyroidism leads to macro-orchidia without any other signs of puberty. This is caused by very high level of TSH which causes "specificity spillover" leading to FSH like action without LH activation that leads to incomplete form of gonadotropin dependent precocious puberty.

Replacement therapy with levothyroxine leads to reversal of macro-orchidia, other features of hypothyroidism and restores growth.

### Nonclassical Congenital Adrenal Hyperplasia (CAH)



**Figure 12.2.9:** Nonclassical CAH

*Photo Courtesy:* Vaman Khadilkar, Pune

Nonclassical congenital adrenal hyperplasia usually does not manifest with atypical genitalia at birth. This form of CAH presents with Precocious adrenarche, menstrual irregularity, hirsutism, acne, and later infertility. However, many males and females may be completely asymptomatic.

Treatment consist of glucocorticoid replacement in a dose of 10 mg/m<sup>2</sup>/24 hours in 3 divided doses. Asymptomatic individuals do not need treatment.

Picture	Note	Management
---------	------	------------

### Peripheral Pseudoprecocious Puberty

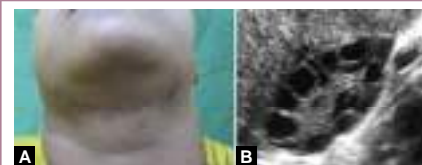

**Figure 12.2.10:** McCune Albright with precocious puberty  
*Photo Courtesy:* Vaman Khadilkar, Pune

Gonadotropin independent precocious puberty is caused by peripheral activation of gonads in this case testes. Also note the fibrous dysplasia of the femur bone. This is seen in McCune Albright syndrome. The disorder is characterized by autonomous hyperfunction of many glands caused by a missense mutation in the gene encoding the  $\alpha$ -subunit of GS.

This condition is very difficult to treat. Various approaches such as combination of medroxyprogesterone, anti-androgens and aromatase inhibitors have been used with limited success.

### Polycystic Ovary Syndrome (PCOS)

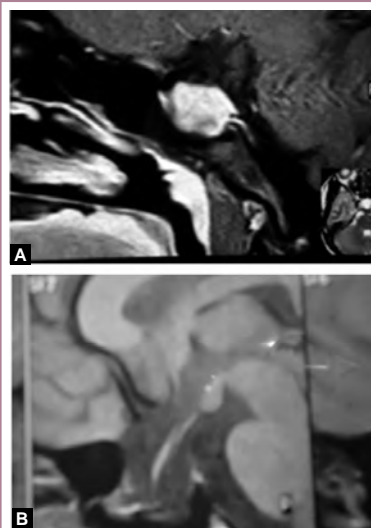


**Figures 12.2.11A and B:** (A) PCOS with hirsutism; (B) Classical polycystic ovary on ultrasound  
*Photo Courtesy:* Vaman Khadilkar, Pune

PCOS is a condition that consists of hyperandrogenism associated with chronic anovulation with or without polycystic ovaries. This evolves through adolescent years and manifests with menstrual irregularity, hirsutism and later infertility. Obesity and insulin resistance are often associated.

Management consists of weight loss in obese girls. Other medications are used to control symptoms and consists of antiandrogens, metformin in insulin resistant cases and oral contraceptive pills to regularize menses and increase sex hormone binding globulin.

### Prolactinoma—Disappearing with Cabergoline Treatment



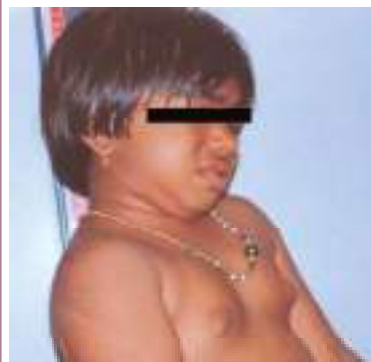**Figures 12.2.12A and B:** (A) Prolactinoma before; (B) Prolactinoma after cabergoline treatment  
*Photo Courtesy:* Vaman Khadilkar, Pune

Prolactinoma is usually seen in adolescents and manifests with galactorrhea. Prolactin levels are very high. The tumor is usually seen on MRI as shown which shrinks or disappears as shown in the picture.

Surgery is very rarely needed for prolactinoma and mass shrinks or disappears on treatment with bromocriptin or cabergoline.

Picture	Note	Management
---------	------	------------

### Pseudoprecocious Puberty Caused by Hypothyroidism

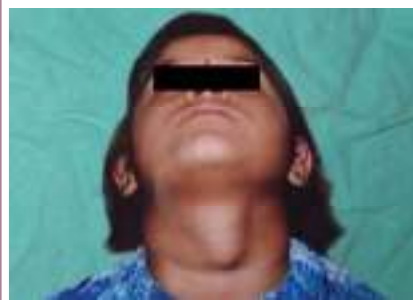

**Figure 12.2.13:** Pseudoprecocious puberty—hypothyroidism  
Photo Courtesy: Vaman Khadilkar, Pune

Hypothyroidism can cause precocious as well as delayed puberty. Precocious puberty is seen as thelarche or rarely menarche but axillary or pubic hair development usually not seen. High prolactin values associated with hypothyroidism also lead to breast development. Large ovarian cysts are seen in long standing untreated hypothyroid girls.

Replacement therapy with levothyroxine usually leads to reversal of all clinical features and restores growth.

### Thyroglossal Cyst



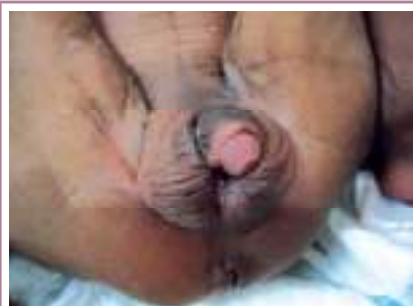**Figure 12.2.14:** Thyroglossal cyst  
Photo Courtesy: Vaman Khadilkar, Pune

Thyroglossal cysts are usually seen in the midline of the neck and may extend up to the base of the tongue. The swelling moves with swallowing. Hypothyroidism may or may not be associated. There is often functioning thyroid tissue in these cysts.

If the child is hypothyroid, replacement with Levothyroxine is warranted which may reduce the size of the cystic swelling. In many children with thyroglossal cyst this may be the only functioning thyroid tissue and hence it should not be removed unless infected or causing significant acute compression.

## 12.3 ENDOCRINE EMERGENCIES

### Congenital Adrenal Hyperplasia (CAH) Salt Wasting Crisis




**Figure 12.3.1:** Salt wasting CAH  
Photo Courtesy: Vaman Khadilkar, Pune


Congenital adrenal hyperplasia of the salt wasting variety presents with Addisonian crisis after the 1<sup>st</sup> week of life. In a female infant it presents with atypical genitalia whereas in a male it is often missed. Hyperpigmentation of the genitals, nipple and axilla is typical.

Correction of hyponatremia and dehydration, replacement with hydrocortisone in a dose of 100 mg/m<sup>2</sup>/day in 3 divided doses as injections and later as 10 to 15 mg/m<sup>2</sup>/day in 3 divided doses orally. Mineralocorticoid therapy is in the dose of 100 to 300 mcg/day in the initial period. This is later reduced to 100 mcg/m<sup>2</sup>/day.




Picture	Note	Management
<b>Disorder of Sexual Development (DSD)</b>		
 <p data-bbox="96 612 464 661"><b>Figure 12.3.2:</b> DSD Photo Courtesy: Vaman Khadilkar, Pune</p>	<p data-bbox="540 298 930 570">Disorder of sexual development is a psychosocial emergency that arises in the delivery room. A common condition that presents as DSD and also comes with medical emergency in the first few days of life is congenital adrenal hyperplasia. Salt wasting and hypoglycemic crisis need to be carefully watched for.</p>	<p data-bbox="962 298 1348 600">Management of DSD requires team approach. It is very important for the caring staff to be gentle, understanding, supportive and communicative with the parents and the family. Team consists of gynecologist, pediatric endocrinologist, psychologist, social worker, pediatric surgeon and nursing support staff.</p>

### Persistent Hyperinsulinemic Hypoglycemia of Newborn

 <p data-bbox="96 1141 464 1189"><b>Figure 12.3.3:</b> PHHI with hairy pinna Photo Courtesy: Vaman Khadilkar, Pune</p>	<p data-bbox="540 846 930 1118">Hypoglycemia in the neonatal period is an emergency. Persistent neonatal hypoglycemia requiring very high glucose infusion rate (&gt; 12 mg/kg/min) is usually caused by persistent hyperinsulinemic hypoglycemia of the newborn (PHHI) also known as insulin dysregulation syndrome.</p>	<p data-bbox="962 846 1348 1024">This conditions requires a combination of therapy in the form of Diazoxide, Hydrochlorothiazide, Octreotide, Corticosteroids and in resistant cases removal of the pancreas.</p>
---	---	---


## 12.4 SYNDROMES

### Laron Dwarfism—Growth Hormone Insensitivity Syndrome


 <p data-bbox="96 1725 464 1774"><b>Figure 12.4.1:</b> Laron dwarfism Photo Courtesy: Vaman Khadilkar, Pune</p>	<p data-bbox="540 1405 930 1703">This condition clinically resembles growth hormone deficiency with profound short stature, immature look, mid facial hypoplasia, micropenis, delayed puberty and central obesity. However, in this condition there is growth hormone insensitivity with high basal and high stimulated growth hormone values. IGF-1 is low.</p>	<p data-bbox="962 1405 1348 1552">This condition does not respond to growth hormone therapy. IGF-1 therapy is still in the experimental stage and is currently not available in India.</p>
---	--	--

Picture	Note	Management
---------	------	------------


### Lawrence-Moon-Biedl (LMB) Syndrome

 <p><b>Figures 12.4.2A and B:</b> (A) LMB, obesity, hypogonadism, night blindness; (B) LMB Retinitis pigmentosa <i>Photo Courtesy:</i> Vaman Khadilkar, Pune</p>	<p>Features of this syndrome include, polydactyly, obesity, hypogonadism and night blindness due to retinitis pigmentosa. Renal abnormalities with chronic renal failure is also a known association.</p>	<p>There is no specific treatment for this condition.</p>
--	---	---

### McCune-Albright Syndrome

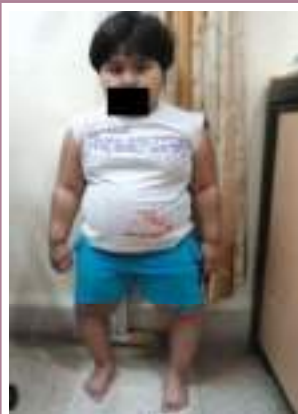 <p><b>Figure 12.4.3:</b> McCune Albright Syndrome <i>Photo Courtesy:</i> Vandana Jain, New Delhi</p>	<p>This syndrome of endocrine dysfunction is associated with patchy cutaneous pigmentation as seen in the photograph and fibrous dysplasia of the skeletal system. Precocious puberty and hyperfunctioning of pituitary, thyroid, and adrenals are also recognized. The disorder is caused by the G protein that stimulates cyclic adenosine monophosphate (cAMP) formation.</p>	<p>There is no specific treatment for this condition and endocrine hyperfunction is difficult to treat.</p>
--	--	---

### Noonan Syndrome

 <p><b>Figure 12.4.4:</b> Noonan syndrome <i>Photo Courtesy:</i> Vaman Khadilkar, Pune</p>	<p>Features of Noonan syndrome include short stature, antimongoloid slant, low posterior hairline, shield chest, congenital heart disease, and a short or webbed neck.</p>	<p>There is no specific therapy for this condition and treatment is symptomatic such as surgical correction of the heart defect and trial of growth hormone for short stature.</p>
--	--	--

Picture	Note	Management
---------	------	------------

### Prader-Willi Syndrome



**Figure 12.4.5:** Prader-Willi syndrome  
Photo Courtesy: Vaman Khadilkar, Pune

Prader-Willi syndrome (PWS) consists of hypothalamic obesity, almond shaped eyes, down turned mouth, hyperphagia, small hands and feet, hypotonia in infancy and hypogonadism. A proportion of children with PWS are growth hormone deficient. Severe apneas can occur in this condition. Partial deletions of chromosome 15 are seen in some children.

There is no specific therapy. PWS children who are growth hormone deficient are treated with growth hormone which improves their height, body composition and even coordination. Sleep apnea can be a major problem and needs treatment.

### Russell-Silver Syndrome




**Figure 12.4.6:** Russell-Silver syndrome  
Photo Courtesy: Vaman Khadilkar, Pune

Russell-Silver syndrome is a disorder present at birth that involves poor growth, low birth weight, short height, and differences in the size of the two sides of the body. Prominent forehead, triangular face maternal uniparental disomy (UPD) for chromosome 7 is seen in some patients and abnormality of chromosome 11 is seen in others.

There is no specific treatment for this genetic disease. Growth hormone therapy has been successfully used to treat short stature in this condition.


### SHOX Gene Defect



**Figure 12.4.7:** SHOX gene defect—Madelung deformity  
Photo Courtesy: Vaman Khadilkar, Pune

Heterozygous mutations of the SHOX gene cause Leri-Weil dyschondrosteosis where as milder form may lead to only short stature. There is severe mesomelic dwarfism, bowing of the radius and ulna, Madelung deformity and bony exostosis.

Short stature caused by SHOX gene defect is now a licensed indication for growth hormone therapy. Deformities such as Madelung deformity may need orthopedic correction.

Picture	Note	Management
<p data-bbox="88 249 317 278"><b>Turner Syndrome</b></p>  <p data-bbox="96 616 492 687"><b>Figure 12.4.8:</b> Turner syndrome, webbing of neck, short neck <i>Photo Courtesy:</i> Vaman Khadilkar, Pune</p>	<p data-bbox="540 298 933 631">This is caused by the chromosomal abnormality of 45 X0 or 46 XX, the second X as ring chromosome. Mosaic forms are also common. Phenotypic features are short stature, webbed neck, increased carrying angle, epicanthic folds, low hair line and many other systemic abnormalities such as coarctation of aorta, horseshoe shaped kidneys and streak ovaries.</p>	<p data-bbox="962 298 1336 540">Short stature in Turner syndrome responds to growth hormone therapy. The dose of growth hormone is higher than in Growth hormone deficiency. At the time of puberty hormone replacement therapy to induce and maintain puberty is needed.</p>



# Section 13

---

# Genetics

## ***Section Editors***

Shubha R Phadke, ML Kulkarni

## ***Photo Courtesy***

Shubha R Phadke, ML Kulkarni

- 13.1 Chromosomal Disorders
- 13.2 Syndromes with Growth Disorders
- 13.3 Lysosomal Storage Disorders
- 13.4 Skeletal Dysplasias
- 13.5 Malformations/Malformation Syndromes
- 13.6 Miscellaneous Monogenic Disorders

## SECTION OUTLINE

### 13.1 CHROMOSOMAL DISORDERS 261

- ◆ Angelman Syndrome 261
- ◆ Chromosome 1p36 Submicroscopic Deletion 261
- ◆ Cri du Chat (Deletion of 5p Terminal) 261
- ◆ Down Syndrome (Trisomy 21) 262
- ◆ Klinefelter Syndrome 262
- ◆ Prader-Willi Syndrome 262
- ◆ Rubinstein-Taybi Syndrome 263
- ◆ Turner Syndrome (Monosomy X) 263
- ◆ Velocardiofacial Syndrome 263
- ◆ Williams Syndrome 264
- ◆ Wolf-Hirschhorn Syndrome (4p Deletion Syndrome) 264

### 13.2 SYNDROMES WITH GROWTH DISORDERS 264

- ◆ Beckwith-Wiedemann Syndrome 264
- ◆ Cockayne Syndrome 265
- ◆ Cornelia de Lange Syndrome 265
- ◆ Hallermann-Streiff Syndrome 265
- ◆ Hemihyperplasia—Isolated 266
- ◆ Microcephalic Osteodysplastic Primordial Dwarfism II (MOPD II) 266
- ◆ Proteus Syndrome 266
- ◆ Russell-Silver Syndrome 267
- ◆ Seckel Syndrome 267
- ◆ Sotos Syndrome 267

### 13.3 LYSOSOMAL STORAGE DISORDERS 268

- ◆ Fabry Disease 268
- ◆ I-Cell Disease (Mucopolidosis Type II) 268
- ◆ Mucopolysaccharidosis I (Hurler Syndrome) 268
- ◆ Mucopolysaccharidosis II (Hunter Syndrome) 269
- ◆ Mucopolysaccharidosis Type IV—Morquio Type 269

### 13.4 SKELETAL DYSPLASIAS 269

- ◆ Achondrogenesis 269
- ◆ Achondroplasia 270
- ◆ Ellis-Van Creveld Syndrome 270

- ◆ Osteogenesis Imperfecta (OI)—Type III 270
- ◆ Osteopetrosis 271
- ◆ Pseudoachondroplasia 271
- ◆ Spondyloepiphyseal Dysplasia (SED) 271

### 13.5 MALFORMATIONS/MALFORMATION SYNDROMES 272

- ◆ Apert Syndrome (Acrocephalosyndactyly) 272
- ◆ Aplasia of Corpus Callosum (ACC) 272
- ◆ Bardet-Biedl Syndrome (BBS) 272
- ◆ Cardiofacial Syndrome (Asymmetric Crying Facies) 273
- ◆ Cardiofaciocutaneous (CFC) Syndrome 273
- ◆ Carpenter Syndrome (Acrocephalopolysyndactyly II) 273
- ◆ Crozon Syndrome 274
- ◆ Dandy-Walker Malformation (DWM) 274
- ◆ Goldenhar Syndrome (Facio-Auriculo-Vertebral Syndrome) 274
- ◆ Holoprosencephaly 275
- ◆ Holt-Oram Syndrome 275
- ◆ Noonan Syndrome (NS) 275
- ◆ Orofaciodigital Syndrome (OFD)—Type IV 276
- ◆ Pachygyria 276

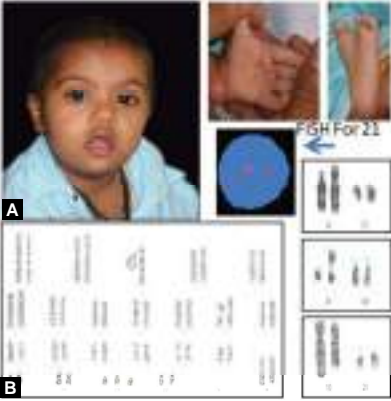
### 13.6 MISCELLANEOUS MONOGENIC DISORDERS 276

- ◆ Albinism Type I 276
- ◆ Ataxia Telangiectasia 277
- ◆ Cutis Laxa 277
- ◆ Ehlers-Danlos Syndrome 277
- ◆ Fanconi Pancytopenia 278
- ◆ Fragile X Syndrome 278
- ◆ Griscelli Syndrome with Hemophagocytosis (Type II) 278
- ◆ Larsen Syndrome 279
- ◆ Marfan Syndrome 279
- ◆ Neurofibromatosis 1 (NF 1) 279
- ◆ Tuberous Sclerosis (TS) 280
- ◆ Waardenburg Syndrome (WS)—Type I 280
- ◆ X-Linked Anhidrotic Ectodermal Dysplasia 280


## 13.1 CHROMOSOMAL DISORDERS

Picture	Note	Management
<p><b>Angelman Syndrome</b></p>  <p><b>Figure 13.1.1:</b> Angelman syndrome Photo Courtesy: Shubha R Phadke</p>	<p>Microcephaly, mental retardation and seizures associated with inappropriate laughter, significant speech delay and jerky ataxic puppet like movements of trunk and upper limbs are features. Skin and hair color may be lighter. Prominent chin and slight prognathism give a characteristic appearance. Caused by microdeletion on the maternal copy of chromosome 15 and the region is the same as that for Prader-Willi region. Paternal disomy of chromosome 15 and methylation abnormalities are other causes.</p>	<p>Supportive care and genetic counseling are important aspects of management. Risk of recurrence is low but depends on the etiology. Prenatal diagnosis is possible.</p>
<p><b>Chromosome 1p36 Submicroscopic Deletion</b></p>  <p><b>Figure 13.1.2:</b> Chromosome 1p36 submicroscopic deletion Photo Courtesy: Shubha R Phadke</p>	<p>Characteristic features are flat midface, straight eyebrows, deep set eyes and wide anterior fontanelle. Microcephaly and mental retardation are present. Caused by submicroscopic deletion of terminal part of <i>p</i> arm of chromosome 1. This syndrome has been recently described with development of FISH technique and appears to be not uncommon.</p>	<p>Supportive therapy is only treatment. Genetic counseling should be provided. Risk of recurrence in sibs is unlikely to be increased. Prenatal diagnosis is possible.</p>
<p><b>Cri du Chat (Deletion of 5p Terminal)</b></p>  <p><b>Figure 13.1.3:</b> Cri du chat (Deletion of 5p terminal) Photo Courtesy: Shubha R Phadke</p>	<p>Some facial dysmorphism like round face, hypertelorism, small chin and mental retardation is present. Characteristic cat like cry is present in some. Clinical features are variable. In many cases the deletion may be detectable only by molecular cytogenetic tests like fluorescence <i>in situ</i> hybridization (FISH), MLPA or microarray.</p>	<p>Management is supportive. Genetic counseling should be provided. Risk of recurrence is negligible unless one of the parents has balanced chromosomal rearrangement. Prenatal diagnosis is possible.</p>




Picture	Note	Management
<p><b>Down Syndrome (Trisomy 21)</b></p>  <p><b>Figures 13.1.4A and B:</b> Down syndrome (Trisomy 21) Photo Courtesy: Shubha R Phadke</p>	<p>Characteristic flat face, upslant of eyes, hypertelorism with protruding tongue is diagnostic. In spite of easy clinical diagnosis karyotype of each child with Down syndrome is essential as the risk of recurrence in sibs depends on the chromosomal abnormality of the proband (Fig. 13.1.2B). Clinical diagnosis may be difficult in preterm neonates in whom increased gap between first and second toes and single palmar crease may support the clinical impression.</p>	<p>All neonates with Down syndrome should be investigated for hypothyroidism and associated malformations in gut, heart, eyes. Primary prevention is possible by offering ultrasonographic and biochemical screening in first or second trimesters (Triple or quadruple test) to pregnant women of all ages. In addition to traditional karyotyping, fluorescence <i>in situ</i> hybridization (FISH) (Fig. 13.1.2B) and quantitative fluorescence polymerase chain reaction (QF PCR) on amniotic fluid sample can help to provide rapid results of prenatal diagnosis within 48 hours.</p>

### Klinefelter Syndrome


 <p><b>Figure 13.1.5:</b> Klinefelter syndrome Photo Courtesy: Shubha R Phadke</p>	<p>Usually present as tall stature, arrested puberty in boys. Small penis, testes and oligo/azospermia are always present in postpubertal cases. Some may have gynecomastia. Karyotype shows two or more X chromosomes. Patients with mosaicism and normal karyotype in some cells may have milder manifestations.</p>	<p>Testosterone therapy is indicated. Gynecomastia may need surgery. Infertility is universal. Aspiration of sperms from testis and intracytoplasmic sperm injection (ICSI) can help in infertility. Klinefelter patients may need help to have a satisfactory self image and to minimize the psychological problems due to hypogonadism.</p>
--	--	---

### Prader-Willi Syndrome


 <p><b>Figure 13.1.6:</b> Prader-Willi syndrome Photo Courtesy: Shubha R Phadke</p>	<p>Obesity, short stature, small hands and feet, almond shaped eyes, hypogonadism and mental retardation are features. Hypotonia and feeding difficulties are seen in neonates and early infancy. Other than a microdeletion on chromosome 15 of paternal origin, disomy of maternal chromosome 15 and methylation defects of imprinted region on chromosome 15 can cause Prader-Willi syndrome.</p>	<p>Behavioral therapy, diet control are needed. Growth hormone therapy has been tried for control of obesity. Sudden death in a child on growth hormone therapy was reported. Genetic counseling should be provided. Recurrence in sibs is rare and depends on the etiology. Prenatal diagnosis is possible.</p>
--	--	--

Picture	Note	Management
---------	------	------------


### Rubinstein-Taybi Syndrome


 <p><b>Figures 13.1.7A to C:</b> Rubinstein-Taybi syndrome Photo Courtesy: Shubha R Phadke</p>	<p>Broad (bifid and medially deviated) thumbs and great toes with characteristic facial features namely, antimongoloid slant, long beaked nose with overhanging columella clinches the diagnosis. Short stature and mental retardation are seen. Etiologies include a microdeletion on chromosome 16 involving <i>CREBBP</i> gene, mutations in <i>CREBBP</i> gene, <i>EP 300</i> gene and other unknown causes.</p>	<p>Management is supportive. Associated cardiac abnormalities and central nervous system abnormalities like Dandy-Walker anomaly may need treatment.</p>
---	--	--

### Turner Syndrome (Monosomy X)


 <p><b>Figure 13.1.8:</b> Turner syndrome (Monosomy X) Photo Courtesy: Shubha R Phadke</p>	<p>Characteristic features namely short webbed neck, naevi, increased carrying angle, short fourth metacarpal and nail hypoplasia may not be presents in many cases. Commonly presents as delayed puberty or isolated short stature in a prepubertal girl. Some may present with edema of hands and feet during neonatal period (←). Chromosomal abnormality can be 45, X in all cells or in mosaic form or deletion or isochromosome of X. Intelligence is usually normal though learning difficulties in some focal areas may be present.</p>	<p>All girls with Turner syndrome need to be evaluated for cardiac and renal abnormalities at the time of diagnosis and regularly investigated for hypothyroidism and hearing problems. Growth hormone therapy if started early may add 5 to 7 cm to final height. At puberty, girls with Turner syndrome will need to be started on hormone replacement therapy for development of secondary sexual characters and menstrual cycles. Problem of infertility can be managed by assisted reproductive technique using ova donation.</p>
--	---	--

### Velocardiofacial Syndrome

 <p><b>Figures 13.1.9A and B:</b> Velocardiofacial syndrome Photo Courtesy: Shubha R Phadke</p>	<p>The syndrome consists of cardiac abnormality, cleft palate (submucous), pear shaped broad nose (Seen in both children in the picture). Eye abnormalities, other malformations and developmental delay may be present.</p>	<p>Appropriate management of cardiac and associated malformations. Velocardiofacial syndrome is caused by microdeletion of chromosome <i>22q11</i>. FISH or MLPA for <i>22q</i> deletion should be done in all prenatal and postnatal cases with cardiac malformations.</p>
--	--	---


Picture	Note	Management
 <p><b>Figure 13.1.10:</b> Williams syndrome Photo Courtesy: Shubha R Phadke</p>	<p>The main features are a characteristic face, heart defects (aortic or pulmonary stenosis), mental retardation with an outgoing personality and sometimes hypercalcemia in infancy. The facial features consist of periorbital fullness, medial eyebrow flare, a stellate iris pattern, full cheeks and lips, and a wide mouth with a long smooth philtrum. Note the similarity between two patients. The facies may become coarser with age. The deleted region on chromosome 7 includes elastin gene.</p>	<p>Treatment of cardiac problems and supportive therapy for learning disabilities is indicated. Risk of recurrence in sibs is negligible unless the parent has chromosomal deletion which is very rare. Prenatal diagnosis by FISH technique is possible.</p>

### Wolf-Hirschhorn Syndrome (4p Deletion Syndrome)

 <p><b>Figure 13.1.11:</b> Wolf-Hirschhorn syndrome (4p deletion syndrome) Photo Courtesy: Shubha R Phadke</p>	<p>There is hypertelorism, prominent glabella, cleft lip, microcephaly and mental retardation. The chromosomal deletion on 4p may be too small to be detected on karyotype and may need investigations like FISH or multiplex ligation probe amplification (MLPA). MLPA picture in the figure shows small peak of chromosome 4p in patient (small arrow) as compared to that in the control sample (big arrow).</p>	<p>Associated malformations like cardiac anomaly and diaphragmatic hernia need treatment. Genetic counseling is important. If parents do not have structural abnormality of chromosome 4 then the risk of recurrence in the sibs of the patient is not significantly increased. Prenatal diagnosis can be done on amniotic fluid sample or chorionic villi.</p>
--	---	---

## 13.2 SYNDROMES WITH GROWTH DISORDERS

### Beckwith-Wiedemann Syndrome

 <p><b>Figure 13.2.1:</b> Beckwith-Wiedemann syndrome Photo Courtesy: Shubha R Phadke</p>	<p>It is an overgrowth syndrome characterized by macroglossia, visceromegaly, omphalocele and hypoglycemia. Ear pits and creases on ears may be present. Some have hemihypertrophy. The etiology is complex and the disorder can be caused by deletion, mutations or imprinting abnormalities of any of the four genes on chromosome 11p15.5 region.</p>	<p>Increased risk of Wilms tumor and other tumors is observed. Surveillance till growth is complete is indicated. Increased prevalence of Beckwith-Wiedemann syndrome and disorders caused by abnormalities of imprinting are being reported in babies born by artificial reproductive techniques.</p>
--	--	--

Picture	Note	Management
---------	------	------------

### Cockayne Syndrome

	<p>Figure shows a child with Cockayne syndrome at 5 years and 12 years of age. Microcephaly, growth and mental retardation, deep set eyes, deafness, retinal dystrophy and photosensitivity are characteristic features. Changes of premature aging are obvious with age. It is caused by mutations in DNA repair genes namely; <i>ERCC 6</i> and <i>ERCC 8</i>.</p>	<p>No therapy other than supportive therapy is available. Being autosomal recessive in inheritance there is 25% risk of recurrence in the sibs of an affected child. Prenatal diagnosis can be provided if the mutations are detected in the proband of the family or the parents.</p>
--	--	--

**Figures 13.2.2A and B:** Cockayne syndrome  
Photo Courtesy: Shubha R Phadke

### Cornelia de Lange Syndrome

	<p>Characterized by low birth weight, short stature, mental retardation, increased body hair and upper limb defects of varying severity. Facial dysmorphism is characteristic with microcephaly; short upturned nose and synophrys (Note: Facial similarity between two patients). The causative genes are <i>NIPBL</i>, <i>SMC1A</i> and <i>SMC3</i>.</p>	<p>Only supportive management is possible. Mutation detection in clinical settings is practically difficult as any of the 3 genes may be the cause. Most cases are sporadic and risk of recurrence in sibs of the patient is not significantly increased.</p>
--	--	---

**Figure 13.2.3:** Cornelia de Lange syndrome  
Photo Courtesy: ML Kulkarni, Shubha R Phadke

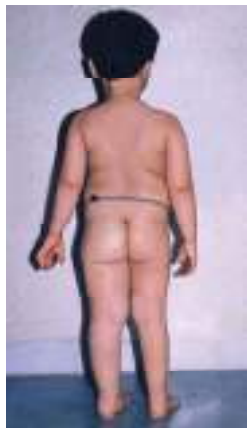### Hallermann-Streiff Syndrome

	<p>Diagnosis is suggested by prominent forehead, pointed nose, small chin and usually presence of microphthalmia and cataract. Sparse hair, dental abnormalities and short stature are other features. Mental retardation is present in a minority of cases.</p>	<p>Management of ophthalmological conditions is warranted.</p>
--	--	--

**Figure 13.2.4:** Hallermann-Streiff syndrome  
Photo Courtesy: ML Kulakarni

Picture	Note	Management
---------	------	------------

### Hemihyperplasia—Isolated

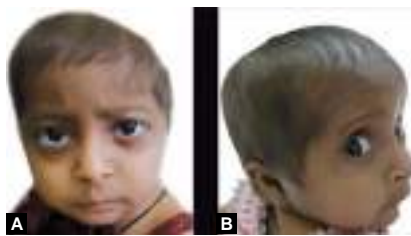

**Figure 13.2.5:** Hemihyperplasia—isolated  
Photo Courtesy: Shubha R Phadke

The diagnosis should be considered after exclusion of syndromes like Klippel-Trenaunay-Weber syndrome, Proteus syndrome, Beckwith-Wiedemann syndrome which are associated with hemihypertrophy. In isolated hemihypertrophy the disproportion is not severe and does not worsen with growth. There may be associated skin hemangiomas or other pigmentary abnormalities.

It is likely to be heterogeneous in etiology with some cases being mild forms of Beckwith-Wiedemann syndrome. There is increased risk of malignancies. Some studies have reported up to 5% risk.

### Microcephalic Osteodysplastic Primordial Dwarfism II (MOPD II)

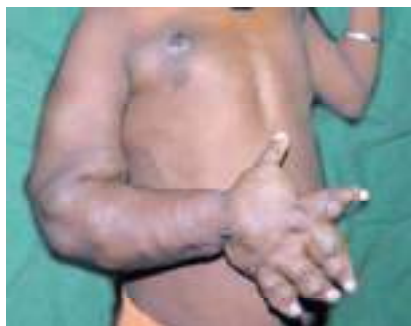

**Figures 13.2.6A and B:** Microcephalic osteodysplastic primordial dwarfism II (MOPD II)  
Photo Courtesy: Shubha R Phadke

It is an autosomal recessive disorder caused by mutations in *PCNT* gene. It is characterized by severe degree of growth retardation and microcephaly with some radiological changes in bones. Though the severity of microcephaly is more than Seckel syndrome; mental retardation is mild or absent. Figure shows two sisters with MOPD II from a consanguineous family.

Management is supportive. Complications like scoliosis may need treatment.

### Proteus Syndrome



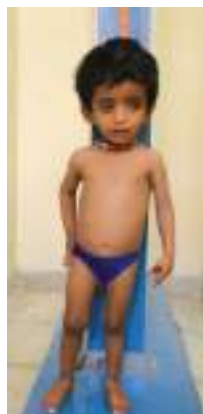**Figure 13.2.7:** Proteus syndrome  
Photo Courtesy: Shubha R Phadke

There is rapidly progressive overgrowth of some of body parts (mosaic distribution) along with asymmetry, nevi, pigmentary abnormalities, hemangiomas, varicosities and lipomas. The distortion of body proportion is disfiguring and handicapping. There may be macrodactyly. Proteus syndrome is associated with mosaicism for a somatic activating mutation in the *AKT1* gene.

Surgical management is difficult and may lead to disfigurement and exaggeration of existing problems.

Picture	Note	Management
---------	------	------------

### Russell-Silver Syndrome



**Figure 13.2.8:** Russell-Silver syndrome  
Photo Courtesy: ML Kulkarni

Prenatal growth retardation, proportionate short stature and limb asymmetry are features. (Right lower limb of the child in the picture is smaller than the left). Relatively normal head circumference gives an appearance of large head. Bluish sclera, clinodactyly, triangular face and café au lait spots are other features. Intelligence is usually normal. Maternal disomy of chromosome 7 is the cause in some cases.

Supportive management and genetic counseling. Growth retardation during fetal life may not be obvious during first-two trimesters.

### Seckel Syndrome

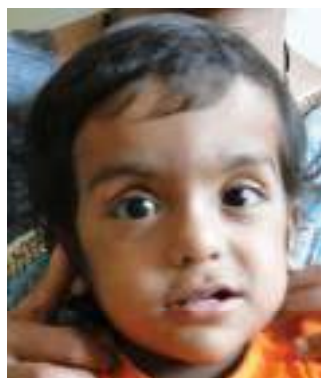

**Figure 13.2.9:** Seckel syndrome  
Photo Courtesy: Shubha R Phadke

Intrauterine growth retardation, severe microcephaly, mental retardation and 'bird like' appearance due to prominent nose are characteristic features. Mode of inheritance is autosomal recessive. Causative genes are 5 and include the gene encoding ataxia telangiectasia.

Intelligence quotient is not as poor as indicated by severe microcephaly. Supportive treatment is necessary.

### Sotos Syndrome



**Figure 13.2.10:** Sotos syndrome  
Photo Courtesy: Shubha R Phadke


The disorder is characterized by rapid growth, advanced bone age with or without mental retardation. The facial phenotype consists of large head, prominent forehead, and prominent chin with mild prognathism. The disorder is caused by mutations in *NSD 1* gene.

Most cases are sporadic and due to de novo mutation. However, if one of the parents is affected the risk in the offspring is 50%. There is increased risk of neoplasms like Wilms tumor, neuroblastoma, hepatoblastoma and leukemia. The risk is reported to be 2%.


### 13.3 LYSOSOMAL STORAGE DISORDERS

Picture	Note	Management
---------	------	------------


#### Fabry Disease

 <p><b>Figures 13.3.1A to C:</b> Fabry disease Photo Courtesy: Shubha R Phadke</p>	<p>An X linked disorder caused by deficiency of alpha-galactosidase presents as episodic burning pain in limbs without any signs (Note the agony on the patient's face). This makes diagnosis difficult and patient may be labeled as a neurotic and diagnosis gets delayed for years. The characteristic angiokeratomas (Fig. 13.3.1C) on skin if present clinches the diagnosis. Corneal deposits and mild coarsening of face are other diagnostic clues.</p>	<p>Enzyme replacement therapy (ERT) is available and it reduces pain and improves quality of life. ERT also reduces the risk of stroke, cardiomyopathy and chronic renal failure which are the main causes of morbidity and mortality in Fabry's disease patients. Relatives including females should be screened for the enzyme deficiency as there is a great deal of variability in the presentation.</p>
---	---	--

#### I-Cell Disease (Mucopolidosis Type II)


 <p><b>Figures 13.3.2A and B:</b> I-cell disease (Mucopolidosis Type II) Photo Courtesy: Shubha R Phadke</p>	<p>This condition is characterized clinically by psychomotor retardation, short stature and Hurler-like features. Most cases present during first year with coarse facial features, joint contractures, gum hypertrophy and hepatosplenomegaly. Motor development may be more severely affected than cognitive development. The etiology is deficiency of an enzyme N-acetyl-<math>\alpha</math>-glucosaminyl phosphotransferase (GNPTA).</p>	<p>Management is supportive. Risk of recurrence in sibs of an affected child is 25%. Though clinical features along with radiological changes of dysostosis multiplex are suggestive of diagnosis; confirmation of diagnosis by enzyme assays is essential for genetic counseling and prenatal diagnosis.</p>
--	---	---

#### Mucopolysaccharidosis I (Hurler Syndrome)


 <p><b>Figures 13.3.3A and B:</b> Mucopolysaccharidosis I (Hurler syndrome) Photo Courtesy: ML Kulkarni, Shubha R Phadke</p>	<p>It is a progressive disorder caused by deficiency of a lysosomal enzyme, alpha-L-iduronidase. The manifestations appear in the form of gibbus, coarsening of facial features, joint stiffening, growth retardation and hepatosplenomegaly. There is clouding of corneas, mental retardation and characteristic bony changes described as dysostosis multiplex. Mild variant is known as MPS I scheie type. Variants of intermediate severity (MPS ISH) have normal cognitive function (girl shown in Figure 13.5.3).</p>	<p>Enzyme replacement therapy helps greatly in improvement in contractures, skin thickening and hepatosplenomegaly and is useful in patients without involvement of brain. Bone marrow transplantation if done before deterioration of cognitive function has shown good results. Being inherited in autosomal recessive fashion, the risk of recurrence in sibs of the affected child is 25% or 1 in 4. Prenatal diagnosis is possible by testing mutations or assaying enzyme in the chorionic villus sample.</p>
---	---	---

Picture	Note	Management
---------	------	------------

### Mucopolysaccharidosis II (Hunter Syndrome)


	<p>The type II mucopolysaccharidosis is inherited in an X-linked fashion. Manifestations are similar to that of MPS I except absence of corneal clouding. Age of onset is one-two years. Confirmation of Hunter syndrome and all lysosomal storage disorders should be done by enzyme assay. Milder variants with normal IQ are known.</p>	<p>Enzyme replacement therapy is available and effective. However cost is enormous. Bone marrow transplantation is another option. Genetic counseling, carrier detection of at risk female relatives and prenatal diagnosis are helpful to the family.</p>
<p><b>Figure 13.3.4:</b> Mucopolysaccharidosis II (Hunter syndrome)  <i>Photo Courtesy:</i> Shubha R Phadke</p>		

### Mucopolysaccharidosis Type IV—Morquio Type


	<p>This is an autosomal recessively inherited type of mucopolysaccharidosis with predominant bone involvement leading to short trunk dwarfism (flattened vertebrae with anterior beaking and changes in metacarpals and metaphyses). Onset may be in the first-two years of life with genu valgum, a short trunk and neck, pectus carinatum and coarse facies. Clouding of the cornea is mild but deafness may be a problem.</p>	<p>Joint laxity, genu valgum, odontoid hypoplasia leading to atlantoaxial dislocation need appropriate treatment. Genetic counseling is important part of management.</p>
<p><b>Figures 13.3.5A to C:</b> Mucopolysaccharidosis type IV—Morquio type  <i>Photo Courtesy:</i> Shubha R Phadke</p>		

## 13.4 SKELETAL DYSPLASIAS

### Achondrogenesis


	<p>There are two types of achondrogenesis caused by DTDST and COL2A1 and need to be differentiated from numerous other neonatal lethal skeletal dysplasias. Thorax is narrow and small and limbs are very small. Radiograph shows characteristic absence of ossification of vertebral bodies.</p>	<p>Lethal in neonatal period. Radiograph, photograph and autopsy of all stillborns should be done for identifying cause of stillbirth and provide genetic counseling. Disproportionately short limbs suggest the possibility of skeletal dysplasia. Prenatal diagnosis by ultrasonography should be offered.</p>
<p><b>Figures 13.4.1A and B:</b> Achondrogenesis  <i>Photo Courtesy:</i> Shubha R Phadke</p>		




Picture	Note	Management
<p><b>Achondroplasia</b></p>  <p><b>Figures 13.4.2A to C:</b> Achondroplasia Photo Courtesy: Shubha R Phadke</p>	<p>Achondroplasia is a common skeletal dysplasia with autosomal dominant inheritance. The diagnosis is possible at birth. The large head with prominent forehead, rhizomelic shortening of limbs, trident hand (during infancy) and short stature are clinical features. Radiological confirmation is by square iliac bones (elephant ear) and decreasing interpeduncular distance in lumbar spine. One specific mutation in <i>FGFR 3</i> gene is seen in most of the cases of achondroplasia and is helpful for prenatal diagnosis.</p>	<p>Role of limb lengthening surgeries and growth hormone therapy is limited and debatable. Associated complications like hydrocephalus, lumbar canal stenosis and sleep apnea may need treatment. Obesity is another complication which needs to be avoided. Risk of recurrence in the sibs of a sporadic case with normal parents is 1 in 400 while the risk in the offspring of a person with achondroplasia is 50%. Ultrasound based prenatal diagnosis is not possible till third trimester.</p>
<p><b>Ellis-Van Creveld Syndrome</b></p>  <p><b>Figures 13.4.3A to C:</b> Ellis-Van creveld syndrome Photo Courtesy: ML Kulkarni, Shubha R Phadke</p>	<p>The cardinal features are short limbed short stature, narrow thorax, postaxial polydactyly, deep set nails and cardiac anomaly. Multiple oral frenula, missing teeth, midline pseudocleft of lip are other features. Narrow thorax may be cause respiratory distress and neonatal death in about half of cases. Mode of inheritance is autosomal recessive and causative genes are <i>EVC</i> genes.</p>	<p>Associated cardiac abnormality will need surgery. Respiratory problems should be managed with care. Though limb shortening may not become obvious before 20 weeks of gestation; prenatal diagnosis can be done by looking for polydactyly by ultrasonography.</p>
<p><b>Osteogenesis Imperfecta (OI)—Type III</b></p>  <p><b>Figures 13.4.4A to C:</b> Osteogenesis imperfecta (OI)—Type III Photo Courtesy: Shubha R Phadke</p>	<p>A well known disease presenting with recurrent fractures and deformities, has many types based on clinical presentation and causative genes. Severity varies greatly. Type II is lethal in neonatal life and type III is most severe of the rest. Limb deformities, blue sclera, joint laxity may be present. Radiographs show marked decrease in bone density and vertebrae may be flattened.</p>	<p>Biphosphonates improve bone density, reduce fracture rate and improve quality of life. Treatment should be done under close supervision. Deafness is a common complication of OI. Severe varieties may be detected by prenatal ultrasonography. Risk of recurrence depends on the type of OI.</p>

Picture	Note	Management
---------	------	------------


### Osteopetrosis

 <p><b>Figures 13.4.5A and B:</b> Osteopetrosis Photo Courtesy: Shubha R Phadke</p>	<p>The inheritance can be recessive or dominant. The causative genes are very many and severity is greatly variable. The cases presenting during childhood are usually of severe variety presenting with pancytopenia, hepatosplenomegaly, prominent forehead with or without optic atrophy. Radiographs show increased bone density and bone in bone appearance.</p>	<p>Bone marrow transplantation is curative. Cranial nerve involvement may need surgical decompression. Recurrence in sibs can be prevented by prenatal diagnosis if mutations are identified in the affected child. Prenatal ultrasonography and radiography cannot pick up increased bone density.</p>
--	---	---

### Pseudoachondroplasia

 <p><b>Figures 13.4.6A to C:</b> Pseudoachondroplasia Photo Courtesy: Shubha R Phadke</p>	<p>Pseudoachondroplasia presents at 2 to 3 years with short stature, short limbs, waddling gait and lumbar lordosis. Joint laxity, small and delayed epiphyses, wide metaphyses and radiological changes in spine give the diagnosis. Face is normal. Causative gene is <i>COMP</i>.</p>	<p>Osteoarthritis, deformities at knee and atlantoaxial dislocation if present need to be treated. Genetic counseling is indicated.</p>
---	--	---

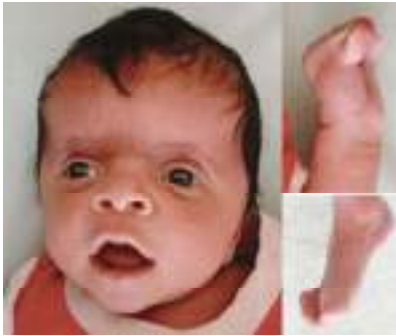### Spondyloepiphyseal Dysplasia (SED)

 <p><b>Figures 13.4.7A to C:</b> Spondyloepiphyseal dysplasia (SED) Child with SED and similarly affected maternal uncle Photo Courtesy: Shubha R Phadke</p>	<p>It is a skeletal dysplasia with predominant trunk shortening (hands reach up to the knees). Platyspondyly (flattened vertebrae) are characteristic. There are many types caused by different genes, the commonest being X linked. (Affected child and his maternal uncle are shown in figure) The manifestations vary from short stature at birth to early onset osteoarthritis in adults. Associated features like cleft palate, myopia may be present in some types of SED.</p>	<p>Osteoarthritis may need medical treatment and joint replacement in some cases. Mode of inheritance can be autosomal or X linked and recessive or dominant. Risk of recurrence depends on accurate diagnosis and family history.</p>
---	--	--

### 13.5 MALFORMATIONS/MALFORMATION SYNDROMES

Picture	Note	Management
---------	------	------------

#### Apert Syndrome (Acrocephalosyndactyly)

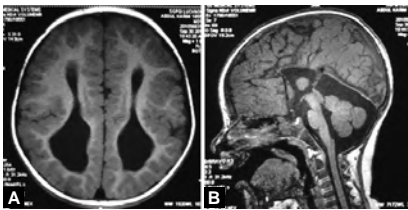


**Figure 13.5.1:** Apert syndrome (Acrocephalosyndactyly)  
Photo Courtesy: ML Kulkarni

Tower shaped skull, prominent eyes, syndactyly of hands (mitten hands) and feet makes clinical diagnosis easy. One common mutation in *FGFR 2* gene accounts for most cases making molecular diagnosis easy. Fifty percent of children are mentally retarded.

Surgery for craniosynostosis should be done as early as possible for best results. Mental retardation may be there in spite of early and good surgery. Hands need plastic surgery work. Prenatal diagnosis is possible.

#### Aplasia of Corpus Callosum (ACC)

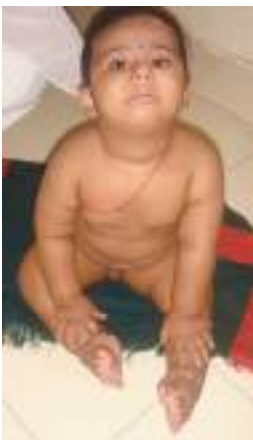

**Figures 13.5.2A and B:** Aplasia of corpus callosum (ACC)  
Photo Courtesy: Shubha R Phadke

Aplasia of corpus callosum (ACC) is infrequently detected in normal individuals. It can be a part of many malformation syndromes. Sagittal MRI brain is necessary for demonstration of ACC. Parallel lateral ventricles and dilatation of posterior horns of lateral ventricles (colpocephaly) in axial CT scan of head and prenatal USG is suggestive of ACC.

Screening for associated malformations and appropriate treatment if present.

#### Bardet-Biedl Syndrome (BBS)



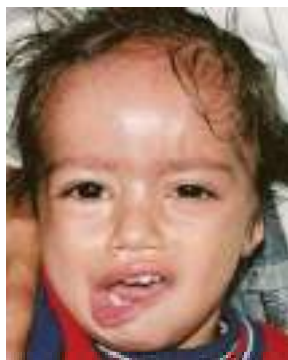**Figure 13.5.3:** Bardet-Biedl syndrome (BBS)  
Photo Courtesy: ML Kulkarni

Characterized by postaxial polydactyly, short stature, obesity, renal problems, retinal degeneration and deafness. Etiology is heterogeneous making molecular diagnosis difficult. Risk of recurrence in the sibs of a child with BBS is 25%.

Supportive management is needed for associated retinal, renal problems and deafness. USG can be used to look for polydactyly for prenatal diagnosis.

Picture	Note	Management
---------	------	------------

### Cardiofacial Syndrome (Asymmetric Crying Facies)

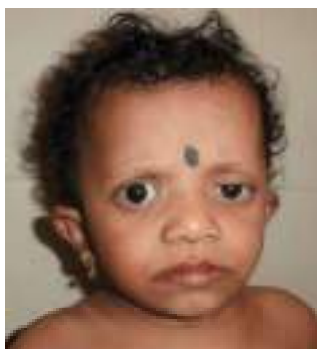

**Figure 13.5.4:** Cardiofacial syndrome (Asymmetric crying facies)  
Photo Courtesy: Shubha R Phadke

It is caused by partial facial palsy or hypoplasia of depressor anguli oris muscle. There may be associated cardiac malformations like ventricular septal defect.

Abnormality is obvious only while crying. Cardiac malformations should be appropriately treated.

### Cardiofaciocutaneous (CFC) Syndrome

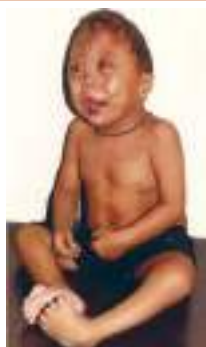

**Figure 13.5.5:** Cardiofaciocutaneous (CFC) syndrome  
Photo Courtesy: ML Kulkarni

Cardiac anomaly with facial dysmorphism like Noonan syndrome, dry skin and sparse, friable and curly hair are features. Head may be large. Pulmonary stenosis is common. CFC syndrome is caused by mutations in *KRAS* and *BRAF* genes.

Surgical management of cardiac malformation is necessary.


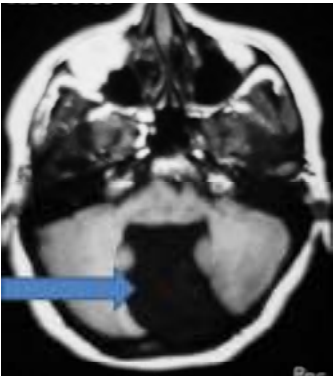
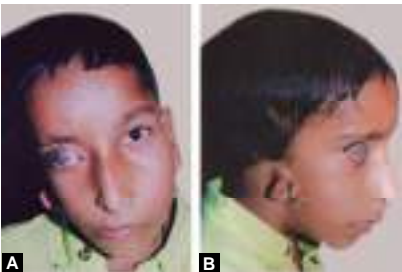
### Carpenter Syndrome (Acrocephalopolysyndactyly II)



**Figure 13.5.6:** Carpenter syndrome (Acrocephalopolysyndactyly II)  
Photo Courtesy: Shubha R Phadke


Preaxial polydactyly in feet and craniosynostosis are features. Mental retardation may or may not be present. Postaxial polydactyly and cardiac anomalies, brachydactyly and syndactyly also may be present. Causative gene is *RAB 23*.

Surgical treatment for craniosynostosis and hand abnormalities is necessary. Mode of inheritance is autosomal recessive and risk of recurrence in the sibs of the patient is 25%. Prenatal diagnosis is possible by ultrasonography or mutation detection.


Picture	Note	Management
<b>Crouzon Syndrome</b>		
 <p data-bbox="106 566 484 612"><b>Figures 13.5.7A and B:</b> Crouzon syndrome Photo Courtesy: ML Kulkarni</p>	<p data-bbox="543 304 930 512">Tower skull, proptosis, midface hypoplasia with beaked nose and dental malocclusion is characteristic. There are no limb abnormalities. Crouzon syndrome is caused by mutations in <i>FGFR 2</i> gene.</p>	<p data-bbox="965 304 1343 540">Possible complications like hydrocephalus, eyeball dislocation may need treatment. Surgical treatment for craniosynostosis is needed during infancy. Risk of recurrence in the offspring of an individual with Crouzon syndrome is 50%.</p>
<b>Dandy-Walker Malformation (DWM)</b>		
 <p data-bbox="106 1171 484 1217"><b>Figure 13.5.8:</b> Dandy-Walker malformation Photo Courtesy: Shubha R Phadke</p>	<p data-bbox="543 778 936 1050">Absence of cerebellar vermis and a large posterior fossa cyst (→) are the characteristic features. DWM can be isolated or a part of chromosomal or nonchromosomal syndromes. Hydrocephalus, aplasia of corpus callosum and other system malformations may be associated.</p>	<p data-bbox="965 778 1311 989">Isolated DWM may have good neurological outcome. Surgical treatment for CNS and non-CNS malformations is needed. Genetic counseling is indicated. There is high-risk of associated chromosomal abnormalities.</p>
<b>Goldenhar Syndrome (Facio-Auriculo-Vertebral Syndrome)</b>		
 <p data-bbox="106 1725 503 1802"><b>Figures 13.5.9A and B:</b> Goldenhar syndrome (Facio-Auriculo-Vertebral syndrome) Photo Courtesy: ML Kulkarni</p>	<p data-bbox="543 1443 933 1715">Characterized by microtia, preauricular ear tags, macrostomia, mandibular hypoplasia and epibulbar dermoid. Both sides of the face may be involved but asymmetrically. There may be associated abnormalities of cervical spine, heart, kidneys, brain and limbs.</p>	<p data-bbox="965 1443 1348 1594">Surgical management of malformations. Most cases are usually sporadic. Risk of recurrence in the sibs is not significantly increased.</p>

Picture	Note	Management
---------	------	------------


### Holoprosencephaly


 <p><b>Figure 13.5.10:</b> Holoprosencephaly Photo Courtesy: Shubha R Phadke</p>	<p>Varying degrees of midline defects of brain are seen in stillborn and live born. Fused thalami and single ventricle is seen in the CT scan of the neonate with microcephaly. Holoprosencephaly was prenatally detected in the baby during third trimester.</p>	<p>An attempt to identify etiology by chromosomal analysis, examination of parents should be done. Single central incisor may be the only feature in a carrier parent. Many genes have been identified, but mutation detection in clinical practice may not be feasible. Prenatal diagnosis is possible by USG.</p>
---	---	---

### Holt-Oram Syndrome


 <p><b>Figures 13.5.11A to C:</b> Holt-Oram syndrome Photo Courtesy: ML Kulkarni</p>	<p>Thumb abnormalities with atrial septal defect are characteristic. Ventricular septal defect and varying degree of forearm involvement may be there. The syndrome is caused by mutations in <i>TBX 5</i> gene.</p>	<p>Cardiac defects need surgical intervention. Intelligence is normal. Prenatal diagnosis of upper limb malformations will be possible by ultrasonographically.</p>
--	--	---

### Noonan Syndrome (NS)

 <p><b>Figures 13.5.12A to C:</b> Noonan syndrome (NS) Photo Courtesy: Shubha R Phadke, ML Kulkarni</p>	<p>Facial features include hypertelorism, ptosis, upturned nose (Figs 13.12.4A and B). The main features are short stature, a short neck with webbing (C) or redundancy of the skin, cardiac anomalies and hypertrophic cardiomyopathy (B-scar of surgery). Pectus deformity may be present. NS is caused by <i>PTPN 11</i> or <i>KRAS</i> gene mutations.</p>	<p>Treatment for cardiac problems is necessary.</p>
--	--	---


Picture	Note	Management
<p><b>Orofaciodigital Syndrome (OFD)—Type IV</b></p>  <p><b>Figures 13.5.13A to C:</b> Orofaciodigital syndrome (OFD)—type IV Photo Courtesy: Shubha R Phadke</p>	<p>Orofaciodigital syndromes are characterized by hypertelorism, cleft lip, polydactyly, bifid tongue, tongue lobulations. There are cardiac, CNS and other malformations. Hypoplastic tibia is characteristic of type IV (OFD_ Mohr Majewski type).</p>	<p>Genetic counseling is indicated. Prenatal diagnosis is possible by ultrasonography.</p>

### Pachygyria

 <p><b>Figure 13.5.14:</b> Pachygyria Photo Courtesy: Shubha R Phadke</p>	<p>Pachygyria is an abnormality of neuronal migration characterized by a few and broad gyri and thick cortex. Etiology is heterogeneous. Head circumference may be normal or small.</p>	<p>Supportive treatment for cognitive deficit, seizures is indicated. Family should be referred for genetic counseling.</p>
---	---	---

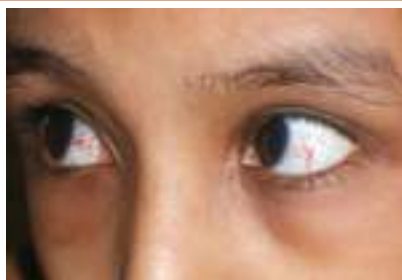## 13.6 MISCELLANEOUS MONOGENIC DISORDERS

### Albinism Type I

 <p><b>Figures 13.6.1A and B:</b> Albinism type I Photo Courtesy: ML Kulkarni</p>	<p>The most common type of albinism (type I) is caused by mutations in tyrosinase gene and is inherited in autosomal recessive fashion. Reduced or absent pigment in skin, hair and eyes is seen. Vision is markedly affected. Iris transillumination, nystagmus, strabismus, high refractive errors, foveal dysgenesis, chorioretinal hypopigmentation are major problems.</p>	<p>Dark glasses for photophobia and appropriate clothing is important. Mutation detection is possible and can help in providing prenatal diagnosis. The risk of recurrence in the sibs of a child with albinism is 25%. Parents are obligate carriers but are clinically normal.</p>
--	---	--

Picture	Note	Management
---------	------	------------

### Ataxia Telangiectasia

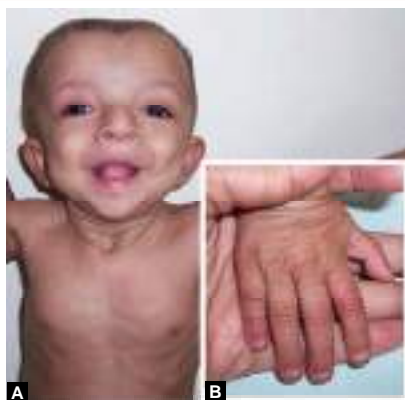

**Figure 13.6.2:** Ataxia telangiectasia  
Photo Courtesy: Shubha R Phadke

An autosomal recessive disorder presenting in early childhood with ataxia, dysarthria, immunodeficiency and conjunctival telangiectasia is caused by mutations in *ATM* gene. There is increased risk of malignancy. Alpha fetoprotein (AFP) is raised in patient's serum.

Only supportive management is possible. Genetic counseling and prenatal diagnosis is indicated. Prenatal diagnosis can only be done if the mutations in the affected patient or carrier parents are detected.

### Cutis Laxa

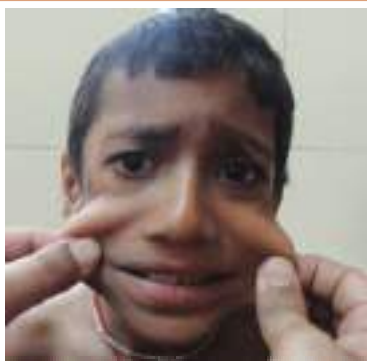

**Figure 13.6.3:** Cutis laxa  
Photo Courtesy: Shubha R Phadke

Cutis laxa is genetically heterogeneous condition. Sagging cheeks, lax and redundant skin, excessive wrinkling are clinical manifestations. Joint dislocations, bladder diverticula, gut rupture can be complications. Autosomal recessive variety is associated with developmental delay. Large anterior fontanelle and wormian bones are seen.

Surveillance for complications and appropriate treatment is necessary. Genetic diagnosis can help in prenatal diagnosis by mutation detection in the chorionic villus sample.

### Ehlers-Danlos Syndrome




**Figure 13.6.4:** Ehlers-Danlos syndrome  
Photo Courtesy: ML Kulkarni

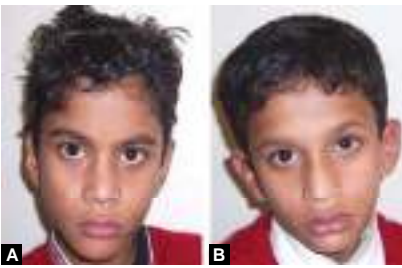
The characteristic features are hyperextensible, soft and velvety skin and joint laxity. Easy bruisability and thin scars are other features. There are many biochemical, clinical and genetic types.

Aneurysms, lens dislocation and other treatable complications should be looked for and treated. Joint laxity may be difficult to treat and may cause handicap. Genetic counseling is indicated.




Picture	Note	Management
 <p><b>Figure 13.6.5:</b> Fanconi pancytopenia Photo Courtesy: Shubha R Phadke</p>	<p>Anemia or pancytopenia presents around 8 years. Thumb abnormalities and radial defects are common. Microcephaly, mental retardation and growth retardation may be present. There is increased risk of cancers. At least 8 causative genes are known. Being a DNA repair disorder the diagnosis can be done by demonstrating chromosomal breakages → and quadri/triradials → in metaphases.</p>	<p>Bone marrow transplantation from HLA matched sibling is the treatment. It should be made sure that the donor sib is not an affected nonmanifesting sib.</p>

### Fragile X Syndrome

 <p><b>Figures 13.6.6A and B:</b> Fragile X syndrome Photo Courtesy: Shubha R Phadke</p>	<p>Figure shows normal facies of two brothers with fragile X syndrome. Mental subnormality of various severity, long face, large head, macroorchidism, joint laxity, hyperactivity, seizures and behavioral problems are features. Clinical features are subtle and not diagnostic. Being an X linked semi-dominant disorder carrier females may be normal or have mild manifestations. The disorder is caused by dynamic triplet repeat mutation.</p>	<p>Being the most common cause of familial mental retardation, counseling and carrier detection of family members is important. All males with idiopathic mental retardation should be tested for Fragile X syndrome by DNA based test. Depending upon IQ, training and habilitation are important. Prenatal diagnosis is possible.</p>
--	--	---

### Griscelli Syndrome with Hemophagocytosis (Type II)

 <p><b>Figures 13.6.7A and B:</b> Griscelli syndrome with hemophagocytosis (Type II) Photo Courtesy: Shubha R Phadke</p>	<p>An autosomal recessive disorder is caused by mutations in <i>RAB 27A</i> gene. The clinical features include silver gray hair, pale skin and immunodeficiency. Recurrent infections can be severe and are accompanied by hepatosplenomegaly, pancytopenia and lymphadenopathy. Investigations reveal a granulocytopenia, abnormal cellular immunity, reduced immunoglobulins, hypertriglyceridemia, hypoproteinemia and erythrophagocytosis. Hair microscopy shows large clumps of pigment. Other types with neurological manifestations or only skin manifestations are caused by other genes.</p>	<p>Bone marrow transplantation from HLA matched donor is successful for cases without neurological manifestations. Cases with isolated skin and hair findings need to be followed up for the possibility of development of immunological or neurological manifestations.</p>
---	--	--

Picture	Note	Management
---------	------	------------

### Larsen Syndrome


	<p>It is a syndrome of joint hypermobility and multiple dislocations. Depressed nasal bridge, flat midface and spatulate fingers are characteristic features. It is a genetically and phenotypically heterogeneous condition.</p>	<p>Joint laxity needs specialist's treatment. Atlanto axial dislocation is a complication to be looked for and treated.</p>
<p><b>Figures 13.6.8A and B:</b> Larsen syndrome Photo Courtesy: Shubha R Phadke</p>		

### Marfan Syndrome


	<p>Hyposthenic build, long arms, arachnodactyly, pectus deformity, scoliosis, joint laxity, flat feet and striae are suggestive of Marfan syndrome. Aortic root dilatation, myopia and lens dislocation are main problems. Marfan syndrome is caused by mutation in <i>FBN 1</i> gene.</p>	<p>Close surveillance for cardiac problems and surgery if needed. Eye problems need specialist's treatment. Beta blockers are given to control progression of cardiac pathology. Recent success of losartan in preventing cardiac complications in animals has prompted trials in humans.</p>
<p><b>Figures 13.6.9A to D:</b> Marfan syndrome Photo Courtesy: ML Kulkarni</p>		

### Neurofibromatosis 1 (NF 1)


	<p>A common disorder inherited in autosomal dominant fashion manifests with neurofibromas, café au lait spots. Some may have mental subnormality. The causative gene is <i>NF 1</i>. Plexiform neurofibromas (seen in right lower limb in Fig. 13.6.1B) may occur in one-third of cases and can be disfiguring.</p>	<p>Complications like scoliosis, pseudoarthrosis of the tibia, and hypertension due to renal artery stenosis, pheochromocytoma, neurofibrosarcomas, meningiomas, and acoustic neuromas will need appropriate treatment. Risk of recurrence in the offspring of a parent with <i>NF 1</i> is 50%. If mutation is detected in the affected individual prenatal diagnosis can be done by chorionic villus sampling. It will confirm presence or absence of mutation in the fetus but cannot give any idea about the severity of manifestations.</p>
<p><b>Figures 13.6.10A and B:</b> Neurofibromatosis 1 (NF 1) Photo Courtesy: ML Kulkarni, Shubha R Phadke</p>		

Picture	Note	Management
<b>Tuberous Sclerosis (TS)</b>		
 <p data-bbox="106 586 515 637"><b>Figures 13.6.11A and B:</b> Tuberous sclerosis (TS) Photo Courtesy: ML Kulkarni</p>	<p data-bbox="543 308 936 665">Tuberous sclerosis is an autosomal dominant disorder with great deal of intrafamilial variability. Seizures and mental retardation are present in 60% and 40% cases respectively. Skin manifestations include adenoma sebaceum (seen in the picture with affected mother and son), hypopigmented patches, shagreen patches, subungual fibromas. Presence of calcified tubers in neuroimaging is diagnostic.</p>	<p data-bbox="965 308 1349 665">Seizures are difficult to control. Angiolipomas of kidney, astrocytoma of brain, rhabdomyoma of heart are possible complications to look for and treat. Causative genes are <i>TSC 1</i> and <i>TSC 2</i>. Mutation detection helps in providing prenatal diagnosis. Parents need to be screened for TS stigmata before counseling. Risk of recurrence in sibs of a sporadic case (normal parents) of TS is 2 to 3%.</p>

**Waardenburg Syndrome (WS)—Type I**

 <p data-bbox="106 1185 460 1257"><b>Figure 13.6.12:</b> Waardenburg syndrome (WS)—Type I Photo Courtesy: Shubha R Phadke</p>	<p data-bbox="543 828 936 1215">This autosomal dominant condition manifests with a white forelock, light colored iris, heterochromia of iris, high nasal bridge, synophrys and dystopia canthorum (Increased distance between inner canthi but normal interpupillary distance. About half of the patients have deafness. Type II WS does not have dystopia canthorum. Cleft lip and palate, Hirschsprung's disease, and a congenital heart defect may be present.</p>	<p data-bbox="965 828 1349 943">Deafness can be treated by hearing aid or cochlear implant with speech therapy. Causative gene is <i>PAX 3</i>. Genetic counseling is indicated.</p>
---	---	--

**X-Linked Anhidrotic Ectodermal Dysplasia**

 <p data-bbox="106 1739 419 1812"><b>Figure 13.6.13:</b> X-linked anhidrotic ectodermal dysplasia Photo Courtesy: Shubha R Phadke</p>	<p data-bbox="543 1415 936 1679">Common ectodermal dysplasia. Affected males have saddle nose, oligodontia, sparse and light colored hair and normal intelligence. Eyebrows and eyelashes are sparse. The affected patients do not sweat and often present in infancy with high fevers. Autosomal varieties of ectodermal dysplasia are known.</p>	<p data-bbox="965 1415 1349 1649">Symptomatic management to prevent hyperpyrexia. Carrier females may have some teeth missing. Mutation in X-linked causative genes, namely <i>EDA 1</i>; if detected, carrier detection and prenatal diagnosis can be provided to the relatives.</p>
--	--	---

## Section 14

---

# Allergy, Rheumatology

### *Section Editors*

Major K Nagaraju, Vijay Viswanathan

### *Photo Courtesy*

Major K Nagaraju, M Ramprakash, Raju P Khubchandani, Vijay Viswanathan

- 14.1 Common Allergic Conditions
- 14.2 Uncommon Allergic Conditions but not Rare
- 14.3 Common Rheumatological Conditions
- 14.4 Uncommon Rheumatological Conditions but not Rare
- 14.5 Musculoskeletal Syndromes

## SECTION OUTLINE

### 14.1 COMMON ALLERGIC CONDITIONS 283

- ◆ Acute Urticaria 283
- ◆ Allergic Conjunctivitis 283
- ◆ Allergic Line 283
- ◆ Allergic Shiners 284
- ◆ Atopic Dermatitis—Face 284
- ◆ Atopic Dermatitis—Elbow (Flexural Eczema) 284
- ◆ CT-Paranasal Sinuses—Normal 285
- ◆ CT-Paranasal Sinuses—Pan Sinusitis 285
- ◆ CT-Paranasal Sinuses—Polyp in Left Maxillary Sinus 285
- ◆ Method of Examination of the Nose 286
- ◆ Papular Urticaria—Insect Bite Allergy 286
- ◆ Phlyctenular Conjunctivitis 286
- ◆ Tonsillar Enlargement 287
- ◆ X-Ray Neck Lateral View for Adenoids 287

### 14.2 UNCOMMON ALLERGIC CONDITIONS BUT NOT RARE 287

- ◆ Allergic Conjunctivitis—Conjunctival Pigments 287
- ◆ Allergic Conjunctivitis—Horner-Trantas Spots 288
- ◆ Allergic Conjunctivitis—Limbal Gelatinous Nodules 288
- ◆ Allergic Conjunctivitis—Limbus Nodules 288
- ◆ Allergic Gape 289
- ◆ Allergic Giant Papillary Conjunctivitis 289
- ◆ Allergic Mannerisms 289
- ◆ Allergic Salute 290
- ◆ Allergic Salute—Alternative Method 290
- ◆ Allergy Skin Testing—Reaction (Forearm) 290
- ◆ Allergy Skin Testing—Reaction (on the Back) 291
- ◆ Autologous Serum Skin Test (ASST) 291
- ◆ Dennis Morgan Folds—Sign of Allergic Rhinitis 291
- ◆ Long Face Syndrome 292
- ◆ Peak Nasal Inspiratory Flow Meter for Assessment of Nasal Obstruction 292

- ◆ Technique of Administration of Intranasal Steroids in a Small Child 292
- ◆ Technique of Administration of Intranasal Steroids in Adolescent 293

### 14.3 COMMON RHEUMATOLOGICAL CONDITIONS 293

- ◆ Enthesitis Related Arthritis 293
- ◆ Juvenile Idiopathic Oligoarthritis 293
- ◆ Juvenile Idiopathic Polyarthritis 294
- ◆ Kawasaki Disease 294
- ◆ Kawasaki Disease—Erythematous Induration Over BCG 294
- ◆ Side Effect of Prolonged Steroid Therapy—Collapsed Vertebra 295
- ◆ Systemic Onset Juvenile Idiopathic Arthritis 295
- ◆ Typical Purpuric Rash of HSP 295

### 14.4 UNCOMMON RHEUMATOLOGICAL CONDITIONS BUT NOT RARE 296

- ◆ Juvenile Dermatomyositis 296
- ◆ Juvenile Dermatomyositis—Nodular Swellings (Calcinosis) 296
- ◆ Juvenile Dermatomyositis—Calcinosis Cutis 296
- ◆ Juvenile Systemic Sclerosis—“Pursed lip” Appearance 297
- ◆ Juvenile Systemic Sclerosis—Flexion Contractures with Hypopigmentation over Bony Points 297
- ◆ Juvenile Systemic Sclerosis—Healed Vasculitic Ulcer 297
- ◆ Linear Scleroderma 298
- ◆ SLE—“Butterfly” Rash 298
- ◆ SLE—Mucositis Involving Central Hard Palate 298

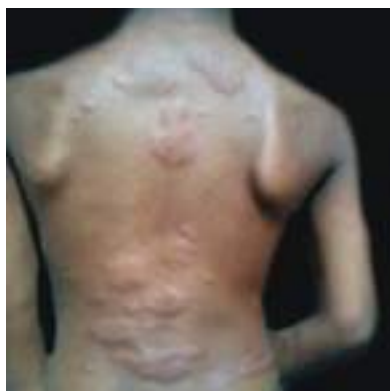### 14.5 MUSCULOSKELETAL SYNDROMES 299

- ◆ Benign Joint Hypermobility Syndrome 299

## 14.1 COMMON ALLERGIC CONDITIONS

Picture	Note	Management
---------	------	------------

### Acute Urticaria

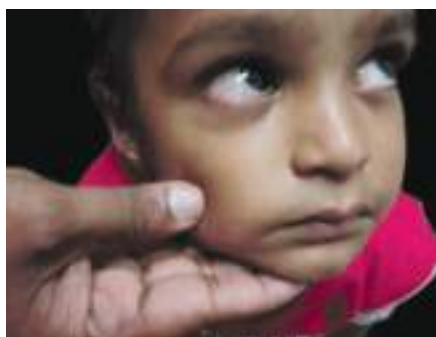

**Figure 14.1.1:** Acute urticaria  
Photo Courtesy: Major K Nagaraju, Chennai

Picture showing raised red skin lesions over the back of 10 years old child, associated with itching. The most common causes are viral infections, food and drugs.

Antihistamines. Steroids if there is angioedema.

### Allergic Conjunctivitis



**Figure 14.1.2:** Allergic conjunctivitis  
Photo Courtesy: Major K Nagaraju, Chennai

Allergic conjunctivitis is inflammation of the conjunctiva due to allergy. Commonly associated with allergic rhinitis.

- Treatment by avoiding causative allergens, local antihistamines and local nonsteroidal anti-inflammatory drugs.
- Sodium chromoglycolate eye drops are used for prophylaxis.




### Allergic Line



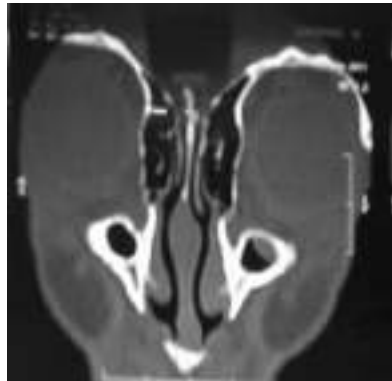


**Figure 14.1.3:** Allergic line  
Photo Courtesy: Major K Nagaraju, Chennai




Dark line between cartilaginous and bony septum due to constant pressing over the cartilaginous portion of the septum for relieving nasal block.




Leukotriene antagonists are useful in seasonal allergic rhinitis and allergic rhinitis associated with asthma.




Picture	Note	Management
<b>Allergic Shiners</b>		
 <p data-bbox="164 600 565 649"><b>Figure 14.1.4:</b> Allergic shiners <i>Photo Courtesy:</i> Major K Nagaraju, Chennai</p>	<p data-bbox="626 277 1027 527">Bluish black discoloration of lower eyelids due to venous stasis in alveolar tissues of lower orbitopalpebral grooves from pressure on veins by edematous allergic mucus membranes of nose and paranasal cavities. It is very useful sign of allergic rhinitis.</p>	<p data-bbox="1070 277 1471 431">Allergic Shiners indicate nasal block. Treat with intranasal steroid or leukotriene antagonists of low systemic bioavailability leukotriene receptor antagonists.</p>
<b>Atopic Dermatitis—Face</b>		
 <p data-bbox="164 1246 565 1295"><b>Figure 14.1.5:</b> Atopic dermatitis—Face <i>Photo Courtesy:</i> Major K Nagaraju, Chennai</p>	<p data-bbox="626 840 1027 993">Picture showing erythematous skin lesion over the cheek in an infant. The most common cause is due to atopic dermatitis, which often associated with itching.</p>	<p data-bbox="1070 840 1471 891">Treat with emollients/mild potency steroids.</p>
<b>Atopic Dermatitis—Elbow (Flexural Eczema)</b>		
 <p data-bbox="164 1792 565 1868"><b>Figure 14.1.6:</b> Atopic dermatitis—Elbow (Flexural eczema) <i>Photo Courtesy:</i> Major K Nagaraju, Chennai</p>	<p data-bbox="626 1463 1027 1555">Flexural erythema more seen in children. One of the manifestation of atopic dermatitis.</p>	<p data-bbox="1070 1463 1471 1514">Treat with emollients/mild potency steroids.</p>




Picture	Note	Management
<p><b>CT-Paranasal Sinuses—Normal</b></p>  <p><b>Figure 14.1.7:</b> CT-Paranasal Sinuses—Normal Photo Courtesy: Major K Nagaraju, Chennai</p>	<p>CT scan of paranasal sinuses—Coronal view showing normal maxillary sinuses, ethmoidal sinuses, patency of osteomeatal complex and bilateral agenesis of frontal sinuses in a child.</p> <p>Axial and coronal views are used to assess sinusitis, polyps and the patency of osteomeatal complex.</p>	<p><i>Acute sinusitis:</i> Treat with Co-amoxiclav for 10 to 14 days.</p>
<p><b>CT-Paranasal Sinuses—Pan Sinusitis</b></p>  <p><b>Figure 14.1.8:</b> CT-Paranasal sinuses—Pan sinusitis Photo Courtesy: Major K Nagaraju, Chennai</p>	<p>CT paranasal sinuses showing bilateral maxillary sinusitis. Ethmoidal sinusitis with bilateral osteomeatal block.</p>	<ul style="list-style-type: none"> <li>• <i>Chronic sinusitis:</i> Antimicrobials for six weeks.</li> <li>• <i>Resistance cases:</i> Refer for surgery. Other indications for sinus surgery are antrochoanal polyp, orbital abscess and intracranial complications due to sinusitis.</li> </ul>
<p><b>CT-Paranasal Sinuses—Polyp in Left Maxillary Sinus</b></p>  <p><b>Figure 14.1.9:</b> CT-Paranasal sinuses—Polyp in left maxillary sinus Photo Courtesy: Major K Nagaraju, Chennai</p>	<p>CT-Paranasal sinuses—Coronal view in a 12 years old showing polyp in the left maxillary sinus.</p>	<p>Polyps can be managed with minimal invasive functional endoscopic sinus surgery.</p>






Picture	Note	Management
<b>Method of Examination of the Nose</b>		
 <p data-bbox="164 645 594 727"><b>Figure 14.1.10:</b> Method of examination of the nose <i>Photo Courtesy:</i> Major K Nagaraju, Chennai</p>	<p data-bbox="626 273 1037 461">In children examination of nose can be better done by lifting the tip of the nose of patient with thumb of the examiner to visualize the nasal mucosa, septum and inferior turbinates.</p> <p data-bbox="626 472 1037 533">Children will be very scared if we use nasal speculum.</p>	<p data-bbox="1070 273 1484 369">Examination of the nose forms an important part of respiratory system.</p>
<b>Papular Urticaria—Insect Bite Allergy</b>		
 <p data-bbox="164 1279 594 1371"><b>Figure 14.1.11:</b> Papular urticaria—Insect bite allergy <i>Photo Courtesy:</i> Major K Nagaraju, Chennai</p>	<p data-bbox="626 880 1037 1167">Papular urticaria is a common and often annoying disorder manifested by chronic or recurrent papules caused by a hypersensitivity reaction to the bites of mosquitoes, fleas, bedbugs, and other insects. Individual papules may surround a wheal and display a central punctum.</p>	<p data-bbox="1070 880 1484 1003">Self-limited, and children eventually outgrow this disease, probably through desensitization after multiple arthropod exposures.</p>
<b>Phlyctenular Conjunctivitis</b>		
 <p data-bbox="164 1821 594 1870"><b>Figure 14.1.12:</b> Phlyctenular conjunctivitis <i>Photo Courtesy:</i> Major K Nagaraju, Chennai</p>	<p data-bbox="626 1514 1037 1667">Phlyctenular is a type IV hypersensitivity to an antigen present elsewhere in the body. It presents as a conjunctival nodule at the limbus with congestion.</p>	<p data-bbox="1070 1514 1484 1545">Treatment is topical steroids.</p>




Picture	Note	Management
<b>Tonsillar Enlargement</b>		
 <p data-bbox="138 605 540 656"><b>Figure 14.1.13:</b> Tonsillar enlargement Photo Courtesy: Major K Nagaraju, Chennai</p>	<p data-bbox="602 269 862 300"><i>Tonsillar enlargement:</i></p> <p data-bbox="602 308 964 404"><i>Grade 1:</i> Tonsils just outside of the tonsillar fossa, <math>\leq 25\%</math> of the oropharyngeal width.</p> <p data-bbox="602 412 1003 476"><i>Grade 2:</i> Tonsils occluding 26 to <math>\leq 50\%</math> of the oropharyngeal width.</p> <p data-bbox="602 484 987 547"><i>Grade 3:</i> Tonsils occluding 51 to <math>&lt; 75\%</math> of the oropharyngeal width.</p> <p data-bbox="602 555 997 652"><i>Grade 4:</i> Tonsils occluding greater than 75% of the oropharyngeal width.</p>	<p data-bbox="1045 269 1451 427">Tonsillectomy indicated in patients with three or more infections of tonsils per year in each of the preceding three years despite adequate medical therapy.</p>
<b>X-Ray Neck Lateral View for Adenoids</b>		
 <p data-bbox="138 1222 540 1293"><b>Figure 14.1.14:</b> X-ray neck lateral view for adenoids Photo Courtesy: Major K Nagaraju, Chennai</p>	<p data-bbox="602 788 1013 852">X-ray neck lateral view showing soft tissue shadow.</p> <p data-bbox="602 860 948 923">(Adenoids) compromising the Nasopharyngeal airway.</p> <p data-bbox="602 932 1018 1028">Adenoid hypertrophy will compromise the nasopharyngeal air passage.</p>	<p data-bbox="1045 788 1446 913">Adenoidectomy is indicated in severe obstructive sleep apnea and recurrent acute otitis media or chronic serous otitis media.</p>
<b>14.2 UNCOMMON ALLERGIC CONDITIONS BUT NOT RARE</b>		
<b>Allergic Conjunctivitis—Conjunctival Pigments</b>		
 <p data-bbox="138 1794 496 1896"><b>Figure 14.2.1:</b> Allergic conjunctivitis—Conjunctival pigments Photo Courtesy: Major K Nagaraju, M Ramprakash, Chennai</p>	<p data-bbox="602 1483 1013 1669">Pigment deposition in the conjunctiva occurs in chronic allergic conjunctivitis and clinically is evident as muddy conjunctiva. This is a sign of chronic allergic conjunctivitis.</p>	<p data-bbox="1045 1483 1297 1514">No treatment needed.</p>


Picture	Note	Management
<b>Allergic Conjunctivitis—Horner-Trantas Spots</b>		
	<p>Horner-Trantas spots are fine white spots found at the limbus and are due to accumulation of eosinophils.</p>	<p>Treated with fluoromethalone eye drops or loteprednol eye drops along with tear substitutes.</p>
<p><b>Figure 14.2.2:</b> Allergic conjunctivitis—Horner-Trantas spots  <i>Photo Courtesy:</i> Major K Nagaraju, M Ramprakash, Chennai</p>		
<b>Allergic Conjunctivitis—Limbal Gelatinous Nodules</b>		
	<p>Normally seen in allergic conjunctivitis. This has to be differentiated from phlyctenular keratoconjunctivitis by slit-lamp examination.</p>	<p>Treated with topical anti-inflammatory agents or with topical steroids. Tear substitutes provide relief from itching.</p>
<p><b>Figure 14.2.3:</b> Allergic conjunctivitis—Limbal gelatinous nodules  <i>Photo Courtesy:</i> Major K Nagaraju, M Ramprakash, Chennai</p>		
<b>Allergic Conjunctivitis—Limbus Nodules</b>		
	<p>Accumulation of WBCs and conjunctival hypertrophy at the limbus (presents as gelatinous nodules) or in the upper tarsal conjunctiva.</p>	<p>Dual acting drugs like olopatadine ketotifen eye drops can be used.</p>
<p><b>Figure 14.2.4:</b> Allergic conjunctivitis—Limbus nodules  <i>Photo Courtesy:</i> Major K Nagaraju, M Ramprakash, Chennai</p>		

Picture	Note	Management
<b>Allergic Gape</b>		
 <p data-bbox="138 637 540 690"><b>Figure 14.2.5:</b> Allergic gape Photo Courtesy: Major K Nagaraju, Chennai</p>	<p data-bbox="602 271 1013 431">See this child is having open mouth—due to mouth breathing. It is one of the sign's of allergic rhinitis in which due to nasal block child breathes through the mouth.</p>	<p data-bbox="1045 271 1435 333"><i>Allergic rhinitis:</i> Intranasal steroids are the drug of choice in blockers.</p>
<b>Allergic Giant Papillary Conjunctivitis</b>		
 <p data-bbox="138 1183 487 1291"><b>Figure 14.2.6:</b> Allergic giant papillary conjunctivitis Photo Courtesy: Major K Nagaraju, M Ramprakash, Chennai</p>	<p data-bbox="602 872 1013 1032">The septae separating the papillae rupture, leading to formation of giant papillae in the upper tarsal conjunctiva. Can be seen in contact lens users also.</p>	<p data-bbox="1045 872 1409 934">Treated with anti-inflammatory agents or steroids.</p>
<b>Allergic Mannerisms</b>		
 <p data-bbox="138 1819 540 1876"><b>Figure 14.2.7:</b> Allergic mannerisms Photo Courtesy: Major K Nagaraju, Chennai</p>	<p data-bbox="602 1453 1013 1514">Child exhibiting facial grimaces due to nasal block.</p>	<p data-bbox="1045 1453 1409 1575">For treatment of allergic rhinitis avoid first generation antihistamines due to cognitive impairment and sedation.</p>

Picture	Note	Management
<p><b>Allergic Salute</b></p>  <p><b>Figure 14.2.8:</b> Allergic salute Photo Courtesy: Major K Nagaraju, Chennai</p>	<p>Child constantly rub the tip of the nose to relieve itching and free the edematous turbinate from septum.</p>	<p>Subcutaneous or sublingual immunotherapy is recommended in one or two antigens responsible for symptoms of AR and in cases not responding to pharmacotherapy.</p>
<p><b>Allergic Salute—Alternative Method</b></p>  <p><b>Figure 14.2.9:</b> Allergic salute—Alternative method Photo Courtesy: Major K Nagaraju, Chennai</p>	<p>This clinical picture is commonly seen in our day-to-day office practice as a manifestation of allergic salute.</p>	<p>Treat with intranasal steroids to relieve the nasal obstruction.</p>
<p><b>Allergy Skin Testing—Reaction (Forearm)</b></p>  <p><b>Figure 14.2.10:</b> Allergy skin testing—Reaction (Fore arm) Photo Courtesy: Major K Nagaraju, Chennai</p>	<p>Allergy skin testing is done using lancet for prick method which is the common method used to detect the sensitization of body to allergen.</p> <p>Interpretation done by measuring the size of the wheal. If wheal &gt;2 cm of negative control its significant.</p>	<ul style="list-style-type: none"> <li>• Allergy skin test is the prerequisite for immunotherapy.</li> <li>• Sensitivity and specificity for upper respiratory symptoms 94% and 80%, where as lower respiratory symptoms 84% and 87%. For food allergies 76 to 98% sensitivity and 29 to 57% specificity.</li> </ul>

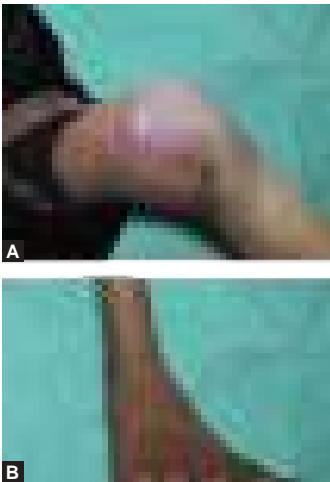
Picture	Note	Management
<b>Allergy Skin Testing—Reaction (on the Back)</b>		
 <p data-bbox="136 641 565 717"><b>Figure 14.2.11:</b> Allergy skin testing—Reaction (on the back) Photo Courtesy: Major K Nagaraju, Chennai</p>	<p data-bbox="602 267 1013 329">Highly sensitive site for allergy skin testing is back of the body.</p>	<p data-bbox="1045 267 1446 396">It is very difficult to perform over the back and so next sensitive portion viz. volar surface of the forearm is commonly used.</p>
<b>Autologous Serum Skin Test (ASST)</b>		
 <p data-bbox="136 1214 537 1289"><b>Figure 14.2.12:</b> Autologous serum skin test (ASST) Photo Courtesy: Major K Nagaraju, Chennai</p>	<p data-bbox="602 868 1013 1030">ASST is useful in autoimmune and chronic urticaria patients who exhibit functional autoantibodies against IgE and/or its high-affinity receptor FcεRI.</p>	<p data-bbox="1045 868 1446 1030">Autoimmune urticaria treated with high doses of antihistamines, systemic corticosteroids and sometimes immunomodulator drugs.</p>
<b>Dennis Morgan Folds—Sign of Allergic Rhinitis</b>		
 <p data-bbox="136 1786 565 1862"><b>Figure 14.2.13:</b> Dennis Morgan folds—Sign of allergic rhinitis Photo Courtesy: Major K Nagaraju, Chennai</p>	<p data-bbox="602 1453 1013 1561">Creases in the lower eyelid due to Mueller's muscle spasm. One of the sign's of allergic rhinitis.</p>	<p data-bbox="1045 1453 1446 1561"><i>Allergic rhinitis:</i> Mainly by oral 2<sup>nd</sup> generation antihistamines, intranasal steroids.</p>

Picture	Note	Management
<b>Long Face Syndrome</b>		
 <p data-bbox="164 649 594 703"><b>Figure 14.2.14:</b> Long face syndrome <i>Photo Courtesy:</i> Major K Nagaraju, Chennai</p>	<p data-bbox="626 273 1037 335">Constant mouthbreathing causes unbalanced muscle.</p> <p data-bbox="626 345 1037 472">Forces, which compresses the upper jaw, which creates a very high vault in the palate and increases the overall length of the lower face.</p>	<p data-bbox="1070 273 1451 400">Laser maxillofacial surgery performed specially after completion of bony growth helps the patient.</p>
<b>Peak Nasal Inspiratory Flow Meter for Assessment of Nasal Obstruction</b>		
 <p data-bbox="164 1195 561 1275"><b>Figure 14.2.15:</b> Peak nasal inspiratory flow meter for assessment of nasal obstruction <i>Photo Courtesy:</i> Major K Nagaraju, Chennai</p>	<p data-bbox="626 846 1037 1034">Portable inspiratory flow meter can be used to monitor both the nasal obstruction and the response to treatment, through objective assessment of congestion within the nasal passages.</p>	<p data-bbox="1070 846 1476 999">Recordings over several weeks provide detailed information about changes in the nasal airways, and correlate well with both symptom scores.</p>
<b>Technique of Administration of Intranasal Steroids in a Small Child</b>		
 <p data-bbox="164 1774 594 1855"><b>Figure 14.2.16:</b> Technique of administration of intranasal steroids in a small child <i>Photo Courtesy:</i> Major K Nagaraju, Chennai</p>	<p data-bbox="626 1418 1037 1575">Nostril of the device to be directed into inferior turbinate towards outer canthus of the ear and should be directed away from septum to prevent perforation.</p> <p data-bbox="626 1586 1016 1678">Intranasal steroids recommended for three months as per the guidelines.</p>	<p data-bbox="1070 1418 1484 1510">Intranasal steroids forms the corner stone of therapy in moderate-to-severe allergic rhinitis.</p>

Picture	Note	Management
 <p><b>Figure 14.2.17:</b> Technique of administration of intranasal steroids in adolescent <i>Photo Courtesy:</i> Major K Nagaraju, Chennai</p>	<p>Use right hand for left nostril and left hand for right nostril intranasal steroids are recommended for moderate-severe allergic rhinitis and blocked nose.</p>	<p>Right technique for the right duration of time helps to prevent the local complications of intranasal steroids.</p>

### 14.3 COMMON RHEUMATOLOGICAL CONDITIONS


#### Enthesitis Related Arthritis (ERA)

 <p><b>Figures 14.3.1A and B:</b> Enthesitis related arthritis <i>Photo Courtesy:</i> Vijay Viswanathan, Mumbai</p>	<p>A preadolescent boy with pain and swelling over left knee and right ankle (insertion of achilles tendon)—asymmetrical large joint involvement of lower extremities. Enthesitis related arthritis. Enthesitis is inflammation of attachment of a ligament, tendon, joint capsule or fascia to bone.</p>	<ul style="list-style-type: none"> <li>• HLA-B27 and rheumatoid factor needs to be sent in these cases.</li> <li>• Treatment options include intra-articular triamcinolone acetate, use of systemic steroids with disease modifying antirheumatic drugs (DMARDs) in resistant disease.</li> </ul>
---	---	---


#### Juvenile Idiopathic Oligoarthritis

 <p><b>Figure 14.3.2:</b> Juvenile idiopathic oligoarthritis <i>Photo Courtesy:</i> Vijay Viswanathan, Mumbai</p>	<p>A five years old girl unilateral large joint swelling for 8 weeks with significant wasting of the quadriceps. This is very classical of juvenile idiopathic oligoarthritis.</p>	<ul style="list-style-type: none"> <li>• Ruling out infections, bleeding disorders and tumors essential.</li> <li>• ANA (for associated uveitis) and Rheumatoid factor (RF negative polyarthritis) needs to be investigated in these cases.</li> <li>• Treatment options include intra-articular triamcinolone acetate, use of systemic steroids with DMARDs in resistant disease.</li> </ul>
--	--	---




Picture	Note	Management
 <p><b>Figures 14.3.3A to D:</b> Juvenile idiopathic polyarthritis Photo Courtesy: Vijay Viswanathan, Mumbai</p>	<p>A ten years old girl bilateral symmetrical joint swelling—wrists, knees, ankles and metacarpophalangeal joints with PIP joints, tenderness and restriction of movements (large and small joints). This is very classical of juvenile idiopathic polyarthritis.</p>	<p>Rheumatoid factor needs to be sent in these cases (for prognostication). Also aggressive management with steroids, DMARDs (methotrexate, leflunomide) and in resistant cases, biological agents (anti-TNF alpha-agents).</p>

### Kawasaki Disease

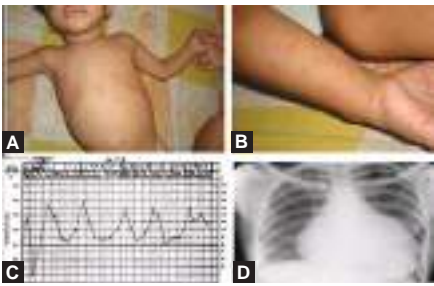
 <p><b>Figure 14.3.4:</b> Kawasaki disease Photo Courtesy: Vijay Viswanathan, Mumbai</p>	<p>A seven years old girl with persistent pyrexia, tender unilateral cervical adenopathy. Examination reveals the classical strawberry tongue (due to diffuse erythema and prominent papillae) and the oral mucositis. Cervical adenopathy with oral mucositis (strawberry tongue) form a part of the criteria for Kawasaki disease.</p>	<ul style="list-style-type: none"> <li>• 2 D echocardiogram always mandatory in investigation.</li> <li>• Treatment consists of intravenous gammaglobulin and high dose aspirin followed by antiplatelet doses of aspirin. Resistant cases may be treated with steroids and/or TNF alpha-blockers.</li> </ul>
--	--	---

### Kawasaki Disease—Erythematous Induration Over BCG


 <p><b>Figure 14.3.5:</b> Kawasaki disease—Erythematous induration over BCG Photo Courtesy: Vijay Viswanathan, Mumbai</p>	<p>A six months old child with persistent pyrexia, rash, irritability, loose motions. Examination reveals mucositis along with an erythematous indurated BCG scar. This phenomenon has been ascribed to cross-reactivity between mycobacterial heat shock protein (HSP) 65 and human homologue HSP 63.</p>	<p><i>Significance:</i> Incomplete Kawasaki disease (KD) does not present with all the criteria. Early diagnosis is important as these children are more prone to cardiac complications. Reactivation of BCG is a rare but specific sign of KD; hence can be used as a tool for diagnosing KD.</p>
--	--	--

Picture	Note	Management
<p><b>Side Effect of Prolonged Steroid Therapy—Collapsed Vertebra</b></p>  <p><b>Figure 14.3.6:</b> Side effect of prolonged steroid therapy—Collapsed vertebra Photo Courtesy: Raju P Khubchandani, Mumbai</p>	<p>A ten years old girl diagnosed with systemic onset juvenile idiopathic arthritis on prolonged steroid therapy. Presented with backache. Imaging reveals a collapsed vertebra secondary to steroid therapy.</p>	<p>In cases of chronic inflammatory conditions on prolonged immunosuppression, it is important to rule out complications of therapy. Treatment comprises of supportive management, calcium supplements and bisphosphonates.</p>




### Systemic Onset Juvenile Idiopathic Arthritis




 <p><b>Figures 14.3.7A to D:</b> Systemic onset juvenile idiopathic arthritis Photo Courtesy: Vijay Viswanathan, Mumbai</p>	<p>A two years old boy presented with persistent pyrexia for four weeks and rash. Examination reveals a classical macular evanescent, erythematous rash over trunk, extremities and abdomen. (A and B) Also the quotidian pattern of fever (C) is specific for systemic onset juvenile idiopathic arthritis (SOJIA). Associated criteria include lymphadenopathy, organomegaly and serositis—pericardial effusion (D).</p>	<ul style="list-style-type: none"> <li>• Investigations reveal anemia of chronic inflammation, neutrophilic leukocytosis and thrombocytosis with elevated acute phase markers.</li> <li>• Treatment comprises of anti-inflammatory agents along with systemic steroids. DMARDs like methotrexate used with moderate success in managing arthritis. Anti interleukin-1 and anti-IL6 used in resistant disease.</li> </ul>
---	--	--




### Typical Purpuric Rash of HSP

 <p><b>Figure 14.3.8:</b> Typical purpuric rash of HSP Photo Courtesy: Vijay Viswanathan, Mumbai</p>	<p>A five years old girl acute onset abdominal pain and eruptions over lower extremities. Examination reveals the typical lesions of Henoch Schonlein purpura on the lower extremities and buttocks (dependent area of body). Classic lesions consist of urticarial wheals, erythematous maculo papules and larger, palpable ecchymosis—like lesions. Petechiae and target lesions may be present as well.</p>	<p>Usually symptomatic. Steroids indicated for renal, severe abdominal/CNS manifestations.</p>
---	--	--

## 14.4 UNCOMMON RHEUMATOLOGICAL CONDITIONS BUT NOT RARE

Picture	Note	Management
<p><b>Juvenile Dermatomyositis</b></p>  <p><b>Figures 14.4.1A and B:</b> (A) Gottron's papules; (B) Dyspigmented lesions over the elbows in the same patient Photo Courtesy: Vijay Viswanathan, Mumbai</p>	<p>A five years old with skin lesions since 1 year. Developed muscle proximal weakness one year later. Gottron's papules are considered a hallmark sign of dermatomyositis. Primary lesions consist of erythematous to violaceous symmetrical papules and plaques over the extensor surfaces of metacarpal and interphalangeal joints and over knees, elbows, and ankles. Secondary changes can be present, including scaling, crusting, erosions, ulcerations or dyspigmentation.</p>	<p>Combination of steroids with disease modifying agents (DMARDs) like methotrexate with hydroxychloroquine. Immunosuppression with cyclophosphamide in cases with severe organ involvement.</p>
<p><b>Juvenile Dermatomyositis—Nodular Swellings (Calcinosis)</b></p>  <p><b>Figure 14.4.2:</b> Juvenile dermatomyositis—Nodular swellings Photo Courtesy: Raju P Khubchandani, Mumbai</p>	<p>A ten years old girl diagnosed case of juvenile dermatomyositis with nodular deposits. This is a known complication of chronic juvenile dermatomyositis. Calcinosis cutis in JDM represents a aggressive inflammation with a delayed diagnoses. It is seen in 40% of cases in the late stages.</p>	<p>Various modalities have been tried, bisphosphonates, diltiazem, etc. It is usually resistant to treatment modalities. Aggressive disease control reduces chances of calcification.</p>
<p><b>Juvenile Dermatomyositis—Calcinosis Cutis</b></p>  <p><b>Figures 14.4.3A and B:</b> Juvenile dermatomyositis—Calcinosis cutis Photo Courtesy: Raju P Khubchandani, Mumbai</p>	<p>X-ray imaging of the same patient as in Figures 14.4.2, revealing dense calcium nodules.</p>	<p>Various modalities have been tried, bisphosphonates, diltiazem, etc. It is usually resistant to treatment modalities. Aggressive disease control reduces chances of calcification.</p>

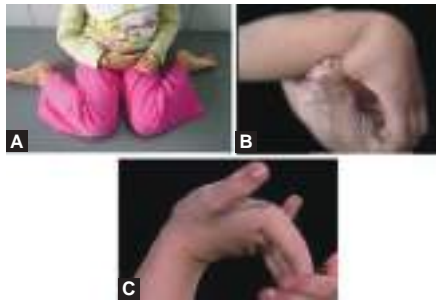
Picture	Note	Management
<b>Juvenile Systemic Sclerosis—“Pursed lip” Appearance</b>		
 <p data-bbox="138 629 570 705"><b>Figure 14.4.4:</b> Juvenile systemic sclerosis—“Pursed lip” appearance <i>Photo Courtesy:</i> Raju P Khubchandani, Mumbai</p>	<p data-bbox="602 271 1013 649">A ten years old girl presented with difficulty in opening mouth, progressive deformities of fingers and ulcers over bony prominences. The examination reveals the classic “pursed lip” appearance with loss of facial folds and narrow nose, shiny skin, with contractures and vasculitic ulcers over bony prominences. The findings are typical for juvenile systemic sclerosis.</p>	<p data-bbox="1045 271 1450 527">ANA, anti-SCL 70 (specific for topoisomerase 1) needs to be sent. Organ involvement (renal, pulmonary, cardiac, GI and neurological) to be ruled out. Treated with steroids, DMARDs, and immunosuppression (organ involvement).</p>
<b>Juvenile Systemic Sclerosis— Flexion Contractures with Hypopigmentation over Bony Points</b>		
 <p data-bbox="138 1185 570 1261"><b>Figure 14.4.5:</b> Juvenile systemic sclerosis—Hypopigmentation over bony points <i>Photo Courtesy:</i> Raju P Khubchandani, Mumbai</p>	<p data-bbox="602 899 1013 1089">Same patient as in Figure 14.4.4. The fingers show a shiny taut skin with flexion deformities of the PIP joints and shiny hypopigmentation over bony points. The findings are typical for juvenile systemic sclerosis.</p>	<p data-bbox="1045 899 1450 1154">ANA, anti-SCL 70 (specific for topoisomerase 1) needs to be sent. Organ involvement (renal, pulmonary, cardiac, GI and neurological) to be ruled out. Treated with steroids, DMARDs, and immunosuppression (organ involvement).</p>
<b>Juvenile Systemic Sclerosis—Healed Vasculitic Ulcer</b>		
 <p data-bbox="138 1800 570 1876"><b>Figure 14.4.6:</b> Juvenile systemic sclerosis—Healed vasculitic ulcer <i>Photo Courtesy:</i> Raju P Khubchandani, Mumbai</p>	<p data-bbox="602 1457 1013 1647">Same patient as in Figure 14.4.4. Healed vasculitic ulcer over the lateral malleolus with the adjacent taut looking shiny skin. The findings are typical for juvenile systemic sclerosis.</p>	<p data-bbox="1045 1457 1450 1712">ANA, anti-SCL 70 (specific for topoisomerase 1) needs to be sent. Organ involvement (renal, pulmonary, cardiac, GI and neurological) to be ruled out. Treated with steroids, DMARDs, and immunosuppression (organ involvement).</p>

Picture	Note	Management
<p><b>Linear Scleroderma</b></p>  <p><b>Figures 14.4.7A and B:</b> Linear scleroderma Photo Courtesy: Vijay Viswanathan, Mumbai</p>	<p>A eight years old girl presented with difficulty in walking with pain over right ankle over the last three months. Examination revealed flesh colored, waxy, shiny lesion appearing like a broad band running along the entire extremity (Fig. 14.4.7A). She had involvement of underlying joint, muscle and fascia (Fig. 14.4.7B). Interestingly the involved ankle also revealed synovitis.</p>	<p>Management consist DMARDs like methotrexate with/without steroids. Intra-articular steroids do benefit in localized synovitis.</p>
<p><b>SLE—“Butterfly” Rash</b></p>  <p><b>Figure 14.4.8:</b> SLE—“Butterfly” rash Photo Courtesy: Raju P Khubchandani, Mumbai</p>	<p>A 10 years old girl with persistent pyrexia, rash, mouth ulcers, arthralgias. Examination reveals the typical malar rash of systemic lupus erythematosus sparing the nasolabial folds.</p> <p>The malar rash of lupus is red or purplish and mildly scaly having the shape of a butterfly and involves the bridge of the nose. Notably, the rash spares the naso labial folds of the face. It is usually macular with sharp edges and not itchy. Rash occurs in 70 to 80% of cases.</p>	<p>Anti-dsDNA, other antibodies to extractable nuclear antigens (ENAs) and urinalysis need to be sent. Organ involvement needs to be ruled out.</p>
<p><b>SLE—Mucositis Involving Central Hard Palate</b></p>  <p><b>Figure 14.4.9:</b> SLE—Mucositis involving central hard palate Photo Courtesy: Raju P Khubchandani, Mumbai</p>	<p>Same patient as in Figure 14.4.8, 10 years old girl with mucositis involving the central part of hard palate—typical feature of SLE.</p>	<p>Anti-dsDNA, other antibodies to extractable nuclear antigens (ENAs) and urinalysis need to be sent. Organ involvement needs to be ruled out.</p>

## 14.5 MUSCULOSKELETAL SYNDROMES

Picture	Note	Management
---------	------	------------

### Benign Joint Hypermobility Syndrome



**Figures 14.5.1A to C:** (A) Typical W sitting posture in joint hypermobility; (B) Hypermobile thumbs; (C) Hypermobile fingers  
*Photo Courtesy:* Vijay Viswanathan, Raju P Khubchandani, Mumbai

A five years old girl with aches and pains over lower extremities. Easy bruisability, frequent falls while walking, joint hypermobility and associated high myopia.

Hypermobility (also called “double jointedness” or hypermobility syndrome, benign joint hypermobility syndrome, or hyperlaxity) describes joints that stretch farther than is normal. Joint hypermobility syndrome shares many common features with conditions, such as Marfan syndrome, Ehlers-Danlos syndrome, and osteogenesis imperfecta. The Beighton scoring system and the Brighton scoring system assesses hypermobility and the benign joint hypermobility syndrome.



## Section 15

---

# Adolescent Health and Medicine

**Section Editor**

Swati Y Bhave

**Photo Courtesy**

Abhaya Martin, Anand Galagali, Ashish Kakkar, Harish Pemde, Jayakar Thomas, MKC Nair, Nitin A Yelikar, Paula Goel, Preeti Galagali, Quresh B Maskati, Shailaja Mane, Shaji Thomas John, Siddharth S Budhraj, Sonia Kanitkar, Swati Y Bhave, Tanmaya Amladi, Vaman Khadilkar, Vijay Zavar

- 15.1 Growing Up Issues
- 15.2 Systemic Problems
- 15.3 Miscellaneous
- 15.4 Community Programs



## SECTION OUTLINE

### 15.1 GROWING UP ISSUES 303

#### 15.1.1 Sexual Maturity Rating (SMR, Tanner's Staging) 303

- ◆ Prepubertal Genitalia—SMR 1 303
- ◆ Prepubertal Breasts and Axillary Hair 303
- ◆ Breast Development in Girls—SMR 2 and 3 303
- ◆ Breast Development in Girls—SMR 4 and 5 304
- ◆ Axillary Hair Growth in Boys 304
- ◆ Facial Hair Development in Boys 304
- ◆ Adam's Apple in Boys 305
- ◆ Pubic Hair and Testes in Boys—SMR 4 and 5 305

#### 15.1.2 Miscellaneous 305

- ◆ A Typical Metro Teenager of India 305
- ◆ Participation in Sports Important for Teens 306
- ◆ Peer Pressure 306
- ◆ AFHS 306
- ◆ Adolescent Clinic in Private Set-up-1 and 2 307
- ◆ Accessory Nipple 307
- ◆ Corporal Punishment by Teacher 307
- ◆ Self-inflicted Wounds 308

#### 15.1.3 Nutrition 308

- ◆ Malnutrition in Adolescent Boy 308
- ◆ Obesity in a Boy and Girl 308

### 15.2 SYSTEMIC PROBLEMS 309

#### 15.2.1 Miscellaneous 309

- ◆ Bell's Palsy Left 309
- ◆ Dermatitis Medicamentosa 309
- ◆ Xanthoma Tuberosum Right Knee 309
- ◆ Large Hemangioma 310
- ◆ Hypohidrotic Ectodermal Dysplasia 310
- ◆ Small Vessel Vasculitis 310
- ◆ Gangrene of Terminal Phalanges 311
- ◆ Superficial Abscess 311

#### 15.2.2 Syndromes 311

- ◆ Klippel-Trenaunay-Weber Syndrome 311
- ◆ Peutz-Jeghers Syndrome 312
- ◆ Marfan's Syndrome 312

### 15.3 MISCELLANEOUS 313

#### 15.3.1 Dental 313

- ◆ Tooth Decay 313
- ◆ Dental Malocclusion Distocclusion 313
- ◆ Dental Braces 313
- ◆ Simple Front Tooth Fracture 314
- ◆ Trauma to Front Tooth 314
- ◆ Tooth Jewelry—Upper Lateral Incisor 314
- ◆ Guthaka and Pan Stains 315
- ◆ Loss of Teeth After Accident 315
- ◆ X-ray Shows Fracture on Upper Central Incisors 315
- ◆ Fragments of Extracted Tooth 316
- ◆ Picture of the Gums Showing Dental Implant 316
- ◆ X-ray—Dental Implant 316

#### 15.3.2 Ophthalmology 317

- ◆ Hypopyon 317
- ◆ Sectoral Heterochromia 317
- ◆ Malignant Melanoma 317
- ◆ Bitot's Spots—Vitamin A Deficiency-1 318
- ◆ Bitot's Spots—Vitamin A Deficiency-2 318
- ◆ Allergic Conjunctivitis-1 319

- ◆ Keratoconus—Munson's Sign—Causing Bowing of the Lower Eyelid on Looking Down 319
- ◆ LASIK Surgery 320
- ◆ Cosmetic Contact Lenses—Diamond and Gold Embedded in Cosmetic Scleral Contact Lens 320

#### 15.3.3 Body Piercing and Tattooing 321

- ◆ Piercing of Ear 321
- ◆ Ear Perichondritis 321
- ◆ Ear Contact Dermatitis 321
- ◆ Piercing of Nose 322
- ◆ Body Tattoo 322
- ◆ Tattoo Initials 322
- ◆ Modern Teen Tattoo 323
- ◆ Removed Tattoo 323

#### 15.3.4 Adolescent Dermatology and Sexually Transmitted Disease (STD) 324

- ◆ Dandruff 324
- ◆ Mobile Phone Dermatitis—Hand 324
- ◆ Mobile Phone Dermatitis—Ear 324
- ◆ Contact Allergic Dermatitis to Footwear 325
- ◆ Hair Perming 325
- ◆ Hair Gel 325
- ◆ Sequelae of Acne—Scarring 326
- ◆ Sequelae of Acne—Pigmentation 326
- ◆ Hidradenitis Suppurativa 327
- ◆ Prurigo Nodularis 327
- ◆ Becker's Nevus 327
- ◆ Condyloma Acuminata 328
- ◆ Molluscum Contagiosum 328

#### 15.3.5 Subacrossion Orthopedic 328

- ◆ Adolescent Scoliosis 328
- ◆ Adolescent Scoliosis—Adam's Test 329
- ◆ X-ray Scoliosis Cobb's Angle 330
- ◆ Tuberculous Dactylitis 330
- ◆ X-ray—TB Dactylitis 330
- ◆ Osteochondritis Dissecans Presurgery MRI Scan-1 331
- ◆ Cervical Rib 331

### 15.4 COMMUNITY PROGRAMS 332

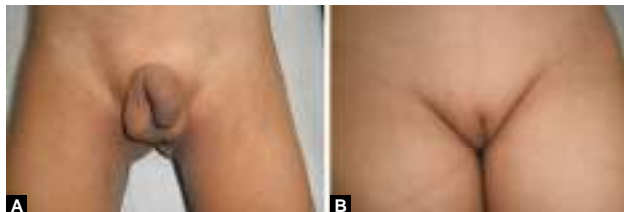- ◆ Pranayama-1 332
- ◆ Stress Management—Relaxation 332
- ◆ Health Education for Teens 332
- ◆ Parenting Workshops—Role Play 333
- ◆ Parenting Workshops—Stress Management 333
- ◆ Orientation Program for Teachers and Parents—Adolescent Development 333
- ◆ Orientation Program for Teachers and Parents—Suicide Prevention 334
- ◆ With Special Adolescents (Mentally Challenged) 334
- ◆ School Counseling 334
- ◆ Adolescent Friendly Health Services in the Rural Set-up 335
- ◆ Oath to Prevent Sexual Abuse-1 335
- ◆ Oath to Prevent Sexual Abuse-2 335
- ◆ School Health Check-up Dental Examination 336
- ◆ School Health Check-up ENT Examination 336

## 15.1 GROWING UP ISSUES

Picture	Note
---------	------

### 15.1.1 Sexual Maturity Rating (SMR, Tanner's Staging)

#### Prepubertal Genitalia—SMR 1



**Figures 15.1.1.1A and B:** (A) Prepubertal genitalia boys—SMR 1;  
(B) Prepubertal genitalia girls—SMR 1  
Photo Courtesy: Shailaja Mane, Pune

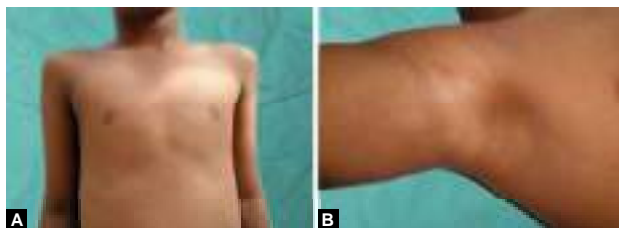
#### *Pubic hair SMR stage 1 (PH1) in boys*

- No pubic, scrotal hair growth.
- Normal pigmentation of scrotum and penis.
- Normal small size of penis.
- Testicular volume less than 3 ml.

#### *Pubic hair SMR stage 1 (PH1) in girls*

No pubic hair growth.

#### Prepubertal Breasts and Axillary Hair



**Figures 15.1.1.2A and B:** (A) Prepubertal breasts girls—SMR 1;  
(B) Prepubertal axillary hair—Boys  
Photo Courtesy: Shailaja Mane, Pune

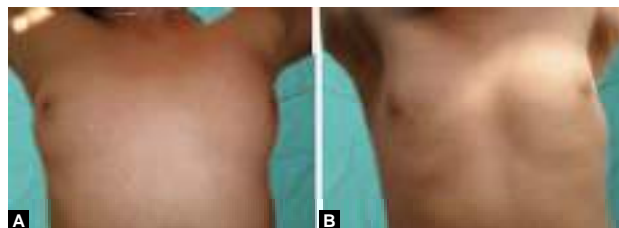
#### *Prepubertal breasts in girls SMR 1 or B1 stage*

- Small areola.
- No secondary mound or nipple prominence.

#### *Axillary hair in girls and boys—SMR stage 1*

No hair growth.

#### Breast Development in Girls—SMR 2 and 3



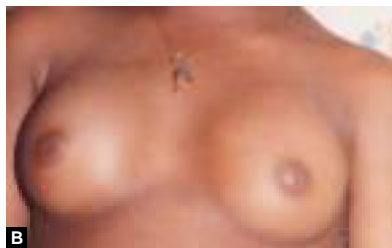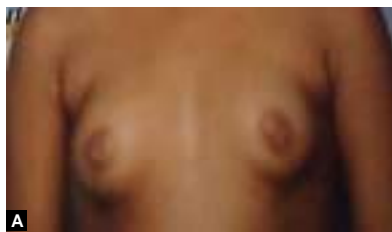**Figures 15.1.1.3A and B:** (A) Breast development in girls—SMR 2;  
(B) Breast development in girls—SMR 3  
Photo Courtesy: Shailaja Mane, Pune

*Breast development in girls SMR 2 (B2):* Breast and papilla elevated as a small mound; areolar diameter increased.

*SMR 3 (B3):* Breast and areola are enlarged, no contour separation.

Picture	Note
---------	------

### Breast Development in Girls—SMR 4 and 5

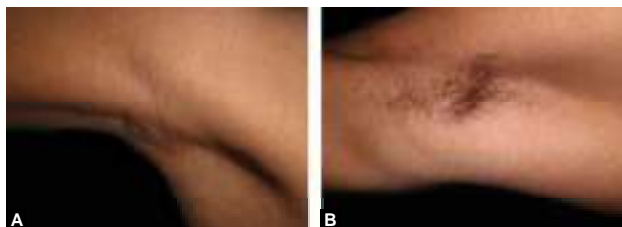


**Figures 15.1.1.4A and B:** (A) Breast development in girls—SMR 4; (B) Breast development in girls—SMR 5  
*Photo Courtesy:* Vaman Khadilkar, Pune

*Breast development in girls SMR 4 (B4):* Areola and papilla form a secondary mound.

*SMR 5 (B5):* Mature nipple projects, areola part of general breast contour.

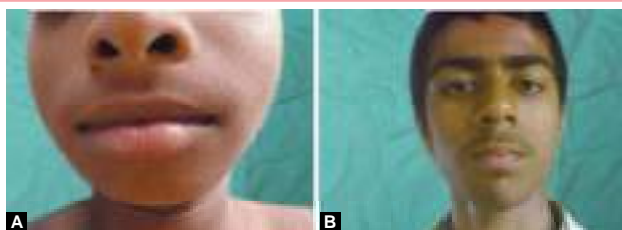
### Axillary Hair Growth in Boys



**Figures 15.1.1.5A and B:** (A) Early axillary hair growth in boys; (B) Advanced axillary hair growth in boys  
*Photo Courtesy:* Shailaja Mane, Pune

- Axillary hair development is staged as Ax 0, 1 and 2.
- Axillary hair starts appearing by SMR stage 4.
- Axillary perspiration would start by SMR stage 3 in boys and girls.

### Facial Hair Development in Boys

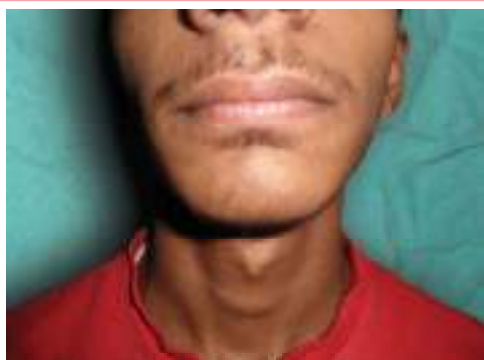

**Figures 15.1.1.6A and B:** (A) Hair development in boys—Prepubertal facial hair; (B) Early pubertal facial hair in boys  
*Photo Courtesy:* Shailaja Mane, Pune

- Hair growth over face in a boy indicates adrenarche.
- Facial hair appears around SMR stage 4 in boys.
- Growth of hair over upper lip, and chin.

Picture	Note
---------	------

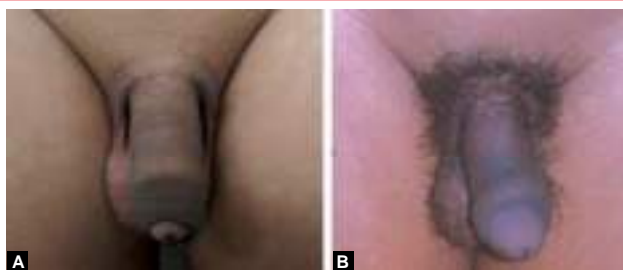### Adam's Apple in Boys



**Figures 15.1.1.7:** Adam's apple in boys  
Photo Courtesy: Shailaja Mane, Pune

- Growth of hair over upper lip, chin and cheek.
- Prominence of Adam's apple in boys.
- Voice change starts appearing much after SMR stage 4 and around SMR stage 5.

### Pubic Hair and Testes in Boys—SMR 4 and 5



**Figures 15.1.1.8A and B:** (A) Pubic hair and testes in boys—SMR 4; (B) Pubic hair and testes in boys—SMR 5  
Photo Courtesy: Vaman Khadilkar, Pune

#### SMR stage 4 (G4)

- *Testes:* Volume 12 to 20 ml.
- *Scrotum:* Further enlargement and darkening.
- *Phallus:* Increased length and circumference.

#### SMR stage 5 (G5)

- *Testes:* Volume more than 20 ml.
- *Scrotum and phallus:* Adult.
- Pubic and scrotal hair.

## 15.1.2 Miscellaneous

### A Typical Metro Teenager of India



**Figure 15.1.2.1:** A typical metro teenager of India  
Photo Courtesy: Paula Goel, Mumbai

A well-balanced teenager who is empowered with life skills is confident has good self esteem and can deal with the transition period with confidence. Parental communication and rapport is a very important protective factor that helps teens to keep away from the temptation of high-risk taking behavior.

- Parental counseling required: adolescents will spend less time with families and more with peers.
- Set firm limits.
- Be empathetic.
- Help to develop self-esteem.
- Encourage to develop talents and interests.
- Solicit their opinions and listen to them patiently.
- Constructive criticism when necessary.

Picture	Note	Management
---------	------	------------

### Participation in Sports Important for Teens



**Figure 15.1.2.2:** Participation in sports important for teens  
Photo Courtesy: Paula Goel, Mumbai

Participation in sports is very important for all round personality development. It improves their confidence, grit and sense of achievement gives leadership skills, camaraderie and team work. Keeps high motivation, keeps them involved and away from high-risk behavior.

- Need to monitor for sport doping.
- Coach and peer sexual and emotional abuse.
- Ragging.
- Sports injuries can lead to life long disability.
- Inability to cope up with failures can lead to mental issues.

### Peer Pressure



**Figure 15.1.2.3:** Peer pressure  
Photo Courtesy: Paula Goel, Mumbai

#### *Protection from negative peer pressure*

- Peers are very important for adolescent development.
- Parents should accept the important role of peers in their teens life.
- Forcing them away from peers will result in rebellion and high-risk behavior .
- Parents should have a strong bond with their children that protects them from negative peer pressure.

A good communication between teens and their parents, a sense of belonging to a community and social circle, strong moral values are some of the factors that will protect teens from falling prey to negative peer pressure.

### AFHS




**Figures 15.1.2.4A and B:** (A) AFHS at a Govt Hospital-1; (B) AFHS at a Govt Hospital-2  
Photo Courtesy: Harish Pemde, New Delhi

Informational/educational materials focused at adolescent health are also available. These materials are also used to conduct lectures at various institutions. To maintain privacy, a screen is kept where the doctor examines the patient. This area is also useful for conducting psychotherapy like relaxation, etc.


Establishments of AFHS in public setup are very important for the teenagers who come from the deprived section of society and cannot afford to pay for the Teen clinics in private setups.

Picture	Note	Management
---------	------	------------


### Adolescent Clinic in Private Set-up-1 and 2


 <p><b>Figures 15.1.2.5A and B:</b> (A) Adolescent clinic in private set-up-1; (B) Adolescent clinic in private set-up-2 <i>Photo Courtesy:</i> Sonia Kanitkar, Bengaluru</p>	<ul style="list-style-type: none"> <li>• Private consultation room.</li> <li>• Young, smiling adolescent-friendly receptionist.</li> <li>• Comfortable adult—like waiting area.</li> <li>• Separate examination area.</li> <li>• Should have female/male attendant while examining girls/boys.</li> <li>• Adolescent friendly ambience.</li> <li>• Display board—health messages.</li> <li>• Educative pamphlets given.</li> </ul>	<p>Since the parents of teens in private setup can pay the fees, these AFHS can be a state of art, delivering the best services for teens.</p>
--	--	--

### Accessory Nipple

 <p><b>Figure 15.1.2.6:</b> Accessory nipple <i>Photo Courtesy:</i> Shaji Thomas John, Calicut</p>	<ul style="list-style-type: none"> <li>• Otherwise known as ‘polythelia’</li> <li>• Often mistaken for moles.</li> <li>• Appears along the ‘milk-lines’</li> <li>• Usually only on one side.</li> </ul>	<ul style="list-style-type: none"> <li>• Reassurance.</li> <li>• Very important for Adolescent’s body image</li> <li>• Cosmetic surgery if associated with fat tissue (pseudomamma)</li> </ul>
--	---	--


### Corporal Punishment by Teacher

 <p><b>Figure 15.1.2.7:</b> Corporal punishment by teacher <i>Photo Courtesy:</i> Shaji Thomas John, Calicut</p>	<ul style="list-style-type: none"> <li>• ‘Spare the rod and spoil the child’ used to be the dictum in schools in olden days.</li> <li>• But now with the ban on corporal punishments by the government of India (GOI), it is ‘spare the rod or end up in jail’.</li> <li>• But teachers still do resort to such measures in many of the schools and most of the children silently endure because they were initially at fault.</li> </ul>	<ul style="list-style-type: none"> <li>• The teachers should be made aware of the consequences of the law.</li> <li>• Children should be encouraged to do things based on positive reinforcements and ‘rewards’.</li> </ul>
---	---	---


Picture	Note	Management
<p><b>Self-inflicted Wounds</b></p>  <p><b>Figure 15.1.2.8:</b> Self-inflicted wounds Photo Courtesy: Shaji Thomas John, Calicut</p>	<ul style="list-style-type: none"> <li>• The wounds are of bizarre shapes and sizes.</li> <li>• Typically they are on the left hand in a right handed person and on the ventral side of the forearm.</li> <li>• Usually by adolescent to take advantage, by provoking the parents or teachers.</li> </ul>	<ul style="list-style-type: none"> <li>• Treat the wound with antibiotics if indicated or local antibiotic cream/lotion.</li> <li>• Manage the underlying cause counseling.</li> </ul>

### 15.1.3 Nutrition




#### Malnutrition in Adolescent Boy

 <p><b>Figure 15.1.3.1:</b> Malnutrition in adolescent boy Photo Courtesy: Shailaja Mane, Pune</p>	<ul style="list-style-type: none"> <li>• During adolescence there is high incidence of nutritional deficiencies due to poor eating habits.</li> <li>• Most malnutrition is due to poverty and reduced intake.</li> <li>• Severe metabolic diseases and chronic illnesses also can lead to severe malnutrition.</li> </ul>	<p>Anorexia nervosa is characterized by self starvation through extreme dieting, intense weight loss.</p>
--	---	---




#### Obesity in a Boy and Girl

 <p><b>Figures 15.1.3.2A and B:</b> (A) Obesity in a boy; (B) Obesity in a girl Photo Courtesy: Shailaja Mane, Pune</p>	<ul style="list-style-type: none"> <li>• Obesity in children and adolescents has reached alarming levels.</li> <li>• The prevalence of the metabolic syndrome increased with the severity of obesity.</li> <li>• Obesity, which is the most common cause of insulin resistance in children, is also associated with metabolic syndrome—dyslipidemia, type 2 diabetes, and long-term vascular complications.</li> </ul>	
--	--	--

## 15.2 SYSTEMIC PROBLEMS

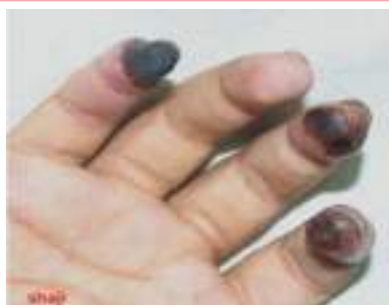Picture	Note	Management
<b>15.2.1 Miscellaneous</b>		
<b>Bell's Palsy Left</b>		
 <p data-bbox="106 691 484 737"><b>Figure 15.2.1.1:</b> Bell's palsy left Photo Courtesy: Shaji Thomas John, Calicut</p>	<ul data-bbox="543 399 928 520" style="list-style-type: none"> <li>• Acute unilateral facial nerve palsy.</li> <li>• Not associated with other cranial neuropathies or brain stem dysfunction.</li> </ul> <p data-bbox="543 532 717 560"><i>Clinical features</i></p> <ul data-bbox="543 572 893 701" style="list-style-type: none"> <li>• LMN type of palsy.</li> <li>• Drooping of corner of mouth.</li> <li>• Loss of taste on anterior 2/3 of tongue on involved side.</li> </ul>	<ul data-bbox="965 399 1330 596" style="list-style-type: none"> <li>• Oral prednisolone.</li> <li>• Oral acyclovir/valacyclovir if indicated.</li> <li>• Physiotherapy.</li> <li>• Ocular lubricants for protecting cornea.</li> </ul>
<b>Dermatitis Medicamentosa</b>		
 <p data-bbox="106 1137 484 1183"><b>Figure 15.2.1.2:</b> Dermatitis medicamentosa Photo Courtesy: Shaji Thomas John, Calicut</p>	<ul data-bbox="543 854 923 1135" style="list-style-type: none"> <li>• Extensive oozing with inflammation and crusting noted on both palms and fingers.</li> <li>• Patient had mild contact dermatitis and indigenous medicines were applied.</li> <li>• Resulted in flaring up of dermatitis leading on to systemic symptoms also.</li> </ul>	<ul data-bbox="965 854 1345 1120" style="list-style-type: none"> <li>• Antibiotics for the secondary infection.</li> <li>• Saline compress and local steroids.</li> <li>• Management of itching and pain.</li> <li>• Oral steroids if needed.</li> <li>• Avoid the offending agent to prevent CD.</li> </ul>
<b>Xanthoma Tuberosum Right Knee</b>		
 <p data-bbox="106 1764 484 1836"><b>Figure 15.2.1.3:</b> Xanthoma tuberosum right knee Photo Courtesy: Shaji Thomas John, Calicut</p>	<ul data-bbox="543 1290 928 1655" style="list-style-type: none"> <li>• Cutaneous manifestation of lipidosis.</li> <li>• Xanthoma tuberosum occurs around the joints.</li> <li>• Accumulation of lipids in large foam cells within the skin.</li> <li>• Elevated LDL cholesterol.</li> <li>• Risk of premature cardiovascular and cerebrovascular diseases.</li> <li>• May be associated with dementia, ataxia, cataract.</li> </ul>	<ul data-bbox="965 1290 1345 1554" style="list-style-type: none"> <li>• Lifestyle modification—Dietary changes and exercise.</li> <li>• Statins in high doses, bile acid sequestrants, niacin and ezetimibe tried.</li> <li>• LDL apheresis.</li> <li>• Liver transplantation.</li> <li>• Porto-caval anastomosis.</li> </ul>



Picture	Note	Management
<p><b>Large Hemangioma</b></p>  <p><b>Figure 15.2.1.4:</b> Large hemangioma Photo Courtesy: Shaji Thomas John, Calicut</p>	<ul style="list-style-type: none"> <li>• Hemangiomas usually seen in infancy and they normally resolve by the time they become adolescents.</li> <li>• But large ones like that seen in the picture can persist and can give rise to psychosocial issues.</li> <li>• Common complications include ulcerations and bleeding. Pressure effects can be seen depending on the site. Large ones can also rarely result in high output cardiac failures and thrombocytopenia.</li> </ul>	<ul style="list-style-type: none"> <li>• Usually left alone.</li> <li>• Large ones like these require surgical treatment both for cosmetic improvement as well as to prevent complications.</li> <li>• Steroids and laser therapy are tried for smaller lesions.</li> </ul>
<p><b>Hypohydrotic Ectodermal Dysplasia</b></p>  <p><b>Figures 15.2.1.5A and B:</b> Hypohydrotic ectodermal dysplasia Photo Courtesy: Shaji Thomas John, Calicut</p>	<ul style="list-style-type: none"> <li>• The most common cause of ectodermal dysplasia.</li> <li>• Heterogenous group of inherited disorders.</li> <li>• Have a reduced ability to sweat (hypohydrosis).</li> <li>• Sparse slow growing scalp and body hair (hypotrichosis).</li> <li>• Absent teeth (hypodontia) or malformed small pointed teeth.</li> <li>• Distinctive facial features of prominent forehead, thick lips and flattened bridge.</li> <li>• Absent hair, absent eyebrows and eyelashes.</li> <li>• Lack of sweating.</li> <li>• Dry scaly hypopigmented skin.</li> <li>• Thin wrinkled dark colored skin.</li> <li>• Xerophthalmia/conjunctivitis.</li> </ul>	<ul style="list-style-type: none"> <li>• Temperature control, prevent hyperthermia.</li> <li>• Care of the eyes and skin.</li> <li>• Oral hygiene.</li> <li>• Management of pharyngitis, otitis and rhinitis which is very common.</li> <li>• Optimize growth and development with nutritional support.</li> </ul>
<p><b>Small Vessel Vasculitis</b></p>  <p><b>Figure 15.2.1.6:</b> Small vessel vasculitis Photo Courtesy: Shaji Thomas John, Calicut</p>	<p><i>Causes:</i> Immune complex mediated (HSP, etc.), ANCA disorders (Wegener's granulomatosis, etc.), Miscellaneous (Connective tissue disorders, etc.)</p> <p><i>Clinical features:</i> Purpura, petechiae, GI bleed, arthritis, hematuria, uveitis.</p> <p>Pain, tenderness and discoloration seen in the index case.</p>	<ul style="list-style-type: none"> <li>• Investigate for any specific cause.</li> <li>• Oral/IV steroids.</li> <li>• Immunosuppressants: Cyclophosphamide, methotrexate.</li> </ul>

Picture	Note	Management
---------	------	------------

### Gangrene of Terminal Phalanges

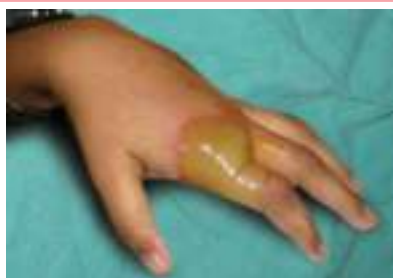

**Figure 15.2.1.7:** Gangrene of terminal phalanges  
Photo Courtesy: Shaji Thomas John, Calicut

- Gangrene due to small vessel vasculitis.
- Started as pain and discoloration of the tips of fingers and toes.
- Progressed on to gangrene of most of the phalanges.
- Other manifestations of small vessel vasculitis seen later.

- Steroids.
- Heparin to improve the circulation.
- Amputation as a last resort.
- Follow-up.

### Superficial Abscess



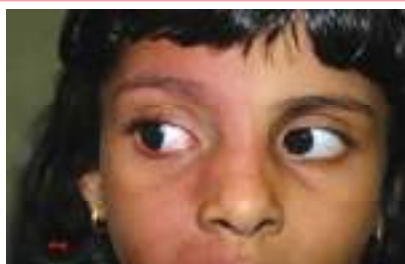**Figure 15.2.1.8:** Superficial abscess  
Photo Courtesy: Shaji Thomas John, Calicut

- Skin is the most common site of an abscess; may be superficial or deep. It could extend as in this case, but get limited by the abscess wall or a capsule.
- Or it could lead on to inflammation of the subcutaneous layers also, resulting in cellulitis.

- Incision and drainage.
- Pus for c/s
- Parenteral antibiotics: *Staphylococcus aureus* is the most common organism; hence cloxacillin is the classical drug of choice.
- Alternatives used with the emergence of MRSA.

### 15.2.2 Syndromes


#### Klippel-Trenaunay-Weber Syndrome





**Figure 15.2.2.1:** Klippel-Trenaunay-Weber syndrome  
Photo Courtesy: Shaji Thomas John, Calicut

- Triad of portwine stain, varicose veins and bony and soft tissue hypertrophy.
- Presents at birth or during early infancy or childhood.
- Usually affects single extremity.
- May involve visceral organs.
- Major cause of concern in affected adolescents.




- Mainly conservative.
- Symptomatic when needed.
- Pain management.
- Antibiotics and analgesics for cellulitis and thrombophlebitis.
- Anticoagulation if there is thrombosis.
- Management of limb hypertrophy and cosmetic correction if possible.

Picture	Note	Management
<p><b>Peutz-Jeghers Syndrome</b></p>  <p><b>Figure 15.2.2.2:</b> Peutz-Jeghers syndrome Photo Courtesy: Shaji Thomas John, Calicut</p>	<ul style="list-style-type: none"> <li>• Autosomal dominant. Intestinal hamartomatous polyps.</li> <li>• Mucocutaneous pigmentation and melanin spots mostly circumoral/peribuccal.</li> <li>• Gynecomastia and growth acceleration if there is testicular mass.</li> <li>• High-risk of malignancy.</li> </ul>	<ul style="list-style-type: none"> <li>• Removal of large and symptomatic polyps.</li> <li>• Treatment of complications like bleeding.</li> <li>• Lifelong cancer surveillance.</li> </ul>

### Marfan's Syndrome

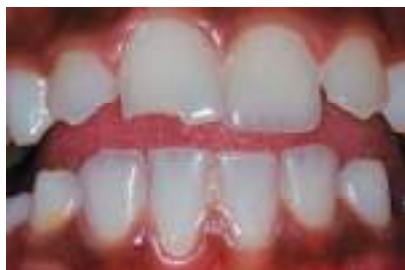 <p><b>A</b></p>  <p><b>B</b></p> <p><b>Figures 15.2.2.3A and B:</b> Marfan's syndrome Photo Courtesy: Nitin A Yelikar, Pune</p>	<p>Adolescents—tall stature and a long, thin face with narrowness of the maxilla and dental crowding.</p> <p>Ocular abnormalities reflect the connective tissue defect and include blue sclerae, myopia occurring in 60% of affected individuals, and suspensory ligament laxity with iridodonesis.</p> <p>Slit-lamp examination—may disclose lens dislocation.</p>	<p>The management is specific to the problem they will present with.</p>
---	---	--

## 15.3 MISCELLANEOUS

Picture	Note	Management
<h3>15.3.1 Dental</h3>		
<h4>Tooth Decay</h4>		
 <p data-bbox="106 681 428 731"><b>Figure 15.3.1.1:</b> Toody decay Photo Courtesy: Shailaja Mane, Pune</p>	<p><i>Dental caries</i>—One of the common problem in adolescence. Improper cleaning, Malaligned teeth, habits of eating chocolates and sweets increase the risk.</p> <p><i>Clinical features</i>—Tooth ache, root abscess, cellulitis.</p> <p><i>Complications</i>—Risk of bacterial endocarditis in heart disease patients.</p> <p>Can disturb self image and confidence.</p>	<ul style="list-style-type: none"> <li>• <i>Prevention</i>—Proper cleaning, correction of wrong habits, routine dental checkup.</li> <li>• Filling of caries teeth with silver or ceramic.</li> <li>• Root cannal treatment for deep caries.</li> <li>• Extraction of caries tooth and implantation of ceramic tooth.</li> <li>• Fluoride painting of teeth regularly helps to prevent caries.</li> </ul>
<h4>Dental Malocclusion Distocclusion</h4>		
 <p data-bbox="106 1072 484 1145"><b>Figure 15.3.1.2:</b> Dental malocclusion distocclusion Photo Courtesy: Shaji Thomas John, Calicut</p>	<ul style="list-style-type: none"> <li>• Improper alignment of teeth can be due to hereditary causes, habits like thumb sucking, decay and disease of gums, early loss of milk teeth, retained milk teeth, etc.</li> <li>• Can result in crossbite, overbite and crowding.</li> <li>• In the picture there is overbite with minimal retrognathism resulting in distocclusion.</li> </ul>	<p>Treatment should be individualized.</p> <p>Most important is prevention where applicable.</p> <p>Correction with appliances can be started by 12 to 13 years.</p> <p>Surgical correction only after 18 years in females and 20 years in males.</p>
<h4>Dental Braces</h4>		
 <p data-bbox="106 1507 428 1558"><b>Figure 15.3.1.3:</b> Dental braces Photo Courtesy: Shailaja Mane, Pune</p>	<ul style="list-style-type: none"> <li>• To treat malalignment braces or other appliances may be used. Metal bands are placed around some teeth, or metal, ceramic, or plastic bonds are attached to the surface of the teeth. Wires or springs apply force to the teeth.</li> <li>• Wires, plates, or screws may be used to stabilize the jaw bone, in a similar manner to the surgical stabilization of jaw fracture.</li> </ul>	<p><i>Brushing and flossing every day</i> regular visits to a general dentist. Plaque accumulates on braces - permanently mark teeth or cause tooth decay if not properly cared for</p> <p><i>Complications</i></p> <ul style="list-style-type: none"> <li>• Tooth decay.</li> <li>• Discomfort during treatment.</li> <li>• Irritation of mouth and gums (gingivitis) caused by appliances.</li> <li>• Chewing or speaking difficulty during treatment.</li> <li>• Treatment is most successful in children and adolescents because their bone is still soft and teeth are moved easily.</li> <li>• Treatment may last 6 months to 2 or more years, depending on the severity of the case.</li> </ul>

Picture	Note	Management
---------	------	------------

### Simple Front Tooth Fracture

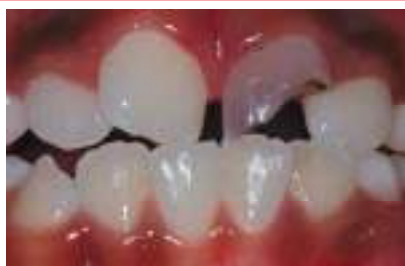

**Figure 15.3.1.4:** Simple front tooth fracture  
Photo Courtesy: Ashish Kakkar, New Delhi

Such teeth do not require a root canal therapy.

Management is conservative.  
*Includes:* Pulp capping and esthetic bonding with composite resins to restore form and function.

### Trauma to Front Tooth

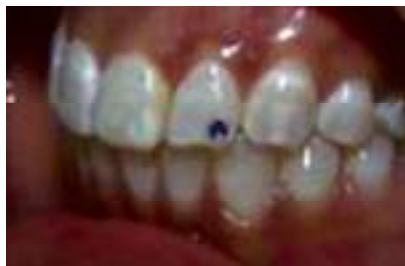

**Figure 15.3.1.5:** Trauma to front tooth  
Photo Courtesy: Ashish Kakkar, New Delhi

Since no treatment was initiated, the front left incisor tooth has become nonvital and looks dark. This has various implications such as formation of periapical lesions like granulomas and cysts.

Early treatment should be initiated which involves root canal treatment of the involved tooth.

### Tooth Jewelry—Upper Lateral Incisor



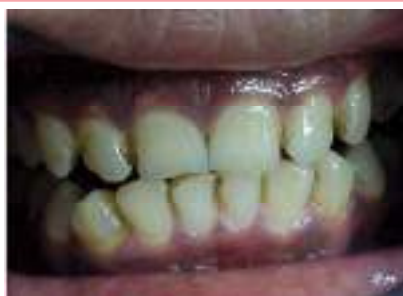**Figure 15.3.1.6:** Tooth jewelry—Upper lateral incisor  
Photo Courtesy: Ashish Kakkar, New Delhi

Tooth jewelry was used since ancient times but now it has revived as a latest fashion craze. Tooth jewel made of gems or diamond is cemented on the tooth surface through a simple procedure. The design can be changed several times as desired, or can be brought back to original smile.

Potentially there is no harm to the tooth surface but extra care is needed to make sure that the area is kept clean of all food debris after meals to prevent caries around the bonded enamel surface.

Picture	Note	Management
---------	------	------------

### Guthaka and Pan Stains



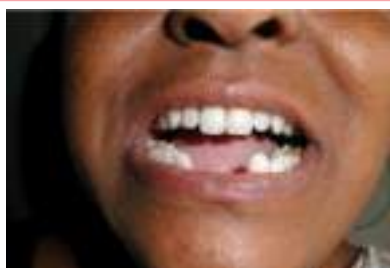**Figure 15.3.1.7:** Guthaka and Pan stains  
Photo Courtesy: Ashish Kakkar, New Delhi

Very commonly seen in adolescents. A growing habit in India especially among youngsters!

- ill effects include stains on teeth.
- loss of tooth enamel due to wear.
- development of gingivitis and periodontitis.
- submucous fibrosis.
- hyperkeratosis of the oral mucosa.
- oral squamous cell carcinoma.

- The use of tobacco has to be stopped. Cleaning of the teeth has to be done.
- Treatment has to be given for the gingivitis and periodontitis.
- Referred to a oral cancer surgeons for specific management as needed.

### Loss of Teeth After Accident

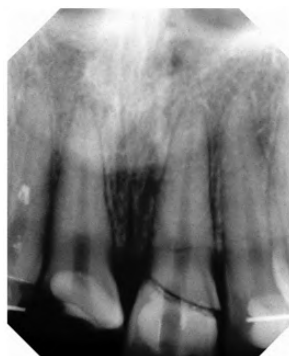

**Figure 15.3.1.8:** Loss of teeth after accident  
Photo Courtesy: Shailaja Mane, Pune

Adolescents are involved in high-risk behavior. This often leads to accidents and injuries. Participation in sports also can cause trauma to teeth.

- Loss of teeth specially the front teeth can cause lot of embarrassment to a adolescent. If not replaced in time this can affect their self esteem.
- They can be replaced by dental bridges.
- If the parents can afford it the best treatment is dental implants.


### X-ray Shows Fracture on Upper Central Incisors




**Figure 15.3.1.9:** X-ray shows fracture on upper central incisors  
Photo Courtesy: Ashish Kakkar, New Delhi

Fracture of the incisor is below the crest of bone rendering the teeth nonsalvageable.

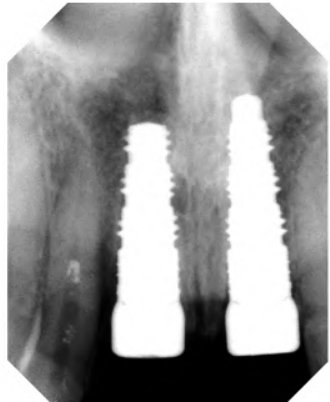
Extraction and replacement is the only option.

Picture	Note	Management
<b>Fragments of Extracted Tooth</b>		
 <p data-bbox="106 570 515 616"><b>Figure 15.3.1.10:</b> Fragments of extracted tooth <i>Photo Courtesy:</i> Ashish Kakkar, New Delhi</p>	<p data-bbox="543 308 918 399">Fracture of the incisor is below the crest of bone rendering the teeth nonsalvageable.</p>	<p data-bbox="965 308 1330 368">Extraction and replacement is the only option.</p>

### Picture of the Gums Showing Dental Implant

 <p data-bbox="106 1104 474 1177"><b>Figure 15.3.1.11:</b> Gums showing dental implant <i>Photo Courtesy:</i> Ashish Kakkar, New Delhi</p>	<p data-bbox="543 802 879 862">Extraction of the fractured root fragments.</p>	<ul data-bbox="965 802 1316 923" style="list-style-type: none"> <li>• After extraction there is placement of the dental implants.</li> <li>• Later the crown is fitted on the implants.</li> </ul>
--	--	--

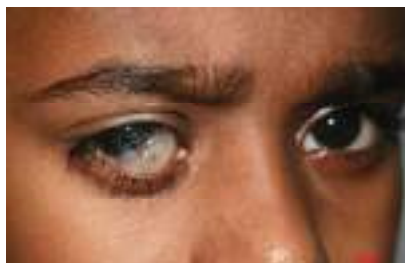### X-ray—Dental Implant

 <p data-bbox="106 1774 474 1818"><b>Figure 15.3.1.12:</b> X-ray—Dental implant <i>Photo Courtesy:</i> Ashish Kakkar, New Delhi</p>	<p data-bbox="543 1356 918 1477">This is an X-ray of the implants done. This is necessary to check the position of the implants before fitting the crown.</p>	<p data-bbox="965 1356 1316 1417">Once the implants are well fitted, they are covered with a crown.</p>
--	---	---

Picture	Note	Management
---------	------	------------

### 15.3.2 Ophthalmology

#### Hypopyon

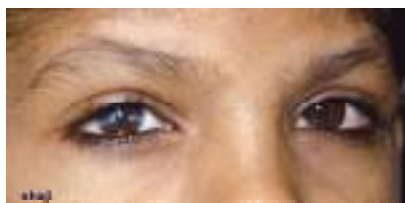

**Figure 15.3.2.1:** Hypopyon  
Photo Courtesy: Shaji Thomas John, Calicut

Pus or leukocyte exudate in anterior chamber of eye.  
Causes include corneal ulcer esp. fungal, Behcet's disease, endophthalmitis, panuveitis, panophthalmitis.  
Seen as yellowish exudate in lower part of anterior chamber of eye, with conjunctival congestion and anterior uveitis.

Treat the underlying cause  
parenteral antibiotics.

#### Sectoral Heterochromia



**Figure 15.3.2.2:** Sectoral heterochromia  
Photo Courtesy: Shaji Thomas John, Calicut

Heterochromia refers to a difference in color.

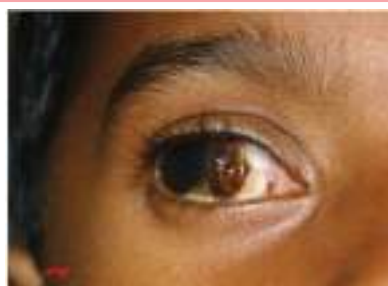Left eye is normal in color.

Right eye has hypopigmented streaks at the 4 o'clock and 8 o'clock positions.

When part of the iris is colored differently it is known as partial or sectoral heterochromia.

- Nothing need be done.
- Reassurance needed.
- Adolescents may take it as mark of beauty.
- But if unduly concerned contact lenses may be used with any color of their choice.

#### Malignant Melanoma




**Figure 15.3.2.3:** Malignant melanoma  
Photo Courtesy: Shaji Thomas John, Calicut


Very aggressive tumor of eye can affect several parts of eye—most common choroid layer.  
Could be asymptomatic can present with bulging eyes, change in color of iris, poor vision, red painful eye, defect on iris or conjunctiva.


- Small melanomas—laser, brachytherapy, radiotherapy.
- Enucleation.
- Chemotherapy.




Picture	Note	Management
<p><b>Bitot's Spots—Vitamin A Deficiency-1</b></p>  <p><b>Figure 15.3.2.4:</b> Bitot's spots—Vitamin A deficiency-1 Photo Courtesy: Shailaja Mane, Pune</p>	<p><i>Night blindness</i>—Earliest symptom.</p> <p><i>Eye changes</i>—Xerophthalmia, Bitot's spots, corneal xerosis, ulceration, xerophthalmic fundi.</p> <p><i>Skin changes</i>—Dry, scaly, hyperkeratotic patches, commonly on the arms, legs, shoulders, and buttocks.</p>	<p>Prophylaxis with mega vitamin A doses for children under five in our public health programs has reduced the incidence of severe vitamin A deficiency and associated blindness.</p>


### Bitot's Spots—Vitamin A Deficiency-2

 <p><b>Figure 15.3.2.5:</b> Bitot's spots—Vitamin A deficiency-2 Photo Courtesy: Siddharth S Budhraj, Pune</p>	<p>In urinary bladder, loss of epithelial integrity—pyuria and hematuria.</p> <p><i>Epithelial changes</i>—In respiratory system-bronchial obstruction.</p>	<p>Health education creating awareness of the need of vitamin A in our daily diet and use of supplement wherever needed will prevent this condition.</p>
--	---	--


Picture	Note	Management
<p><b>Allergic Conjunctivitis-1</b></p>  <p><b>Figures 15.3.2.6A and B:</b> (A) Allergic conjunctivitis—Confluent papillae at limbus (B) Palpebral allergic conjunctivitis—Giant or cobblestone papillae <i>Photo Courtesy:</i> Quresh B Maskati, Mumbai</p>	<p>In India, allergic conjunctivitis is present almost throughout the year, unlike its predilection for spring in temperate countries. Primary symptom is itching in eyes. Watering, discharge and redness are accompanying symptoms. The presence of papillae, either on inner surface of eyelids or around the limbus clinches the diagnosis. It is a type IV hypersensitivity response to external antigens like house dust, mites, pollen, etc.</p>	<ul style="list-style-type: none"> <li>• Local hygiene and prevention of rubbing of eyes.</li> <li>• Local antihistaminic drops for symptomatic relief.</li> <li>• Mast cell stabilizer drops for long-term desensitization.</li> <li>• Local steroids are used in refractory cases. They are given in pulsed doses with caution as they may cause dependence, dryness, cataracts and glaucoma.</li> </ul>

### Keratoconus—Munson’s Sign—Causing Bowing of the Lower Eyelid on Looking Down

 <p><b>Figure 15.3.2.7:</b> Keratokonus—Munson’s sign—causing bowing of the lower eyelid on looking down <i>Photo Courtesy:</i> Quresh B Maskati, Mumbai</p>	<p>Keratoconus is a degenerative condition of the cornea, typically manifesting in late teens. Only 20% of the cases are progressive. It is suspected when the patient is unhappy with quality of vision with spectacles or has marked changes in spectacle prescription every few months or suddenly develops contact lens intolerance. In rare cases there can be splitting of the stromal layers due to too much stretch, causing ‘hydrops’ with formation of an opacity at the apex of the cone.</p>	<p>Early keratoconus are managed with spectacles; later they may require special contact lenses such as ‘semisoft’ or ‘piggyback lenses’. Those intolerant to these may be fitted with custom made lenses such as the ‘Rose K design’ or large contact lenses sitting away from the cornea known as ‘scleral lenses’. Progress can be halted by a procedure called ‘collagen cross linking’ in which the bonds between the collagen bundles in the stroma is strengthened with riboflavin drops exposed to UV light. In advanced cases, the cone may be flattened by inserting plastic pieces in the periphery of the cornea. Corneal grafting surgery is the last option.</p>
---	--	--

Picture	Note	Management
<p><b>LASIK Surgery</b></p>  <p><b>Figure 15.3.2.8:</b> LASIK surgery Photo Courtesy: Quresh B Maskati, Mumbai</p>	<p>Spectacle number removal. Painless procedure done under topical (eye drop) anesthesia to remove spectacle numbers in myopia, hypermetropia and astigmatism. Patient should be above 18 years and have stable refraction since past one year. Prior topography and pachymetry is a must to rule out keratoconus and abnormally thin corneas which are contraindications. Wearing of contact lenses is discontinued at least a week prior.</p>	<ul style="list-style-type: none"> <li>• A partial thickness flap is lifted with a keratome.</li> <li>• Excimer laser is applied in a pattern controlled by a computer in which the patient's data has been fed.</li> <li>• The flap is repositioned back and the other eye is similarly done.</li> <li>• Postoperative the patient is put on a short course of antibiotic +steroid +lubricant eye drops for a couple of weeks.</li> <li>• Patient can resume all activities within 24 to 48 hours.</li> </ul>


### Cosmetic Contact Lenses—Diamond and Gold Embedded in Cosmetic Scleral Contact Lens

 <p><b>Figure 15.3.2.9:</b> Cosmetic contact lenses—Diamond and gold embedded in cosmetic scleral contact lens Photo Courtesy: Quresh B Maskati, Mumbai</p>	<ul style="list-style-type: none"> <li>• For the fashionable adolescent, a wide variety of cosmetic contact lenses (CL) are available.</li> <li>• The usual cosmetic CL are soft lenses available over the counter and come in various colors and designs such as various country flags, etc.</li> <li>• The latest cosmetic CL are large scleral lenses with either diamonds or gold embedded in the substance. These are custom made and can incorporate the wearers refractive error as well.</li> </ul>	<ul style="list-style-type: none"> <li>• Like with any CL, proper hygiene and optimum wearing time rules need to be observed. It can carry risk otherwise.</li> <li>• Since these are purchased in most cases off the shelf, these instructions are often not given to the patient by the shop owner, resulting in needless complications.</li> <li>• Any drop in vision, redness or watering after wearing these lenses should warrant an emergency visit to an ophthalmologist.</li> </ul>
---	---	--


Picture	Note	Management
---------	------	------------

### 15.3.3 Body Piercing and Tattooing


#### Piercing of Ear

 <p><b>Figures 15.3.3.1A and B:</b> Piercing of ear Photo Courtesy: Shailaja Mane, Pune</p>	<p>Body piercing, a form of body modification practice of puncturing or cutting a part of the human body, creating an opening in which jewelry may be worn.</p> <p>Ears are pierced—commonly at one or even at multiple sites. Different types of ornaments are used to wear at different sites.</p>	<p>Needed only if there are complications of the piercing.</p>
--	--	--

#### Ear Perichondritis

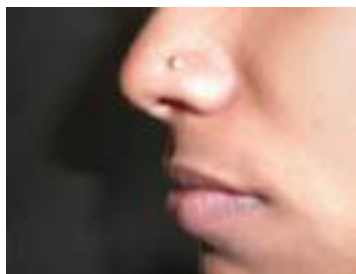 <p><b>Figure 15.3.3.2:</b> Ear perichondritis Photo Courtesy: Vijay Zawar, Nashik</p>	<p>Secondary infections after unhygienic ear piercing is a common finding, especially when done by nonmedical persons. Cellulitis of pinna and suppuration if not treated in time, may lead to suppurative perichondritis, which often presents as pain and swelling in the area of helix of pinna.</p>	<ul style="list-style-type: none"> <li>• In early course, systemic medical treatment consisting of analgesics and antibiotics are helpful.</li> <li>• Surgical treatment may be required.</li> <li>• Health education, early diagnosis and treatment are generally helpful.</li> </ul>
--	---	--

#### Ear Contact Dermatitis

 <p><b>Figure 15.3.3.3:</b> Ear contact dermatitis Photo Courtesy: Vijay Zawar, Nashik</p>	<p>Ear contact dermatitis due to cheap imitation jewelry. Patients with known sensitivity to nickel or related metals in ear rings are often at the risk of contact dermatitis, especially during summer months and in the patients who sweat a lot. Nickel ions leach during sweating and can cause discomfort due to contact dermatitis.</p>	<ul style="list-style-type: none"> <li>• Avoid nickel in pseudo-jewelry.</li> <li>• Use metals with less known sensitivity such as gold or silver or even stainless steel ear studs.</li> <li>• Treatment is with topical steroids and antihistamines.</li> </ul>
---	--	---

Picture	Note	Management
---------	------	------------

### Piercing of Nose



**Figure 15.3.3.4:** Piercing of nose  
Photo Courtesy: Shailaja Mane, Pune

Nose piercing remains customary for Indian Hindu women of childbearing age to wear a nose stud, usually in the left nostril.

Other sites—Lips, nipple, navel and genital piercing, cheeks, etc.

Tools used for piercing—needles, gun, canula, punch, forceps, etc.

*Complications:* Allergic reactions, infections, keloid formation.

### Body Tattoo



**Figure 15.3.3.5:** Body tattoo  
Photo Courtesy: Shailaja Mane, Pune

A tattoo is a permanent marking made by inserting ink into the skin primarily used for cosmetic, sentimental or religious reasons.

Preferred as a form of identification, especially in incarcerative set-ups, as the tattoo pigment is buried deep within the skin and is usually not destroyed even by severe burns.

Management will depend upon the specific treatment for the complications below:

- Unhygienic tattooing can result in transmission of infections like HIV, Hepatitis B and C, etc.
- It can also lead to bacterial sepsis and keloid formation.


### Tattoo Initials




**Figure 15.3.3.6:** Tattoo initials  
Photo Courtesy: Shailaja Mane, Pune

Putting the initials of the romantic partner is an age old practice.

In today's era removal of the tattoo if the relationship breaks off is an important aspect. The tattoo removal is expensive and can result in keloid formation.

Picture	Note	Management
 <p><b>Figure 15.3.3.7:</b> Modern teen tattoo Photo Courtesy: Tanmaya Amladi, Mumbai</p>	<p>Teens tattoo their body to:</p> <ul style="list-style-type: none"> <li>Enhance beauty of the body.</li> <li>Sex appeal.</li> <li>Memory of a loved one.</li> <li>Expressing faithfulness to a loved one.</li> <li>Macho image in males.</li> <li>Peer pressure.</li> <li>Poor self image—it is said that if there are more than 3 tattoos—the person has a poor self-image.</li> </ul>	<p><i>Precautions:</i></p> <ul style="list-style-type: none"> <li>• Use a disposable needle which is heated to red hot before it is cooled and used for tattooing.</li> <li>• Do not share needles.</li> <li>• Wash the skin with soap and dry it with a clean cloth before tattooing.</li> <li>• Dab bleeds during tattooing with sterile cotton.</li> <li>• If required spread an antiseptic cream over the tattoo after it is done.</li> <li>• Use clean washed clothing after completion of tattooing procedure.</li> <li>• Get a small tattoo on an area which is not visible when clothed, to check if the body and skin adjusts well to it.</li> <li>• Overexposure to sun may cause fading away of the tattoo.</li> </ul>

### Removed Tattoo

 <p><b>Figure 15.3.3.8:</b> Removed tattoo Photo Courtesy: Vijay Zawar, Nasik</p>	<p>Erasing a tattoo is not an easy job. This has been done with the help of Q-switched NdYag Lasers. Multiple sittings are required. Before advent of lasers, the different modalities used were dermabrasion, salabrasion, surgical excision and grafting, electrocauterization, cryotherapy.</p>	<ul style="list-style-type: none"> <li>• Scarring, pigmentary changes, keloid formation are adverse effects by other methods than lasers.</li> <li>• Hence, the latter are preferred these days.</li> </ul>
--	--	---

Picture	Note	Management
---------	------	------------

### 15.3.4 Adolescent Dermatology and Sexually Transmitted Disease (STD)

#### Dandruff



**Figure 15.3.4.1:** Dandruff  
Photo Courtesy: MKC Nair, Thiruvananthapuram

Dandruff is probably the most common scalp problem for the adolescents with lots of white flakes coming out, with hair fall causing self-esteem problems.

Dandruff has been associated with;

- skin oil commonly referred to as sebum or sebaceous secretion.
- the metabolic by-products of skin microorganisms (most specifically *Malassezia* yeasts).
- individual susceptibility with possible psychological overlay.

There is no permanent cure and regular treatment may be required for years. Since there is an association of fungus, dandruff—shampoo containing; selenium sulfide, zinc pyrithione, ketoconazole, terbinafine, etc. is recommended and in extremely severe cases systemic steroids and isotretinoin may be indicated.

#### Mobile Phone Dermatitis—Hand

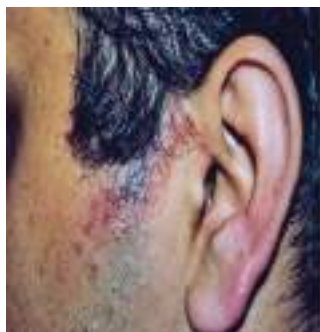

**Figure 15.3.4.2:** Mobile phone dermatitis—Hand  
Photo Courtesy: Abhaya Martin, Calicut

Cell phone usage has increased among teenagers. Constant cell phone usage can induce allergic contact dermatitis at the points of contact with the gadget. This is a photograph of the hand having contact dermatitis.

A patch testing may be done to identify the allergen.

#### Mobile Phone Dermatitis—Ear



**Figure 15.3.4.3:** Mobile phone dermatitis—Ear  
Photo Courtesy: Abhaya Martin, Calicut

The allergen is very often the nickel plating done on the phones. This nickel leaches out on sweating and leads to contact allergic dermatitis.

- The patient has to stop using the phone and switch to another handset that does not leach nickel.
- The standard treatment for contact dermatitis has to be given for the affected parts.

Picture	Note	Management
---------	------	------------

### Contact Allergic Dermatitis to Footwear



**Figure 15.3.4.4:** Contact allergic dermatitis to footwear  
Photo Courtesy: Abhaya Martin, Calicut

Footwears are a major cause of contact allergy.  
Newer trends in fashionable footwear and the use of synthetic chemicals in its manufacture have led to increasing number of cases of contact allergy to footwear.  
Fashion statements among teenagers and peer pressure force teenagers to try out new fanciful footwear.

- The patient has to stop wearing the footwear that has caused this problem.
- Patch testing with a footwear series is appropriate in this group of patients to identify the offending agent.

### Hair Perming

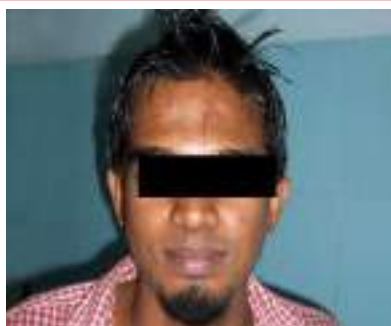

**Figure 15.3.4.5:** Hair perming  
Photo Courtesy: Abhaya Martin, Calicut

Hair grooming fads have become the norm among teenagers.  
Hair straightening, hair curling, hair weaving and perming may cause chemical induced damage to the hair shaft.

- This may be an important cause of lusterless hair and hair fall.
- The patient has to be explained the cause and advised to stop doing repeated perming.

### Hair Gel



**Figure 15.3.4.6:** Hair Gel  
Photo Courtesy: Abhaya Martin, Calicut

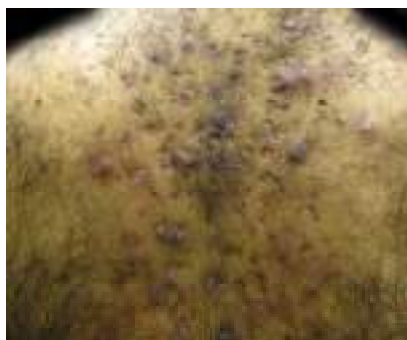Hair gel is very often used by today's teenagers to enable the hair to be styled in different ways and stay the same for a long time.

- This may be an important cause of lusterless hair and hair fall.
- The patient has to be explained the cause and advised to stop using gel completely or have restricted use at least.



Picture	Note	Management
---------	------	------------

### Sequelae of Acne—Scarring



**Figure 15.3.4.7:** Sequelae of acne—Scarring  
Photo Courtesy: Abhaya Martin, Calicut

Scars occur due to profound inflammation in the pilosebaceous unit.

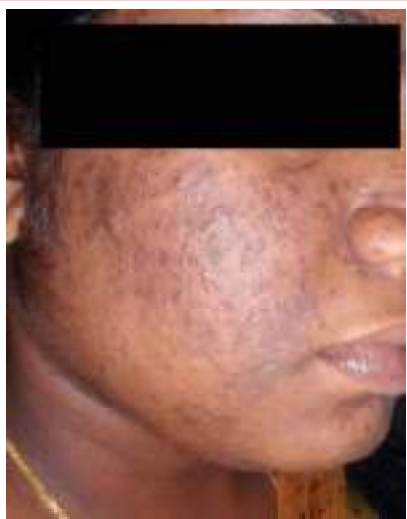More often seen in patients with nodulocystic acne.

Scars may be classified as ice-pick scars, box scars, linear scars, etc.

Classifications have bearing on treatment options.

Dermatosurgical options are needed in the management of acne scars and may include—subcision, discission, punch floatation, microdermabrasion and chemical peels.

### Sequelae of Acne—Pigmentation



**Figure 15.3.4.8:** Sequelae of acne—Pigmentation  
Photo Courtesy: Abhaya Martin, Calicut

Acne in some individuals may leave behind sequelae like post-inflammatory pigmentation (PIH).

Teenagers presenting with acne and PIH need empathetic management.

*Pathogenesis:* The pigmentation is most often dermal and may have a bluish-black discoloration.

*Differentials:*

- Minocycline induced bluish-black pigmentation
- Acne excorie de juvenilis
- Lichenoid dermatitis and lichen planus.

*Treatment options:*

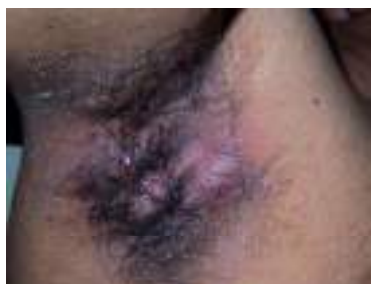- Demelanising agents—hydroquinone, kojic acid, arbutin, glabridin
- *Procedures*—Chemical peels with glycolic acid.

Demelanising agents—hydroquinone, kojic acid, arbutin, glabridin.

*Procedures:* Chemical peels with glycolic acid.

Picture	Note	Management
---------	------	------------

### Hidradenitis Suppurativa



**Figure 15.3.4.9:** Hidradenitis suppurativa  
Photo Courtesy: Abhaya Martin, Calicut

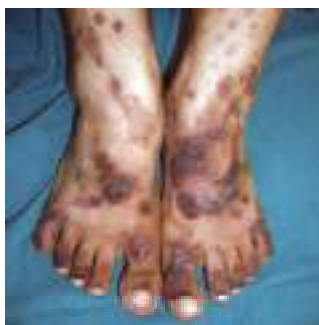Disease of the apocrine glands now termed acne inversa.

Exacerbates in pubertal age group and in the reproductive age.

Presents as nodular and cystic painful eruptions in the axillae, groin and perineal region lesions may rupture to form discharging sinuses.

- Difficult to treat due high rates of recurrence.
- May be associated with Acne conglobata and pilonidal sinus and such a presentation is called Triad of Pillsbury.

### Prurigo Nodularis



**Figure 15.3.4.10:** Prurigo nodularis  
Photo Courtesy: Abhaya Martin, Calicut

A psychocutaneous disorder seen very often in adolescents.

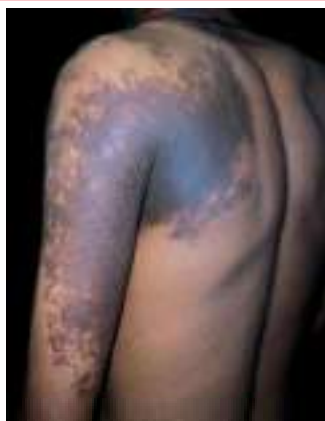A deep underlying and persistent stress is usually the cause for this ailment.

The lesions are usually hyperpigmented and lichenified papulonodular eruptions over easily accessible sites like extremities.

They start as itchy areas (most often) over points of insect bites and are repeatedly scratched to cause thickening and lichenification.

- Counseling.
- Psychiatric assessment.
- Topical and intralesional steroids may be warranted to relieve the intense desire to itch.

### Becker's Nevus




**Figure 15.3.4.11:** Becker's nevus  
Photo Courtesy: Abhaya Martin, Calicut


This hyperpigmented nevus is well known to exacerbate and enlarge in pubertal period and continues to enlarge through the adolescent period.

The nevus is benign but may develop secondary changes like acne-like eruptions and hair growth, ipsilateral breast hypoplasia and aplasia of pectoralis muscle.

Management depends upon the complications. It should be left alone if there are no complications.


Picture	Note	Management
<p><b>Condyloma Acuminata</b></p>  <p><b>Figure 15.3.4.12:</b> Condyloma acuminata Photo Courtesy: Abhaya Martin, Calicut</p>	<p>Sexually transmissible diseases are increasingly being recognized among teenagers.</p> <p>Unsafe sexual practices put the adolescent at risk of developing infections like HPV induced genital warts.</p> <p>HPV 16 and 18 serotypes are important as they may predispose to malignant transformation (carcinoma cervix).</p>	<p>Treatment options include:</p> <ul style="list-style-type: none"> <li>• Podophyllin in 25% tincture benzoin.</li> <li>• Trichloroacetic acid.</li> <li>• Imiquimod.</li> <li>• Radioand.</li> </ul>


### Molluscum Contagiosum



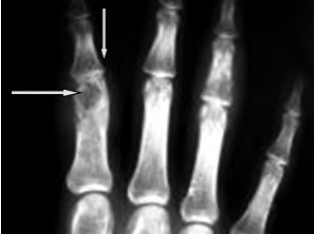
 <p><b>Figure 15.3.4.13:</b> Molluscum contagiosum Photo Courtesy: Jayakar Thomas, Chennai</p>	<p>An adolescent with dome shaped, pearly white, discrete umbilicated papules.</p> <p>Perilesional eczema, secondary bacterial infection, and spread of infection by Koebner's phenomenon are common complications.</p> <p>This patient gave history of sexual exposure.</p>	<p>First rule out HIV and other STIs.</p> <p>Manual removal wherever possible.</p> <p>In younger children, topical: retinoic acid 0.025 to 0.1%, KOH 10%, imiquimod 1-5%, flexible collodion - 17% salicylic acid and 17% lactic acid are useful. Electrocautery, liquid nitrogen cryotherapy. In older children. Ritonavir, cidofovir, zidovudine are found to be useful.</p>
--	--	--

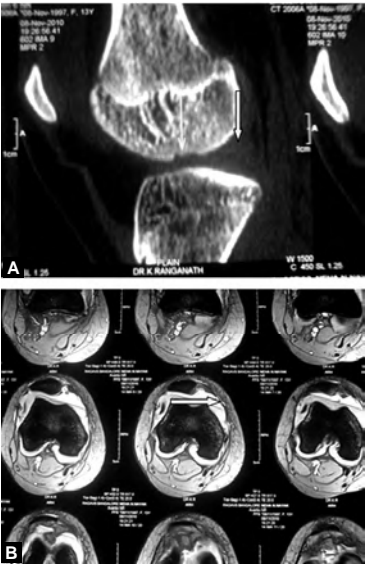
### 15.3.5 Subsection Orthopedic

#### Adolescent Scoliosis

 <p><b>Figure 15.3.5.1:</b> Adolescent scoliosis Photo Courtesy: Preeti Galagali, Bengaluru</p>	<p>Scoliosis is lateral curvature of spine &gt;10 degrees on X-ray Spine PA view.</p> <p>More common in girls, 3 to 5% of adolescent girls have scoliosis out of these only 15% need treatment.</p> <p>Most common cause is idiopathic scoliosis probably caused due to genetic and hormonal factors. Other causes include structural defects and neuromuscular diseases.</p>	<ul style="list-style-type: none"> <li>• Twenty three teens present with back pain.</li> <li>• Maximum progression occurs in periods of rapid growth in SMR stages 2 to 3 in girls and 3 to 4 in boys.</li> <li>• Long-term sequelae of untreated severe scoliosis include chronic back pain, arthritis, poor body image and cardiorespiratory compromise.</li> </ul>
--	---	---


Picture	Note	Management
<p data-bbox="88 247 522 278"><b>Adolescent Scoliosis—Adam’s Test</b></p>  <p data-bbox="106 592 511 663"><b>Figure 15.3.5.2:</b> Adolescent Scoliosis—Adam’s test <i>Photo Courtesy:</i> Anand Galagali, Bengaluru</p>	<p data-bbox="543 304 927 334">Forward bending test of Adams.</p> <p data-bbox="543 344 927 506">The patient in a standing position is asked to bend over 90 degrees or more with arms hanging downward in a relaxed position, elbows extended and palms together.</p> <p data-bbox="543 516 927 610">The forward bending test assesses spinal flexibility and asymmetry of thoracic/lumbar spine.</p>	<ul data-bbox="965 304 1346 1326" style="list-style-type: none"> <li>• Depends on degree of curvature, rate of growth, associated symptoms and patient compliance. Close follow-up is required.</li> <li>• No treatment is indicated for adolescents who have completed their growth (SMR stages 4 to 5) with asymptomatic and cosmetically acceptable curves of &lt; 20 degrees and no indication of underlying neurologic or musculoskeletal disease.</li> <li>• Immature adolescents (SMR stages 2 to 4) with &lt;25 degrees may not need treatment but require close follow-up with periodic clinical and radiographic assessment according to the following schedule: <ul data-bbox="965 949 1346 1326" style="list-style-type: none"> <li>• &lt;15 degrees—follow at 6 to 12 months</li> <li>• 15 to 20 degrees—follow at 5 to 6 months</li> <li>• &gt;25 degrees—follow at 4 months</li> </ul> </li> <li>• Curves &gt;30 degrees, rapidly progressive curves, symptomatic curves with cardiorespiratory compromise, structural vertebral defects require surgical intervention.</li> </ul>

Picture	Note	Management
<p><b>X-ray Scoliosis Cobb's Angle</b></p>  <p><b>Figure 15.3.5.3:</b> X-ray scoliosis Cobb's angle Photo Courtesy: Anand Galagali, Bengaluru</p>	<p>X-ray spine—Left thoracolumbar scoliosis from T10 to L4. Cobb's method is used to measure curves. Straight lines are drawn from the top of the uppermost vertebrae of both the thoracic and lumbar curves. Perpendiculars are then drawn from thoracic and lumbar lines. The acute angle of intersect of these perpendiculars is taken as the degree of scoliosis.</p>	<ul style="list-style-type: none"> <li>• Curves &lt;30 degrees at skeletal maturity do not show progression.</li> <li>• Curves &gt;30 degrees or rapidly increasing curves need orthopedic management in form of bracing and/or surgery.</li> </ul>
<p><b>Tuberculous Dactylitis</b></p>  <p><b>Figure 15.3.5.4:</b> Tuberculous dactylitis Photo Courtesy: Preeti Galagali, Bengaluru</p>	<p>Dactylitis is inflammation of phalanges. It presents with pain, swelling and restriction of movement of interphalangeal joints seen in sickle cell anemia, enchondroma, juvenile idiopathic arthritis, psoriasis, gonococcal and tubercular arthritis.</p>	<p>The management is giving treatment for the underlying cause, in this case antituberculosis drugs.</p>
<p><b>X-ray—TB Dactylitis</b></p>  <p><b>Figure 15.3.5.5:</b> X-ray—TB dactylitis Photo Courtesy: Anand Galagali, Bengaluru</p>	<p>This is a X-ray of a hand showing to filling defects in the phalanges due to tuberculosis.</p>	<p>Repeat X-ray should be taken at the end of the drug treatment to see the healing.</p>

Picture	Note	Management
	<p>13-year-old girl presented with acute pain and swelling of the knee joint following a twisting injury while performing Bharatnatyam Dance.</p> <p>On examination—Restricted movements of the knee joint with hemarthrosis</p> <p>MRI Scan—Well demarcated radiolucent area on the medial condyle.</p> <ul style="list-style-type: none"> <li>• Important cause of anterior knee pain, limitation of movement and effusion in adolescents. Characterized by delamination of subchondral bone.</li> <li>• Exact etiology not known, probably due to overuse or local vascular insufficiency.</li> <li>• <i>Complication:</i> Intra-articular loose body, locking of knee joint, early arthritis.</li> <li>• CT and MRI scan are done to confirm diagnosis and rule out meniscal and intra-articular ligament tear.</li> </ul>	<ul style="list-style-type: none"> <li>• Rest and analgesics to allow for healing over 8 to 12 weeks.</li> <li>• Poor response to conservative treatment should prompt an early referral to Orthopedic Surgeon for surgery.</li> <li>• Surgery entails arthroscopy to identify and grade the lesion. Mild cases are treated with fixation with bioscrews and the severe ones require microdrilling with cartilage transfer.</li> </ul>

**Figures 15.3.5.6A and B:** Osteochondritis dessicans presurgery MRI scan-1  
*Photo Courtesy:* Anand Galagali, Bengaluru

### Cervical Rib

	<p>Arises from the 7<sup>th</sup> cervical vertebra 1 in 500 incidence.</p> <p>Usually unilateral, rarely seen on both sides.</p> <p>Can result in 'thoracic outlet syndrome'</p> <p>Numbness or weakness of the hand especially on abduction and external rotation of shoulder may be the earliest symptom.</p>	<ul style="list-style-type: none"> <li>• Confirmation by X-ray.</li> <li>• Reassurance.</li> <li>• Excision of the rib if there is vascular compromise or neurological problem.</li> </ul>
---	--	--

**Figure 15.3.5.7:** Cervical rib  
*Photo Courtesy:* Shaji Thomas John, Calicut

## 15.4 COMMUNITY PROGRAMS

Picture	Note	Management
---------	------	------------

### Pranayama-1



**Figure 15.4.1:** Pranayama-1  
Photo Courtesy: Swati Y Bhave, New Delhi

Due to fierce academic competition, today's Indian teens are under tremendous stress and often manifest with stress-related physical and mental symptoms.

- Learning to cope with emotions and stress will keep adolescents away from substance abuse and mental problems like depression, aggression, and violence. Adolescents need to be taught stress management.
- Yoga and pranayama are good methods.

### Stress Management—Relaxation



**Figure 15.4.2:** Stress management—Relaxation  
Photo Courtesy: Swati Y Bhave, New Delhi

Learning to de-stress and handle stress in their life in a positive manner is an important skill for adolescents. There are various techniques for relaxation like meditation, progressive muscular relaxation, etc.

This is a session to teach meditation to teenagers.

### Health Education for Teens



**Figure 15.4.3:** Health education for teens  
Photo Courtesy: Swati Y Bhave, New Delhi

This is a poster competition for tobacco or health. Health Quizzes are also good ways of educating teens.

Poster competitions for teens. On various health issues are a very good methodology to create awareness and give information and also bring out creativity.

Picture	Note	Management
---------	------	------------

### Parenting Workshops—Role Play



**Figure 15.4.4:** Parenting workshops—Role play  
Photo Courtesy: Swati Y Bhawe, New Delhi

Interactive workshops are a very good way of teaching parenting skills and giving them insight into adolescent issues and the skills to deal with them.

Giving them case scenarios and asking them to do role plays to highlight various issues are a practical way of learning.

### Parenting Workshops—Stress Management



**Figure 15.4.5:** Parenting workshops—Stress management  
Photo Courtesy: Swati Y Bhawe, New Delhi

Parents of teenagers are often extremely stressed out due to their own middle age related problems and find it difficult to cope up with teenage issues.

Coping with their own stress is equally important for parents and pranayama and yoga can be taught in these workshops.

### Orientation Program for Teachers and Parents—Adolescent Development



**Figure 15.4.6:** Orientation program for teachers and parents—Adolescent development  
Photo Courtesy: Swati Y Bhawe, New Delhi

Orientation programs for parents and teachers on adolescent mental, physical and psychosocial development are very important for them to understand and improving communication with teens.

Attending such programs helps the parents to understand that all teens have similar problems and they need to develop better parenting skills to deal with them in a positive and healthy manner.



Picture	Note	Management
---------	------	------------

### Orientation Program for Teachers and Parents—Suicide Prevention



**Figure 15.4.7:** Orientation program for teachers and parents—Suicide prevention  
*Photo Courtesy:* Swati Y Bhave, New Delhi

Teenage suicides are on the rise in India. The common causes are academic failure and rejection and failures in romantic relationships.

Suicide prevention sessions are important for parents to understand depression and flag signs of suicide attempts.

### With Special Adolescents (Mentally Challenged)



**Figure 15.4.8:** With special adolescents (Mentally challenged)  
*Photo Courtesy:* Shaji Thomas John, Calicut

Adolescent nursing students seen with early adolescent mentally challenged children in a juvenile home.  
An enlightening and educative interaction for them.  
A recreational outing and a training session for the early adolescents with special needs.

Encourage interactions with adolescents with special needs. Normal adolescent children should be sensitized on the status of their lesser privileged counterparts. Such interactive programs help both these groups of children.

### School Counseling



**Figure 15.4.9:** School counseling  
*Photo Courtesy:* MKC Nair, Thiruvananthapuram

School counseling focuses on the relations and interactions between students and their school environment to reduce the effects of environmental and institutional barriers that impede student academic success.  
The counselor assists students in their academic, career, social, and personal development and helps them follow the path to success.

The school counselor serves as a leader as well as an effective team member working with teachers, and empowers families to act on behalf of their children by helping parents and guardians identify student needs and interests, and access available resources.

Picture	Note	Management
---------	------	------------

### Adolescent Friendly Health Services in the Rural Set-up



**Figure 15.4.10:** Adolescent friendly health services in the rural set-up  
Photo Courtesy: MKC Nair, Thiruvananthapuram

Adolescent friendly health services (AFHS) is one that is accessible, acceptable, equitable, inclusive, comprehensive in nature and with friendly staff. In the rural setting.

Adolescent friendly health services must meet the needs of rural children between 10 and 19 years sensitively and effectively. Such services deliver on the rights of adolescents and represent an efficient use of precious health resources.

### Oath to Prevent Sexual Abuse-1



**Figure 15.4.11:** Oath to prevent sexual abuse-1  
Photo Courtesy: MKC Nair, Thiruvananthapuram

One of the effective strategy to reduce sexual abuse among adolescent children is to empower them to protect themselves.

The school children are made to take the oath *"I am the custodian of my mind, body and spirit—I will protect, preserve and enhance it"*.


### Oath to Prevent Sexual Abuse-2




**Figure 15.4.12:** Oath to prevent sexual abuse-2  
Photo Courtesy: MKC Nair, Thiruvananthapuram

One of the effective strategy to reduce sexual abuse among adolescent children is to empower them to protect themselves.

Wearing a badge saying the same in the school assembly. They will continue to wear the badge throughout the day, creating discussion points with peers and parents.

Picture	Note	Management
<p data-bbox="88 247 652 278"><b>School Health Check-up Dental Examination</b></p>  <p data-bbox="107 590 513 637"><b>Figure 15.4.13:</b> School health check-up dental examination</p> <p data-bbox="107 641 513 667"><i>Photo Courtesy:</i> MKC Nair, Tiruvnatanapuram</p>	<p data-bbox="543 308 936 550">School health check-ups are very important for teens. They help to identify health problems that can have long-term adverse health effects. They also serve to monitor the growth and health progress of a teen and decide appropriate referral for timely treatment.</p>	<p data-bbox="965 308 1300 368">School health check-up should include immunization status:</p> <ul data-bbox="965 379 1300 1048" style="list-style-type: none"> <li>• Weight</li> <li>• Height</li> <li>• Blood pressure</li> <li>• Hemoglobin</li> <li>• Goiter</li> <li>• Dental caries</li> <li>• Headache</li> <li>• Vision</li> <li>• Hearing</li> <li>• Menstrual problems</li> <li>• Polycystic ovary disease</li> <li>• Genitourinary infections</li> <li>• Medical problems</li> <li>• Behavioral problems</li> <li>• Anxiety</li> <li>• Depression</li> <li>• Suicidal ideation</li> <li>• Any other (specify).</li> </ul>

### School Health Check-up ENT Examination

 <p data-bbox="107 1576 513 1622"><b>Figure 15.4.14:</b> School health check-up ENT examination</p> <p data-bbox="107 1626 513 1653"><i>Photo Courtesy:</i> MKC Nair, Tiruvnatanapuram</p>	<p data-bbox="543 1294 899 1354">ENT examination of a teen being done in a health camp.</p>	<p data-bbox="965 1294 1358 1415">ENT examination is very important as defective hearing may affect the academic performance and also the personality development of a teen.</p>
---	---	--

## Section 16

---

# Child Abuse, Neglect and Child Labor

*Section Editor*  
Meenakshi Mehta

*Photo Courtesy*  
Meenakshi Mehta

- 
- 16.1 Child Abuse and Neglect
  - 16.2 Child Labor

## SECTION OUTLINE

### 16.1 CHILD ABUSE AND NEGLECT 339

- ◆ Rat Bite in an Abandoned Newborn 339
- ◆ Abandoned Newborn with Rat Bite Marks 339
- ◆ Child Neglect: Rat Bite 339
- ◆ Severe Abuse—Physical, in a Child Employed as Domestic Servant 340
- ◆ Physical Abuse in Two Sisters 340
- ◆ Child Abuse: Physical, Beaten by her Employer 340
- ◆ Sexual Abuse: Three Years Old Girl, “Raped” by Father’s Employee 341
- ◆ Sexual and Other Abuses in Children, India—Statewise 2010 341
- ◆ Child Sexual Abuses in Children Statewise Data, 2010 341
- ◆ Child Sexual Abuse 342
- ◆ Child Abuse: Abandoned Newborn with Congenital Anomalies 342
- ◆ Abandoned Newborn with Marasmus 342
- ◆ Child Abuse: Abandoned in Pediatric Ward 343
- ◆ Child Abuse: Child Used for Entertainment 343
- ◆ Child Abuse: Girls Used for Entertainment 343
- ◆ Child Abuse: Entertainment (Girl Walking on Rope) 344
- ◆ Child Abuse: Entertainment (Boy Climbing on Pole) 344
- ◆ Child Abuse: Entertainment (Self-Employed) 345
- ◆ Child Abuse: Alcohol Abuse/Child Neglect 345
- ◆ Child Neglect: Burns Due to Maternal Neglect 345
- ◆ Child Neglect: Burns with Hot Water 346
- ◆ Child Abuse: Manchaunsan’s Syndrome by Proxy 346

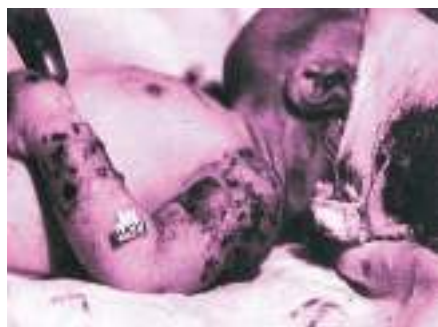### 16.2 CHILD LABOR 347

- ◆ Child Labor: Children Working in Different Industries 347
- ◆ Child Labor: Children Working in Different Industries 347
- ◆ Child Labor: Girl Carrying Stone on Head 347
- ◆ Child Labor: Boy Working in Puffed Rice Factory 348
- ◆ Child Labor: Boy Working on Street Pot Hole 348
- ◆ Child Labor: Boy Crushing Stones 348
- ◆ Child Labor: Children Working in Brick-Kiln 349
- ◆ Child Labor: Boy Fixing Screws on a Machine 349
- ◆ Child Labor: Children Carrying Heavy Loads/Bricks/Stones on Head 349
- ◆ Child Labor: Child Working in Mines 350
- ◆ Child Labor: Girl Carrying Earthen Pots 350
- ◆ Child Labor: Girl Selling Flowers, Garlands 350
- ◆ Child Labor: Child Carrying Stones 351
- ◆ Child Labor: Child Carrying Cowdung Cakes 351
- ◆ Child Labor: Child Working in Garage 351
- ◆ Child Labor: Child Working in Mirchi Field 352
- ◆ Child Labor: Boy Working in Tea Stall 352
- ◆ Child Labor: Boy Working in Tea Stall 352
- ◆ Child Labor: Boy Working in Tea Stall 353
- ◆ Child Labor: Child Working in Workshop/Factory 353
- ◆ Child Labor: Young Boy Working at Construction Site 353
- ◆ Child Labor: Child Selling Earrings 354
- ◆ Child Labor: Children Cleaning Utensils 354
- ◆ Child Labor: Child Laborers Caught by Police from Railway Station 354
- ◆ Child Labor: Ban or No Ban 355

## 16.1 CHILD ABUSE AND NEGLECT

Picture	Note	Management
---------	------	------------

### Rat Bite in an Abandoned Newborn

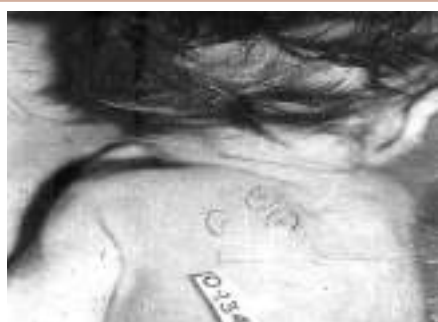

**Figure 16.1.1:** Rat bite in an abandoned newborn.  
 Photo Courtesy: Meenakshi Mehta, Mumbai

Abandoned newborn with multiple rat bite injuries on left hand, arm neck and avulsion of scalp, found by police from garbage.

Immediate Rx of injuries, hypothermia and sepsis. Prevent tetanus by giving ATS and tetanus immunoglobulin and later rehabilitation through orphanage and juvenile court.

### Abandoned Newborn with Rat Bite Marks

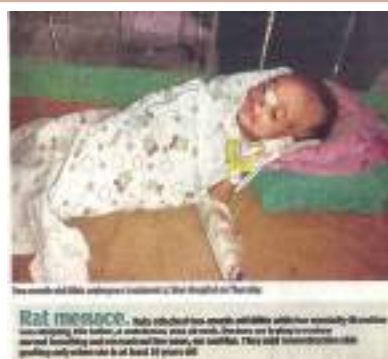

**Figure 16.1.2:** Abandoned newborn with rat bite marks.  
 Photo Courtesy: Meenakshi Mehta, Mumbai

This newborn was abandoned in a garbage. On salvaging, rat bite marks were seen on the back.

Creating social awareness towards the welfare of children and elimination of poverty, which is a difficult task.




### Child Neglect: Rat Bite



**Figure 16.1.3:** Rat bite  
 Photo Courtesy: DNA, Mumbai, 17th September, '11, Meenakshi Mehta, Mumbai

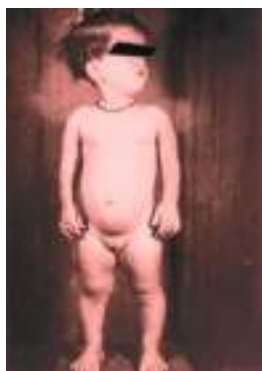Two months old baby attacked by rat(s), destroying nose, lip and ears while the baby was asleep, next to her mentally ill mother in slums. Father was at work as watchman and detected the injured baby when he returned from work in the morning.

Immediate Rx of wounds, blood loss, prevent infection. Reconstructive surgery when the child grows up to about 10 years of age.

Picture	Note	Management
<p data-bbox="152 212 1031 247"><b>Severe Abuse—Physical, in a Child Employed as Domestic Servant</b></p>  <p data-bbox="164 629 574 731"><b>Figure 16.1.4:</b> Severe abuse—Physical, in a child employed as domestic servant <i>Photo Courtesy:</i> Mumbai Mirror, October 1st, 2011, Meenakshi Mehta, Mumbai</p>	<p data-bbox="630 273 1031 461">Ten years old boy, hired as domestic help? adopted, by a family for last three years was allegedly pierced with a ‘screw driver’ by his employer, because he dropped a plate in the house.</p>	<ul data-bbox="1073 273 1471 629" style="list-style-type: none"> <li>• Neighbors took the bleeding and wailing boy to the clinic, where many more marks of previous torture—bruises, burn marks, healed scars on the back, limbs, hips and face were noticed.</li> <li>• Social welfare schemes for education, medical and comprehensive care of working children and rehabilitation in his own family.</li> </ul>
<p data-bbox="152 833 545 868"><b>Physical Abuse in Two Sisters</b></p>  <p data-bbox="164 1197 574 1279"><b>Figures 16.1.5A and B:</b> Girls, two sisters with injuries on hand and neck <i>Photo Courtesy:</i> Meenakshi Mehta, Mumbai</p>	<p data-bbox="630 895 1031 1050">Tortured by their father, beaten and scalded with iron rods repeatedly. Father was going to sacrifice these two girls at the advice of the “tantric” as his business was failing.</p>	<p data-bbox="1073 895 1471 956">Salvaging these two sisters from this situation and counseling the father.</p>
<p data-bbox="152 1365 773 1400"><b>Child Abuse: Physical, Beaten by her Employer</b></p>  <p data-bbox="164 1810 574 1884"><b>Figure 16.1.6:</b> Girl with hematomas below both eyes <i>Photo Courtesy:</i> Meenakshi Mehta, Mumbai</p>	<p data-bbox="630 1426 1031 1549">This 10 years old girl worked as a domestic help. She was beaten for eating without permission from family’s “shrikhand.” [dessert]</p>	<p data-bbox="1073 1426 1471 1488">Salvaging the girl from child labor and later rehabilitation.</p>

Picture	Note	Management
---------	------	------------

**Sexual Abuse: Three Years Old Girl, “Raped” by Father’s Employee**



**Figure 16.1.7:** Index case three years, illegitimate girl raped by father’s employee  
*Photo Courtesy:* Meenakshi Mehta, Mumbai

This girl child, illegitimate, was raped by father’s employee. Father was owner of a gambling den and one of the workers raped this child. Was brought to LTMG hospital, Sion, Mumbai.

Rehabilitated through Children’s Remand Home.

**Sexual and Other Abuses in Children, India—Statewise 2010**



**Figure 16.1.8:** Sexual and other abuses in children, India—Statewise 2010  
*Photo Courtesy:* Hindustan Times, Mumbai, Oct., 31, 2011, Meenakshi Mehta, Mumbai

National Crime Records Bureau: 5484 children sexually assaulted, 1408 killed and over 10,000 kidnapped. Maharashtra had highest incidence of sexual assault.

Protection of children by all the adults—family, government, police, legal, NGOs. Sexual education of children and teach about reporting sexual abuse.

**Child Sexual Abuses in Children Statewise Data, 2010**



**Figure 16.1.9:** Child sexual abuses in children Statewise data, 2010  
*Photo Courtesy:* Hindustan Times, 31st October 2011, Meenakshi Mehta, Mumbai

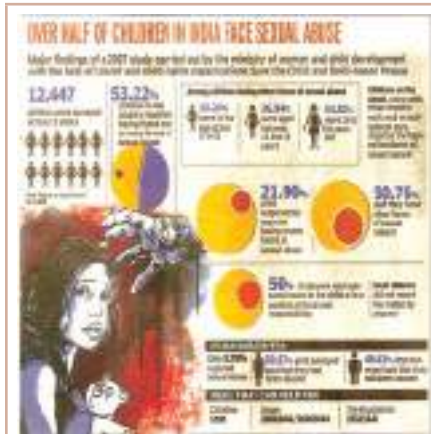
National Crime Records Bureau: 5484 children sexually assaulted, 1408 killed and over 10,000 kidnapped. Maharashtra had highest incidence of sexual assault

Protection of children by all the adults—family, government, police, legal, NGOs. Sexual education of children and teach about reporting sexual abuse.



Picture	Note	Management
---------	------	------------

**Child Sexual Abuse**

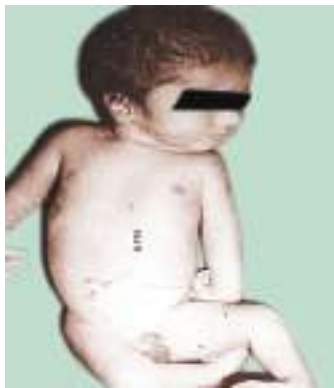

**Figure 16.1.10:** Child sexual abuse  
 Source: Hindustan Times, 4th October 2011, Mumbai

National Crime Records Bureau: 5484 children sexually assaulted, 1408 killed and over 10,000 kidnapped. Maharashtra had highest incidence of sexual assault.

Protection of children by all the adults—family, government, police, legal, NGOs. Sexual education of children and teach about reporting sexual abuse.

**Child Abuse: Abandoned Newborn with Congenital Anomalies**

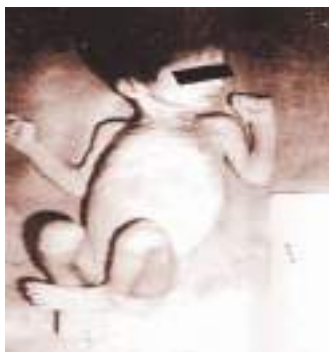

**Figure 16.1.11:** Abandoned newborn with congenital anomalies  
 Photo Courtesy: Meenakshi Mehta, Mumbai

Newborn with congenital anomalies abandoned in garbage, example of child abuse. Was brought by police to hospital.

Social education and overall welfare of children including disabled.

**Abandoned Newborn with Marasmus**





**Figure 16.1.12:** Abandoned newborn with marasmus  
 Photo Courtesy: Meenakshi Mehta, Mumbai




Fifteen/Sixteen days old brought for loose motions in marasmic condition, deserted in an orphanage cradle. Example of nutritional abuse/ neglect.


Social awareness towards acceptance of illegitimacy and elimination of poverty.

Picture	Note	Management
<p><b>Child Abuse: Abandoned in Pediatric Ward</b></p>  <p><b>Figure 16.1.13:</b> Unknown girl abandoned in Childrens ward <i>Photo Courtesy:</i> Meenakshi Mehta, Mumbai</p>	<p>This 3 years old girl was deserted in the children’s ward of LTMG Hospital, Sion, Mumbai, in unconscious condition. Diagnosed to have TBM, treated and later rehabilitated</p>	<p>Later rehabilitated through Children’s Remand Home, Mumbai.</p>
<p><b>Child Abuse: Child Used for Entertainment</b></p>  <p><b>Figure 16.1.14:</b> Boy with stone hanging from neck <i>Photo Courtesy:</i> Meenakshi Mehta, Mumbai</p>	<p>Street child lifting heavy stones on neck and doing shows for entertainment of people.</p>	<p>Comprehensive help to the child and his family especially educational, social and economical rehabilitation through government schemes.</p>
<p><b>Child Abuse: Girls Used for Entertainment</b></p>  <p><b>Figures 16.1.15A and B:</b> Girls balancing on rope for entertainment <i>Photo Courtesy:</i> Meenakshi Mehta, Mumbai</p>	<p>Young girls balancing, walking on rope, performing risky street show for entertainment of people to earn livelihood for the family.</p>	<p>Elimination of poverty, social upliftment, job security for the family, education and welfare of children.</p>


Picture	Note	Management
<b>Child Abuse: Entertainment (Girl Walking on Rope)</b>		
 <p data-bbox="164 574 566 647"><b>Figure 16.1.16:</b> A nomad girl walks on the rope <i>Photo Courtesy:</i> Meenakshi Mehta, Mumbai</p>	<p data-bbox="626 273 1024 513">A nomad girl walks on rope, balancing act—a form of protest in New Delhi for implementation of the Rinke Commission Report.</p> <p data-bbox="626 421 1045 513">Example of child abuse, using children for entertainment of people for earning livelihood.</p>	<p data-bbox="1070 273 1442 400">This report recommends enhancement of their social and economic status of nomads and people in general.</p>

<b>Child Abuse: Entertainment (Boy Climbing on Pole)</b>		
 <p data-bbox="164 1606 566 1655"><b>Figure 16.1.17:</b> Boy on the pole <i>Photo Courtesy:</i> Meenakshi Mehta, Mumbai</p>	<p data-bbox="626 825 1045 887">Boy climbing on a pole, entertaining people for street show.</p>	<p data-bbox="1070 825 1471 952">Social upliftment, elimination of poverty, education, job security for family. Rehabilitation of affected children in their families.</p>

Picture	Note	Management
<p><b>Child Abuse: Entertainment (Self-Employed)</b></p>  <p><b>Figure 16.1.18:</b> Boy with monkey as a pet Photo Courtesy: Meenakshi Mehta, Mumbai</p>	<p>Poor street boy probably uneducated, unemployed has kept monkey as pet and earns petty amount by doing street shows with this monkey for entertainment of people.</p>	<p>Comprehensive help to the child and his family especially educational, social and economical rehabilitation through government schemes.</p>
<p><b>Child Abuse: Alcohol Abuse/Child Neglect</b></p>  <p><b>Figure 16.1.19:</b> Child abuse, alcohol abuse Photo Courtesy: Meenakshi Mehta, Mumbai</p>	<p>Ten years old girl brought in unconscious state detected to be in "alcoholic coma". Mother had deserted the child in care of grandmother who had a business of "country liquor". This girl used to help the grandmother in serving the customers and got drunk, became unconscious.</p>	<p>Education of the parents/guardians towards proper care of children. If possible, elimination of poverty, job security and social rehabilitation.</p>
<p><b>Child Neglect: Burns Due to Maternal Neglect</b></p>  <p><b>Figure 16.1.20:</b> Burns on left leg, buttocks Photo Courtesy: Meenakshi Mehta, Mumbai</p>	<p>This infant was left alone near hot water for bath, while the mother went to get something. The infant crawled/turned over and got burnt.</p>	<p>Mother/caretaker should be careful while handling infants and children to prevent such mishaps.</p>

Picture	Note	Management
 <p><b>Figure 16.1.21:</b> Burn injury on thighs Photo Courtesy: Meenakshi Mehta, Mumbai</p>	<p>This infant was left alone near hot water for bath, while the mother went to get something. The infant crawled/turned over and got burnt.</p>	<p>Mother/caretaker should be careful while handling infants and children to prevent such mishaps.</p>

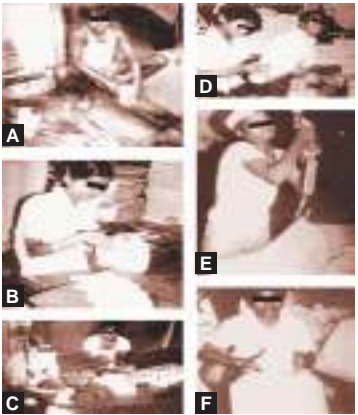
### Child Abuse: Manchaunsan's Syndrome by Proxy

 <p><b>Figure 16.1.22:</b> Manchaunsan's syndrome by proxy Photo Courtesy: Meenakshi Mehta, Mumbai</p>	<p>Child was brought with history of hematemesis, faked by his father. Clinically there was no evidence of any organ involvement; this illness was fabricated by the father. It is a manifestation of fabricated illness usually by an adult—a parent/guardian, in a child which may mimic a real illness, with an objective of drawing attention of medical personnel and in turn getting self importance. The faked “blood” in the bottle was “sindoor” dissolved in water.</p>	<p>Psychiatric treatment with counseling of the responsible parent to prevent recurrence.</p>
---	---	---

## 16.2 CHILD LABOR

Picture	Note	Management
---------	------	------------


### Child Labor: Children Working in Different Industries




 <p><b>Figures 16.2.1A to F:</b> Children working in different industries  <i>Photo Courtesy:</i> Meenakshi Mehta, Mumbai</p>	<p>Children working in different industries at “Dharavi”, Mumbai, India’s biggest slum. Example: Hardware, packing, plastic products, etc.</p>	<p>Comprehensive rehabilitation of child labor. Educational, social, economical with relocation in the family with financial support.</p>
--	--	---




### Child Labor: Children Working in Different Industries

 <p><b>Figures 16.2.2A to F:</b> Children working in different industries  <i>Photo Courtesy:</i> Meenakshi Mehta, Mumbai</p>	<p>Children working in hosiery, readymade garments, auto garage, cobbler, selling vegetables, etc. at Dharavi slums, Mumbai.</p>	<p>Through government employment schemes. Elimination of Child Labor is no solution unless alternative familial help is assured.</p>
---	--	--




### Child Labor: Girl Carrying Stone on Head




 <p><b>Figure 16.2.3:</b> Girl carrying stone on head  <i>Photo Courtesy:</i> Meenakshi Mehta, Mumbai</p>	<p>For example of child labor. Almost ½ of India is grappling with child labor, approximately 18 million children toiling for daily wages, majority in exploitative situations.</p>	<p>Comprehensive rehabilitation of child labor. Education, social, economical with relocation of the child in his family with financial support to the family through government employment schemes, etc.</p>
--	---	---


Picture	Note	Management
<b>Child Labor: Boy Working in Puffed Rice Factory</b>		
 <p data-bbox="162 629 584 678"><b>Figure 16.2.4:</b> Boy working in puffed rice factory <i>Photo Courtesy:</i> Meenakshi Mehta, Mumbai</p>	<p data-bbox="625 275 1036 398">Many children in puffed rice factories develop respiratory problems because they work near cauldrons heated to 800°C.</p>	<p data-bbox="1068 275 1409 367">Socioeconomic development of India. Family rehabilitation, educational, economic, social.</p>
<b>Child Labor: Boy Working on Street Pot Hole</b>		
 <p data-bbox="162 1277 584 1326"><b>Figure 16.2.5:</b> Boy working on street pot hole <i>Photo Courtesy:</i> Meenakshi Mehta, Mumbai</p>	<p data-bbox="625 848 1036 970">This young boy is seen working and helping repair pot hole. Danger of drowning in deeper gutter below where he is working.</p>	<p data-bbox="1068 848 1409 940">Socioeconomic development of India. Family rehabilitation, educational, economic, social.</p>
<b>Child Labor: Boy Crushing Stones</b>		
 <p data-bbox="162 1829 584 1880"><b>Figure 16.2.6:</b> Boy crushing stones <i>Photo Courtesy:</i> Meenakshi Mehta, Mumbai</p>	<p data-bbox="625 1502 1036 1645">Young child involved in strenuous job of breaking stones. Danger of injury to hands, legs and inhalation of stone fine particles.</p>	<p data-bbox="1068 1502 1409 1604">Socioeconomic development of India. Family rehabilitation, educational, economic, social.</p>

Picture	Note	Management
<p><b>Child Labor: Children Working in Brick-Kiln</b></p>  <p><b>Figure 16.2.7:</b> Children working in brick-kiln <i>Photo Courtesy:</i> Meenakshi Mehta, Mumbai</p>	<p>Young children working at a brick-kiln in Allahabad.</p>	<p>Socioeconomic development of India. Family rehabilitation, educational, economic, social.</p>
<p><b>Child Labor: Boy Fixing Screws on a Machine</b></p>  <p><b>Figure 16.2.8:</b> Boy fixing screws on a machine <i>Photo Courtesy:</i> Meenakshi Mehta, Mumbai</p>	<p>Young children are employed in all sorts of work violating ban under the Child Labor [Prohibition and Regulation] Act 1986, would lead to prosecution, penalties and other punitive action.</p>	<p>Socioeconomic development of India. Family rehabilitation, educational, economic, social.</p>
<p><b>Child Labor: Children Carrying Heavy Loads/Bricks/Stones on Head</b></p>  <p><b>Figure 16.2.9:</b> Children carrying heavy loads/bricks/stones on head <i>Photo Courtesy:</i> Meenakshi Mehta, Mumbai</p>	<p>Children carrying heavy loads/bricks/stones on head.</p>	<p>Government is supposed to follow-up on the education of rescued child laborers after being sent back to their parents. However, the HC has pulled up the state for failing to produce any such records.</p>



Picture	Note	Management
<b>Child Labor: Child Working in Mines</b>		
	<p>A girl works in an iron ore dump yard in Jharkhand's West Singhbhum district.</p>	<p>Government is supposed to follow-up on the education of rescued child laborers, after being sent back to their parents. However, the HC has pulled up the state for failing to produce any such records.</p>
<p><b>Figure 16.2.10:</b> Child working in mines Photo Courtesy: Meenakshi Mehta, Mumbai</p>		
<b>Child Labor: Girl Carrying Earthen Pots</b>		
	<p>Typical site seen "<i>Kumbharwada, Dharavi</i>". Girl helps her family for selling small pots.</p>	<p>Government to follow-up is supposed on the education of rescued child laborers, after being sent back to their parents. However, the HC has pulled up the state for failing to produce any such records.</p>
<p><b>Figure 16.2.11:</b> Girl carrying earthen pots Photo Courtesy: Meenakshi Mehta, Mumbai</p>		
<b>Child Labor: Girl Selling Flowers, Garlands</b>		
	<p>A girl 7 to 8 years old making garlands and selling them.</p>	<p>Socioeconomic development of India. Family rehabilitation, educational, economic, social.</p>
<p><b>Figure 16.2.12:</b> Girl selling flowers, garlands Photo Courtesy: Meenakshi Mehta, Mumbai</p>		


Picture	Note	Management
<p><b>Child Labor: Child Carrying Stones</b></p>  <p><b>Figure 16.2.13:</b> Child carrying stones Photo Courtesy: Meenakshi Mehta, Mumbai</p>	<p>Child carrying stones/load.</p>	<p>Notification issued prohibiting employment of children as domestic servants and in dhabas, eateries, tea shops, etc. with effect from 2006. Offending employers are liable for criminal prosecution.</p>
<p><b>Child Labor: Child Carrying Cowdung Cakes</b></p>  <p><b>Figure 16.2.14:</b> Girl carrying cowdung cakes Photo Courtesy: Meenakshi Mehta, Mumbai</p>	<p>Child carrying cowdung cakes for selling. Typical site in village and Urban slums.</p>	<p>Notification issued prohibiting employment of children as domestic servants and in dhabas, eateries, tea shops, etc. with effect from 2006. Offending employers are liable for criminal prosecution.</p>
<p><b>Child Labor: Child Working in Garage</b></p>  <p><b>Figure 16.2.15:</b> Child working in garage: wheel Photo Courtesy: Meenakshi Mehta, Mumbai</p>	<p>Young child working in garage, strenuous work, on the wheel.</p>	<p>Presently, 13 occupations and 57 processes being hazardous are banned for employment of children.</p>




Picture	Note	Management
<b>Child Labor: Child Working in Mirchi Field</b>		
	<p>Child working in mirchi godown, commonly seen in Gujarat where 31.8% children, every 3<sup>rd</sup> child working as opposed to 9% children from Maharashtra engaged in some or other kind of labor. Economically and industrially progressive, 1/18 children are paid workers.</p>	<p>Notification issued prohibiting employment of children as domestic servants and in dhabas, eateries, tea shops, etc. with effect from 2006. Offending employers are liable for criminal prosecution.</p>
<p><b>Figure 16.2.16:</b> Child working in mirchi field  <i>Photo Courtesy:</i> Meenakshi Mehta, Mumbai</p>		


### Child Labor: Boy Working in Tea Stall

	<p>There is ban from October 2006 of working/engaging in eateries, restaurants, tea stalls, <i>dhabas</i>, or as domestic servants.</p>	<p>Notification issued prohibiting employment of children as domestic servants and in dhabas, eateries, tea shops, etc. with effect from 2006. Offending employers are liable for criminal prosecution.</p>
<p><b>Figure 16.2.17:</b> Boy working on tea stall  <i>Photo Courtesy:</i> Meenakshi Mehta, Mumbai</p>		

### Child Labor: Boy Working in Tea Stall

	<p>There is ban from October 2006 of working/engaging in eateries, restaurants, tea stalls, dhabas, or as domestic servants.</p>	<p>Notification issued prohibiting employment of children as domestic servants and in dhabas, eateries, tea shops, etc. with effect from 2006. Offending employers are liable for criminal prosecution.</p>
<p><b>Figure 16.2.18:</b> Boy working on tea stall  <i>Photo Courtesy:</i> Meenakshi Mehta, Mumbai</p>		

Picture	Note	Management
<p><b>Child Labor: Boy Working in Tea Stall</b></p>  <p><b>Figure 16.2.19:</b> Boy working on tea stall <i>Photo Courtesy:</i> Meenakshi Mehta, Mumbai</p>	<p>There is ban from October 2006 of working/engaging in eateries, restaurants, tea stalls, dhabas, or as domestic servants.</p>	<p>Notification issued prohibiting employment of children as domestic servants and in dhabas, eateries, tea shops, etc. with effect from 2006. Offending employers are liable for criminal prosecution.</p>
<p><b>Child Labor: Child Working in Workshop/Factory</b></p>  <p><b>Figure 16.2.20:</b> Child working in workshop/factory <i>Photo Courtesy:</i> Meenakshi Mehta, Mumbai</p>	<p>Child working in workshop/factory.</p>	<p>Presently, 13 occupations and 57 processes being hazardous are banned for employment of children.</p>
<p><b>Child Labor: Young Boy Working at Construction Site</b></p>  <p><b>Figure 16.2.21:</b> Young boy working at construction site <i>Photo Courtesy:</i> Meenakshi Mehta, Mumbai</p>	<p>Child collecting sand for construction of building.</p>	<p>The NCLP scheme covers 250 districts at present and is likely to be expanded. Features of the scheme include bridging education, prevocational skills, stipend, mid-day meal, health care facilities.</p>

Picture	Note	Management
<b>Child Labor: Child Selling Earrings</b>		
 <p data-bbox="162 605 597 654"><b>Figure 16.2.22:</b> Child selling earrings <i>Photo Courtesy:</i> Meenakshi Mehta, Mumbai</p>	<p data-bbox="630 269 987 298">Child selling earrings in a train.</p>	<p data-bbox="1068 269 1481 490">The National Child Labor Project (NCLP) scheme covers 250 districts at present and is likely to be expanded. Features of the scheme include bridging education, prevocational skills, stipend, mid-day meal, health care facilities.</p>
<b>Child Labor: Children Cleaning Utensils</b>		
 <p data-bbox="162 1177 584 1226"><b>Figure 16.2.23:</b> Children washing utensils <i>Photo Courtesy:</i> Meenakshi Mehta, Mumbai</p>	<p data-bbox="630 793 987 850">Children washing utensils at the roadside dhaba/eatery.</p>	<p data-bbox="1068 793 1481 1013">The National Child Labor Project (NCLP) scheme covers 250 districts at present and is likely to be expanded. Features of the scheme include bridging education, prevocational skills, stipend, mid-day meal, health care facilities.</p>
<b>Child Labor: Child Laborers Caught by Police from Railway Station</b>		
 <p data-bbox="162 1810 584 1888"><b>Figures 16.2.24A and B:</b> Child laborers caught by police from railway station <i>Photo Courtesy:</i> Meenakshi Mehta, Mumbai</p>	<p data-bbox="630 1349 1036 1406">Children working on railway station caught by police.</p>	<p data-bbox="1068 1349 1481 1537">Notification issued prohibiting employment of children as domestic servants and in dhabas, eateries, tea shops etc with effect from 2006. Offending employers are liable for criminal prosecution.</p>

Picture	Note	Management
---------	------	------------

**Child Labor: Ban or No Ban**



**Figure 16.2.25:** Ban or no ban  
 Source: Times of India, 13th June 2007, Mumbai

India has 12.7 million (actually >18 million) children between 5 to 14 years working, highest in the world. They constitute 5% of the population and 3.15% of the work force. This is despite the official ban on children under 14 years for exploitative working/laboring.

Comprehensive welfare schemes for working children and rehabilitation in their families. Elimination of child labor without financial help/ improvement will not help either the working child or the family.



## Section 17

---

# Dermatology

*Section Editor*

Jayakar Thomas

*Photo Courtesy*

Jayakar Thomas, Parimalam Kumar

- 
- 17.1 Common Conditions
  - 17.2 Uncommon Conditions but not Rare
  - 17.3 Dermatologic Emergencies
  - 17.4 Syndromes



## SECTION OUTLINE

### 17.1 COMMON CONDITIONS 359

- ◆ Alopecia Areata 359
- ◆ Atopic Dermatitis 359
- ◆ Cellulitis 359
- ◆ Cutaneous Larva Migrans (CLM) 360
- ◆ Diaper Dermatitis 360
- ◆ Ecthyma 360
- ◆ Erysipelas 361
- ◆ Furuncle 361
- ◆ Herpes Zoster (HZ) 361
- ◆ Impetigo 362
- ◆ Insect Bite Allergy 362
- ◆ Kerion 362
- ◆ Molluscum Contagiosum 363
- ◆ Pediculosis Capitis 363
- ◆ Pityriasis Alba 363
- ◆ Scabies 364
- ◆ Seborrheic Dermatitis 364
- ◆ Tinea Capitis 364
- ◆ Urticaria 365
- ◆ Verruca Vulgaris 365

### 17.2 UNCOMMON CONDITIONS BUT NOT RARE 365

- ◆ Acanthosis Nigricans (AN) 365
- ◆ Acne Vulgaris 366
- ◆ Café au Lait Macule (CALM) 366
- ◆ Candidiasis 366
- ◆ Chronic Bullous Dermatitis of Childhood (CBDC) 367
- ◆ Collodion Baby 367
- ◆ Dermatomyositis 367
- ◆ Discoid Lupus Erythematosus (DLE) 368
- ◆ Epidermolysis Bullosa 368
- ◆ Erythema Nodosum (EN) 368

- ◆ Fixed Drug Eruption 369
- ◆ Hand, Foot and Mouth Disease 369
- ◆ Hansen's Disease 369
- ◆ Hemangioma 370
- ◆ Herpes Simplex 370
- ◆ Ichthyosis Vulgaris 370
- ◆ Infective Eczema 371
- ◆ Keratosis Pilaris 371
- ◆ Lichen Planus 371
- ◆ Lichen Striatus 372
- ◆ Miliaria Rubra 372
- ◆ Morphea 372
- ◆ Nevus Anemicus 373
- ◆ Pityriasis Rosea 373
- ◆ Pityriasis Versicolor 373
- ◆ Polymorphous Light Eruption (PLE) 374
- ◆ Psoriasis 374
- ◆ Systemic Lupus Erythematosus (SLE) 374
- ◆ Systemic Sclerosis 375
- ◆ Tinea Cruris 375
- ◆ Tuberculosis Verrucosa Cutis (TBVC) 375
- ◆ Tuberous Sclerosis 376
- ◆ Vitiligo 376
- ◆ Xeroderma Pigmentosum (XP) 376




### 17.3 DERMATOLOGIC EMERGENCIES 377




- ◆ Eczema Herpeticum (EH) 377
- ◆ Erythema Multiforme (EMF) 377
- ◆ Henoch Schönlein Purpura (HSP) 377
- ◆ Toxic Epidermal Necrolysis (TEN) 378


### 17.4 SYNDROMES 378




- ◆ Peutz-Jeghers Syndrome 378
- ◆ Sturge-Weber Syndrome 378




## 17.1 COMMON CONDITIONS




Picture	Note	Management
<b>Alopecia Areata</b>		
 <p><b>Figure 17.1.1:</b> Alopecia areata Photo Courtesy: Jayakar Thomas, Parimalam Kumar, Chennai</p>	<p>The smooth patches of non-scarring alopecia with depigmented hair indicating regrowth. The hair pull test was positive in the newer patch indicating the activity of the disease.</p>	<ul style="list-style-type: none"> <li>• Local irritant topical and intral- esional steroids (beware of skin atrophy).</li> <li>• Topical calcineurin inhibitors in atopy associated cases.</li> <li>• Topical minoxidil 2% sol.</li> <li>• Systemic immunomodulators, e.g. levamisole.</li> <li>• <i>Avoid systemic corticosteroids.</i></li> </ul>
<b>Atopic Dermatitis</b>		
 <p><b>Figure 17.1.2:</b> Atopic dermatitis Photo Courtesy: Jayakar Thomas, Parimalam Kumar, Chennai</p>	<p>Erythematous, edematous dry scaly patch over the cheeks. The infants skin is dry.</p>	<ul style="list-style-type: none"> <li>• Use of a mild surfactant based soap.</li> <li>• Liberal use of topical emol- lients and moisturizers applied frequently. Mild topical steroid (hydrocortisone) till inflamma- tion subsides followed by TCI.</li> <li>• Systemic antihistamines and anti- biotics when ever necessary.</li> </ul>
<b>Cellulitis</b>		
 <p><b>Figure 17.1.3:</b> Cellulitis Photo Courtesy: Jayakar Thomas, Parimalam Kumar, Chennai</p>	<p>Acute, subacute or chronic inflammation of loose connective tissue and deeper subcutaneous tissue of infective origin. Diagnosis is by erythema, warmth, swelling, pain, tenderness. Borders diffuse and ill-defined. Fever, lymphangitis, lymphadenitis may be present.</p>	<ul style="list-style-type: none"> <li>• Surgical incision and drainage.</li> <li>• Treat with systemic antibiotics.</li> <li>• Topical antibiotics of no use.</li> </ul>


Picture	Note	Management
<b>Cutaneous Larva Migrans (CLM)</b>		
 <p data-bbox="164 568 594 639"><b>Figure 17.1.4:</b> Cutaneous larva migrans (CLM) Photo Courtesy: Jayakar Thomas, Parimalam Kumar, Chennai</p>	<p data-bbox="626 273 1024 335">Local pruritus begins within hours after larval penetration.</p> <p data-bbox="626 349 1032 472">The serpiginous, thin, linear, raised, tunnel like erythematous migrating eruption over the sole in a boy who recently visited beach.</p> <p data-bbox="626 486 1032 547">Secondary eczematization/ infection are complications of CLM.</p>	<ul data-bbox="1073 273 1479 574" style="list-style-type: none"> <li>• Thiabendazole topical 10% alben-dazole 400 mgm for three days is safe and often effective. Liquid nitrogen may be applied to the progressing end of larval burrow.</li> <li>• Antihistamines, antibiotics along with topical steroid may be needed if there is eczematization.</li> <li>• <i>Avoid contact with wet soil.</i></li> </ul>
<b>Diaper Dermatitis</b>		
 <p data-bbox="164 1140 464 1212"><b>Figure 17.1.5:</b> Diaper dermatitis Photo Courtesy: Jayakar Thomas, Parimalam Kumar, Chennai</p>	<p data-bbox="626 764 1024 860">Erythematous patch with distinct border sparing the depths of the flexures.</p>	<ul data-bbox="1073 764 1479 1058" style="list-style-type: none"> <li>• Avoid occlusive napkins. Careful use of topical antibiotics, anti-fungals, and mild steroids, alone or in combination for a short course are useful. Always keep the skin dry.</li> <li>• <i>Strong steroid creams should not be applied to a baby's folds and bottom.</i></li> </ul>
<b>Echthyma</b>		
 <p data-bbox="164 1808 464 1880"><b>Figure 17.1.6:</b> Echthyma Photo Courtesy: Jayakar Thomas, Parimalam Kumar, Chennai</p>	<p data-bbox="626 1340 1040 1436">Deep-seated impetigo characterized by the formation of adherent crusts, beneath which ulceration occurs.</p> <p data-bbox="626 1451 1024 1641">Small bullae or pustules on an erythematous base. Surmounted by a hard crust of dried exudates. Removal of crusts shows ulcers. Heals with scarring. Common sites are buttocks, thighs and legs.</p>	<ul data-bbox="1073 1340 1471 1477" style="list-style-type: none"> <li>• Improve hygiene and nutrition.</li> <li>• Antibiotics as in impetigo. Soaks to remove crust. Treat primary disease, if any.</li> </ul>

Picture	Note	Management
<p><b>Erysipelas</b></p>  <p><b>Figure 17.1.7:</b> Erysipelas Photo Courtesy: Jayakar Thomas, Parimalam Kumar, Chennai</p>	<p>Bacterial infection of dermis and subcutaneous tissue. Erythema, swelling and pain. Surface may show blister. Edges well-defined.</p> <p>Fever, lymphangitis and lymphadenitis are invariably associated.</p>	<ul style="list-style-type: none"> <li>• No surgical intervention systemic antibiotics. Prevent recurrence by use of long acting antibiotics.</li> </ul>
<p><b>Furuncle</b></p>  <p><b>Figure 17.1.8:</b> Furuncle Photo Courtesy: Jayakar Thomas, Parimalam Kumar, Chennai</p>	<p>Bright-red, tender, indurated, round, follicular nodules. May evolve into an abscess. The angioedema secondary to the furuncle.</p> <p>Recurrent furunculosis is common in nasal carriers.</p>	<ul style="list-style-type: none"> <li>• Warm compresses and systemic antibiotics may arrest early furuncles. Cloxacillin, erythromycin, or cephalosporin 1 to 2 gm per day according to body weight and severity of the condition. Carrier state should be treated with application of mupirocin ointment over the internal nares, axillae and perianal area for 2 to 3 weeks.</li> </ul>
<p><b>Herpes Zoster (HZ)</b></p>  <p><b>Figure 17.1.9:</b> Herpes zoster (HZ) Photo Courtesy: Jayakar Thomas, Parimalam Kumar, Chennai</p>	<p>Strictly unilateral grouped erythematous, papules, rapidly becoming vesicular and then pustular in a continuous or interrupted band over one or more (immunocompromised) dermatome. The ipsilateral facial palsy and vesicles on the external ear—<i>Ramsay Hunt syndrome</i> - Positive Hutchinson's sign (vesicles on side and tip of nose indicates nasociliary branch involvement. Tzanck smear showed multinucleate giant cell.</p>	<ul style="list-style-type: none"> <li>• HZ in immunocompetent children is self-limiting. Topical antiseptic, antibiotic to treat secondary infection. <i>Do not use steroid combinations</i>. Systemic analgesics antibiotic when ever needed.</li> <li>• Immunocompetent: Oral acyclovir, 30 g/kg 5 times daily for 7 days, started within 48 hours of onset of the rash.</li> <li>• Immunosuppressed: IV acyclovir or recombinant interferon alpha-2a. Ophthalmologists opinion to take care of and prevent the ocular complications.</li> </ul>


Picture	Note	Management
<p><b>Impetigo</b></p>  <p><b>Figure 17.1.10:</b> Impetigo Photo Courtesy: Jayakar Thomas, Parimalam Kumar, Chennai</p>	<p>Scattered and discrete thin-walled vesicles erosions with golden-yellow crusts.</p> <p>Periorificial involvement should alert one to suspect development of staphylococcal scalded skin syndrome.</p>	<ul style="list-style-type: none"> <li>• Saline soaks to remove crusts. Sparkling cleanliness should be maintained. Topically mupirocin/sisomicin/fusidic acid/gentamycin is useful. Cream is preferred to an ointment and should be applied 3 to 4 times daily.</li> <li>• Cloxacillin 25 to 50 mg/kg/day in divided doses for 5 days/appropriate antibiotic to which the organism grown in culture is sensitive.</li> <li>• <i>Avoid systemic steroids.</i></li> </ul>
<p><b>Insect Bite Allergy</b></p>  <p><b>Figure 17.1.11:</b> Insect bite allergy Photo Courtesy: Jayakar Thomas, Parimalam Kumar, Chennai</p>	<p>The wheals surmounted by vesicle and excoriated papules over the face, limbs. Sparing of the chest (covered by clothing). These were itchy. Child was an atopic child whose mother gave history of wheezing. Secondary infection, eczematization are common complications.</p>	<p>Fully covered clothing should be advised.</p> <ul style="list-style-type: none"> <li>• Counseling, on use of mosquito repellents.</li> <li>• Prevention, by maintaining surrounding hygiene.</li> <li>• Reassurance, on its self-healing course.</li> </ul> <p>Topical antipruritics (crotamiton), mild steroids (hydrocortisone), TCI (tacrolimus). Oral antihistamines, antibiotics if needed.</p>
<p><b>Kerion</b></p>  <p><b>Figure 17.1.12:</b> Kerion Photo Courtesy: Jayakar Thomas, Parimalam Kumar, Chennai</p>	<p>Boggy, elevated, purulent, inflamed swelling with nodules and plaques that drain serous. Hairs do not break off but fall out and can be pulled easily without pain (i.e. loose). Kerion heals with scarring alopecia.</p>	<ul style="list-style-type: none"> <li>• Where possible, infected hair should be clipped away to reduce infectivity. Crusts removed using wet compresses. Kerion should never be incised.</li> <li>• Antifungal (ketoconazole) shampoo.</li> <li>• Oral griseofulvin (ultramicrosized):</li> <li>• <i>Dose:</i> 10 to 12.5 mg/kg/day (<i>Maximum:</i> 750 to 1000 mg/day) after fatty meals for better absorption for 1 to 2 months.</li> </ul>

Picture	Note	Management
<p><b>Molluscum Contagiosum</b></p>  <p><b>Figure 17.1.13:</b> Molluscum contagiosum Photo Courtesy: Jayakar Thomas, Parimalam Kumar, Chennai</p>	<p>Dome shaped, pearly white, discrete umbilicated papules.</p> <p>Perilesional eczema, secondary bacterial infection, and spread of infection by Koebner's phenomenon are common complications.</p>	<ul style="list-style-type: none"> <li>• Manual removal wherever possible.</li> <li>• <i>Topical:</i> Retinoic acid 0.025 to 0.1%, KOH 10%, imiquimod 1 to 5%, flexible collodion - 17% salicylic acid and 17% lactic acid are useful. Electrocautery, liquid nitrogen cryotherapy in older children. Ritonavir, cidofovir, zidovudine are found to be useful in children with HIV.</li> </ul>
<p><b>Pediculosis Capitis</b></p>  <p><b>Figure 17.1.14:</b> Pediculosis capitis Photo Courtesy: Jayakar Thomas, Parimalam Kumar, Chennai</p>	<p>Presence of lice and nits secondary infection, eczematization cervical lymphadenopathy, and matting of hair (Plica polonica) are common complications.</p>	<ul style="list-style-type: none"> <li>• Topical application of permethrin 1%, benzyl benzoate emulsion 25% followed by wash.</li> <li>• Oral cotrimoxazole, ivermectin 200 µ gm stat (in older children)</li> <li>• Systemic antihistamine and antibiotics if needed.</li> </ul>
<p><b>Pityriasis Alba</b></p>  <p><b>Figure 17.1.15:</b> Pityriasis alba Photo Courtesy: Jayakar Thomas, Parimalam Kumar, Chennai</p>	<p>The ill-defined, hypopigmented patch with mild scaling. The skin of the face is dry. Child is an atopic.</p>	<p>Condition is self resolving. Simple emollient cream is good enough. TCI or topical 1% hydrocortisone preparations may be helpful if inflammation is present.</p>

Picture	Note	Management
 <p><b>Figure 17.1.16:</b> Scabies Photo Courtesy: Jayakar Thomas, Parimalam Kumar, Chennai</p>	<p>Child with history of nocturnal pruritus and positive family history. Showing papules, papulopustules, excoriations, vesicles, over the interdigital space. Child also had impetiginised nodules over the genitals.</p> <p>Face is spared except in infants. Norwegian or crusted scabies occurs in immunocompromised children.</p>	<ul style="list-style-type: none"> <li>• Treat all contacts-</li> <li>• Permethrin 2.5 to 5%,</li> <li>• Sulfur precipitate 3 to 5%,</li> <li>• Gamma benzene hexachloride 1%,</li> <li>• Bezyl benzoate emulsion 25 to 33%,</li> <li>• Crotamiton 10%,</li> <li>• Oral antihistamines.</li> <li>• Antibiotics for secondary infection.</li> <li>• Oral ivermectin 3 to 6 mg—single dose.</li> </ul>
 <p><b>Figure 17.1.17:</b> Seborrheic dermatitis Photo Courtesy: Jayakar Thomas, Parimalam Kumar, Chennai</p>	<p>The greasy scales. There is secondary infection and excoriation due to scratching. The cervical lymphadenopathy. KOH mount for fungal element was negative.</p>	<ul style="list-style-type: none"> <li>• Removal of crusts with 2 to 3% salicylic acid in olive oil .</li> <li>• Shampoos containing selenium sulfide or zinc pyrithione, tar, ketoconazole. Topical steroid lotion in very severe forms, for short periods. Oral antihistamine and antibiotic required when there is secondary infection.</li> <li>• Recurrences should be treated depending on degree of severity.</li> </ul>
 <p><b>Figure 17.1.18:</b> Tinea capitis Photo Courtesy: Jayakar Thomas, Parimalam Kumar, Chennai</p>	<p>Well-defined, round or oval patches covered with small grayish-white scales. The scales tend to be more densely arranged around the openings of the hair follicles. The hairs in the affected area are broken off into small stumps.</p>	<ul style="list-style-type: none"> <li>• Where possible, infected hair should be clipped away to reduce the infectivity.</li> <li>• Antifungal (ketoconazole) shampoo can be used to wash scalp and hair.</li> <li>• Oral griseofulvin (ultramicro-sized):</li> <li>• Dose: 10 to 12.5 mg/kg /day after fatty meals for 1 to 2 months.</li> </ul>


Picture	Note	Management
 <p><b>Figure 17.1.19:</b> Urticaria Photo Courtesy: Jayakar Thomas, Parimalam Kumar, Chennai</p>	<p>The erythematous wheals which are usually transient. If painful and persist for more than 24 hours healing with pigmentation think of urticarial vasculitis.</p> <p>Test for hepatitis-associated antigen. Assess complement system, specific IgE antibodies by RAST. ESR is ↑ in persistent urticaria (necrotizing vasculitis), transient eosinophilia—seen in urticaria from reactions to foods and drugs.</p>	<ul style="list-style-type: none"> <li>• Eliminate etiologic factor antihistamines are the mainstay of treatment.</li> <li>• Prednisolone in angioedema-urticaria-eosinophilia syndrome, Danazol as long-term therapy for hereditary angioedema; whole plasma or C1 esterase inhibitor in the acute attack.</li> <li>• <i>Emergency treatment:</i> Subcutaneous adrenaline. Intravenous hydrocortisone should follow but not before adrenaline. Topical soothing lotions as calamine will help.</li> </ul>

### Verruca Vulgaris

 <p><b>Figure 17.1.20:</b> Verruca vulgaris Photo Courtesy: Jayakar Thomas, Parimalam Kumar, Chennai</p>	<p>Sharply demarcated, rough-surfaced, verrucous, firm, skin colored papules, plaque. The periungual location and one over the upper lip.</p>	<ul style="list-style-type: none"> <li>• Depends on lesion location, type, extent, duration and child's age, immunestatus. Topical keratolytics, 5 fluorouracil (1/5%), Electrocautery, radiofrequency, laser ablation, cryocautery are other modalities. Immunomodulators are used in extensive lesions and to prevent recurrence.</li> <li>• Advise against nail biting.</li> </ul>
--	---	---


## 17.2 UNCOMMON CONDITIONS BUT NOT RARE

### Acanthosis Nigricans (AN)


 <p><b>Figure 17.2.1:</b> Acanthosis nigricans (AN) Photo Courtesy: Jayakar Thomas, Parimalam Kumar, Chennai</p>	<p>The pigmented rough, velvety thickening of the skin over the axillae in an obese boy. AN may be inherited or may be associated with endocrine abnormality, obesity, drug intake, or internal malignancy.</p>	<ul style="list-style-type: none"> <li>• Acanthosis nigricans (AN) is directed towards the underlying cause. Advise on weight reduction, as in this boy. Correction of endocrinological abnormality, discontinuation of offending drugs or the therapy of underlying malignancy. Therapies for idiopathic AN include emollients, keratolytics.</li> </ul>
---	---	---




Picture	Note	Management
<p><b>Acne Vulgaris</b></p>  <p><b>Figure 17.2.2:</b> Acne vulgaris <i>Photo Courtesy:</i> Jayakar Thomas, Parimalam Kumar, Chennai</p>	<p>Papules, pustules over the face with pigmentation and scarring in an adolescent.</p>	<ul style="list-style-type: none"> <li>• Frequent cleansing of face.</li> <li>• Topical antibiotics (clindamycin, erythromycin).</li> <li>• Benzoyl peroxide gels (2%, 5%) retinoids 0.025%, adapalene.</li> <li>• Add systemic antibiotics and anti-inflammatory drugs in more severe forms. Dapsone 1 to 2 mg/kg/day in cystic acne.</li> <li>• Counseling is of paramount importance.</li> </ul>
<p><b>Café au Lait Macule (CALM)</b></p>  <p><b>Figure 17.2.3:</b> Café au lait macule <i>Photo Courtesy:</i> Jayakar Thomas, Parimalam Kumar, Chennai</p>	<p>The coffee brown colored asymptomatic patch with irregular border present since birth. There are more than 6 in number measuring more than 0.5 cm, suggestive of neurofibromatosis. The mother also had CALM macules more than 6 in number.</p>	<ul style="list-style-type: none"> <li>• No treatment is required. However, laser can be used in selected cases.</li> <li>• Parental and patient counseling is the mainstay in supporting the child and parent.</li> </ul>
<p><b>Candidiasis</b></p>  <p><b>Figure 17.2.4:</b> Candidiasis <i>Photo Courtesy:</i> Jayakar Thomas, Parimalam Kumar, Chennai</p>	<p>The painless curdy white precipitate over the tongue not removable. The para nasal skin may show erythematous scaly plaques of seborrheic dermatitis in HIV positive adolescents. Scraping examined with 10% KOH showed hyphae and spores.</p>	<ul style="list-style-type: none"> <li>• Systemic fluconazole is used as per body weight.</li> <li>• Local application of clotrimazole is also helpful.</li> <li>• Oral candidiasis in HIV-positive children indicates a decline in immunestatus.</li> </ul>

Picture	Note	Management
<p><b>Chronic Bullous Dermatitis of Childhood (CBDC)</b></p>  <p><b>Figure 17.2.5:</b> Chronic bullous dermatosis of childhood (CBDC) Photo Courtesy: Jayakar Thomas, Parimalam Kumar, Chennai</p>	<p>The classic lesions of CBDC are clear round or oval vesicles or bullae on normal, erythematous, or urticarial skin. The lesions are very itchy and show a characteristic 'string of jewel' appearance. Scratching leads to secondary infection and eczematization.</p>	<ul style="list-style-type: none"> <li>• Ruptured and infected lesions may be treated with topical mupirocin and sterile dressing changes twice daily. Oral dapsone is the drug of choice and the response of the condition to dapsone is almost confirmatory of the diagnosis. Oral steroids may be required in small doses for initial early resolution.</li> </ul>

### Collodion Baby




 <p><b>Figure 17.2.6:</b> Collodion baby Photo Courtesy: Jayakar Thomas, Parimalam Kumar, Chennai</p>	<p>The tight, shiny, moist membrane encasing the newborn. There was mild ectropion and eclabium. The outcome is unpredictable. Some of them turn normal, while some develop nonbullous ichthyosiform erythroderma. Still others have chronic and severe lamellar ichthyosis.</p>	<ul style="list-style-type: none"> <li>• The mainstay is hydration of the skin, correction of fluid and electrolyte balance and prevention of secondary bacterial and candidal infection in special intensive care with liberal application of emollients (liquid paraffin) and moisturisers (glycolic acid) under antibiotic cover.</li> <li>• Oral synthetic retinoids can be considered after 2 weeks.</li> <li>• Parental counseling is important.</li> </ul>
---	--	---




### Dermatomyositis




 <p><b>Figure 17.2.7:</b> Dermatomyositis Photo Courtesy: Jayakar Thomas, Parimalam Kumar, Chennai</p>	<p>Child with recurrent fever, fatigue and muscle weakness and pruritus. Child had proximal muscle weakness.</p> <p>The periorbital erythema, violaceous heliotrope and edema.</p> <p>Watch for calcinosis cutis which is a sign of poor prognosis.</p>	<ul style="list-style-type: none"> <li>• <i>Multidisciplinary</i> 3-day pulse-IV methyl prednisolone pulse, oral prednisolone 1 to 2 mg/kg tapered and stopped, substituted by immunosuppressive drug monitoring muscle enzymes and blood count. (MTX is suppressive, rather than a remittive).</li> <li>• IV immunoglobulin, infliximab are also useful. Calcinosis can be treated with diltiazem, aluminum hydroxide, probenecid, intralesional corticosteroid injections.</li> </ul>
---	---	---




Picture	Note	Management
<b>Discoid Lupus Erythematosus (DLE)</b>		
 <p><b>Figure 17.2.8:</b> Discoid lupus erythematosus (DLE) Photo Courtesy: Jayakar Thomas, Parimalam Kumar, Chennai</p>	<p>Scalp showing erythematous depigmented atrophic plaque with adherent scale. The ear shows shuster sign.</p> <p><i>Note:</i></p> <ul style="list-style-type: none"> <li>• The risk of SLE is higher in childhood DLE.</li> <li>• Disseminated DLE seems to have a poorer outcome.</li> <li>• Frequent systemic findings—arthralgia and Raynaud's.</li> <li>• IgM—The most common immune deposit.</li> </ul>	<ul style="list-style-type: none"> <li>• Avoid exposure to light. Wear broad brimmed hat. Topical sunscreen like Zinc, stearic acid. Sytemic <math>\beta</math> carotenes, chloroquine.</li> <li>• Regular follow-up.</li> </ul>
<b>Epidermolysis Bullosa</b>		
 <p><b>Figure 17.2.9:</b> Epidermolysis bullosa Photo Courtesy: Jayakar Thomas, Parimalam Kumar, Chennai</p>	<p>Bullae are present since birth and present on the sites of friction such as elbows, dorsa of hands and feet. There was no milia or scarring.</p>	<ul style="list-style-type: none"> <li>• Essentially supportive and avoidance of trauma. Sterile dressings and topical antibiotics (2% mupirocin) form the mainstay of therapy.</li> <li>• Cutaneous infections unresponsive to topical antibiotics will need systemic antibiotics.</li> </ul>
<b>Erythema Nodosum (EN)</b>		
 <p><b>Figure 17.2.10:</b> Erythema nodosum (EN) Photo Courtesy: Jayakar Thomas, Parimalam Kumar, Chennai</p>	<p>The deep seated erythematous nodules which were tender. The common causes of EN in children in our country are TB and streptococcal infections. Drugs like sulphonamides add to the causes. History and investigation in that order will help in the vast majority.</p>	<ul style="list-style-type: none"> <li>• Find the cause and treat. Rest, Pain killers/NSAID are the main stay of treatment.</li> </ul>

Picture	Note	Management
<p><b>Fixed Drug Eruption</b></p>  <p><b>Figure 17.2.11:</b> Fixed drug eruption <i>Photo Courtesy:</i> Jayakar Thomas, Parimalam Kumar, Chennai</p>	<p>Itchy, sharply demarcated round erythema, occurred within 6 hours after ingestion of septran. Followed by blistering.</p>	<ul style="list-style-type: none"> <li>• Identify and with hold the offending drug. The offending drug and allied group of drugs should be avoided in future.</li> <li>• Symptomatic treatment, with topical calamine lotion or topical steroids (Betamethasone).</li> <li>• Oral sedative antihistamines are indicated when itching is severe.</li> </ul>
<p><b>Hand, Foot and Mouth Disease</b></p>  <p><b>Figure 17.2.12:</b> Hand, foot and mouth disease <i>Photo Courtesy:</i> Jayakar Thomas, Parimalam Kumar, Chennai</p>	<p>This child was seen with low-grade fever for 2 days followed by itchy vesicles over the hand, legs, gluteal region. Child also had vesicles over the feet. The mouth was sore and the child was having difficulty in eating.</p>	<ul style="list-style-type: none"> <li>• Disease is self limiting. Parents need reassurance.</li> <li>• Plenty of oral fluids.</li> <li>• Antibiotics and antihistaminics are given if required.</li> <li>• No topical treatment is required.</li> </ul>
<p><b>Hansen's Disease</b></p>  <p><b>Figure 17.2.13:</b> Hansen's disease <i>Photo Courtesy:</i> Jayakar Thomas, Parimalam Kumar, Chennai</p>	<p>The hypopigmented patch having coppery hue with streaking border. The patch was anesthetic suggestive of borderline tuberculoid leprosy. There was no palpable cutaneous nerve twig nor peripheral nerve thickening.</p>	<ul style="list-style-type: none"> <li>• Rifampicin 450 mgm on empty stomach supervised once monthly and dapsone 50 mgm daily unsupervised for 6 months. Regular follow-up for 6 months is mandatory.</li> </ul>



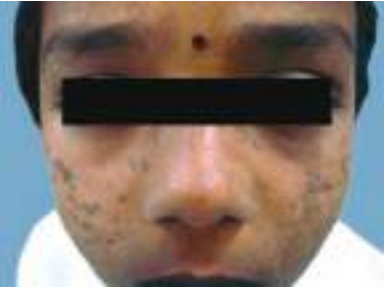
Picture	Note	Management
<p><b>Hemangioma</b></p>  <p><b>Figure 17.2.14:</b> Hemangioma Photo Courtesy: Jayakar Thomas, Parimalam Kumar, Chennai</p>	<ul style="list-style-type: none"> <li>• Most common tumor of neonate</li> <li>• Rapid growth but involutes completely with mild cosmetic disfigurement</li> <li>• Hemangiogenesis is the key term</li> <li>• No inter-connecting channels</li> <li>• Biopsy is the only required investigation</li> <li>• <i>Raised hemangiomas may cause:</i> <ol style="list-style-type: none"> <li>1. Platelet trapping</li> <li>2. Airway obstruction</li> <li>3. Visual obstruction</li> <li>4. Cardiac decompensation.</li> </ol> </li> </ul>	<p>In many instances, no treatment will be indicated. If treatment is needed, however, it may include:</p> <ul style="list-style-type: none"> <li>• <i>Cortisone:</i> Injected into the hemangioma or given.</li> <li>• <i>Pulsed dye laser therapy:</i> This therapy treats the superficial blood vessels best.</li> <li>• <i>Alpha interferon:</i> This therapy is limited to the most severe and potentially life-threatening hemangiomas.</li> <li>• Surgical removal</li> <li>• Oral propranolol under supervision has shown good results.</li> </ul>
<p><b>Herpes Simplex</b></p>  <p><b>Figure 17.2.15:</b> Herpes simplex Photo Courtesy: Jayakar Thomas, Parimalam Kumar, Chennai</p>	<p>The grouped monomorphous vesicles on erythematous base. Note there is no segmental distribution as in herpes zoster. Note secondary infection with cellulitis and labial edema in a HIV positive girl. The submandibular node was enlarged in both children.</p>	<ul style="list-style-type: none"> <li>• Less than 6 years of age, acyclovir 15 mg/kg/day in 5 divided doses. Adult dose, for children &gt; 40 kg weight.</li> <li>• Herpes simplex in immunocompromised child requires prophylactic dose till the child is on immunosuppressant drugs.</li> </ul>
<p><b>Ichthyosis Vulgaris</b></p>  <p><b>Figure 17.2.16:</b> Ichthyosis vulgaris Photo Courtesy: Jayakar Thomas, Parimalam Kumar, Chennai</p>	<p>Ichthyosis is seen as dry scaly skin. Ichthyosis vulgaris is an autosomal dominant genetic disorder first evident in early childhood. It is the most common form of ichthyosis, accounting for more than 95% of ichthyosis cases. It may be associated with atopy.</p>	<ul style="list-style-type: none"> <li>• The main approach to treatment includes hydration of the skin and application of an ointment to prevent evaporation. Moisturizers containing urea in lower strengths (10–20%) produce a more pliable stratum corneum by acting as a humectant. Topical retinoids (e.g. tretinoin 0.025%) may be beneficial. Ichthyosis vulgaris is not responsive to steroids, but a mild topical steroid may be useful for pruritus.</li> </ul>




Picture	Note	Management
 <p><b>Figure 17.2.17:</b> Infective eczema <i>Photo Courtesy:</i> Jayakar Thomas, Parimalam Kumar, Chennai</p>	<p>The erythematous scaly papules around the external auditory meatus with involvement of the cheek in a child having ASOM.</p>	<ul style="list-style-type: none"> <li>• Since the eczema is secondary to an infective discharge, correction of infection ASOM will heal the eczema.</li> </ul>
 <p><b>Figure 17.2.18:</b> Keratosis pilaris <i>Photo Courtesy:</i> Jayakar Thomas, Parimalam Kumar, Chennai</p>	<p>Horny follicular papules in an atopic child.</p>	<ul style="list-style-type: none"> <li>• Topical emollients, moisturisers, keratolytics like salicylic acid, essential fatty acid will help.</li> </ul>
 <p><b>Figure 17.2.19:</b> Lichen planus <i>Photo Courtesy:</i> Jayakar Thomas, Parimalam Kumar, Chennai</p>	<p>Itchy polygonal/oval, flat-topped, violaceous shiny papules showing Koebner's phenomenon. Oral mucosa showed white lacy plaque. Palms and soles and nail were normal.</p>	<ul style="list-style-type: none"> <li>• Reassurance of the patient and avoidance of stress and drugs causing lichenoid eruptions.</li> <li>• Topical fluorinated steroid creams and ointments, sedative antihistamines. Systemic steroids, e.g. prednisolone 15 to 20 mg/day in short courses, are indicated in severe cases, in acute generalized lichen planus, in ulcerative oral lesions, and when there is progressive nail destruction.</li> </ul>




Picture	Note	Management
 <p><b>Figure 17.2.20:</b> Lichen striatus Photo Courtesy: Jayakar Thomas, Parimalam Kumar, Chennai</p>	<p>Lichen striatus is a rare, benign, self-limited inflammatory linear dermatosis of unknown origin. It is clinically diagnosed on the basis of its appearance and characteristic developmental pattern of hypopigmented patches and papules following the lines of Blaschko. Many etiologic or predisposing factors are suggested, commonly the combination of genetic predisposition with environmental stimuli. Atopy may be a predisposing factor.</p>	<ul style="list-style-type: none"> <li>• Is a self-limited disorder and spontaneously regresses within 3 to 12 months. The patient and family should be reassured. Lichen striatus of the nail may indicate a protracted course. Nail involvement resolves spontaneously without deformity within 30 months.</li> </ul>
 <p><b>Figure 17.2.21:</b> Miliaria rubra Photo Courtesy: Jayakar Thomas, Parimalam Kumar, Chennai</p>	<p>Erythematous very itchy papules over face and other sweaty areas like trunk and axillae.</p> <p>Itching leads to secondary infection (Eccrine poritis, as shown on face) and eczematization.</p> <p>Lesions may heal with scaling.</p>	<ul style="list-style-type: none"> <li>• Usually self-resolving.</li> <li>• Itching is managed with bland lotions like calamine lotion and oral antihistamines.</li> <li>• Good aeration is the sheet anchor of all remedies.</li> </ul>
 <p><b>Figure 17.2.22:</b> Morphea Photo Courtesy: Jayakar Thomas, Parimalam Kumar, Chennai</p>	<p>The shiny atrophic skin over a sclerosed plaque in a segmental distribution. The skin was hard, bound down and difficult to be pinched.</p> <p>Histology showed hyalinised, hypertrophied and homogenised collagen replacing the subcutis with high uptake of sweat glands.</p>	<ul style="list-style-type: none"> <li>• Topical calcipotriene 0.005% twice a day.</li> <li>• Oral phenytoin sodium 4 to 8 mgm/kg body weight.</li> <li>• Steroids will stop progress during early inflammatory stage.</li> </ul>

Picture	Note	Management
<p><b>Nevus Anemicus</b></p>  <p><b>Figure 17.2.23:</b> Nevus anemicus Photo Courtesy: Jayakar Thomas, Parimalam Kumar, Chennai</p>	<p>Hypopigmented patch with intact sensation. Note the serrated margin.</p>	<ul style="list-style-type: none"> <li>• No treatment is required. Should be differentiated from vitiligo and re-assure the parents that it is a benign birth mark.</li> </ul>
<p><b>Pityriasis Rosea</b></p>  <p><b>Figure 17.2.24:</b> Pityriasis rosea Photo Courtesy: Jayakar Thomas, Parimalam Kumar, Chennai</p>	<p>The erythematous oval scaly herald patch and the smaller patches in Christmas tree pattern. The peripheral collarette of scales.</p>	<ul style="list-style-type: none"> <li>• It is a self limiting condition.</li> <li>• Avoid irritant woolen cloths, hot baths and soap. Topically—emollient, mild corticosteroid lotion will suffice.</li> <li>• Oral antihistamine when there is itching and if severe. UVB treatment by an expert may be required for the remnant post-inflammatory hypopigmentation.</li> </ul>
<p><b>Pityriasis Versicolor</b></p>  <p><b>Figure 17.2.25:</b> Pityriasis versicolor Photo Courtesy: Jayakar Thomas, Parimalam Kumar, Chennai</p>	<p>Pencil drawn, sharply marginated, scattered, discrete, round or oval macules, with fine branny scaling showing positive finger nail sign—The scales can be easily scraped off with the edge of a glass microscope slide.</p>	<ul style="list-style-type: none"> <li>• Short applications of selenium sulfide (2.5% to be washed off in 30 minutes) for 12 nights. Repeat every 2 weeks.</li> <li>• Sodium thiosulfate (25%) solution in water applied once or twice daily.</li> <li>• Miconazole 1 to 2% cream.</li> <li>• Topical ketoconazole (2%) either as shampoo or cream.</li> <li>• In older children with extensive lesion, oral ketoconazole 200 mg on empty stomach X 10 days.</li> </ul>




Picture	Note	Management
<b>Polymorphous Light Eruption (PLE)</b>		
 <p><b>Figure 17.2.26:</b> Polymorphous light eruption (PLE) <i>Photo Courtesy:</i> Jayakar Thomas, Parimalam Kumar, Chennai</p>	<p>Hypopigmented scaly patch and plaque with history of itching getting worse on exposure to sun light over the malar prominence and bridge of nose.</p>	<ul style="list-style-type: none"> <li>• Encourage child to wear hat while going out in sun/ playing.</li> <li>• Topical sunscreen should always be used and re-applied when sweating is more and wash away the cream. Mild steroid cream (hydrocortisone) or TCI will help.</li> <li>• Systemic antihistamines should be given when itching is severe.</li> </ul>
<b>Psoriasis</b>		
 <p><b>Figure 17.2.27:</b> Psoriasis <i>Photo Courtesy:</i> Jayakar Thomas, Parimalam Kumar, Chennai</p>	<p>The erythematous plaque with silvery scales over the extensor aspect of elbows and knees. Auspitz sign was positive. Finger nails showed pitting.</p>	<ul style="list-style-type: none"> <li>• Exclude focal sepsis in the ENT and dental area.</li> <li>• Mid potent topical steroid with anti-histamines. Followed by topical TCI. Child needs regular follow-up.</li> </ul>
<b>Systemic Lupus Erythematosus (SLE)</b>		
 <p><b>Figure 17.2.28:</b> Systemic lupus erythematosus (SLE) <i>Photo Courtesy:</i> Jayakar Thomas, Parimalam Kumar, Chennai</p>	<p>The malar rash as pigmented macules and patches in a child with recurrent fever. The palatal erosions were painless. Child was positive for ANA, Ds DNA, ↓C3 and C4, ↑ 24 hours urinary protein.</p>	<ul style="list-style-type: none"> <li>• Treatment depends on the severity of the disease and the organ system involvement after excluding other possibilities. The most important management tool in the treatment of systemic lupus erythematosus (SLE) is meticulous and frequent re-evaluation of patients.</li> <li>• Hydroxy chloroquine.</li> <li>• Dexamethasone monthly pulse.</li> <li>• The management of lupus nephritis depends on the grade after doing a renal biopsy.</li> </ul>

Picture	Note	Management
 <p><b>Figure 17.2.29:</b> Systemic sclerosis <i>Photo Courtesy:</i> Jayakar Thomas, Parimalam Kumar, Chennai</p>	<p>This girl gave history suggestive of Raynaud's phenomenon and dysphagia. The ironed out forehead and pinched nose. The hands showed tapering of fingers, depigmentation and finger tip ulcer and stellate scars. All children should be closely watched for development of gangrene. It is worth checking for ANA, ACA, APL antibody, the latter is more frequently positive in pediatric Raynaud's phenomenon.</p>	<ul style="list-style-type: none"> <li>• Goals of treatment of Raynaud's are to: Reduce the number and severity of attacks. Prevent tissue damage. Treat underlying disease. Avoid precipitating factors. Treatment of JSSc is aimed at arresting further progress of disease, organ damage. Drugs used are D penicillamine, nifedipine, ACE inhibitors, NSAIDs, omeprazole, careful usage of glucocorticosteroids and immunosuppressants. IV Ig and prostanoids are future promises.</li> </ul>
 <p><b>Figure 17.2.30:</b> Tinea cruris <i>Photo Courtesy:</i> Jayakar Thomas, Parimalam Kumar, Chennai</p>	<p>Very itchy, well demarcated plaques over the groins. The margins show scaling and are studded with fine papules. Pigmentation occurs due to scratching.</p>	<ul style="list-style-type: none"> <li>• Local hygiene, particularly in teen-aged boys regular change to clean and dry inner wear. Topical 1% clotrimazole/1% miconazole to be used for 4 to 6 weeks.</li> <li>• Add oral sedative antihistaminics (pheniramine maleate) to control the itch.</li> <li>• Oral griseofulvin (micronized) 250 mg daily with milk for 3 weeks may be required for stubborn cases of tinea cruris.</li> <li>• Never use topical steroids.</li> </ul>
 <p><b>Figure 17.2.31:</b> Tuberculosis verrucosa cutis (TBVC) <i>Photo Courtesy:</i> Jayakar Thomas, Parimalam Kumar, Chennai</p>	<p>Asymptomatic rough verrucous plaque with purulent discharge from the crypts on pressing. There was no regional lymphadenopathy, nor pulmonary TB.</p>	<ul style="list-style-type: none"> <li>• Management of cutaneous tuberculosis is the same as that of tuberculosis elsewhere in the body. The two months of four drugs and four months of two drugs regime holds good and gives successful results. Before starting on treatment, systemic involvement should be ruled out.</li> </ul>

Picture	Note	Management
<b>Tuberous Sclerosis</b>		
 <p data-bbox="164 615 597 690"><b>Figure 17.2.32:</b> Tuberous sclerosis <i>Photo Courtesy:</i> Jayakar Thomas, Parimalam Kumar, Chennai</p>	<p data-bbox="626 273 1037 431">Skin colored to brown papules, thick firm fibrous plaque and hypopigmented macule over the arm with history of seizures. The CT brain showed periventricular tuber.</p>	<ul data-bbox="1070 273 1479 369" style="list-style-type: none"> <li>• Electrocautery or laser ablation of the skin lesion and appropriate management of the seizures.</li> </ul>
<b>Vitiligo</b>		
 <p data-bbox="164 1208 597 1283"><b>Figure 17.2.33:</b> Vitiligo <i>Photo Courtesy:</i> Jayakar Thomas, Parimalam Kumar, Chennai</p>	<p data-bbox="626 866 1037 1218">Nonscarring depigmented patch. The leukotrichia (depigmented hair) which indicates stability of the disease and chances of repigmentation spontaneously or to medical management is much less. Search for thyroid disease, diabetes mellitus, pernicious anemia, Addison's disease, poly endocrinopathy syndrome with mucocutaneous candidiasis.</p>	<ul data-bbox="1070 866 1479 1167" style="list-style-type: none"> <li>• Topical steroid, TCI, PUVA may help only to some extent as the disease is stable.</li> <li>• Systemic PUVA should not be tried in children below 10 years of age.</li> <li>• Ruling out or correcting focus of sepsis in the ENT and dental area is useful.</li> </ul>
<b>Xeroderma Pigmentosum (XP)</b>		
 <p data-bbox="164 1800 597 1876"><b>Figure 17.2.34:</b> Xeroderma pigmentosum (XP) <i>Photo Courtesy:</i> Jayakar Thomas, Parimalam Kumar, Chennai</p>	<p data-bbox="626 1459 1037 1616">The xerotic skin, pigmented and hypopigmented atrophic macules in a child with XP. The larger growth is squamous cell carcinoma and the smaller one actinic keratosis.</p>	<ul data-bbox="1070 1459 1479 1749" style="list-style-type: none"> <li>• Complete protection from sun is the first line of treatment. Topical sunscreen like zinc cream and systemic beta carotene should be started as early as possible. Oral synthetic retinoids will prevent or at least postpone development of cutaneous malignancy. Surgical removal of malignant lesions.</li> </ul>


## 17.3 DERMATOLOGIC EMERGENCIES

Picture	Note	Management
 <p><b>Figure 17.3.1:</b> Eczema herpeticum (EH) Photo Courtesy: Jayakar Thomas, Parimalam Kumar, Chennai</p>	<p>Clusters of umbilicated vesiculopustules in a febrile sick atopic child preceded by fever, chills, and malaise. Few vesiculopustules progressed to develop painful hemorrhagic, crusted, punched-out erosions. Tzanck smear showed multinucleated giant cells.</p> <p>Seborrheic dermatitis, ichthyosis, Darier's disease are some of other conditions where EH occurs in children.</p>	<ul style="list-style-type: none"> <li>• EH is a medical emergency and involvement of eye is an ophthalmological emergency.</li> <li>• Acyclovir 25 mg/kg/day, divided into 5 equal doses for 5 to 10 days. Renal impairment can be prevented with adequate hydration.</li> <li>• <i>Topical steroids and calcineurin inhibitors, are contraindicated during a herpetic outbreak.</i></li> </ul>
 <p><b>Figure 17.3.2:</b> Erythema multiforme Photo Courtesy: Jayakar Thomas, Parimalam Kumar, Chennai</p>	<p>Sick child with mucosal erosion and crusting. Seen here are the classical target lesions are seen on the skin. The child also had fever and respiratory infection.</p>	<ul style="list-style-type: none"> <li>• Admission into ICU. Maintenance of fluid electrolyte balance and nutrition.</li> <li>• Early institution of systemic steroids. According to body weight in all cases of drug induced EMF and SJS. Acyclovir in recurrent EMF, if herpes simplex is suspected to be the cause.</li> <li>• Appropriate safe antibiotic and saline soaks for the crusting should be considered.</li> </ul>
 <p><b>Figure 17.3.3</b> Henoch Schönlein purpura (HSP) Photo Courtesy: Jayakar Thomas, Parimalam Kumar, Chennai</p>	<p>The purpuric macules flat and elevated (palpable) over the lower limbs.</p> <p>HSP may be a signature lesion of underlying vasculitis. Pain abdomen and arthralgia are frequent associations.</p>	<ul style="list-style-type: none"> <li>• It is largely supportive. Analgesics, NSAID or acetaminophen to reduce joint and soft tissue discomfort. Role of corticosteroid is controversial. It prevents development of nephritis in children with HSP, although its use in the treatment of intestinal and neurologic complications is gaining acceptance. If used, prednisolone 1 to 2 mg/kg/day PO for 7 days is recommended. Antihypertensives are indicated in renal involvement.</li> </ul>


Picture	Note	Management
<b>Toxic Epidermal Necrolysis (TEN)</b>		
	<p>Multiple hemorrhagic bullae with erosions in a sick child following intake of septran. There was cutaneous tenderness and Nikolsky sign was positive.</p> <p>The involvement of conjunctival and genital mucosa.</p>	<ul style="list-style-type: none"> <li>• Should be treated as a thermal burn patient. The role of corticosteroids is controversial but will arrest the progression of TEN if given in the first 24 to 48 hours. Maintain fluid and electrolyte balance with IV replacement of water, electrolytes, albumin and plasma with appropriate wound and eye care. Safe antibiotic and IV immuno- globulin only in selected children. Prevent aspiration pneumonitis, avoid re-exposure to offending drug.</li> </ul>
<p><b>Figure 17.3.4:</b> Toxic epidermal necrolysis (TEN) Photo Courtesy: Jayakar Thomas, Parimalam Kumar, Chennai</p>		

## 17.4 SYNDROMES

### Peutz-Jeghers Syndrome

	<p>Pigmented macule over the skin, lip, buccal mucosa palm and sole. Child had associated intestinal polyposis.</p>	<ul style="list-style-type: none"> <li>• Close observation and periodic evaluation is required.</li> </ul>
<p><b>Figure 17.4.1:</b> Peutz-Jeghers syndrome Photo Courtesy: Jayakar Thomas, Parimalam Kumar, Chennai</p>		

### Sturge-Weber Syndrome

	<p>Red, blanching plaque in child with history of seizures. Look for glaucoma, mental retardation and ipsilateral leptomeningeal angioma.</p>	<ul style="list-style-type: none"> <li>• Laser ablation will fade the lesion. The associated neuro-ocular problem should be attended to.</li> <li>• Reassure the parents that it is a benign birthmark.</li> </ul>
<p><b>Figure 17.4.2:</b> Sturge-Weber syndrome Photo Courtesy: Jayakar Thomas, Parimalam Kumar, Chennai</p>		

## Section 18

---

# Ophthalmology

***Section Editor***

TS Surendran, S Meenakshi, R Srikanth

***Photo Courtesy***

S Meenakshi, Sumita Agarkar, Kavitha Kalaivani N,  
R Srikanth, Akila Veeraputhiran, A Radhi Malar

- 18.1 Common Conditions
- 18.2 Uncommon Conditions but not Rare
- 18.3 Emergencies
- 18.4 Syndromes

## SECTION OUTLINE

### 18.1 COMMON CONDITIONS 381

- ◆ Accommodative Esotropia 381
- ◆ Amblyopia 381
- ◆ Astigmatism 381
- ◆ Congenital Cataract 382
- ◆ Congenital NLD Obstruction 382
- ◆ Hypermetropia 382
- ◆ Infantile Esotropia 383
- ◆ Intermittent Exotropia 383
- ◆ Myopia 384
- ◆ Optic Atrophy 384
- ◆ Pseudostrabismus 385
- ◆ Ptosis 385
- ◆ Vernal Keratoconjunctivitis (VKC) 386

### 18.2 UNCOMMON CONDITIONS BUT NOT RARE 386

- ◆ Brown Syndrome 386
- ◆ Cone Dystrophy 387
- ◆ Corneal Opacities in Newborn 387
- ◆ Duane's Retraction Syndrome—Type 1 388
- ◆ Infantile Glaucoma 388
- ◆ Juvenile Idiopathic Arthritis 389
- ◆ Orbital Rhabdomyosarcoma 389

- ◆ Periocular Capillary Hemangioma 389
- ◆ Retinitis Pigmentosa 390
- ◆ Retinoblastoma 390
- ◆ Retinopathy of Prematurity (ROP) 390
- ◆ Viral Conjunctivitis 391


### 18.3 EMERGENCIES 391

- ◆ Chemical Injuries 391
- ◆ Corneal Ulcer 392
- ◆ Ophthalmia Neonatorum 392
- ◆ Orbital Cellulitis 393
- ◆ Orbital Floor Fracture 393
- ◆ Penetrating Injury 394
- ◆ Preseptal Cellulitis 394


### 18.4 SYNDROMES 395

- ◆ Bardet-Biedl Syndrome 395
- ◆ Blepharophimosis Syndrome 395
- ◆ Crouzon Syndrome 396
- ◆ Down's Syndrome 396
- ◆ Goldenhar Syndrome 397
- ◆ Marfan's Syndrome 397
- ◆ Neurofibromatosis (NF) 398
- ◆ Sturge-Weber Syndrome 398


## 18.1 COMMON CONDITIONS

Picture	Note	Management
<p><b>Accommodative Esotropia</b></p>  <p><b>Figures 18.1.1A and B:</b> Accommodative esotropia Photo Courtesy: S Meenakshi, Sankara Nethralaya</p>	<ul style="list-style-type: none"> <li>• Esodeviation caused due to excessive convergence associated with accommodation.</li> <li>• Presents at 2<sup>nd</sup> year of life.</li> <li>• Classified into refractive and nonrefractive.</li> <li>• Associated with it is variable angle of esodeviation, uncorrected hypermetropia, high AC/A ratio and convergence excess type.</li> </ul>	<ul style="list-style-type: none"> <li>• Full cyclopegic correction.</li> <li>• Harness frames for small infants.</li> <li>• Convergence excess types: bifocals glasses.</li> <li>• <i>Miotics</i>: Phospholine iodide (0.06–0.12%).</li> <li>• <i>Prisms</i>: Small residual esodeviation.</li> <li>• <i>Surgery</i>: Nonaccommodative esotropia.</li> </ul>




## Amblyopia


 <p><b>Figure 18.1.2:</b> Amblyopia Photo Courtesy: S Meenakshi, Sankara Nethralaya</p>	<ul style="list-style-type: none"> <li>• Child with complaints of unilateral diminution of vision wearing a patch.</li> <li>• Amblyopia may be caused by anisometropia, strabismus or visual deprivation (cataract, corneal opacity).</li> </ul>	<ul style="list-style-type: none"> <li>• Before treating amblyopia it is important to correct the refractive error and treat the cause of visual deprivation.</li> <li>• Patching of the better seeing eye is the mainstay of amblyopia treatment.</li> <li>• Penalization (blurring the vision of the better seeing eye with atropine) is an alternative.</li> </ul>
--	--	---

## Astigmatism


 <p><b>Figure 18.1.3:</b> Astigmatism Photo Courtesy: S Meenakshi, Sankara Nethralaya</p>	<ul style="list-style-type: none"> <li>• Child with complaints of diminution of vision wearing cylindrical lenses.</li> <li>• Image is not sharply focussed on a point because either the cornea or the lens is not spherical and has greater power in one meridian.</li> <li>• Astigmatism may be regular or irregular (caused by corneal scar/ keratoconus).</li> </ul>	<ul style="list-style-type: none"> <li>• Regular astigmatism is managed with cylindrical lenses. Toric contact lenses are an alternative.</li> <li>• Irregular astigmatism is usually difficult to correct with glasses; contact lenses are a better alternative.</li> </ul>
--	---	--





Picture	Note	Management
<b>Congenital Cataract</b>		
 <p data-bbox="164 564 477 635"><b>Figure 18.1.4:</b> Congenital cataract Photo Courtesy: Sumita Agarkar, Sankara Nethralaya</p>	<ul data-bbox="630 277 1013 625" style="list-style-type: none"> <li>• Opacity of lens at birth.</li> <li>• <i>Etiology:</i> Idiopathic, AD, metabolic syndrome, maternal infections and PHPV.</li> <li>• Types of congenital cataract</li> <li>• Zonular, Polar, Nuclear and Posterior lenticonus.</li> <li>• Presents with leukocoria (white reflex in the pupil), nystagmus, strabismus, RAPD.</li> </ul>	<ul data-bbox="1073 277 1479 380" style="list-style-type: none"> <li>• Treat associated ocular condition.</li> <li>• Refer to a pediatrician to treat underlying systemic disorder.</li> </ul> <p data-bbox="1073 390 1170 416"><i>Surgical:</i></p> <ul data-bbox="1073 431 1463 527" style="list-style-type: none"> <li>• Below two years: lensectomy</li> <li>• Above two years: lens aspiration with IOL implantation.</li> </ul>
<b>Congenital NLD Obstruction</b>		
 <p data-bbox="164 1116 561 1187"><b>Figure 18.1.5:</b> Congenital NLD obstruction Photo Courtesy: Kavitha Kalaivani N, Sankara Nethralaya</p>	<ul data-bbox="630 805 1040 1275" style="list-style-type: none"> <li>• Obstruction of drainage below the lacrimal sac occurs in 5% newborns.</li> <li>• Membrane at lower end of nasolacrimal duct is the cause.</li> <li>• Symptoms become manifest by age 1 month in 80-90%, it presents with epiphora.</li> <li>• Sticky mucopurulent discharge accumulates on the eyelid.</li> <li>• Digital pressure over the lacrimal sac produces reflux cloudy fluid through the punctum.</li> </ul>	<p data-bbox="1073 805 1471 962"><i>Nonsurgical:</i> Digital massage of lacrimal sac is performed till one year of age. It uses hydrostatic pressure to opens the duct. Topical instillation of antibiotics.</p> <p data-bbox="1073 983 1463 1079"><i>Surgical:</i> Early probing: before age 12 months reduces the duration of symptoms.</p> <ul data-bbox="1073 1095 1446 1310" style="list-style-type: none"> <li>• Infraction of inferior turbinate.</li> <li>• Balloon catheter dilation.</li> <li>• <i>Intubation:</i> Silicone intubation recommended when simple probing fails or Dacryocystorhinostomy.</li> </ul>
<b>Hypermetropia</b>		
 <p data-bbox="164 1790 440 1862"><b>Figure 18.1.6:</b> Hypermetropia Photo Courtesy: S Meenakshi, Sankara Nethralaya</p>	<ul data-bbox="630 1453 1040 1800" style="list-style-type: none"> <li>• Child with complaints of diminution of vision wearing plus lenses.</li> <li>• Hypermetropia in children is usually well compensated because of the strong accommodative power of the lens.</li> <li>• Children with hypermetropia may present with an acquired convergent squint.</li> </ul>	<ul data-bbox="1073 1453 1479 1657" style="list-style-type: none"> <li>• Hypermetropia is managed by the use of convex lenses. Contact lenses and refractive laser surgery are alternative options.</li> <li>• Use of reading glasses may be required earlier in life.</li> </ul>


Picture	Note	Management
<p data-bbox="126 212 383 247"><b>Infantile Esotropia</b></p>  <p data-bbox="139 619 444 694"><b>Figure 18.1.7:</b> Infantile esotropia <i>Photo Courtesy:</i> S Meenakshi, Sankara Nethralaya</p>	<ul data-bbox="607 277 1008 791" style="list-style-type: none"> <li>• Large angle inward deviation of the eye.</li> <li>• Presents from birth to 6 months of age.</li> <li>• Mild limitation of abduction may be present.</li> <li>• The incidence of amblyopia is proportional to the duration of esotropia.</li> <li>• The classic triad of motor abnormalities associated are inferior oblique overaction, dissociated vertical deviation and latent nystagmus.</li> </ul>	<ul data-bbox="1050 277 1459 605" style="list-style-type: none"> <li>• The treatment for infantile esotropia is surgical.</li> <li>• Main indication of early surgery is to obtain binocular fusion.</li> <li>• Important to treat amblyopia and any refractive error before surgery.</li> <li>• <i>Procedure of choice:</i> Bilateral medial rectus recession.</li> </ul>

### Intermittent Exotropia


 <p data-bbox="139 1692 558 1768"><b>Figures 18.1.8A and B:</b> Intermittent exotropia <i>Photo Courtesy:</i> S Meenakshi, Sankara Nethralaya</p>	<ul data-bbox="607 1003 1008 1269" style="list-style-type: none"> <li>• Large exophoria that is intermittently controlled by fusional vergence.</li> <li>• May become a manifest divergent squint with passage of time.</li> <li>• Signs include blurred vision, asthenopia, visual fatigue, diplophotophobia.</li> </ul>	<ul data-bbox="1050 1003 1459 1310" style="list-style-type: none"> <li>• <i>Nonsurgical management:</i> Appropriate refractive correction. <i>Orthoptics treatment:</i> Anti-suppression exercises.</li> <li>• <i>Optical treatment:</i> Over corrected minus lens to stimulate convergence.</li> <li>• Prisms.</li> <li>• Strabismus surgery.</li> </ul>
--	---	---

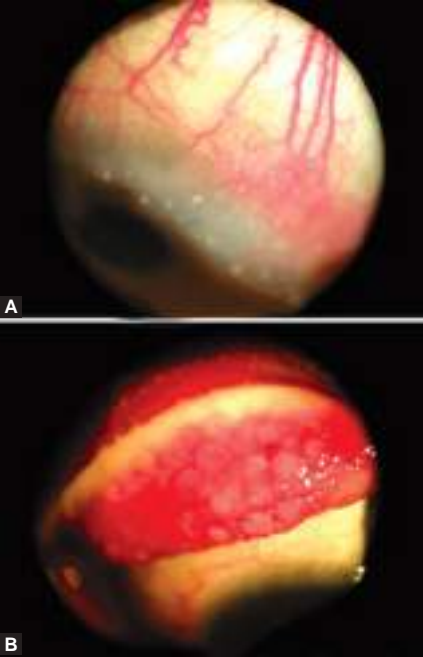
Picture	Note	Management
<p><b>Myopia</b></p>  <p><b>Figure 18.1.9:</b> Myopia <i>Photo Courtesy:</i> S Meenakshi, Sankara Nethralaya</p>	<ul style="list-style-type: none"> <li>• Child with complaints of diminution of vision for distance; wearing minus lenses.</li> <li>• Two forms of myopia are known—simple or physiological and the pathological type with degenerative changes of the retina.</li> </ul>	<ul style="list-style-type: none"> <li>• Simple myopia requires concave lenses. Contact lenses or laser refractive surgery are alternative options.</li> <li>• Patients with pathological myopia have higher risk of developing glaucoma, cataract, retinal tears and retinal detachment which needs surgical management.</li> </ul>

<p><b>Optic Atrophy</b></p>  <p><b>Figure 18.1.10:</b> Optic atrophy <i>Photo Courtesy:</i> S Meenakshi, Sankara Nethralaya</p>	<ul style="list-style-type: none"> <li>• Child was brought with the complaints of inability to recognize parents. Fundus examination revealed a pale optic disc.</li> <li>• Congenital optic atrophy is a type of hereditary optic neuropathy which may be inherited either as an autosomal dominant or recessive trait.</li> <li>• It is characterized by irreversible degeneration of retinal ganglion cells.</li> <li>• Other common causes of optic atrophy in children are glaucoma, stroke, papilledema, trauma, toxicity and tumors of brain.</li> </ul>	<ul style="list-style-type: none"> <li>• There is no known treatment as the degeneration of optic nerve fibers is irreversible.</li> <li>• Optic nerve fiber loss secondary to raised intracranial pressure may be arrested by identifying the cause and treating it.</li> <li>• Optic atrophy secondary to vascular, traumatic, degenerative and toxic cause have a poorer prognosis.</li> </ul>
---	---	---

Picture	Note	Management
<p><b>Pseudostrabismus</b></p>  <p><b>Figures 18.1.11A and B: Pseudostrabismus</b> Photo Courtesy: S Meenakshi, Sankara Nethralaya</p>	<ul style="list-style-type: none"> <li>• This is a group of conditions where eyes appear misaligned falsely. There can be a pseudo-esotropia or a pseudoexotropia.</li> <li>• Common causes of pseudoesotropia may be prominent epicanthal folds or a broad nasal bridge. Rarely abnormal macular position leading to a negative angle kappa can give rise to pseudoesotropia.</li> <li>• Pseudoexotropia is commonly seen as a sequelae of retinopathy of prematurity where macular dragging temporally leads to a positive angle kappa. This gives rise to an appearance of exotropia.</li> <li>• It is important to differentiate it from true strabismus which can potentially cause amblyopia and loss of binocularity. Pseudostrabismus can easily be diagnosed on doing cover test.</li> </ul>	<ul style="list-style-type: none"> <li>• Pseudostrabismus does not require any intervention. It needs periodic ophthalmic evaluation and counselling of parents.</li> </ul>


### Ptosis


 <p><b>Figure 18.1.12: Ptosis</b> Photo Courtesy: Bipasha Mukherjee, Sankara Nethralaya</p>	<ul style="list-style-type: none"> <li>• Drooping of lids.</li> <li>• <i>Etiology:</i> Defective function of levator or muller muscle complex.</li> <li>• Associated with amblyopia, strabismus, telecanthus and marcus gunn jaw winking phenomenon.</li> <li>• Commonly associated with blepharophimosis syndrome.</li> </ul>	<ul style="list-style-type: none"> <li>• <i>Nonsurgical:</i> Crutch glasses.</li> <li>• Occlusion therapy for amblyopia.</li> <li>• <i>Surgical:</i> Frontalis sling procedure or levator resection surgery.</li> </ul>
--	--	---

Picture	Note	Management
<p><b>Vernal Keratoconjunctivitis (VKC)</b></p>  <p>Figures 18.1.13A and B: Vernal Keratoconjunctivitis (VKC) Photo Courtesy: Bhaskar Srinivasan, Sankara Nethralaya</p>	<ul style="list-style-type: none"> <li>• VKC is a recurrent, bilateral, and self limiting inflammation of conjunctiva.</li> <li>• VKC is thought to be an allergic disorder which is IgE mediated.</li> <li>• <i>Symptoms:</i> Burning and itchy sensations associated symptoms include mild photophobia, lacrimation, stringy discharge and heaviness of eyelids.</li> </ul> <p><i>Types:</i></p> <ul style="list-style-type: none"> <li>• <i>Palpebral form:</i> Typical lesion is characterized by the presence of hard, flat topped papillae arranged in cobble stone or pavement stone fashion.</li> <li>• <i>Bulbar form:</i> It is characterized by dusky red gelatinous thickened accumulation of tissue around limbus and presence of discrete whitish raised dots (Tranta's spots).</li> <li>• <i>Mixed form:</i> Shows the features of both palpebral and bulbar types.</li> </ul>	<ul style="list-style-type: none"> <li>• <i>Local therapy:</i> Topical steroids are effective.</li> <li>• Mast cell stabilizers such as sodium cromoglycate (2%) drops 4 to 5 times a day are quite effective in controlling VKC, Azelastine, olopatadine and ketotifen eyedrops are also effective.</li> <li>• Topical antihistamines can be used. Acetyl cysteine (0.5%) used topically has mucolytic properties and is useful in the treatment of early plaque formation.</li> <li>• Topical cyclosporin is reserved for unresponsive cases.</li> <li>• Treat associated systemic allergies</li> <li>• <i>Treatment of large papillae:</i> Cryo application, surgical excision or supratarsal application of long acting steroids.</li> </ul>

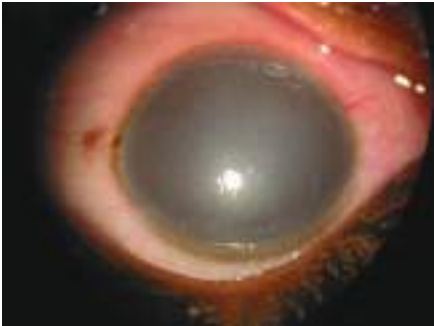
## 18.2 UNCOMMON CONDITIONS BUT NOT RARE


### Brown Syndrome

 <p>Figure 18.2.1: Brown syndrome Photo Courtesy: S Meenakshi, Sankara Nethralaya</p>	<ul style="list-style-type: none"> <li>• Child presented with complaints of inability to elevate the eye.</li> <li>• The patient's inability to elevate the eye is worse in adduction than in midline or abduction.</li> <li>• Positive forced duction test confirms the diagnosis.</li> </ul>	<ul style="list-style-type: none"> <li>• Spontaneous resolution is common.</li> <li>• Indications for surgery include anomalous head posture, hypotropia in primary gaze, diplopia, and downshoot in adduction.</li> <li>• Ipsilateral superior oblique weakening procedure is the surgery of choice.</li> </ul>
--	--	--



Picture	Note	Management
<p><b>Cone Dystrophy</b></p>  <p><b>Figure 18.2.2:</b> Cone dystrophy Photo Courtesy: S Meenakshi, Sankara Nethralaya</p>	<ul style="list-style-type: none"> <li>• Characterized by triad of symptoms namely slowly progressive vision loss, photophobia and poor color vision. Fundus examination may be essentially normal to typical bull's eye maculopathy.</li> <li>• Electro-retinogram shows abnormal cone function with near normal rod response.</li> <li>• Other features may be nystagmus and temporal optic nerve pallor.</li> <li>• Usually sporadic but if inherited usually autosomal dominant.</li> </ul>	<ul style="list-style-type: none"> <li>• There is no proven cure for this condition but palliative measures like tinted glasses and low vision aids help.</li> <li>• Genetic counseling is necessary.</li> </ul>




### Corneal Opacities in Newborn

 <p><b>Figure 18.2.3:</b> Corneal opacities in newborn Photo Courtesy: Bhaskar Srinivasan, Sankara Nethralaya</p>	<ul style="list-style-type: none"> <li>• Varied etiology ranging from infections to metabolic imbalance.</li> <li>• Common causes are, sclerocornea, corneal ulcers, trauma, increased intraocular pressure, metabolic diseases like mucopolysaccharidoses, endothelial dystrophies, Peters anomaly, etc.</li> </ul>	<ul style="list-style-type: none"> <li>• Need detailed evaluation under anesthesia to establish etiology.</li> <li>• Mandatory to check intraocular pressure. Management depends on size and location of opacity.</li> <li>• Large or central opacities need penetrating keratoplasty. Partial thickness opacities may do well with lamellar keratoplasty reducing risk of rejection.</li> <li>• Smaller opacities can be managed by dilating drops or optical iridectomy.</li> <li>• Followup is essential to as risk of rejection is high.</li> </ul>
---	--	---

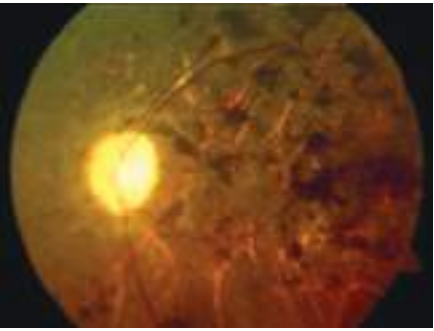
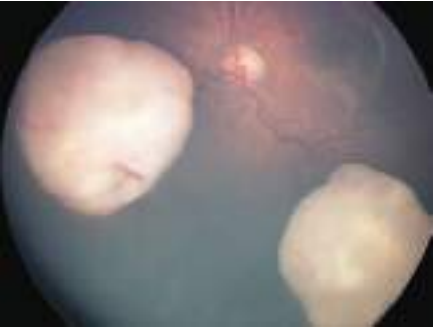

Picture	Note	Management
<p><b>Duane's Retraction Syndrome—Type 1</b></p>  <p><b>Figure 18.2.4:</b> Duane's retraction syndrome—Type 1 Photo Courtesy: S Meenakshi, Sankara Nethralaya</p>	<ul style="list-style-type: none"> <li>• Child was brought with complaints of inward deviation of eye.</li> <li>• Congenital disorder characterized by inability to abduct the affected eye with narrowing of palpebral fissure on adduction.</li> <li>• Caused by innervational misdirection of oculomotor nerve to lateral rectus muscle.</li> <li>• Usually sporadic, may be familial or associated with systemic disease (Goldenhar syndrome, Klippel Feil syndrome).</li> </ul>	<ul style="list-style-type: none"> <li>• Indications for surgery include strabismus in primary gaze, diplopia and significant anomalous head posture.</li> <li>• Bilateral medial rectus recession is the preferred procedure.</li> <li>• Vertical rectus muscle transposition is an alternative.</li> <li>• Y-splitting of lateral rectus muscle may be added in patients with upshoots/downshoots.</li> </ul>

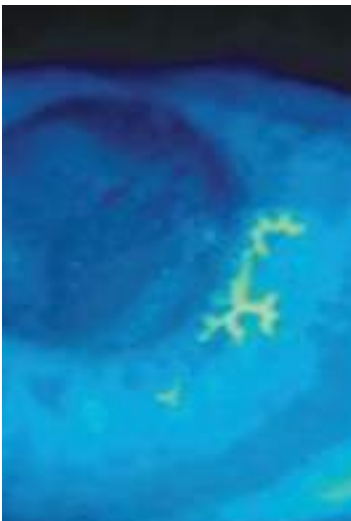
### Infantile Glaucoma

 <p><b>A</b></p>  <p><b>B</b></p>	<ul style="list-style-type: none"> <li>• Usually presents in infancy. There is predilection for male sex.</li> <li>• Typical triad of symptoms include epiphora, photophobia and congestion.</li> <li>• There may be increase in corneal diameter typically more than 12 mm.</li> <li>• Clouding of cornea occurs due to tears in Descemet's membrane called Haabs striae. This rupture leads to corneal edema and subsequent haze.</li> <li>• Intraocular pressure is increased. Optic nerve cupping may be seen.</li> <li>• It is often bilateral but unilateral or asymmetric presentation has been reported.</li> <li>• Most cases are sporadic but autosomal recessive inheritance is known.</li> </ul>	<ul style="list-style-type: none"> <li>• Management is almost always surgical.</li> <li>• Choice of procedure is trabeculectomy or goniotomy.</li> <li>• Severe cases may need trabeculectomy with antimetabolites.</li> <li>• Follow-up is essential despite good pressure control initially as these patients are prone for amblyopia and myopia.</li> <li>• May develop giant retinal tears later in life.</li> </ul>
<p><b>Figures 18.2.5A and B:</b> Infantile glaucoma Photo Courtesy: Sumita Agarkar, Sankara Nethralaya</p>		

Picture	Note	Management
<p><b>Juvenile Idiopathic Arthritis</b></p>  <p><b>Figure 18.2.6:</b> Juvenile idiopathic arthritis <i>Photo Courtesy:</i> R Sudharshan, Sankara Nethralaya</p>	<ul style="list-style-type: none"> <li>• Chronic, nongranulomatous, bilateral anterior uveitis.</li> <li>• In most patients arthritis occurs before the uveitis.</li> <li>• Uveitis is usually asymptomatic</li> <li>• May present with strabismus, cataract or band shaped keratopathy.</li> <li>• More commonly associated with pauciarticular and polyarticular onset.</li> </ul>	<ul style="list-style-type: none"> <li>• Screening of children at risk is most important.</li> <li>• Systemic onset = not required.</li> <li>• Polyarticular onset = every 9 months.</li> <li>• Polyarticular onset + ANA = every 6 months.</li> <li>• Pauciarticular onset = every 3 months.</li> <li>• Pauciarticular + ANA = every 2 months.</li> </ul>
<p><b>Orbital Rhabdomyosarcoma</b></p>  <p><b>Figure 18.2.7:</b> Orbital rhabdomyosarcoma <i>Photo Courtesy:</i> Bipasha Mukherjee, Sankara Nethralaya</p>	<ul style="list-style-type: none"> <li>• Most common primary orbital malignancy of childhood.</li> <li>• Presents with rapidly progressive unilateral proptosis.</li> <li>• First decade.</li> <li>• Superonasal or retrobulbar mass that may be palpable.</li> <li>• Skin may be injected and swollen later.</li> </ul>	<ul style="list-style-type: none"> <li>• MRI shows a poorly defined mass of homogenous density with adjacent bony destruction.</li> <li>• Metastatic work-up including chest X-ray, liver function tests, bone marrow biopsy, lumbar puncture and skeletal survey.</li> <li>• Incisional biopsy by ophthalmologist followed by referral to pediatric oncologist for radiotherapy and chemotherapy.</li> </ul>
<p><b>Periocular Capillary Hemangioma</b></p>  <p><b>Figure 18.2.8:</b> Periocular capillary hemangioma <i>Photo Courtesy:</i> Bipasha Mukherjee, Sankara Nethralaya</p>	<ul style="list-style-type: none"> <li>• A neonate was brought with complaints of a reddish mass lesion around the eye.</li> <li>• Capillary hemangioma is a primary, unilateral, benign hamartoma of tightly packed capillaries apparent at birth or within first 8 weeks of life, most of which regress within 7 years of age.</li> <li>• Most commonly seen in the superonasal quadrant of upper eyelid. Ptosis, astigmatism and amblyopia are the complications of the periocular type.</li> </ul>	<ul style="list-style-type: none"> <li>• Periodic ophthalmologic evaluation.</li> <li>• Superficial type can show spontaneous regression.</li> <li>• Intralesional injection of corticosteroid.</li> <li>• Vincristine.</li> <li>• Pulsed dye laser for superficial lesions.</li> <li>• Surgical resection for localized lesions.</li> <li>• Propranolol—promising results.</li> </ul>

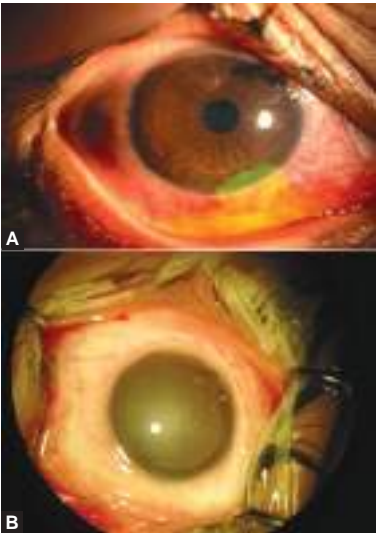



Picture	Note	Management
<p><b>Retinitis Pigmentosa</b></p>  <p><b>Figure 18.2.9:</b> Retinitis pigmentosa Photo Courtesy: Vikas Khetan, Sankara Nethralaya</p>	<ul style="list-style-type: none"> <li>• Presents with night blindness.</li> <li>• Usually in the third decade or may be sooner.</li> <li>• Retinal arteriolar narrowing may be the first sign.</li> <li>• Mild pigmentary changes and 'bone corpuscular' perivascular pigmentary changes.</li> <li>• Tessellated fundus, waxy disk pallor.</li> <li>• Macular atrophy and cystoid macular edema may ensue.</li> </ul>	<ul style="list-style-type: none"> <li>• ERG shows reduced scotopic and combined response and later photopic also.</li> <li>• Rule out associated systemic conditions such as Kearns-Sayre syndrome, Usher's, Refsum's disease.</li> <li>• Gene therapy is being done in some centers.</li> </ul>
<p><b>Retinoblastoma</b></p>  <p><b>Figure 18.2.10:</b> Retinoblastoma Photo Courtesy: Vikas Khetan, Sankara Nethralaya</p>	<ul style="list-style-type: none"> <li>• A 2 years old child was brought with complaints of white reflex seen in both eyes.</li> <li>• Fundus examination revealed extensive white masses and CT scan showed bilateral intraocular calcification.</li> <li>• Retinoblastoma is the most common primary intraocular malignancy in childhood.</li> <li>• Leukocoria and strabismus are the most common modes of presentation.</li> </ul>	<ul style="list-style-type: none"> <li>• Treatment depends on the stage and laterality of the tumor.</li> <li>• Systemic chemotherapy with vincristine, etoposide and cisplatin is used for chemoreduction of tumor.</li> <li>• Eyes with elevated IOP, rubeosis iridis, tumor in anterior chamber and evidence for optic nerve involvement need enucleation.</li> <li>• Brachytherapy, transpupillary thermotherapy and external beam radiotherapy are alternatives.</li> </ul>
<p><b>Retinopathy of Prematurity (ROP)</b></p>  <p><b>Figure 18.2.11:</b> Retinopathy of prematurity Photo Courtesy: Vikas Khetan, Sankara Nethralaya</p>	<ul style="list-style-type: none"> <li>• A 4 weeks old premature, low birth weight neonate was brought for screening eye examination.</li> <li>• Fundus examination revealed an extraretinal fibrovascular tissue with tortuous vessels.</li> <li>• Abnormal proliferation of blood vessels which may progress to fibrous tissue contraction and lead to retinal detachment.</li> <li>• Low birth weight, gestational age and oxygen therapy are major risk factors for development of ROP.</li> </ul>	<ul style="list-style-type: none"> <li>• Treatment should be carried out as soon as possible.</li> <li>• Laser therapy over avascular retina is the procedure of choice.</li> <li>• Cryotherapy is an alternative.</li> <li>• For advanced disease, lens sparing vitreous surgery and scleral buckling are performed.</li> <li>• Strabismus and amblyopia need to be managed during follow-up.</li> </ul>

Picture	Note	Management
 <p data-bbox="138 813 472 885"><b>Figure 18.2.12:</b> Viral conjunctivitis <i>Photo Courtesy:</i> Bhaskar Srinivasan, Sankara Nethralaya</p>	<ul data-bbox="602 275 1019 874" style="list-style-type: none"> <li>• Caused most commonly by adenovirus.</li> <li>• Some sero types are (types 18, 19 and 37) are associated with epidemic keratoconjunctivitis, pharyngoconjunctival fever (types 3 or 7) and follicular conjunctivitis (types 1 to 4, 7 and 10).</li> <li>• After an incubation period 5 to 12 days patient presents with symptoms of watery discharge, irritation, hyperemia of conjunctiva and follicle formation with preauricular adenopathy.</li> <li>• A diffuse superficial keratitis is followed by focal epithelial infiltrates and subepithelial opacities in the cornea.</li> </ul>	<ul data-bbox="1045 275 1406 445" style="list-style-type: none"> <li>• Cold compress.</li> <li>• Topical antibiotics to prevent secondary infection.</li> <li>• Mild topical steroid and tear substitute.</li> </ul>


## 18.3 EMERGENCIES

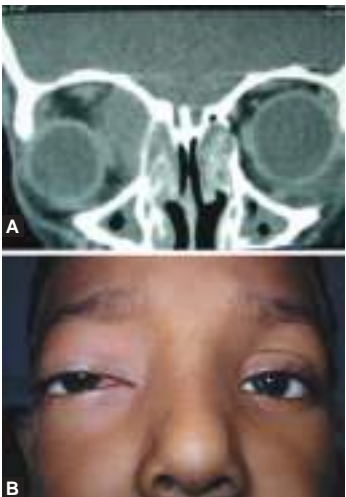
### Chemical Injuries

 <p data-bbox="138 1671 518 1743"><b>Figures 18.3.1A and B:</b> Chemical injuries <i>Photo Courtesy:</i> Bhaskar Srinivasan, Sankara Nethralaya</p>	<ul data-bbox="602 1122 1008 1698" style="list-style-type: none"> <li>• Accidental burns due to alkali such as ammonia, sodium hydroxide or lime, or acid that often occur with common substances in the household.</li> <li>• Alkali penetrates deeper causing more damage.</li> <li>• Necrosis of conjunctival and corneal epithelium is followed by loss of limbal stem cells.</li> <li>• Grading of severity is important for management.</li> <li>• Opacification and vascularization of the cornea follow.</li> <li>• Ocular surface wetting disorders, symblepharon and entropion are long-term problems.</li> </ul>	<ul data-bbox="1045 1122 1450 1520" style="list-style-type: none"> <li>• Emergency management consists of copious irrigation as soon as possible with normal saline for 15 to 30 minutes.</li> <li>• Double eversion of the eye lid to remove retained particulate matter.</li> <li>• Debridement of necrotic epithelium.</li> <li>• Medical treatment includes topical steroids, NSAIDs, ascorbic acid and citric acid.</li> </ul>
--	---	---

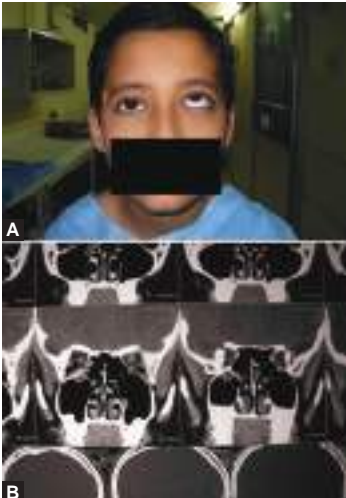
Picture	Note	Management
 <p data-bbox="164 621 493 697"><b>Figure 18.3.2:</b> Corneal ulcer Photo Courtesy: Bhaskar Srinivasan, Sankara Nethralaya</p>	<ul data-bbox="630 277 1036 829" style="list-style-type: none"> <li>• Corneal ulcer may be bacterial, fungal, viral or <i>acanthamoeba</i> in origin. <i>N. gonorrhoea</i>, <i>N. meningitides</i>, <i>C. diphtheriae</i>, <i>H. influenzae</i> can penetrate intact corneal epithelium. Symptoms are pain, redness, watering. Trauma with vegetable matter may cause fungal infections.</li> <li>• Bacterial and <i>acanthamoeba</i> keratitis may be associated with contact lens wear and poor hygiene and maintenance. Variable infiltrates and ulceration may be present.</li> <li>• Herpes viral keratitis may involve skin.</li> </ul>	<ul data-bbox="1073 277 1479 605" style="list-style-type: none"> <li>• Conjunctival swab and corneal scraping for microbiological diagnosis in the form of smear for staining and culture is mandatory to guide therapy.</li> <li>• Empiric therapy to be avoided as it can promote resistance.</li> <li>• Appropriate antimicrobial therapy along with cycloplegic agents to relieve pain.</li> </ul>

### Ophthalmia Neonatorum

 <p data-bbox="164 1537 545 1637"><b>Figures 18.3.3A and B:</b> Ophthalmia neonatorum Photo Courtesy: Namitha Bhuvaneshwari, RIO GOH, Chennai</p>	<ul data-bbox="630 1019 1036 1596" style="list-style-type: none"> <li>• Defined as conjunctivitis occurring in the neonatal period.</li> <li>• Etiology may be chemical or infective.</li> <li>• Common organisms implicated in neonatal conjunctivitis are Gonococcus, <i>Chlamydia</i>, herpes simplex and <i>Staphylococcus aureus</i>.</li> <li>• Presenting features are lid edema, conjunctival congestion and copious mucopurulent discharge.</li> <li>• Membrane formation can happen in severe cases.</li> <li>• Corneal perforation and scarring is common in gonococcal infection.</li> </ul>	<ul data-bbox="1073 1019 1479 1647" style="list-style-type: none"> <li>• Gram staining and conjunctival scraping is done. Geimsa stain is also recommended.</li> <li>• Cultures on blood and chocolate agar is done.</li> <li>• Choice of antibiotic depends on culture and sensitivity report. Broad spectrum antibiotic should be started till reports are available.</li> <li>• In gonococcal infection frequent irrigation of eye is recommended. Systemically ceftriaxone in divided dose of 30-50 mg/kg/day can be given IM or IV.</li> <li>• Chlamydial conjunctivitis is treated with oral erythromycin 50 mg/kg along with topical erythromycin drops.</li> </ul>
--	--	--


Picture	Note	Management
<p><b>Orbital Cellulitis</b></p>  <p><b>Figures 18.3.4A and B:</b> (A) CT scan; (B) Orbital cellulitis  <i>Photo Courtesy:</i> Bipasha Mukherjee, Sankara Nethralaya</p>	<ul style="list-style-type: none"> <li>• Presents with lid edema, pain, proptosis.</li> <li>• Pain on palpation and limitation of eye movements.</li> <li>• Loss of vision and afferent papillary defect may also be present.</li> <li>• Child is systemically ill with fever.</li> <li>• Usually a microbial infection due to penetrating lid trauma, sinus or dental infection.</li> </ul>	<ul style="list-style-type: none"> <li>• Hospitalization.</li> <li>• CT scan orbit to look for presence of subperiosteal abscess.</li> <li>• Monitoring of vision and pupils.</li> <li>• Parenteral antibiotics.</li> <li>• ENT consultation.</li> </ul>

### Orbital Floor Fracture


 <p><b>Figures 18.3.5A and B:</b> Orbital floor fracture  <i>Photo Courtesy:</i> Bipasha Mukherjee, Sankara Nethralaya</p>	<ul style="list-style-type: none"> <li>• Caused by a sudden increase in orbital pressure by a striking object like a tennis ball.</li> <li>• Ecchymoses, edema may be seen.</li> <li>• Diplopia due to entrapment of the inferior rectus or inferior oblique muscle in the fracture, or direct injury.</li> <li>• Enophthalmos is present in severe fractures.</li> <li>• Infraorbital anesthesia involving the lower lid, cheek, nose on that side and upper lip may be due to the fracture line through the infraorbital canal.</li> </ul>	<ul style="list-style-type: none"> <li>• CT scan of orbit with coronal sections to show the extent of the fracture.</li> <li>• Conservative line of management.</li> <li>• Antibiotics if maxillary sinus is involved.</li> <li>• Patient instructed not to blow nose.</li> <li>• Surgical intervention if persistent diplopia or cosmetically bothersome enophthalmos.</li> </ul>
---	--	--

Picture	Note	Management
<p><b>Penetrating Injury</b></p>  <p><b>Figure 18.3.6:</b> Penetrating injury Photo Courtesy: Bhaskar Srinivasan, Sankara Nethralaya</p>	<ul style="list-style-type: none"> <li>• May occur commonly as domestic accidents, in sports by flying objects or sharp objects such as knives.</li> <li>• Variable damage to ocular structures.</li> <li>• May range from simple corneal laceration to severe trauma causing intraocular damage, injury to the lens, iris prolapse, and retinal injury.</li> </ul>	<ul style="list-style-type: none"> <li>• No topical antibiotics in an open globe.</li> <li>• Apply a patch or an eye shield.</li> <li>• Surgical repair as early as possible.</li> <li>• Tetanus prophylaxis.</li> </ul>


### Preseptal Cellulitis


 <p><b>Figure 18.3.7:</b> Preseptal cellulitis Photo Courtesy: Bipasha Mukherjee, Sankara Nethralaya</p>	<ul style="list-style-type: none"> <li>• Bacterial infection of eyelid and adnexa.</li> <li>• Presents with erythema and swelling of lids. There is conjunctivitis and epiphora. Child may have fever.</li> <li>• Preauricular lymphadenopathy may be present.</li> <li>• Common causes are styes, chalazions, trauma, insect bites, etc.</li> <li>• It is important to differentiate from orbital cellulitis which is an ophthalmic emergency.</li> </ul>	<ul style="list-style-type: none"> <li>• Complete ophthalmic evaluation is essential to rule out orbital involvement. This includes vision, pupillary evaluation, ocular motility and fundus examination.</li> <li>• WBC counts and culture of discharge can be done. CT scan can be done if there are signs of orbital involvement like limited motility or RAPD.</li> <li>• Oral and topical antibiotics like Augmentin or third generation cephalosporins. Anti-inflammatory agents can be given orally.</li> <li>• Surgical drainage is required if there is involvement of orbit or signs of compression of optic nerve.</li> </ul>
--	--	--

## 18.4 SYNDROMES


Picture	Note	Management
<p><b>Bardet-Biedl Syndrome</b></p>  <p><b>Figure 18.4.1:</b> Bardet-Biedl syndrome <i>Photo Courtesy:</i> Soumitra, VRF</p>	<ul style="list-style-type: none"> <li>• Bardet-Biedl syndrome is an autosomal recessive condition that includes pigmentary retinopathy, polydactyly, renal dysfunction, short stature with truncal obesity, mental retardation and frequently hypogonadism.</li> <li>• Fundus picture may appear typical of retinitis pigmentosa or only a mild RPE granularity.</li> <li>• Symptoms are night vision problem, progressive acuity loss and field constrictions.</li> <li>• Renal disease may lead to premature death.</li> </ul>	<ul style="list-style-type: none"> <li>• No effective treatment is available for the ophthalmic condition. Treatment of refractive errors and use of low vision aids may play a role.</li> <li>• All patients need renal evaluation and some may even require a renal transplant during teenage years.</li> </ul>


## Blepharophimosis Syndrome

 <p><b>Figure 18.4.2:</b> Blepharophimosis syndrome <i>Photo Courtesy:</i> Bipasha Mukherjee, Sankara Nethralaya</p>	<ul style="list-style-type: none"> <li>• This is a syndrome characterized by complex lid malformation</li> <li>• The four components are ptosis, telecanthus, blepharophimosis and epicanthus inversus.</li> <li>• Other ocular associations are strabismus, refractive errors and amblyopia.</li> <li>• It is also associated with premature ovarian failure.</li> </ul>	<ul style="list-style-type: none"> <li>• Lid abnormalities need surgical intervention. Multiple surgeries may be required.</li> <li>• Canthoplasty is done to correct telecanthus.</li> <li>• This is followed by surgery for epicanthal fold, followed by ptosis surgery.</li> <li>• Refractive correction is given and amblyopia is managed by occlusion.</li> <li>• Hormone replacement therapy for premature ovarian failure.</li> </ul>
---	---	--


Picture	Note	Management
<p data-bbox="152 216 407 247"><b>Crouzon Syndrome</b></p>  <p data-bbox="164 625 472 701"><b>Figure 18.4.3:</b> Crouzon syndrome <i>Photo Courtesy:</i> S Meenakshi, Sankara Nethralaya</p>	<ul data-bbox="630 282 1036 874" style="list-style-type: none"> <li>• Crouzon syndrome is a craniosynostosis syndrome (premature closure of the coronal and saggital sutures) characterized by raised intracranial pressure, kinking and stretching of the optic nerves or narrowed optic canals all leading to progressive optic atrophy.</li> <li>• Other ocular features are shallow orbits, hyperteleorism, V pattern exotropia and hypertropia. Exposure keratopathy, aniridia, ectopia lentis, cataracts, glaucoma, etc. can also be associated.</li> <li>• Systemic feautres are midfacial hypoplasia, prognathism, etc.</li> </ul>	<ul data-bbox="1073 282 1482 513" style="list-style-type: none"> <li>• Treatment of ocular conditions aim at addressing possible individual features like strabismus, exposure keratopathy, etc.</li> <li>• Craniotomies have been tried to relieve optic nerve compression.</li> </ul>

### Down's Syndrome


 <p data-bbox="164 1383 464 1459"><b>Figure 18.4.4:</b> Down's syndrome <i>Photo Courtesy:</i> S Meenakshi, Sankara Nethralaya</p>	<ul data-bbox="630 1081 1036 1582" style="list-style-type: none"> <li>• Multi system involvement resulting from trisomy of chromosome 21. Eyes are involved in 60% of the affected individuals.</li> <li>• Ocular features are narrow and slanted palpebral fissures and floppy eyelids, blepharitis, nasolacrimal duct obstruction.</li> <li>• Anterior segment anomalies include Brushfield spots on iris, and cataract.</li> <li>• Refractive errors, strabismus and nystagmus are common features in patients with Down's syndrome.</li> </ul>	<ul data-bbox="1073 1081 1463 1312" style="list-style-type: none"> <li>• Blepharitis requires lid hygiene and topical antibiotic ointment. Refractive errors require corrective glasses.</li> <li>• Cataract and strabismus may need appropriate surgical intervention.</li> </ul>
---	--	--

Picture	Note	Management
<p><b>Goldenhar Syndrome</b></p>  <p><b>Figure 18.4.5:</b> Goldenhar syndrome Photo Courtesy: Bhaskar Srinivasan, Sankara Nethralaya</p>	<ul style="list-style-type: none"> <li>• Goldenhar syndrome comprises of complex of hemifacial microsomia, preauricular tags, auricular abnormalities, vertebral abnormalities and epibulbar dermoids.</li> <li>• Duane's syndrome, sixth or fourth nerve palsies can be associated.</li> <li>• CNS associations include hydrocephalus and Arnold-Chiari malformations.</li> <li>• It is nonhereditary with male preponderance.</li> </ul>	<ul style="list-style-type: none"> <li>• Ophthalmic conditions are treated conservatively or with appropriate surgeries depending on the clinical features.</li> <li>• Similarly, systemic defects need a multidisciplinary approach.</li> </ul>


### Marfan's Syndrome

 <p><b>Figures 18.4.6A and B:</b> Marfan's syndrome Photo Courtesy: S Meenakshi, Sankara Nethralaya</p>	<ul style="list-style-type: none"> <li>• Marfan's syndrome is a connective tissue syndrome associated with cardiomyopathy, tall stature with long extremities and kyphoscoliosis.</li> <li>• Typically there is bilateral lens subluxation superiorly and temporally. There can also be marked astigmatism, acquired myopia, cataract, etc. Patients carry a high-risk of retinal detachments.</li> <li>• Mode of inheritance is autosomal dominant.</li> </ul>	<ul style="list-style-type: none"> <li>• For subluxations, if asymptomatic can be observed. High myopia and moderate astigmatism can be corrected with glasses.</li> <li>• Surgical removal of lens is warranted for gross subluxations, uncorrectable high refractive errors, cataracts, total dislocations and for pupillary blocks.</li> <li>• Patients need referral to cardiologist for management and follow-up of associated cardiac anomalies.</li> </ul>
---	---	---



Picture	Note	Management
 <p data-bbox="164 880 557 956"><b>Figures 18.4.7A and B:</b> Neurofibromatosis <i>Photo Courtesy:</i> Bipasha Mukherjee, Sankara Nethralaya</p>	<ul style="list-style-type: none"> <li>• NF-1 is the most common phakomatosis with dominant inheritance.</li> <li>• Ocular signs are plexiform neurofibroma of lid and conjunctiva, glaucoma, pulsating proptosis, prominent corneal nerves, myelinated nerves, etc.</li> <li>• Optic nerve and chiasmal gliomas can occur.</li> <li>• NF-2 can have posterior subcapsular cataract.</li> </ul>	<ul style="list-style-type: none"> <li>• Treatment depends on the findings.</li> <li>• Genetic counseling is essential.</li> <li>• Psychological support and counselling for the individual and the family.</li> </ul>

### Sturge-Weber Syndrome

 <p data-bbox="164 1698 527 1774"><b>Figure 18.4.8:</b> Sturge-Weber syndrome <i>Photo Courtesy:</i> Sumita Agarkar, Sankara Nethralaya</p>	<ul style="list-style-type: none"> <li>• It is a rare neurocutaneous disorder presenting with angiomas in leptomeninges and skin, typically on face.</li> <li>• The most characteristic clinical feature is port wine stain on face.</li> <li>• Other systemic manifestations include seizures, developmental delay, hemiparesis and headache. Hemiparesis could be transient.</li> <li>• Ocular involvement is in form of glaucoma. Risk of glaucoma increases if port wine stain involves upper lid. Glaucoma is caused by increased episcleral venous pressure or due to angle abnormalities.</li> <li>• Choroidal hemangioma may cause a tomato ketchup appearance in the fundus.</li> </ul>	<ul style="list-style-type: none"> <li>• Children with Sturge-Weber syndrome need regular monitoring of intraocular pressure as glaucoma may develop later also.</li> <li>• Glaucoma may need multiple surgical interventions and often require antiglaucoma medication in addition.</li> <li>• Laser may be required to correct cosmetic blemish caused by port wine stain.</li> </ul>
--	--	---

## Section 19

---

# Otorhinolaryngology

*Section Editor*  
Divya Prabhat

*Photo Courtesy*  
Divya Prabhat

- 19.1 Common Conditions
- 19.2 Uncommon Conditions but not Rare
- 19.3 ENT Emergencies
- 19.4 Syndromes

## SECTION OUTLINE

### 19.1 COMMON CONDITIONS 401

- ◆ Acute Otitis Media (AOM) 401
- ◆ Adenoid—Facies 401
- ◆ Allergic Rhinitis—Comorbidities 401
- ◆ Allergic Rhinitis—Signs 402
- ◆ Antrochoanal Polyp 402
- ◆ BERA 402
- ◆ Ear Discharge 403
- ◆ Ear Syringing 403
- ◆ Ear Wax 403
- ◆ ENT Examination 404
- ◆ Ethmoidal Polyp 404
- ◆ Facial Palsy 404
- ◆ Furunculosis Ear 405
- ◆ Grommet 405
- ◆ Hearing Loss 405
- ◆ Impedance Audiometry 406
- ◆ Nasal Examination 406
- ◆ Otoscopy 406
- ◆ Pure Tone Audiometry 407
- ◆ Safe Ear—Central Perforation 407
- ◆ Tonsillectomy 407
- ◆ Unsafe Ear—Attic Perforation 408
- ◆ Vocal Nodules 408
- ◆ Voice—Conditions 408

### 19.2 UNCOMMON CONDITIONS BUT NOT RARE 409

- ◆ Branchial Fistula 409
- ◆ Choanal Atresia 409
- ◆ Cleft Palate 409
- ◆ Cochlear Implant 410
- ◆ Congenital Ear 410
- ◆ Cystic Hygroma 410

- ◆ Ear Tags 411
- ◆ Ethmoiditis—Orbital Cellulitis 411
- ◆ Hemangioma 411
- ◆ Juvenile Angiofibroma 412
- ◆ Laryngeal Papilloma 412
- ◆ Laryngomalacia 412
- ◆ Microcephaly 413
- ◆ Esophageal Foreign Body 413
- ◆ Otoacoustic Emissions (OAE) 413
- ◆ Pinna-hematoma 414
- ◆ Preauricular Sinus 414
- ◆ Thyroid 414
- ◆ Tongue Tie 415

### 19.3 ENT EMERGENCIES 415

- ◆ Ear Bleed 415
- ◆ Epistaxis 415
- ◆ Facial Trauma 416
- ◆ Foreign Body Bronchus (Collapse) 416
- ◆ Foreign Body Bronchus (Typical Case) 416
- ◆ Foreign Body Bronchus X-rays 417
- ◆ Foreign Body—Nose 417
- ◆ Fracture Nasal Bone 418
- ◆ Kommerell's Diverticulum 418
- ◆ Retropharyngeal Abscess 419
- ◆ Septal Hematoma 419
- ◆ Stridor—Signs 419
- ◆ Stridor—Sites 420
- ◆ Tracheotomy 420

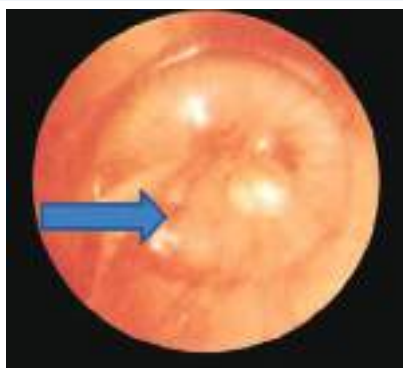### 19.4 SYNDROMES 420

- ◆ Down's Syndrome 420
- ◆ Obstructive Sleep Apnea Syndrome (OSAS) 421
- ◆ Vactral Syndrome 421

## 19.1 COMMON CONDITIONS

Picture	Note	Management
---------	------	------------

### Acute Otitis Media (AOM)

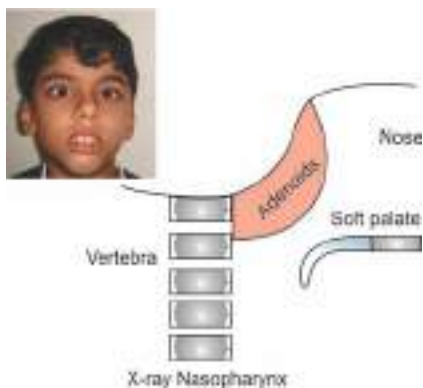


**Figure 19.1.1:** Acute otitis media  
Photo Courtesy: Divya Prabhat

The congested and bulging ear drum.

- One of the most common emergencies in a child.
- Enlarged Adenoids, vomitus and milk may block the tubes.
- Antibiotics for 7 to 10 days.
- Analgesics and antihistaminics for upper respiratory tract infection (URTI).
- For recurrent AOM do hearing tests.

### Adenoid—Facies

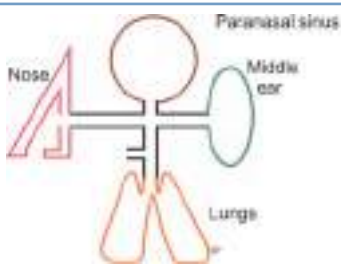


**Figure 19.1.2:** Adenoid—Facies  
Photo Courtesy: Divya Prabhat

Facies and compromised airway.

- Vacant expression.
- Open mouth.
- Pinched nostrils.
- Maxillary hypoplasia.
- Protuding incisors.
- High arched palate.
- Deafness.
- X-ray is diagnostic.
- Treatment with steroid nasal sprays and antihistaminics.


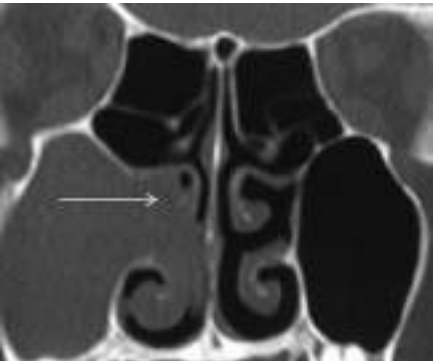
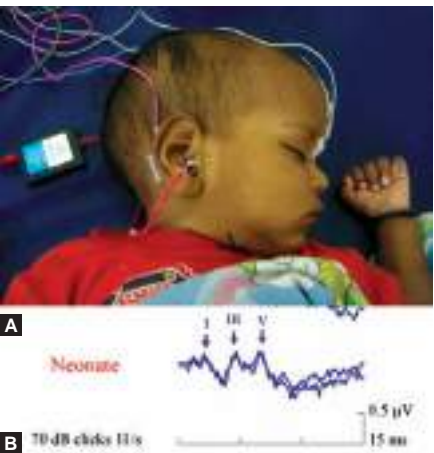
### Allergic Rhinitis—Comorbidities


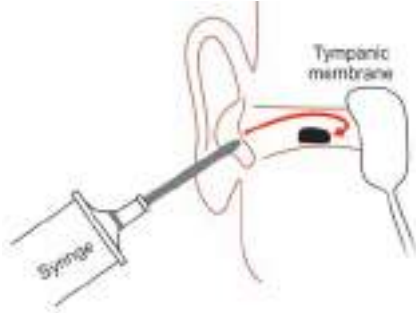




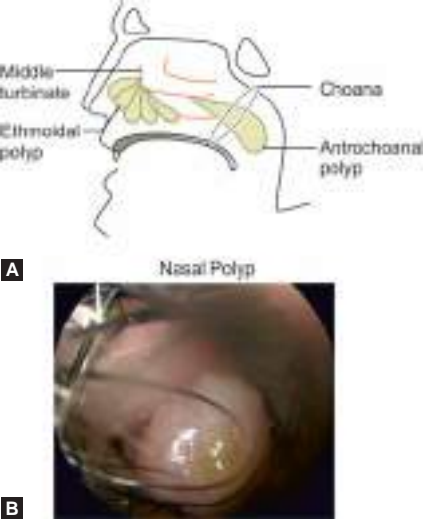

**Figure 19.1.3:** Allergic rhinitis—comorbidities  
Photo Courtesy: Divya Prabhat


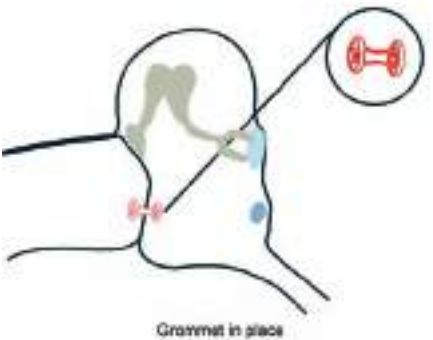
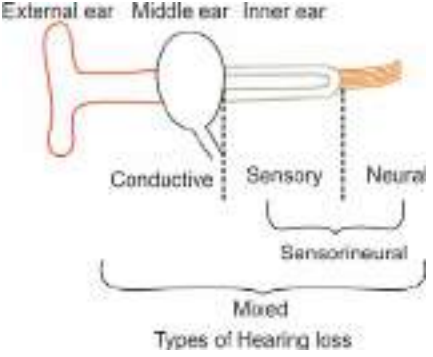
The mucosal continuity.

- Sinusitis.
- Adenoids.
- Otitis media.
- Snoring—Obstructive sleep apnea syndrome (OSAS).
- Pharyngitis.
- Asthma.


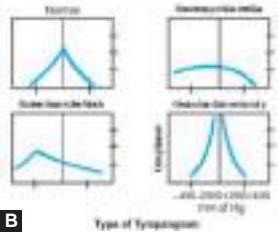



Picture	Note	Management
<b>Allergic Rhinitis—Signs</b>		
 <p data-bbox="164 645 513 697"><b>Figure 19.1.4:</b> Allergic rhinitis—Signs Photo Courtesy: Divya Prabhat</p>	<p data-bbox="626 273 841 304">The allergic salute.</p>	<ul data-bbox="1070 273 1442 461" style="list-style-type: none"> <li>• Allergic salute.</li> <li>• Nose wrinkling.</li> <li>• Darriers line.</li> <li>• Boggy mucosa and turbinates.</li> <li>• Clear transudate.</li> </ul>
<b>Antrochoanal Polyp</b>		
 <p data-bbox="164 1187 557 1238"><b>Figure 19.1.5:</b> Nasal polyp—Antrochoanal Photo Courtesy: Divya Prabhat</p>	<p data-bbox="626 809 976 870">Polyp from the maxillary sinus towards the nasopharynx.</p>	<ul data-bbox="1070 809 1474 1038" style="list-style-type: none"> <li>• Seen in the second decade.</li> <li>• Arises from the Maxillary sinus.</li> <li>• <i>Etiology:</i> Infection.</li> <li>• Grows towards the Nasopharynx.</li> <li>• Always a single/unilateral polyp.</li> <li>• Removal by sinus endoscopy.</li> </ul>
<b>BERA</b>		
 <p data-bbox="164 1835 444 1886"><b>Figure 19.1.6A and B:</b> BERA Photo Courtesy: Divya Prabhat</p>	<p data-bbox="626 1349 948 1410">The waves representing the complete auditory pathway.</p>	<ul data-bbox="1070 1349 1471 1661" style="list-style-type: none"> <li>• Done at any age—from newborn to adolescents.</li> <li>• Gives the pathway from auditory nerve to brainstem.</li> <li>• Objective test.</li> <li>• Must for high-risk babies, adoption candidates, postmeningitis, jaundice, MR-CP or delayed speech, etc.</li> </ul>



Picture	Note	Management
<p><b>Ear Discharge</b></p>  <p><b>Figure 19.1.7:</b> Ear discharge Photo Courtesy: Divya Prabhat</p>	<p>The canal edema with ear discharge.</p>	<p><i>Otitis media:</i></p> <ul style="list-style-type: none"> <li>• Ear canal is normal.</li> <li>• Movement of the pinna is painless.</li> <li>• Treat the URTI.</li> </ul> <p><i>Otitis externa:</i></p> <ul style="list-style-type: none"> <li>• Ear canal is inflamed.</li> <li>• Movement of the pinna is very painful.</li> <li>• Anti-inflammatory agents.</li> </ul>
<p><b>Ear Syringing</b></p>  <p><b>Figure 19.1.8:</b> Syringing the ear Photo Courtesy: Divya Prabhat</p>	<p>The direction of water during syringing.</p>	<ul style="list-style-type: none"> <li>• Done for wax, fungus or foreign body removal.</li> <li>• Child in the sitting position.</li> <li>• Firmly held before procedure.</li> <li>• Pull the pinna downwards and backwards.</li> <li>• Water at body temperature.</li> <li>• Direction of water upwards and backwards.</li> <li>• Dry the ear after the procedure.</li> </ul>
<p><b>Ear Wax</b></p>  <p><b>Figure 19.1.9:</b> Ear wax Photo Courtesy: Divya Prabhat</p>	<p>The ear canal filled with brownish material.</p>	<ul style="list-style-type: none"> <li>• The most common cause of ear-ache in children.</li> <li>• Ear buds would further impact the wax.</li> <li>• Wax dissolving drops advised for a week.</li> <li>• Syringing the ear may be done if wax does not clear up with drops.</li> </ul>

Picture	Note	Management
<b>ENT Examination</b>		
 <p data-bbox="164 605 475 656"><b>Figure 19.1.10:</b> ENT examination Photo Courtesy: Divya Prabhat</p>	<p data-bbox="630 275 1011 333">Position of holding a child during ENT examination.</p>	<ul data-bbox="1073 275 1468 486" style="list-style-type: none"> <li>• Child held firmly.</li> <li>• One hand on the head.</li> <li>• Other hand holding hands of the child.</li> <li>• Legs crossed and held between legs of the parent.</li> </ul>
<b>Ethmoidal Polyp</b>		
 <p data-bbox="164 1336 548 1387"><b>Figures 19.1.11A and B:</b> Ethmoidal polyp Photo Courtesy: Divya Prabhat</p>	<p data-bbox="630 803 932 827">Multiple polyps bilaterally.</p>	<ul data-bbox="1073 803 1479 1120" style="list-style-type: none"> <li>• Arises from ethmoid sinuses.</li> <li>• <i>Etiology:</i> Allergy.</li> <li>• <i>Always:</i> Bilateral and multiple.</li> <li>• Appear like bunch of grapes on rhinoscopy.</li> <li>• Antihistaminics, steroid nasal sprays and avoidance of allergens.</li> <li>• Endoscopic removal for resistant cases.</li> </ul>
<b>Facial Palsy</b>		
 <p data-bbox="164 1839 485 1890"><b>Figure 19.1.12:</b> Facial palsy—LMN Photo Courtesy: Divya Prabhat</p>	<p data-bbox="630 1533 1029 1557">Incomplete closure of the right eye.</p>	<ul data-bbox="1073 1533 1414 1759" style="list-style-type: none"> <li>• Congenital.</li> <li>• Birth trauma.</li> <li>• Bells palsy.</li> <li>• Acute otitis media.</li> <li>• Unsafe ear (cholesteatoma).</li> <li>• Head injury.</li> </ul> <p data-bbox="1073 1770 1338 1794">Treatment of the cause.</p>


Picture	Note	Management
 <p><b>Figure 19.1.13:</b> Furunculosis ear Photo Courtesy: Divya Prabhat</p>	<p>Completely obstructed ear canal, in a 3 month child due to ear buds usage.</p>	<ul style="list-style-type: none"> <li>• Movement of pinna is very painful.</li> <li>• Anti-inflammatory agents are enough.</li> <li>• Antibiotics only if the child is febrile.</li> <li>• Drainage only if abscess formation occurs.</li> </ul>
 <p><b>Figure 19.1.14:</b> Grommet Photo Courtesy: Divya Prabhat</p>	<p>Placement of the grommet on either side of the drum.</p>	<ul style="list-style-type: none"> <li>• Used for serous otitis media (SOM)—Common cause of delayed speech.</li> <li>• Grommet is a ventilation tube for the middle ear.</li> <li>• Extruded on its own by the migration of epithelium peripherally.</li> <li>• Improves hearing by drainage of fluid.</li> </ul>
 <p><b>Figure 19.1.15:</b> Hearing loss Photo Courtesy: Divya Prabhat</p>	<p>Types of hearing loss.</p>	<ul style="list-style-type: none"> <li>• <i>External ear</i>—Wax, fungus, otitis externa.</li> <li>• <i>Middle ear</i>—Otitis media, perforation of drum, glue ear (fluid), ossicular discontinuity.</li> <li>• <i>Inner ear</i>—Meningitis, ototoxicity, genetic disorders, etc. (sensory).</li> <li>• <i>Neural</i>—Auditory nerve to brain-stem.</li> </ul>




Picture	Note	Management
<b>Impedance Audiometry</b>		
 <p><b>A</b></p>  <p><b>B</b></p> <p>Figures 19.1.16A and B: Impedance audiometry Photo Courtesy: Divya Prabhat</p>	<p>Graphs in various conditions of the middle ear.</p>	<ul style="list-style-type: none"> <li>• Done from newborn and above.</li> <li>• Diagnose the exact middle ear pathology.</li> <li>• Most reliable test to detect fluid in the middle ear—serous otitis media (SOM).</li> <li>• Useful for delayed speech, eustachian dysfunction, LD, etc.</li> </ul>
<b>Nasal Examination</b>		
 <p><b>Figure 19.1.17:</b> Nasal examination Photo Courtesy: Divya Prabhat</p>	<p>Nasal septum is dislocated to the left anteriorly.</p>	<ul style="list-style-type: none"> <li>• In children avoid using instruments to examine.</li> <li>• Elevating tip of nose with thumb is enough.</li> <li>• Deviated septum is noted in the picture.</li> <li>• Little's area, Retrocollumellar vein (cause of epistaxis), polyps and turbinates can be seen.</li> </ul>
<b>Otoscopy</b>		
 <p><b>A</b></p>  <p><b>B</b></p> <p>Figures 19.1.18A and B: Otoscopy examination Photo Courtesy: Divya Prabhat</p>	<p>Method of holding the otoscope.</p>	<ul style="list-style-type: none"> <li>• Child held firmly by the parent/nurse.</li> <li>• Little finger of examiner (with scope) rests against child's face.</li> <li>• Ear speculum size chosen as per size of canal.</li> <li>• Pull the pinna downwards and backwards to visualize the ear drum.</li> </ul>




Picture	Note	Management
<p><b>Pure Tone Audiometry</b></p>  <p><b>A</b></p>  <p><b>B</b></p> <p><b>Figures 19.1.19A and B:</b> Pure tone audiometry  <i>Photo Courtesy:</i> Divya Prabhat</p>	<p>Child responds to the sounds.</p>	<ul style="list-style-type: none"> <li>• Tests reliable in children above 5 years.</li> <li>• Red color indicates the right and blue the left ear.</li> <li>• Continuous line is for air conduction and the intermittent for bone conduction.</li> <li>• Both lines are down seen in Sensorineural hearing loss.</li> <li>• Gap between the two lines seen in conductive hearing loss.</li> </ul>

### Safe Ear—Central Perforation




 <p><b>Figure 19.1.20:</b> Safe ear—Central perforation  <i>Photo Courtesy:</i> Divya Prabhat</p>	<p>Large central perforation involving all four quadrants.</p>	<ul style="list-style-type: none"> <li>• Profuse ear discharge.</li> <li>• Odorless discharge.</li> <li>• Associated with respiratory tract infections.</li> <li>• Conductive deafness.</li> <li>• Antibiotics and antihistamines advised.</li> <li>• Tympanoplasty for large perforations only.</li> </ul>
---	--	---




### Tonsillectomy




 <p><b>Figure 19.1.21:</b> Tonsillectomy  <i>Photo Courtesy:</i> Divya Prabhat</p>	<p>Enlarged tonsils with prominent crypts.</p>	<ul style="list-style-type: none"> <li>• Incidence has reduced significantly—indications being.</li> <li>• Recurrent URTI with high fever (5 to 7 in a year).</li> <li>• Failure to thrive.</li> <li>• Difficulty in breathing, speech and/or deglutition.</li> <li>• Ear discharge or bilateral neck nodes not clearing with antibiotics.</li> </ul>
---	--	---




Picture	Note	Management
<b>Unsafe Ear—Attic Perforation</b>		
 <p data-bbox="164 690 581 741"><b>Figure 19.1.22:</b> Unsafe ear—Attic perforation Photo Courtesy: Divya Prabhat</p>	<p data-bbox="630 271 1029 333">The Pars flaccid (attic) also shows a perforation.</p>	<ul data-bbox="1073 271 1484 533" style="list-style-type: none"> <li>• Scanty ear discharge.</li> <li>• Foul odor (due to cholesteatoma).</li> <li>• Not related to respiratory infections.</li> <li>• X-ray mastoid shows destruction.</li> <li>• Mixed hearing loss.</li> <li>• Mastoidectomy required.</li> </ul>
<b>Vocal Nodules</b>		
 <p data-bbox="164 1218 444 1269"><b>Figure 19.1.23:</b> Vocal nodules Photo Courtesy: Divya Prabhat</p>	<p data-bbox="630 880 1029 942">Nodule formation at junction of ant 1/3<sup>rd</sup> with post 2/3<sup>rd</sup>.</p>	<ul data-bbox="1073 880 1484 1203" style="list-style-type: none"> <li>• The most common cause of hoarseness of voice.</li> <li>• Following screaming, shouting, vocal abuse.</li> <li>• Look for focus of infection, e.g. tonsil or dental.</li> <li>• Voice rest and speech therapy is the treatment.</li> <li>• Rarely surgery is required.</li> </ul>
<b>Voice—Conditions</b>		
 <p data-bbox="164 1827 482 1878"><b>Figure 19.1.24:</b> Voice—conditions Photo Courtesy: Divya Prabhat</p>	<p data-bbox="630 1453 902 1483">The anterior glottic web.</p>	<ul data-bbox="1073 1453 1484 1907" style="list-style-type: none"> <li>• <i>Gruff</i>: Chronic laryngitis/hemangioma.</li> <li>• <i>Muffled</i>: Cyst/epiglottitis/retropharyngeal abscess.</li> <li>• <i>Breathy</i>: Granuloma/nodules/palsy.</li> <li>• <i>High pitched</i>: Web (Fig. 19.1.24)/endocrine disorders.</li> <li>• <i>With cough</i>: Allergic/GE reflux/lower respiratory tract infection (LRTI).</li> <li>• <i>Aphonia</i>: Foreign body/psychological.</li> </ul>


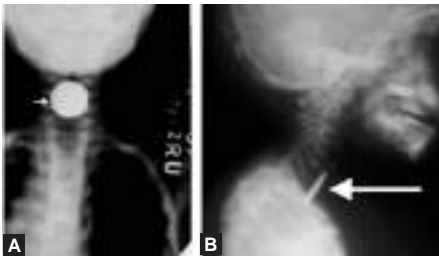

## 19.2 UNCOMMON CONDITIONS BUT NOT RARE

Picture	Note	Management
<p><b>Branchial Fistula</b></p>  <p><b>Figure 19.2.1:</b> Branchial fistula Photo Courtesy: Divya Prabhat</p>	<p>Surgical excision along the length of tract.</p>	<ul style="list-style-type: none"> <li>• Developmental arch abnormality.</li> <li>• Small opening on the neck anteriorly.</li> <li>• Recurrent pus discharge is treated with antibiotics.</li> <li>• Surgical excision of the complete tract for recurrent infections or abscess formations.</li> </ul>
<p><b>Choanal Atresia</b></p>  <p><b>Figure 19.2.2:</b> Choanal atresia Photo Courtesy: Divya Prabhat</p>	<p>Nasal tube introduced as stents after surgery.</p>	<ul style="list-style-type: none"> <li>• Fifty percent of bilateral choanal atresia associated with other congenital anomalies.</li> <li>• Air blast tested by misting on tongue depressor or introduce a rubber catheter in the nostrils.</li> <li>• Child breathless during feeds.</li> <li>• Bilateral repaired immediately and unilateral around 2 to 3 years.</li> </ul>
<p><b>Cleft Palate</b></p>  <p><b>Figure 19.2.3:</b> Cleft palate Photo Courtesy: Divya Prabhat</p>	<p>Wide gap in the palate.</p>	<ul style="list-style-type: none"> <li>• Birth defect, may also affect upper lip.</li> <li>• Problems of speech, feeding and otitis media.</li> <li>• Closure of the palate done around first year, so that speech develops normally.</li> <li>• Deafness also needs to be treated due to glue ear.</li> <li>• Orthodontic management.</li> </ul>




Picture	Note	Management
 <p><b>Figures 19.2.4A and B:</b> Cochlear implant Photo Courtesy: Divya Prabhat</p>	<p>External and internal parts of cochlear implant.</p>	<ul style="list-style-type: none"> <li>• For bilateral severe-profound sensorineural hearing loss not benefiting with a hearing aid.</li> <li>• Done from 10 months upwards.</li> <li>• As natural speech development is over by 5 years, so should be done before this age.</li> <li>• BERA, CT scan, MRI, neurology and psychological assessment a must.</li> <li>• X-ray shows postoperative implant with electrodes into the cochlea.</li> </ul>
 <p><b>Figure 19.2.5:</b> Congenital ear Photo Courtesy: Divya Prabhat</p>	<p>Malformed pinna.</p>	<ul style="list-style-type: none"> <li>• Pinna not completely formed.</li> <li>• CT scan is done to detect whether the cochlea is developed.</li> <li>• BERA for the auditory pathway.</li> <li>• Look for other congenital anomalies.</li> <li>• Priority is to correct deafness and not cosmetic correction of pinna, which can wait.</li> </ul>
 <p><b>Figure 19.2.6:</b> Cystic hygroma Photo Courtesy: Divya Prabhat</p>	<p>Neck bulge laterally.</p>	<ul style="list-style-type: none"> <li>• The cyst may not be recognized at birth.</li> <li>• Typically grows as the child does.</li> <li>• Discovered as a neck mass in infants after respiratory infections.</li> <li>• Ultrasound/CT scan.</li> <li>• Treatment is surgical removal of abnormal tissue, as possible.</li> <li>• Local injection of sclerosing agents can be attempted.</li> </ul>


Picture	Note	Management
<p><b>Ear Tags</b></p>  <p><b>Figure 19.2.7:</b> Ear tags Photo Courtesy: Divya Prabhat</p>	<p>The preauricular area.</p>	<ul style="list-style-type: none"> <li>• Pedunculated skin that arise near the tragus.</li> <li>• They may have cartilagenous components but do not communicate with ear canal or middle ear.</li> <li>• Can be left alone.</li> <li>• Removal only for cosmetic reasons.</li> </ul>
<p><b>Ethmoiditis—Orbital Cellulitis</b></p>  <p><b>Figures 19.2.8A and B:</b> Ethmoiditis—Orbital cellulitis Photo Courtesy: Divya Prabhat</p>	<p>Reduction of cellulitis following nasal endoscopy.</p>	<ul style="list-style-type: none"> <li>• From unresolved ethmoidal sinusitis.</li> <li>• Via lamina papyracea.</li> <li>• Injectable antibiotics and nasal decongestants.</li> <li>• Drainage of abscess by nasal endoscopic sinus surgery.</li> </ul>
<p><b>Hemangioma</b></p>  <p><b>Figures 19.2.9A and B:</b> Hemangioma Photo Courtesy: Divya Prabhat</p>	<p>Hemangioma at the tip of the nose and floor of mouth.</p>	<ul style="list-style-type: none"> <li>• Congenital condition.</li> <li>• Look for other areas involved.</li> <li>• May resolve with time, so wait and watch policy.</li> <li>• Local injections of bleomycin at weekly intervals is the treatment of choice.</li> </ul>

Picture	Note	Management
<p><b>Juvenile Angiofibroma</b></p>  <p><b>Figure 19.2.10:</b> Juvenile angiofibroma Photo Courtesy: Divya Prabhat</p>	<p>Tumor enhancement seen.</p>	<ul style="list-style-type: none"> <li>• Seen exclusively in adolescent boys.</li> <li>• Nasal block and epistaxis.</li> <li>• Origin in nasopharynx.</li> <li>• CT-Angio scan diagnostic.</li> <li>• Nonmalignant and highly vascular.</li> <li>• Surgical removal is the treatment.</li> </ul>
<p><b>Laryngeal Papilloma</b></p>  <p><b>Figure 19.2.11:</b> Laryngeal papilloma Photo Courtesy: Divya Prabhat</p>	<p>Laryngeal inlet blocked by papillomatous growth.</p>	<ul style="list-style-type: none"> <li>• Hoarseness or respiratory distress.</li> <li>• Resolves by puberty.</li> <li>• Direct laryngoscopy done with biopsy.</li> <li>• Never undergoes malignancy.</li> <li>• Laser assisted removal of papilloma done.</li> <li>• Tracheostomy may be required for extensive papillomatosis.</li> </ul>
<p><b>Laryngomalacia</b></p>  <p><b>Figure 19.2.12:</b> Laryngomalacia (Congenital laryngeal stridor) Photo Courtesy: Divya Prabhat</p>	<p>Folded epiglottis and narrow inlet.</p>	<ul style="list-style-type: none"> <li>• Crowing noise.</li> <li>• Folded epiglottis.</li> <li>• Normal sized tube.</li> <li>• Not all children affected.</li> <li>• Failure to thrive.</li> <li>• Disappears by 2 to 5 years.</li> <li>• Surgical treatment usually not required.</li> </ul>

Picture	Note	Management
<p><b>Microcephaly</b></p>  <p><b>Figure 19.2.13:</b> Microcephaly Photo Courtesy: Divya Prabhat</p>	<p>Retrognathia-jaw retracted.</p>	<ul style="list-style-type: none"> <li>• Delayed milestones.</li> <li>• Associated anomalies.</li> <li>• Stridor due to central and local causes.</li> <li>• BERA for detection of a hearing deficit.</li> <li>• Hearing rehabilitation for natural speech development.</li> </ul>
<p><b>Esophageal Foreign Body</b></p>  <p><b>Figures 19.2.14A and B:</b> Esophageal foreign body Photo Courtesy: Divya Prabhat</p>	<p>Coin in the AP and lateral view.</p>	<ul style="list-style-type: none"> <li>• Coin is the most common foreign body.</li> <li>• Site of impaction is usually at cricopharynx.</li> <li>• Round foreign bodies, lower down the cricopharynx generally pass down.</li> <li>• Always ask for AP and Lateral view X-rays.</li> <li>• Esophagoscopy for stationary foreign bodies.</li> </ul>
<p><b>Otoacoustic Emissions (OAE)</b></p>  <p><b>Figure 19.2.15:</b> Otoacoustic emissions (OAE) Photo Courtesy: Divya Prabhat</p>	<p>Ear plug delivers click sound.</p>	<ul style="list-style-type: none"> <li>• Tests the function of the outer hair cells of the cochlea.</li> <li>• Must be done as a screening hearing test for all high-risk babies.</li> <li>• Apgar score &lt;5, on ventilator for &gt;4 days, meningitis, blood transfusion, neonatal jaundice, adoption, etc.</li> </ul>




Picture	Note	Management
<p><b>Pinna-hematoma</b></p>  <p><b>Figure 19.2.16:</b> Pinna-hematoma <i>Photo Courtesy:</i> Divya Prabhat</p>	<p>Collection of blood causing swollen pinna.</p>	<ul style="list-style-type: none"> <li>• Following injury—boxing, slap or twisting ear.</li> <li>• Anti-inflammatory drug are usually enough.</li> <li>• Drainage must be done in aseptic conditions.</li> <li>• Tight dressings to prevent recurrences.</li> <li>• Perichondritis or cauliflower ear are the complications.</li> </ul>
<p><b>Preauricular Sinus</b></p>  <p><b>Figure 19.2.17:</b> Preauricular sinus <i>Photo Courtesy:</i> Divya Prabhat</p>	<p>Opening anterior to the pinna.</p>	<ul style="list-style-type: none"> <li>• Congenital.</li> <li>• Always examine both sides.</li> <li>• Pus discharge needs antibiotics.</li> <li>• Recurrent infections lead to abscess formation.</li> <li>• Surgical excision of the tract may be needed.</li> </ul>
<p><b>Thyroid</b></p>  <p><b>Figure 19.2.18:</b> Thyroid <i>Photo Courtesy:</i> Divya Prabhat</p>	<p>Neck swelling moving on deglutition.</p>	<ul style="list-style-type: none"> <li>• May be congenital.</li> <li>• Chances of malignancy are high.</li> <li>• Thyroid scan a must.</li> <li>• Thyroid function tests.</li> <li>• Calcium/Phosphorus levels.</li> <li>• Anti-TPO antibodies.</li> <li>• Se Calcitonin levels.</li> <li>• Fine needle aspiration cytology (FNAC) and CT scan.</li> <li>• Thyroidectomy SOS.</li> </ul>


Picture	Note	Management
<p><b>Tongue Tie</b></p>  <p><b>Figure 19.2.19:</b> Tongue tie Photo Courtesy: Divya Prabhat</p>	<p>Frenulum preventing complete tongue movement.</p>	<ul style="list-style-type: none"> <li>• A congenital anomaly, known as ankyloglossia as decreases the mobility of the tongue.</li> <li>• May cause disarticulation in about 50% of children.</li> <li>• Speech therapy and wait and watch policy adopted.</li> <li>• Frenotomy may be considered for speech, feeding or social problems.</li> </ul>



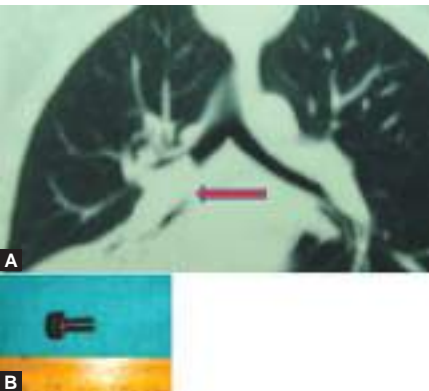
### 19.3 ENT EMERGENCIES

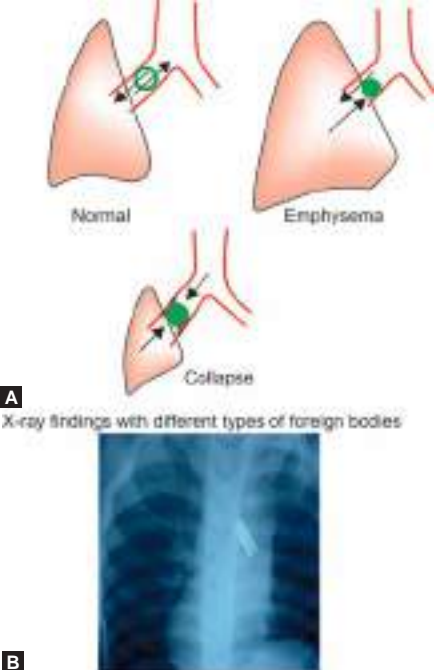
#### Ear Bleed

 <p><b>Figure 19.3.1:</b> Ear bleed Photo Courtesy: Divya Prabhat</p>	<p>Blood clots from the ear canal.</p>	<ul style="list-style-type: none"> <li>• Due to usage of buds, pin, pencil, etc.</li> <li>• Blood stained discharge due to ear polyp/granulations or an unsafe ear.</li> <li>• Avoid instrumentation/cleaning or any ear drops.</li> <li>• Dry cotton will generally stop the bleed.</li> </ul>
---	--	---


#### Epistaxis


 <p><b>Figure 19.3.2:</b> Epistaxis Photo Courtesy: Divya Prabhat</p>	<p>Site of pinching the nostrils.</p>	<ul style="list-style-type: none"> <li>• Pinch nostrils for 5 minutes at Little's area (lower down) and not at the nasal bones.</li> <li>• Postnasal bleed, to spit into the basin.</li> <li>• Ice compressions.</li> <li>• Anterior nasal packs (gauze strip) soaked with dilute adrenaline.</li> </ul>
--	---------------------------------------	--

Picture	Note	Management
<b>Facial Trauma</b>		
 <p><b>Figures 19.3.3A and B:</b> Facial trauma <i>Photo Courtesy: Divya Prabhat</i></p>	Multiple facial injuries.	<ul style="list-style-type: none"> <li>• Facial and neck trauma occur frequently in children.</li> <li>• Most result in soft tissue injuries.</li> <li>• Fortunately, serious facial fractures are uncommon.</li> <li>• Laceration (cuts) that are disfiguring are closed by suturing, to minimize the scarring.</li> </ul>
<b>Foreign Body Bronchus (Collapse)</b>		
 <p><b>Figure 19.3.4:</b> Foreign body bronchus (Collapse) <i>Photo Courtesy: Divya Prabhat</i></p>	Complete collapse of right lobe in a 10 months old child.	<ul style="list-style-type: none"> <li>• Progressive breathlessness.</li> <li>• Collapse (R) side.</li> <li>• Compensatory emphysema (L) side.</li> <li>• Suspect FB/mucous plug (R) main bronchus.</li> <li>• Bronchoscopy for removal.</li> </ul>
<b>Foreign Body Bronchus (Typical Case)</b>		
 <p><b>Figures 19.3.5A and B:</b> Foreign body bronchus (typical case) <i>Photo Courtesy: Divya Prabhat</i></p>	Foreign body in the right bronchus.	<ul style="list-style-type: none"> <li>• Persisting cough.</li> <li>• Improves with antibiotics, bronchodilators, steroids.</li> <li>• Recurrent respiratory tract infections.</li> <li>• Hematology normal.</li> <li>• Suspect foreign body.</li> <li>• CT scan diagnostic of FB.</li> </ul>

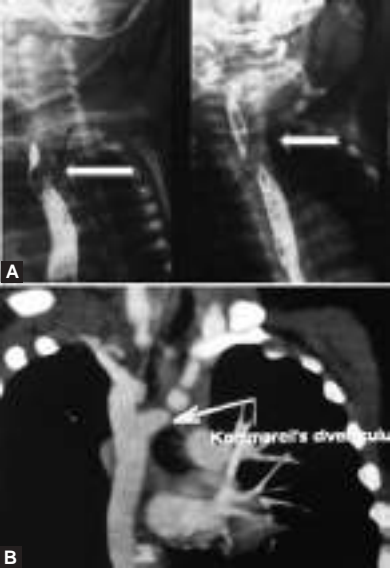
Picture	Note	Management
<p><b>Foreign Body Bronchus X-rays</b></p>  <p><b>A</b> X-ray findings with different types of foreign bodies</p> <p><b>B</b></p> <p><b>Figures 19.3.6A and B:</b> Foreign body bronchus X-rays <i>Photo Courtesy:</i> Divya Prabhat</p>	<p>Lung changes to different types of foreign bodies.</p>	<ul style="list-style-type: none"> <li>• Bypass valve, e.g. ring, button.</li> <li>• One way valve, e.g. metallic foreign body.</li> <li>• Stop valve, e.g. nut, pea, bean (hygroscopic foreign body), etc.</li> </ul>




### Foreign Body—Nose

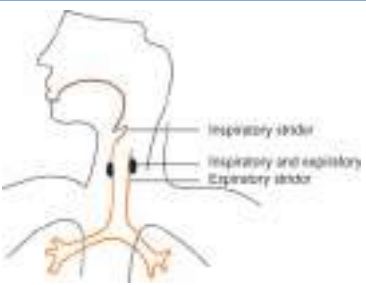
 <p><b>Figure 19.3.7:</b> Foreign body—Nose <i>Photo Courtesy:</i> Divya Prabhat</p>	<p>Instrument going beyond the foreign body.</p>	<ul style="list-style-type: none"> <li>• Unilateral Nasal block with purulent discharge.</li> <li>• Removed by going beyond the FB.</li> <li>• Avoid using forceps, which further push the FB behind.</li> <li>• Only an impacted FB or a rhinolith may require general anesthesia for its removal.</li> </ul>
---	--	--

Picture	Note	Management
 <p><b>Figure 19.3.8:</b> Fracture nasal bone <i>Photo Courtesy:</i> Divya Prabhat</p>	<p>Edema around the nasal bridge and blood clots.</p>	<ul style="list-style-type: none"> <li>• Postnasal bleeding.</li> <li>• CSF rhinorrhea.</li> <li>• Septal hematoma.</li> <li>• Lamina papyracea damage (eye movement).</li> <li>• Frontal lobe trauma (neurologic examination).</li> </ul>

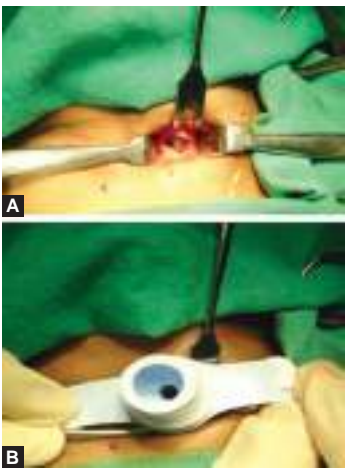
### Kommerell's Diverticulum

 <p><b>Figures 19.3.9A and B:</b> Kommerell's diverticulum <i>Photo Courtesy:</i> Divya Prabhat</p>	<p>Compression of the trachea and esophagus.</p>	<ul style="list-style-type: none"> <li>• Embryogenically, persistent aortic arch.</li> <li>• Respiratory symptoms due to complete vascular ring.</li> <li>• Dysphagia due to pressure on the esophagus (arrow).</li> <li>• Barium swallow and cardiac MRI are diagnostic.</li> <li>• The repair is done via thoracotomy.</li> </ul>
---	--	---

Picture	Note	Management
<p><b>Retropharyngeal Abscess</b></p>  <p><b>Figure 19.3.10:</b> Retropharyngeal abscess <i>Photo Courtesy: Divya Prabhat</i></p>	<p>Increase in the prevertebral space.</p>	<ul style="list-style-type: none"> <li>• Present with dysphagia, stridor and hoarseness.</li> <li>• Check for tonsillitis, dental infection or foreign bodies.</li> <li>• Intravenous antibiotics and watch O<sub>2</sub> saturation.</li> <li>• SOS drainage or aspiration of abscess.</li> <li>• Tracheostomy if stridor.</li> </ul>
<p><b>Septal Hematoma</b></p>  <p><b>Figure 19.3.11:</b> Septal hematoma <i>Photo Courtesy: Divya Prabhat</i></p>	<p>Septal bulge in both nostrils.</p>	<ul style="list-style-type: none"> <li>• Nasal block and history of injury.</li> <li>• Require urgent medical attention.</li> <li>• Nasal cartilage can necrose in 24 hours and result in saddle nose deformity.</li> <li>• Treatment is surgical drainage of the hematoma and nasal packing.</li> </ul>
<p><b>Stridor—Signs</b></p>  <p><b>Figure 19.3.12:</b> Stridor—Signs <i>Photo Courtesy: Divya Prabhat</i></p>	<p>Signs seen in the child with stridor.</p>	<ul style="list-style-type: none"> <li>• Not a diagnosis; is a symptom or sign.</li> <li>• Suprasternal retraction and subcostal indrawing (Fig. 19.3.12).</li> <li>• Continous more serious.</li> <li>• Congenital stridor appears after URTI.</li> <li>• Rising pulse is the most reliable sign.</li> <li>• Poor nutrition, obesity and anemia will all worsen stridor.</li> <li>• Lastly intubation or tracheostomy.</li> </ul>


Picture	Note	Management
<p><b>Stridor—Sites</b></p>  <p><b>Figure 19.3.13:</b> Stridor—Sites Photo Courtesy: Divya Prabhat</p>	<p>Different levels of involvement causing stridor.</p>	<ul style="list-style-type: none"> <li>• Inspiratory—Supraglottis (laryngomalacia).</li> <li>• Biphasic-glottis/subglottis (papilloma, vocal cord palsy, stenosis).</li> <li>• Expiratory—Bronchi (foreign bodies).</li> </ul>

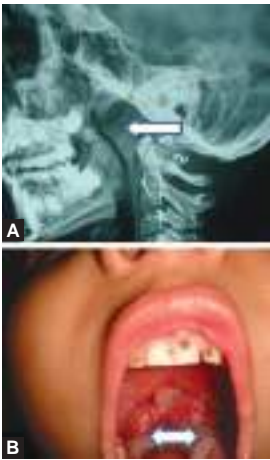
### Tracheotomy

 <p><b>Figures 19.3.14A and B:</b> Tracheotomy Photo Courtesy: Divya Prabhat</p>	<p>Opening of the trachea and portex tube introduction.</p>	<ul style="list-style-type: none"> <li>• Bypass the upper-airway obstruction.</li> <li>• Reduction of dead space.</li> <li>• Access to lower airways.</li> <li>• Easy induction.</li> </ul> <p>(No contraindications for a tracheotomy).</p>
--	---	--


## 19.4 SYNDROMES

### Down's Syndrome

 <p><b>Figure 19.4.1:</b> Downs syndrome Photo Courtesy: Divya Prabhat</p>	<p>Protuding and large tongue.</p>	<ul style="list-style-type: none"> <li>• Stridor on lying down.</li> <li>• Macroglossia and narrow nasopharynx cause the tongue fall.</li> <li>• Enlarged lingual tonsils add to the problems.</li> <li>• Prone or semi position is advised.</li> <li>• Extreme cases a tongue stich is required.</li> </ul>
---	------------------------------------	--

Picture	Note	Management
<p><b>Obstructive Sleep Apnea Syndrome (OSAS)</b></p>  <p><b>Figures 19.4.2A and B:</b> Snoring—OSAS Photo Courtesy: Divya Prabhat</p>	<p>Hypertrophied adenoids and tonsils.</p>	<ul style="list-style-type: none"> <li>• Excessive day time sleepiness.</li> <li>• Abnormal weight gain.</li> <li>• Recent enuresis.</li> <li>• School performance affected.</li> <li>• Progressive hypertension.</li> <li>• Need tonsil-adenoidectomy.</li> </ul>

**Vactral Syndrome**

 <p><b>Figure 19.4.3:</b> Vactral syndrome Photo Courtesy: Divya Prabhat</p>	<p>Midline congenital deformity.</p>	<ul style="list-style-type: none"> <li>• Vertebral anomalies.</li> <li>• Imperforate anus.</li> <li>• Cardiac defects.</li> <li>• Tracheoesophageal fistula.</li> <li>• Renal anomalies.</li> <li>• Limb abnormalities.</li> </ul>
--	--------------------------------------	--





## Section 20

---

# Pediatric Surgery

### *Section Editors*

Ketan Parikh, Arbinder Kumar Singal

### *Photo Courtesy*

Amrish Vaidya, Arbinder Kumar Singal, Ketan Parikh, Manish Jain, Rasik Shah

- 20.1 Common External Conditions
- 20.2 Head and Neck Conditions
- 20.3 Chest and Diaphragm
- 20.4 Gastrointestinal and Hepatobiliary Disorders
- 20.5 Pediatric Urological Conditions
- 20.6 Solid Tumors of Childhood

## SECTION OUTLINE

### 20.1 COMMON EXTERNAL CONDITIONS 425

- ◆ Abscess 425
- ◆ Cleft Lip and Palate 425
- ◆ Congenital Hydrocele 425
- ◆ Hemangioma 426
- ◆ Hydrocephalus 426
- ◆ Inguinal Hernia 426
- ◆ Labial Adhesions 427
- ◆ Meningocele/Meningomyelocele 427
- ◆ Necrotizing Fasciitis 427
- ◆ Phimosi s 428
- ◆ Umbilical Hernia 428
- ◆ Umbilical Polyp/Granuloma 428
- ◆ Undescended Testis 429

### 20.2 HEAD AND NECK CONDITIONS 429

- ◆ Branchial Cyst/Sinus 429
- ◆ Cystic Hygroma 429
- ◆ Ranula 430
- ◆ Thyroglossal Cyst and Sinus 430
- ◆ Torticollis 430

### 20.3 CHEST AND DIAPHRAGM 431

- ◆ Airway Foreign Body (FB) 431
- ◆ Congenital Cystadenomatoid Malformation 431
- ◆ Congenital Diaphragmatic Hernia (CDH) 431
- ◆ Empyema 432
- ◆ Pneumothorax 432
- ◆ Tracheoesophageal Fistula (TEF) 432

### 20.4 GASTROINTESTINAL AND HEPATOBILIARY DISORDERS 433

- ◆ Achalasia Cardia 433
- ◆ Biliary Atresia 433
- ◆ Choledochal Cyst 433
- ◆ Cloaca 434
- ◆ Duodenal Atresia 434
- ◆ Exomphalos 434

- ◆ Gastroesophageal Reflux (GER) 435
- ◆ Gastroschisis 435
- ◆ High-ARM 435
- ◆ Hirschsprung's Disease 436
- ◆ Idiopathic Hypertrophic Pyloric Stenosis (IHPS) 436
- ◆ Intestinal Roundworm Infestations 437
- ◆ Intussusception 437
- ◆ Jejun o-ileal Atresia 437
- ◆ Low ARM—Male 438
- ◆ Malrotation 438
- ◆ Meckel's Diverticulum 438
- ◆ Meconium Peritonitis 439
- ◆ Necrotizing Enterocolitis 439
- ◆ Peritonitis/Intestinal Obstruction 439
- ◆ Rectal Polyp 440
- ◆ Rectovestibular Fistula (RVF) 440




### 20.5 PEDIATRIC UROLOGICAL CONDITIONS 440



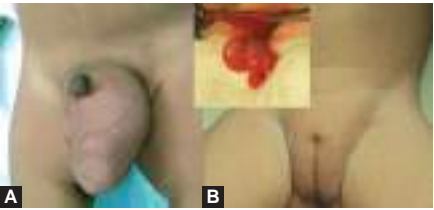
- ◆ Antenatally Diagnosed Hydronephrosis —Bilateral (PUV) 440
- ◆ Antenatally Diagnosed Hydronephrosis (ADH)—Unilateral 441
- ◆ Calculi 441
- ◆ Disorder of Sex Development (DSD) 441
- ◆ Epispadias 442
- ◆ Exstrophy 442
- ◆ Hypospadias 442
- ◆ Neuropathic Bladder 443
- ◆ Pelvi-ureteric Junction Obstruction 443
- ◆ Testicular Torsion 443
- ◆ Ureterocele 444
- ◆ Vesicoureteric Reflux (VUR) 444




### 20.6 SOLID TUMORS OF CHILDHOOD 444




- ◆ Neuroblastoma 444
- ◆ Sacrococcygeal Teratoma 445
- ◆ Wilms' Tumor 445


## 20.1 COMMON EXTERNAL CONDITIONS

Picture	Note	Management
 <p><b>Figure 20.1.1:</b> Abscess Photo Courtesy: Ketan Parikh</p>	<ul style="list-style-type: none"> <li>• Pain, redness and swelling are indicative of inflammation but softening of tissues or fluctuation are definite indicators of pus collection.</li> <li>• In case of clinical doubt, USG may help in deep-seated abscess but poor sensitivity.</li> </ul>	<ul style="list-style-type: none"> <li>• Pus anywhere in the body should be removed at the earliest. Pointing of the pus (due to secondary superficial necrosis) and spontaneous discharge may occur in late cases but poor healing of resultant wound.</li> <li>• Surgical drainage as early as possible avoids the local and systemic morbidity.</li> </ul>
 <p><b>Figure 20.1.2:</b> Cleft lip and palate Photo Courtesy: Ketan Parikh</p>	<ul style="list-style-type: none"> <li>• Cleft lip may be unilateral/bilateral.</li> <li>• Cleft palate leads to nasal regurgitation of feeds, nasal voice, recurrent URTI/ear infections.</li> <li>• Feeding difficulties rare.</li> <li>• In case of small mandible—Pierre-Robin syndrome (PRS)—breathing difficulty due to tongue fall.</li> </ul>	<ul style="list-style-type: none"> <li>• Lip repair may be done at birth but preferably at 3 months age.</li> <li>• Palate repair after 9 months age.</li> <li>• PRS may require RT feeds for few months.</li> <li>• In severe cases of PRS, breathing difficulty—nursing in prone position—SOS tracheostomy.</li> </ul>
 <p><b>Figure 20.1.3:</b> Congenital hydrocele Photo Courtesy: Ketan Parikh</p>	<ul style="list-style-type: none"> <li>• Swelling more likely to be scrotal (possible to get above swelling).</li> <li>• May be difficult to reduce, there may be diurnal variation in size of swelling. Cystic consistency to feel.</li> <li>• Transillumination positive.</li> </ul>	<ul style="list-style-type: none"> <li>• Complications not common.</li> <li>• Spontaneous resolution is common before 6 months of age.</li> <li>• Surgery is thus indicated only if the swelling persists or is increasing in size.</li> <li>• <i>Surgery:</i> Herniotomy.</li> </ul>

Picture	Note	Management
<p><b>Hemangioma</b></p>  <p><b>Figures 20.1.4A and B:</b> (A) 1, 2]Infra-orbital lesion; 3] excised with primary closure; 4] mass having significant subcutaneous element; 5] no residual disfigurement; (B) Lesion on labia - serial photographs after intralesional injections  <i>Photo Courtesy:</i> Ketan Parikh, Amrish Vaidya</p>	<ul style="list-style-type: none"> <li>• Diagnosis is almost always clinical.</li> <li>• Occasionally, imaging necessary to differentiate from other congenital lesions—Doppler, CT, MRI.</li> </ul>	<p>(Fig. 20.1.4A) Lesions which are totally excisable without significant residual tissue loss are best excised surgically.</p> <p>(Fig. 20.1.4B) If surgical excision is likely to lead to disfigurement— intralesional injections—steroids or oral propranolol or steroids.</p>
<p><b>Hydrocephalus</b></p>  <p><b>Figure 20.1.5:</b> Hydrocephalus—the sun-setting sign  <i>Photo Courtesy:</i> Ketan Parikh</p>	<ul style="list-style-type: none"> <li>• Antenatal diagnosis easy on USG</li> <li>• <i>Postnatally:</i> Large head with sutural separation, open AF, sun-setting sign.</li> </ul>	<ul style="list-style-type: none"> <li>• <i>Antenatal:</i> Termination in selected cases.</li> <li>• In case of increasing head circumference or evidence of increasing intracranial tension— VP shunt is necessary.</li> <li>• Endoscopic third ventriculostomy—an option in selected cases.</li> </ul>
<p><b>Inguinal Hernia</b></p>  <p><b>Figures 20.1.6A and B:</b> (A) Left inguinal hernia in a male child; (B) Left inguinal hernia in a female child (inset) ovary and adnexa in the hernia sac  <i>Photo Courtesy:</i> Ketan Parikh</p>	<ul style="list-style-type: none"> <li>• Inguinoscrotal swelling.</li> <li>• Usually reducible.</li> <li>• Never resolves spontaneously.</li> <li>• Seen also in females where ovary could be a content of the sac (inset).</li> </ul>	<ul style="list-style-type: none"> <li>• Diagnosis is essentially clinical and imaging rarely indicated.</li> <li>• High chances of strangulation especially in newborns/ pretermatures.</li> <li>• Early surgery recommended—even in newborns.</li> </ul>


Picture	Note	Management
<p><b>Labial Adhesions</b></p>  <p><b>Figure 20.1.7:</b> Labial adhesions <i>Photo Courtesy:</i> Ketan Parikh</p>	<ul style="list-style-type: none"> <li>• Superficial adhesions of labia minora seen in prepubertal girls.</li> <li>• Mostly asymptomatic but can lead to vulvitis or dysuria.</li> <li>• Diagnosis is based on clinical examination alone and no further tests are required.</li> </ul>	<ul style="list-style-type: none"> <li>• Release under mild sedation / surface anesthesia.</li> <li>• Recurrence prevention by local application of estrogen cream.</li> </ul>
<p><b>Meningocele/Meningomyelocele</b></p>  <p><b>Figures 20.1.8A to C:</b> (A) Skin covered lesion—no emergency; (B) Open lesion; (C) Shows the exposed neural tissue and dural sac <i>Photo Courtesy:</i> Ketan Parikh</p>	<ul style="list-style-type: none"> <li>• The most common site is lumbosacral.</li> <li>• Meningocele (skin covered), neurological deficit—governed by size and location of defect.</li> <li>• Meningomyelocele (exposed neural tissue) high potential of meningitis if not operated early.</li> <li>• Neurological deficit—invariable.</li> </ul>	<ul style="list-style-type: none"> <li>• Meningomyelocele—immediate cover with sterile moist impervious (plastic) dressing.</li> <li>• Surgical correction preferable within 36 to 48 hours of birth.</li> </ul>
<p><b>Necrotizing Fasciitis</b></p>  <p><b>Figure 20.1.9:</b> Necrotizing fasciitis <i>Photo Courtesy:</i> Arbinder Kumar Singal</p>	<p>It is a rapidly spreading subcutaneous infection in neonates/children with compromised immunity.</p>	<p>Early aggressive drainage of all infected tissue with adequate systemic support for control of infection minimizes morbidity and mortality.</p>

Picture	Note	Management
 <p><b>Figures 20.1.10A and B:</b> Phimosis Photo Courtesy: Arbinder Kumar Singal</p>	<ul style="list-style-type: none"> <li>• Common problem in prepubertal boys and; physiological till 4 to 5 years of age.</li> <li>• Considered pathological if there are symptoms like ballooning, dysuria, local infections (balanoposthitis) or urinary infections.</li> <li>• Whitish scarring of foreskin signifies balanitis xerotica obliterans, (BXO) (Fig. 20.1.10B).</li> </ul>	<p>Asymptomatic children till 5 to 6 years should be left alone.</p> <p>Treatment for symptomatic children:</p> <ul style="list-style-type: none"> <li>• Medical treatment with local betamethasone dipropionate.</li> <li>• Nonresponders or children with BXO should be offered circumcision.</li> <li>• Preputioplasty (prepuce preserving surgery) is another option.</li> </ul>
 <p><b>Figure 20.1.11:</b> Umbilical hernia; protrusion of umbilicus Photo Courtesy: Rasik Shah</p>	<ul style="list-style-type: none"> <li>• Common occurrence</li> <li>• Usually resolves spontaneously by 2 years age.</li> <li>• May get strangulated even in infancy.</li> </ul>	<p>Surgery if:</p> <ul style="list-style-type: none"> <li>• Failure to close spontaneously.</li> <li>• In younger patients in case of emergency or history of recurrent obstructions.</li> </ul>
 <p><b>Figure 20.1.12:</b> Umbilical polyp/granuloma Photo Courtesy: Ketan Parikh</p>	<ul style="list-style-type: none"> <li>• Granuloma—common occurrence in infancy due to nonhealing umbilical stump.</li> <li>• Persistent discharge at umbilicus—usually/sanguinous.</li> <li>• Polyp—mucosal surface with mucoid discharge.</li> <li>• Need to rule out sinus or fistula with bladder/intestine.</li> </ul>	<ul style="list-style-type: none"> <li>• Superficial application of silver nitrate, etc. help only in case of granuloma.</li> <li>• Ligation helps in most cases.</li> <li>• <i>Recurrence:</i> Suggestive of internal attachment.</li> </ul>


Picture	Note	Management
<p data-bbox="126 212 394 241"><b>Undescended Testis</b></p>  <p data-bbox="138 676 500 717"><b>Figure 20.1.13:</b> Undescended testis Photo Courtesy: Arbinder Kumar Singal</p>	<ul data-bbox="605 267 992 560" style="list-style-type: none"> <li>• Undescended testis occurs in 1/100 male birth but more than 50% of these complete their descent by 4 to 5 months of age.</li> <li>• Clinical examination suffices for decision making. MRI/USG are not considered 100% reliable for diagnosing/ locating undescended testis.</li> </ul>	<ul data-bbox="1049 267 1442 506" style="list-style-type: none"> <li>• If the testis does not come down by 6 months, surgery is required.</li> <li>• Palpable UDT—daycare orchiopexy.</li> <li>• Nonpalpable UDT—diagnostic laparoscopy and then staged or single stage orchiopexy.</li> </ul>

## 20.2 HEAD AND NECK CONDITIONS




### Branchial Cyst/Sinus

 <p data-bbox="138 1226 500 1293"><b>Figure 20.2.1:</b> Shows a case of bilateral branchial fistula Photo Courtesy: Rasik Shah</p>	<ul data-bbox="605 895 1016 1201" style="list-style-type: none"> <li>• Diagnosis—clinical</li> <li>• Opening along the anterior border of sternomastoid in lower 1/3, may be unilateral/bilateral.</li> <li>• Sinus/fistula more common in children. Inner opening of fistula in pharynx.</li> <li>• <i>Complications:</i> Infection, late malignant changes.</li> </ul>	<ul data-bbox="1049 895 1425 1126" style="list-style-type: none"> <li>• Surgical excision is the only treatment.</li> <li>• <i>Left inset:</i> Excision of the entire tract (usually till the bed of tonsils) essential to prevent recurrence. This may require a step-ladder incision.</li> </ul>
--	--	--

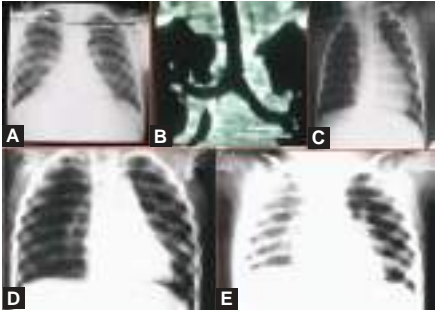

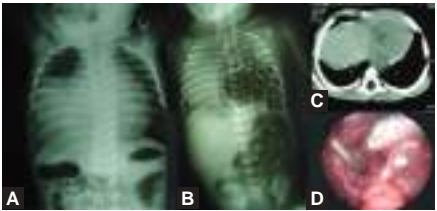
### Cystic Hygroma



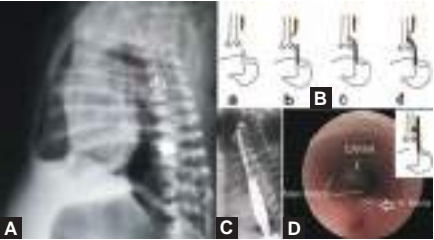
 <p data-bbox="138 1800 500 1868"><b>Figure 20.2.2:</b> Swelling in the neck and axillary region Photo Courtesy: Ketan Parikh</p>	<ul data-bbox="605 1418 1016 1582" style="list-style-type: none"> <li>• Soft, lobulated, cystic, painless mass, brilliantly transilluminant.</li> <li>• <i>Complications:</i> Infection, hemorrhage within mass, stridor/dyspnea/dysphagia.</li> </ul>	<ul data-bbox="1049 1418 1442 1622" style="list-style-type: none"> <li>• Total excision is the treatment of choice.</li> <li>• Aspiration in emergency cases only.</li> <li>• Intralesional injections—an option in selected cases.</li> </ul>
--	--	--



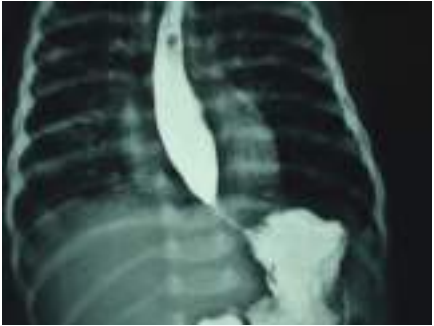


Picture	Note	Management
<p data-bbox="152 216 248 247"><b>Ranula</b></p>  <p data-bbox="164 764 578 840"><b>Figure 20.2.3:</b> Inset: External swelling visible from floor of mouth <i>Photo Courtesy:</i> Ketan Parikh</p>	<p data-bbox="630 273 992 400">Soft, cystic swelling in floor of mouth under the tongue—may cause tongue-fall and problems with swallowing/breathing.</p>	<ul data-bbox="1073 273 1406 400" style="list-style-type: none"> <li>• Excision—intraorally is therapeutic.</li> <li>• Partial excision may lead to recurrence.</li> </ul>
 <p data-bbox="164 1308 548 1355"><b>Figure 20.2.4:</b> Thyroglossal cyst and sinus <i>Photo Courtesy:</i> Ketan Parikh</p>	<ul data-bbox="630 968 1040 1132" style="list-style-type: none"> <li>• Midline swelling moves with deglutition and protrusion of tongue.</li> <li>• If infected, may rupture externally and lead to sinus formation.</li> </ul>	<ul data-bbox="1073 968 1484 1167" style="list-style-type: none"> <li>• Need to rule out ectopic thyroid tissue.</li> <li>• Surgical excision—Sistrunks' operation—excision of entire tract till base of tongue including body of hyoid bone necessary.</li> </ul>
<p data-bbox="152 1432 289 1463"><b>Torticollis</b></p>  <p data-bbox="164 1768 565 1870"><b>Figures 20.2.5A and B:</b> (A) Patient seen in infancy; (B) Untreated case leading to hemihypoplasia of face <i>Photo Courtesy:</i> Rasik Shah</p>	<ul data-bbox="630 1490 1040 1786" style="list-style-type: none"> <li>• Exact etiology unknown.</li> <li>• There may be a history of sterno-mastoid tumor in infancy. Beyond 1 year of age—spontaneous resolution unlikely.</li> <li>• Untreated—may lead to hemihypoplasia of face and permanent ocular manifestations (Fig. 20.2.5B).</li> </ul>	<ul data-bbox="1073 1490 1484 1688" style="list-style-type: none"> <li>• Physiotherapy involving exercises of the neck—helpful in infancy.</li> <li>• If the muscle is fibrotic, surgical release necessary—physiotherapy required even after surgery to correct the soft tissue.</li> </ul>




## 20.3 CHEST AND DIAPHRAGM

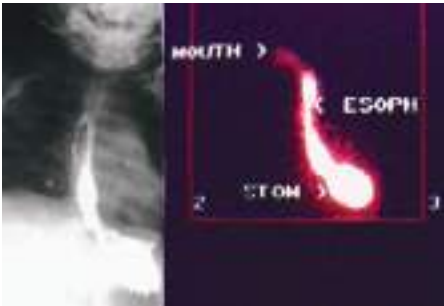


Picture	Note	Management
<p><b>Airway Foreign Body (FB)</b></p>  <p><b>Figures 20.3.1A to E:</b> (A) Right lower lobe collapse-consolidation in case of an old FB confirmed on CT; (B, C) Radiopaque FB; (D, E) Inspiratory and expiratory films in case of radio-lucent FB- highlighting the obstructive emphysema on left side Photo Courtesy: Ketan Parikh</p>	<ul style="list-style-type: none"> <li>• <i>Acute onset:</i> Choking crisis, cough and stridor.</li> <li>• <i>Late cases:</i> Recurrent localized pneumonia, lung abscess.</li> <li>• <i>X-ray:</i> Diagnostic in most cases the most common finding is obstructive emphysema (best seen in an expiratory film). other findings may be: collapse/consolidation or radiopaque FB.</li> <li>• <i>CT/virtual bronchoscopy:</i> Helpful but not 100% sensitive.</li> <li>• Diagnostic bronchoscopy in strong suspicion cases.</li> </ul>	<ul style="list-style-type: none"> <li>• Early removal of FB essential.</li> <li>• <i>Bronchoscopy (rigid):</i> Most effective. Presence of optical forceps—a useful tool.</li> <li>• Bronchotomy/lobectomy in selected cases.</li> </ul>
<p><b>Congenital Cystadenomatoid Malformation</b></p>  <p><b>Figure 20.3.2:</b> Congenital cystic adenoid malformation of lung Photo Courtesy: Arbinder Kumar Singal</p>	<ul style="list-style-type: none"> <li>• <i>Antenatal diagnosis:</i> May resolve in selected cases.</li> <li>• <i>Postnatally:</i> Respiratory distress.</li> <li>• <i>Differential diagnosis:</i> Congenital diaphragmatic hernia (CDH), especially if it is on left side.</li> <li>• <i>Imaging:</i> X-ray/USG/CT scan.</li> </ul>	<ul style="list-style-type: none"> <li>• Surgical excision of the affected lobe of the lung is essential.</li> <li>• Prognosis—good in most cases unless there is multiple lobe involvement.</li> </ul>
<p><b>Congenital Diaphragmatic Hernia (CDH)</b></p>  <p><b>Figures 20.3.3A to C:</b> (A) Right sided hernia: Liver ascended up (colon shadow at same level as stomach); (B) Left sided hernia with bowel; (C) CT scan of right hernia; (D) Thoracoscopic view of the defect in diaphragm (arrow) Photo Courtesy: Ketan Parikh</p>	<ul style="list-style-type: none"> <li>• <i>Antenatal diagnosis:</i> MTP in selected cases.</li> <li>• <i>Postnatal presentation:</i> Respiratory distress with a scaphoid abdomen, vomiting/incidental diagnosis.</li> </ul>	<ul style="list-style-type: none"> <li>• Avoid bag—mask ventilation, intubate if indicated.</li> <li>• Pass NG tube and keep it open to avoid aerophagia.</li> <li>• Ventilatory support mostly required—some cases may require high frequency ventilation.</li> <li>• Surgery after a period of physiological stabilization—may take 1 to 5 days.</li> <li>• Express surgery—no more indicated.</li> </ul>


Picture	Note	Management
<p><b>Empyema</b></p>  <p><b>Figures 20.3.4A to C:</b> Left sided empyema (X-ray): (A) CT appearance with a thick peel of empyema; (B) Fibrinopurulent exudates removed during VATS; (C) Thoracoscopic view (honeycomb) of the loculations <i>Photo Courtesy:</i> Ketan Parikh, Arbinder Kumar Singal</p>	<ul style="list-style-type: none"> <li>• Fever, respiratory distress, fullness of unilateral chest with restricted ipsilateral movement.</li> <li>• <i>Imaging:</i> USG important to identify nature of fluid and loculations if any.</li> <li>• <i>CT:</i> To identify underlying pathology or abscess and anatomical details.</li> </ul>	<ul style="list-style-type: none"> <li>• Early stage—for thin pus with no loculation: Intercostal drainage (ICD) alone may suffice.</li> <li>• For thick pus/loculation: VATS drainage/decortication is the treatment of choice.</li> <li>• ICD with fibrinolytic therapy—an option in selected intermediate stage cases.</li> </ul>
<p><b>Pneumothorax</b></p>  <p><b>Figure 20.3.5:</b> The collapsed lung at hilum differentiates from a cyst or congenital lobar emphysema <i>Photo Courtesy:</i> Ketan Parikh</p>	<ul style="list-style-type: none"> <li>• Distress with fullness of chest on one side.</li> <li>• Clinically—resonant note and decreased air entry.</li> <li>• Diagnosis on chest X-ray.</li> <li>• CT may be required if there is any suspicion of lung cyst.</li> <li>• Spontaneous pneumothorax—in newborns or pulmonary pathologies.</li> </ul>	<ul style="list-style-type: none"> <li>• Intercostal drainage.</li> <li>• Treatment of primary pathology.</li> </ul>
<p><b>Tracheoesophageal Fistula (TEF)</b></p>  <p><b>Figures 20.3.6A to D:</b> (A) Lateral chest view with stiff rubber catheter in upper pouch (red line), air esophagogram delineates lower pouch (white outline); (B) Varieties of anomalies presenting at birth; (C, D) H fistula on esophagogram and bronchoscopy <i>Photo Courtesy:</i> Ketan Parikh</p>	<ul style="list-style-type: none"> <li>• Antenatal diagnosis—rare.</li> <li>• Frothing—most common presentation.</li> <li>• Vomiting/pneumonia in missed cases.</li> <li>• Aspiration syndrome in ‘H’ fistula.</li> <li>• Failure to pass stiff oral tube (Fig. 20.3.6A)—clinically diagnostic.</li> </ul>	<ul style="list-style-type: none"> <li>• Surgery—after stabilization over 24 to 48 hours.</li> <li>• <i>Aim:</i> To disconnect tracheo-esophageal communication and to establish a safe orogastric conduit.</li> <li>• Primary single stage surgery preferable, staged surgery in selected cases.</li> <li>• <i>Postcorrection:</i> Children prone to GER and tracheomalacia.</li> </ul>

## 20.4 GASTROINTESTINAL AND HEPATOBILIARY DISORDERS


Picture	Note	Management
 <p><b>Figure 20.4.1:</b> Dilated esophagus with smooth narrowing at cardia Photo Courtesy: Ketan Parikh</p>	<ul style="list-style-type: none"> <li>• Symptoms similar to GER</li> <li>• Barium swallow is diagnostic.</li> </ul>	<ul style="list-style-type: none"> <li>• Surgical treatment indicated in all symptomatic children, can be done laparoscopically also</li> <li>• Dilatation not recommended in children.</li> </ul>
 <p><b>Figure 20.4.2:</b> Icterus with hepatosplenomegaly Photo Courtesy: Ketan Parikh</p>	<ul style="list-style-type: none"> <li>• Jaundice with claycolored stools due to atretic biliary tree</li> <li>• Direct hyperbilirubinemia since early infancy.</li> <li>• Clinically—firm hepatomegaly and distention</li> <li>• USG—Gallbladder not seen, HIDA scan shows—no excretion of radioisotope in bile.</li> </ul>	<ul style="list-style-type: none"> <li>• Very early diagnosis mandatory for better outcome</li> <li>• Diagnostic laparoscopy with operative cholangiography to confirm diagnosis.</li> <li>• Kasai's procedure (Portoenterostomy) important.</li> <li>• Guarded prognosis and may require liver transplant.</li> </ul>
 <p><b>Figure 20.4.3:</b> Operative cholangiography (needle thro' GB) showing the fusiform dilatation of CBD and near normal hepatic ducts Photo Courtesy: Ketan Parikh</p>	<ul style="list-style-type: none"> <li>• Obstructive jaundice with fever and abdominal pain with or without abdominal lump.</li> <li>• May present with just recurrent episodes of pain abdomen and fever</li> <li>• <i>Diagnosis:</i> USG, MRCP.</li> </ul>	<ul style="list-style-type: none"> <li>• Excision of the cyst with drainage procedure usually curative.</li> <li>• Recurrent cholangitis may need treatment.</li> </ul>

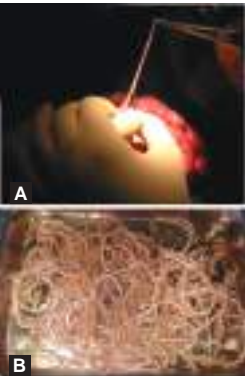
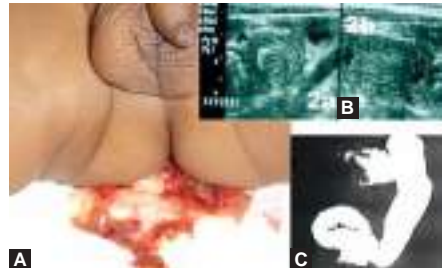
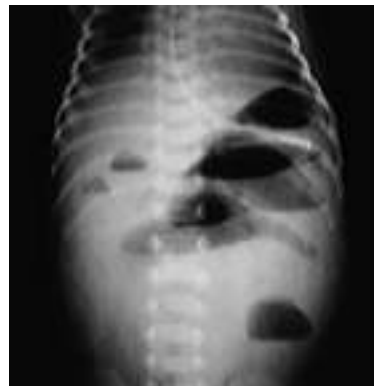
Picture	Note	Management
 <p><b>Figure 20.4.4:</b> Single opening Photo Courtesy: Ketan Parikh</p>	<ul style="list-style-type: none"> <li>• Single opening in perineum for urethra, vagina and anus.</li> <li>• High anomaly.</li> <li>• May be associated with other urogenital anomalies.</li> </ul>	<ul style="list-style-type: none"> <li>• Colostomy at birth.</li> <li>• Staged repair after detailed delineation of pathological anatomy.</li> <li>• Outcome for continence-guarded.</li> </ul>
 <p><b>Figure 20.4.5:</b> Duodenal atresia (Double bubble sign with no distal gas) Photo Courtesy: Ketan Parikh</p>	<ul style="list-style-type: none"> <li>• Bilious or nonbilious vomiting with rapid metabolic deterioration.</li> <li>• <i>X-ray:</i> Double bubble.</li> <li>• Rule out Down's syndrome.</li> </ul>	<ul style="list-style-type: none"> <li>• Metabolic correction is important before surgery.</li> <li>• <i>Surgery:</i> Duodeno-duodenal or duodeno-jejunal anastomosis.</li> </ul>
 <p><b>Figure 20.4.6:</b> Omphalocele (exomphalos) exomphalos major with intact sac Photo Courtesy: Ketan Parikh</p>	<ul style="list-style-type: none"> <li>• Exomphalos—usually diagnosed antenatally. Sac with loops seen clearly.</li> <li>• If syndromic, termination may be indicated.</li> <li>• Sac usually present, umbilical cord inserts on top of the sac.</li> </ul>	<p><i>Exomphalos minor:</i> Usually excellent prognosis after surgical correction.</p> <p><i>Exomphalos major:</i> If possible primary closure, if not—staged. Initial management with scarifying local agents and then closure later.</p>

Picture	Note	Management
 <p><b>Figure 20.4.7:</b> Ba swallow and milk scan: Grade 3 GER Photo Courtesy: Ketan Parikh</p>	<p>Nonbilious vomiting, failure to gain weight, bronchospasm, aspiration syndrome.</p> <ul style="list-style-type: none"> <li>• Diagnosis—clinical history</li> <li>• Barium swallow to rule out esophageal anomalies.</li> </ul> <p>Milk/GER nuclear scan to diagnose and grade reflux.</p>	<p>Primary management—medical. Indications for surgery—recurrent pneumonia, failure of medical management, grade 3 GER, near miss SIDS.</p>
 <p><b>Figure 20.4.8:</b> Matted bowel loops Photo Courtesy: Ketan Parikh</p>	<ul style="list-style-type: none"> <li>• Antenatal diagnosis easy—free floating bowel loops in amniotic cavity</li> <li>• Nonsyndromic, maternal factors contributory</li> <li>• Intact umbilicus, and defect to the right side of umbilical ring</li> <li>• No sac, bowel often matted.</li> </ul>	<ul style="list-style-type: none"> <li>• Immediate neonatal management: Plastic sterile cover to prevent infection and hypothermia during transport</li> <li>• Surgical correction on day 1 of life</li> <li>• May be staged or if possible primary closure.</li> </ul>
 <p><b>Figure 20.4.9:</b> Intermediate and high ARM (male): Flat perineum Photo Courtesy: Ketan Parikh</p>	<ul style="list-style-type: none"> <li>• Flat perineum.</li> <li>• Internal fistula into urinary tract.</li> <li>• Always check for associated anomalies of urinary tract and Spine.</li> </ul>	<ul style="list-style-type: none"> <li>• Staged repair—colostomy followed by PSARP and then colostomy closure.</li> <li>• Outcome dependent on level of atresia and development of levator ani.</li> </ul>


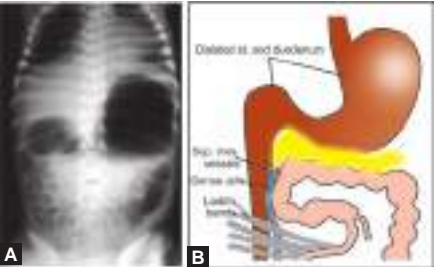

Picture	Note	Management
<p><b>Hirschsprung's Disease</b></p>  <p><b>Figures 20.4.10A to C:</b> (A) Massive abdominal distention; (B) Visible and palpable transverse colon; (C) Barium enema showing the narrow segment (white hollow arrow) classical 'cone' (black arrow) and dilated segment (white block arrow)</p> <p><i>Photo Courtesy:</i> Ketan Parikh</p>	<p><i>Clinical features:</i></p> <ul style="list-style-type: none"> <li>• Delayed passage of meconium and neonatal abdominal distention.</li> <li>• Constipation invariably dates back to neonatal age or early infancy.</li> <li>• Gaseous abdominal distention—with visible loops common.</li> <li>• <i>Per rectal exam:</i> Blast sign—expulsion of gas and stools on PR examination. Seen in common rectosigmoid variety, not in long segment.</li> <li>• Barium enema shows transition zone and proximal distended colon.</li> <li>• Rectal biopsy shows absence of ganglion cells in colon.</li> </ul>	<ul style="list-style-type: none"> <li>• <i>Conservative treatment:</i> (Repeated enemas with saline) may help to buy time.</li> <li>• Surgery involves excision of aganglionic bowel and bringing ganglionic bowel to the anus (may be staged or single-stage, open or laparoscopic).</li> <li>• <i>Long-term outcome:</i> Usually very good.</li> </ul>


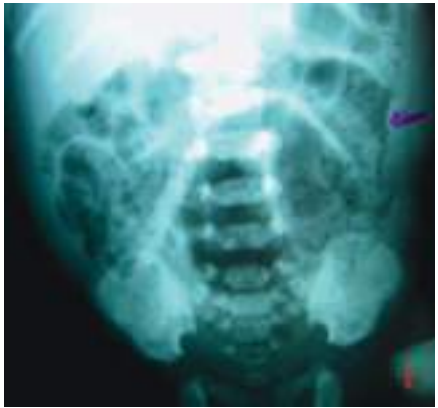
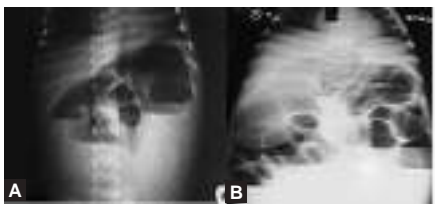
### Idiopathic Hypertrophic Pyloric Stenosis (IHPS)


 <p><b>Figure 20.4.11:</b> Visible peristalsis in a scaphoid abdomen. Insets: string sign on Ba meal, hypertrophied pylorus (pre- and postmyotomy)</p> <p><i>Photo Courtesy:</i> Ketan Parikh</p>	<ul style="list-style-type: none"> <li>• Progressive, projectile, non-bilious vomiting with visible peristalsis (left to right), progressive increase in frequency and intensity of vomiting.</li> <li>• Onset within first month, incidence peaks at 3 weeks.</li> <li>• Hypertrophied pylorus palpable in 70% cases.</li> </ul>	<ul style="list-style-type: none"> <li>• <i>Diagnosis:</i> USG abdomen showing pylorus longer than 14 mm and pyloric muscle thickness more than 6 mm.</li> <li>• In doubtful cases—barium meal.</li> <li>• Preoperative metabolic correction important with replacement of sodium.</li> <li>• <i>Surgery:</i> Open/laparoscopic—excellent results with no long-term consequences.</li> </ul>
--	---	--


Picture	Note	Management
<p data-bbox="126 214 586 245"><b>Intestinal Roundworm Infestations</b></p>  <p data-bbox="126 664 586 772"><b>Figures 20.4.12A and B:</b> Intestinal roundworm infestations roundworms can be seen through intestinal wall and being retrieved <i>Photo Courtesy:</i> Manish Jain, Surat</p>	<p data-bbox="586 214 1024 398">Commonly seen in a particular socioeconomic strata, roundworm infestation may cause acute intestinal obstruction.</p> <p data-bbox="586 408 1024 772">The mass of roundworms is usually palpable on abdominal examination. Tenderness of this mass is indicative of vascular compromise of the involved bowel wall.</p>	<p data-bbox="1024 214 1468 429">Conservative management involves hypertonic saline enemas to disrupt the bolus of roundworms and they pass out into the colon relieving the obstruction.</p> <p data-bbox="1024 439 1468 772">Surgical management is needed in case of failure of conservative management, tenderness on the mass or evidence of peritonitis.</p>
<p data-bbox="126 793 586 823"><b>Intussusception</b></p>  <p data-bbox="126 1175 586 1310"><b>Figures 20.4.13A to C:</b> (A) Red currant jelly stools-typical blood in feces; (B) USG finding; (C) Barium enema <i>Photo Courtesy:</i> Ketan Parikh, Arbinder Kumar Singal</p>	<ul data-bbox="586 891 1024 1124" style="list-style-type: none"> <li>• Severe abdominal colics with vomiting, bleeding per rectum, abdominal lump (diagnostic).</li> <li>• <i>Imaging:</i> USG shows a pseudokidney or target sign</li> <li>• Barium enema if any doubt in diagnosis.</li> </ul>	<ul data-bbox="1024 891 1468 1124" style="list-style-type: none"> <li>• Hydrostatic reduction in early cases. This can be USG guided (preferable) or fluoroscopy guided</li> <li>• <i>Surgery for late cases:</i> Reduction and if there is gangrene—resection and anastomosis.</li> </ul>
<p data-bbox="126 1330 586 1361"><b>Jejuno-ileal Atresia</b></p>  <p data-bbox="126 1815 586 1892"><b>Figure 20.4.14:</b> Jejuno-ileal atresia, more distal the obstruction—more fluid levels <i>Photo Courtesy:</i> Ketan Parikh</p>	<ul data-bbox="586 1412 1024 1645" style="list-style-type: none"> <li>• Bilious vomiting</li> <li>• Distention and fluid levels dependent on level of obstruction more distal the obstruction, more the fluid levels and more the distention</li> <li>• Pale meconium may be passed.</li> </ul>	<ul data-bbox="1024 1412 1468 1584" style="list-style-type: none"> <li>• Correction of metabolic imbalance</li> <li>• Surgery</li> <li>• Prognosis good unless complicated or apple-peel atresia.</li> </ul>



Picture	Note	Management
<p><b>Low ARM—Male</b></p>  <p><b>Figure 20.4.15:</b> Ano-rectal malformations (ARM): Low anomaly in male—meconium on scrotal raphe (external fistula) Photo Courtesy: Ketan Parikh</p>	<ul style="list-style-type: none"> <li>• Diagnosis—clinical. External fistula in midline.</li> <li>• Important to confirm level of ano-rectal atresia.</li> <li>• Imaging studies—invertogram, etc. most useful after 24 hours.</li> <li>• Must rule out anomalies in urinary tract and spine.</li> </ul>	<p><i>Low anomalies:</i> Primary reconstruction (anoplasty)</p>
<p><b>Malrotation</b></p>  <p><b>Figures 20.4.16A and B:</b> Intestinal malrotation with midgut volvulus (Plain X-ray shows the double bubble but with distal gas) line diagram shows the bowel alignment in malrotation Photo Courtesy: Ketan Parikh</p>	<ul style="list-style-type: none"> <li>• Acute attack of bilious vomiting with scaphoid abdomen. Rapid deterioration in case of vascular compromise. There may be blood stained vomitus or meconium.</li> <li>• With onset of volvulus child may become pale and hypovolemic.</li> <li>• <i>Diagnosis:</i> Barium study shows duodenal obstruction, DJ flexure on right side of spine.</li> <li>• <i>D/D in a newborn:</i> Duodenal atresia - volvulus may show some distal gas pattern.</li> </ul>	<ul style="list-style-type: none"> <li>• Rapid metabolic correction with early surgery important to prevent midgut gangrene.</li> <li>• Absolute surgical emergency, should be operated within first few hours.</li> </ul>
<p><b>Meckel's Diverticulum</b></p>  <p><b>Figure 20.4.17:</b> Meckel's diverticulum (Meckel's radio-isotope scan: Hot spot near umbilicus). Photo Courtesy: Ketan Parikh, Arbinder Kumar Singal</p>	<ul style="list-style-type: none"> <li>• Profuse hematochezia, without pain—Meckel's scan may be positive.</li> <li>• Diverticulitis presents with pain, mimics appendicitis.</li> <li>• Intestinal obstruction.</li> <li>• Umbilical discharge.</li> <li>• Imaging not successful in all cases</li> <li>• Meckel's scan may show ectopic gastric mucosa</li> <li>• <i>Diagnostic lap:</i> Only diagnostic modality.</li> </ul>	<ul style="list-style-type: none"> <li>• In case of severe blood loss—blood transfusion may be required.</li> <li>• Surgical excision is the treatment of choice and this can be done laparoscopically.</li> </ul>

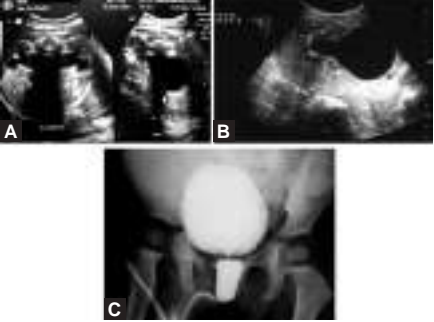
Picture	Note	Management
<p><b>Meconium Peritonitis</b></p>  <p><b>Figures 20.4.18A to C:</b> Meconium peritonitis clinical and radiological features as described Photo Courtesy: Ketan Parikh</p>	<ul style="list-style-type: none"> <li>• Abdominal distention, with intestinal obstruction, characteristic facies, abdominal wall staining.</li> <li>• <i>X-ray:</i> Central bowel with surrounding fluid.</li> <li>• Speckled calcification may be seen.</li> </ul>	<ul style="list-style-type: none"> <li>• Exploratory laparotomy with surgery for the primary cause of meconium peritonitis.</li> </ul>
<p><b>Necrotizing Enterocolitis</b></p>  <p><b>Figure 20.4.19:</b> Necrotizing enterocolitis (Intramural air) Photo Courtesy: Arbinder Kumar Singal</p>	<p>Mostly occurs in preterm babies but seen in full terms also.</p> <p><i>Clinical features:</i> Initial—Physiological deterioration—sick looking, distention, increased pre-feed residuals</p> <ul style="list-style-type: none"> <li>• <i>Later:</i> Vomiting—maybe bilious; abdominal distention; bleeding per rectum</li> <li>• <i>Diagnosis:</i> Clinical as above</li> <li>• <i>X-ray:</i> Pneumatosis intestinalis (intramural air), fixed loop or pneumoperitoneum or portal venous gas.</li> </ul>	<p>Surgical indications. Persistent fixed loop, tender loop. Evidence of perforation/gangrene. Portal venous gas pneumoperitoneum.</p>
<p><b>Peritonitis/Intestinal Obstruction</b></p>  <p><b>Figures 20.4.20A and B:</b> Intestinal obstruction Peritonitis: (A) Intestinal obstruction; (B) Peritonitis (thickened bowel wall and ground glass appearance below) Photo Courtesy: Ketan Parikh</p>	<ul style="list-style-type: none"> <li>• <i>Clinically:</i> Abdominal pain, distention, bilious vomiting, constipation.</li> <li>• <i>X-ray:</i> Fluid levels seen in both obstruction and peritonitis (Fig. 20.4.20A).</li> <li>• In case of peritonitis – ground glass appearance with fluid between bowel loops (Fig. 20.4.20B).</li> <li>• Perforated appendicitis is the most common cause of peritonitis in children also.</li> </ul>	<ul style="list-style-type: none"> <li>• Conservative treatment may be tried in early obstruction without peritonitis if pain is less.</li> <li>• <i>Surgical indications:</i> Severe pain, persistent symptoms, effect of peritonitis.</li> </ul>


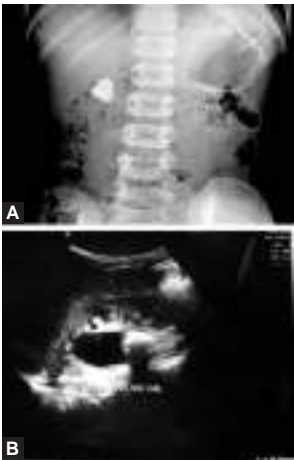

Picture	Note	Management
<p><b>Rectal Polyp</b></p>  <p><b>Figure 20.4.21:</b> Rectal polyp Photo Courtesy: Ketan Parikh</p>	<ul style="list-style-type: none"> <li>• Usually between the ages of 3 to 8 years.</li> <li>• The most common cause of painless fresh bleed per rectum in this age group.</li> <li>• <i>Symptoms:</i> Fresh bleeding, trickle with or after stools. Polyp may prolapse intermittently.</li> </ul>	<ul style="list-style-type: none"> <li>• Sigmoidoscopy with polypectomy.</li> </ul>




<p><b>Rectovestibular Fistula (RVF)</b></p>  <p><b>Figure 20.4.22:</b> Rectovestibular fistula Photo Courtesy: Ketan Parikh</p>	<ul style="list-style-type: none"> <li>• Diagnosis is based on clinical examination—absent anal opening and fistula seen within fourchette behind vaginal opening.</li> <li>• Intermediate anomaly in female but generally wide external fistula so usually no emergency.</li> </ul>	<ul style="list-style-type: none"> <li>• Single stage repair usually preferred. Outcome—good.</li> <li>• If the fistula is narrow and child is not decompressing well—staged repair may be required.</li> <li>• Only cut-back—not recommended.</li> </ul>
---	--	---


## 20.5 PEDIATRIC UROLOGICAL CONDITIONS


### Antenatally Diagnosed Hydronephrosis —Bilateral (PUV)

 <p><b>Figures 20.5.1A to C:</b> Antenatal hydronephrosis—bilateral Photo Courtesy: Arbinder Kumar Singal</p>	<ul style="list-style-type: none"> <li>• Most common cause of bilateral HDN is posterior urethral valves in male babies.</li> <li>• Classical antenatal sonography findings are bilateral hydroureteronephrosis (Fig. 20.5.1A)distended bladder and posterior urethra (Key hole sign) (Fig. 20.5.1B).</li> </ul>	<ul style="list-style-type: none"> <li>• Regular antenatal follow-up.</li> <li>• Bad prognostic signs—oligohydramnios, echogenic kidneys with thin cortex.</li> <li>• Oligohydramnios after 32 weeks—early delivery.</li> <li>• Postnatal catheterization is done on day 1 and MCU to confirm the diagnosis soon thereafter MCU picture of PUV (Fig. 20.5.1C).</li> </ul>
--	--	---


Picture	Note	Management
<p data-bbox="126 212 911 247"><b>Antenatally Diagnosed Hydronephrosis (ADH)—Unilateral</b></p>  <p data-bbox="138 602 557 701"><b>Figure 20.5.2:</b> Antenatal hydronephrosis—Unilateral left kidney shows dilated pelvis and calyces while right kidney is normal <i>Photo Courtesy:</i> Arbinder Kumar Singal</p>	<ul data-bbox="605 271 1008 602" style="list-style-type: none"> <li>• ADH is very common disorder occurring in up to 1% of all pregnancies.</li> <li>• For unilateral hydronephrosis the most common cause is pelvi-ureteric junction obstruction followed by vesicoureteric reflux.</li> <li>• Up to 70% of these may be mild and resolve before birth or within first few months after birth.</li> </ul>	<ul data-bbox="1049 271 1458 602" style="list-style-type: none"> <li>• Antenatal counseling by a pediatric urologist/surgeon is very important.</li> <li>• In unilateral hydronephrosis, the prognosis is very good and a post-natal USG should be done at 5 to 7 days of age.</li> <li>• Regular follow-up to ascertain resolution is a must in first year of life.</li> </ul>
<p data-bbox="126 727 220 762"><b>Calculi</b></p>  <p data-bbox="138 1269 548 1346"><b>Figures 20.5.3A and B:</b> Urolithiasis (Urinary calculi) <i>Photo Courtesy:</i> Arbinder Kumar Singal</p>	<p data-bbox="605 793 997 854">Urinary calculi have become more common in childhood.</p> <p data-bbox="605 864 732 895">Symptoms:</p> <ul data-bbox="605 901 1008 1248" style="list-style-type: none"> <li>• Pain—lumbar region due to renal or a pelvic calculus (Figs 20.5.3A and B).</li> <li>• Colicky pain with radiation from loin to groin- ureteric calculus.</li> <li>• Pain suprapubic with dysuria—bladder calculus.</li> <li>• Hematuria.</li> <li>• Lower urinary symptoms such as frequency, dysuria, etc.</li> </ul> <p data-bbox="605 1259 727 1289">Diagnosis:</p> <ul data-bbox="605 1295 971 1381" style="list-style-type: none"> <li>• Plain X-ray KUB (Fig. 20.5.3A)</li> <li>• Non-contrast thin cut CT, USG KUB (Fig. 20.5.3B).</li> </ul>	<ul data-bbox="1049 793 1435 1197" style="list-style-type: none"> <li>• Renal calculi-lithotripsy (ESWL) or percutaneous nephrolithotomy.</li> <li>• Ureteric calculi—less than 6 mm—wait and watch, alpha blockers; more than 6 mm—ureterorenoscopy.</li> <li>• <i>Bladder calculi:</i> Percutaneous laser cystolithotripsy or open surgery.</li> <li>• Metabolic work-up is a must for all children.</li> </ul>
<p data-bbox="126 1406 602 1441"><b>Disorder of Sex Development (DSD)</b></p>  <p data-bbox="138 1645 561 1800"><b>Figures 20.5.4A and B:</b> Disorder of sex development (DSD) or intersex. (A) Child with CAH and virilization, no gonads palpable; (B) Child with mixed gonadal dysgenesis—severe hypospadias and undescended testis <i>Photo Courtesy:</i> Arbinder Kumar Singal</p>	<p data-bbox="605 1467 919 1498">Suspect DSD when there is:</p> <ul data-bbox="605 1504 1013 1749" style="list-style-type: none"> <li>• Ambiguous genitalia (Fig 20.5.4A)</li> <li>• Clitoromegaly</li> <li>• Hypospadias with undescended testis (Fig. 20.5.4B)</li> <li>• Severe hypospadias</li> <li>• Bilateral nonpalpable undescended testis.</li> </ul> <p data-bbox="605 1759 1008 1915">Most common cause of DSD is congenital adrenal hyperplasia in which karyotype is 46XX but due to excessive androgens—virilization occurs.</p>	<p data-bbox="1049 1467 1166 1498"><i>Diagnosis:</i></p> <ul data-bbox="1049 1504 1458 1647" style="list-style-type: none"> <li>• Karyotype.</li> <li>• Serum 17-OH progesterone levels are high in CAH.</li> <li>• USG to see for internal genitalia.</li> </ul> <p data-bbox="1049 1657 1206 1688"><i>Management:</i></p> <ul data-bbox="1049 1694 1458 1898" style="list-style-type: none"> <li>• Gender assignment surgery based on size of phallus, sex of rearing, internal genitalia and fertility potential.</li> <li>• Counseling and team management very important.</li> </ul>

Picture	Note	Management
 <p><b>Figure 20.5.5:</b> Epispadias Photo Courtesy: Arbinder Kumar Singal</p>	<ul style="list-style-type: none"> <li>• Urethral meatus is on the dorsal aspect of penis and there may be associated dorsal curvature—dorsal chordee.</li> <li>• As compared to hypospadias—incidence is 100 times less.</li> <li>• May be associated with incontinence in severe varieties.</li> </ul>	<ul style="list-style-type: none"> <li>• Urethroplasty is recommended before one year of age.</li> <li>• Children with incontinence may require more extensive surgical procedure including bladder neck reconstruction.</li> </ul>
 <p><b>Figures 20.5.6A and B:</b> Exstrophy Photo Courtesy: Arbinder Kumar Singal</p>	<ul style="list-style-type: none"> <li>• Defect in the lower anterior abdomen wall and bladder so that bladder lies open and exposed.</li> <li>• Continuous urine leak and excoriation occurs.</li> <li>• Diagnosis can be made antenatally as no bladder can be seen on scans.</li> </ul>	<ul style="list-style-type: none"> <li>• Diagnosis is self-evident.</li> <li>• <i>Management:</i> Closure of bladder in one stage or staged procedure should be started in first few days of life itself.</li> <li>• Multiple procedures may be required to achieve continence.</li> </ul>
 <p><b>Figures 20.5.7A and B:</b> Hypospadias Photo Courtesy: Arbinder Kumar Singal</p>	<ul style="list-style-type: none"> <li>• Common congenital anomaly—urethral meatus is on the underside of penis.</li> <li>• More proximal the meatus, more severe the hypospadias.</li> <li>• Most of the cases have associated ventral curvature of penis called chordee.</li> <li>• Diagnosis can be easily made at birth as the defect is easily visible.</li> </ul> <p>Isolated hypospadias does not require any diagnostic tests except children with associated genital ambiguity, undescended testis or micropenis.</p>	<ul style="list-style-type: none"> <li>• Corrective surgery is best done between 6 months to 1 year of age.</li> <li>• Most of the cases can be managed with single stage urethroplasty except severe varieties or the ones with severe chordee.</li> <li>• Surgical outcomes are excellent from functional and cosmetic view with newer techniques.</li> </ul>

Picture	Note	Management
<p><b>Neuropathic Bladder</b></p>  <p><b>Figure 20.5.8:</b> Child with neuropathic bladder postsurgery for spina bifida. Always look at spine when a child comes with urinary problems Photo Courtesy: Arbinder Kumar Singal</p>	<p><i>Symptoms:</i></p> <ul style="list-style-type: none"> <li>• Incontinence, straining, wetting, recurrent urinary infections.</li> <li>• Usually associated problems with defecation also such as incontinence or soiling.</li> <li>• Seen in spina bifida, meningomyelocele, sacral agenesis, cerebral palsy, etc.</li> <li>• Always examine spine, lower limbs with any child with urinary symptoms, constipation to avoid missing.</li> </ul>	<ul style="list-style-type: none"> <li>• <i>Diagnosis:</i> Clinical history, USG, MCU and urodynamics.</li> <li>• MRI for nervous system defects.</li> <li>• <i>Management:</i> Individualized—may include – Anticholinergics, Clean intermittent catheterization, prophylactic antibiotics and bladder augmentation surgeries.</li> </ul>
<p><b>Pelvi-ureteric Junction Obstruction</b></p>  <p><b>Figures 20.5.9A and B:</b> Pelvi-ureteric junction obstruction Photo Courtesy: Arbinder Kumar Singal</p>	<ul style="list-style-type: none"> <li>• Most of these cases of PUJ obstruction are diagnosed antenatally now, less than 10% present later.</li> </ul> <p>Common postnatal symptoms are:</p> <ul style="list-style-type: none"> <li>• Flank lump (Fig. 20.5.9A)</li> <li>• Pain</li> <li>• UTI</li> <li>• Hematuria after minor trauma.</li> </ul>	<p><i>Diagnosis:</i></p> <ul style="list-style-type: none"> <li>• Clinical exam of a renal lump.</li> <li>• Ultrasound showing distended pelvis with thinning of cortex (Fig. 20.5.9B).</li> <li>• Diuretic renal scan (DTPA/EC or MAG3) showing obstruction.</li> </ul> <p><i>Treatment:</i> Pyeloplasty which can be done laparoscopically in current era.</p>
<p><b>Testicular Torsion</b></p>  <p><b>Figures 20.5.10A and B:</b> Testicular torsion Photo Courtesy: Arbinder Kumar Singal</p>	<p><i>Symptoms:</i></p> <ul style="list-style-type: none"> <li>• Sudden pain and swelling of scrotum (Fig. 20.5.10A).</li> <li>• Age first few years or prepubertal.</li> <li>• Affected testis rides higher and is scrotum is red and tender.</li> <li>• Absence of cremasteric reflex is diagnostic.</li> <li>• <i>Diagnosis:</i> Mainly clinical but if available in emergency—USG Doppler or nuclear scan for blood flow may help.</li> <li>• Any doubt: Surgical exploration should be done (Fig. 20.5.10B).</li> </ul>	<ul style="list-style-type: none"> <li>• Emergency scrotal exploration.</li> <li>• If torsion is confirmed, detorsion to restore blood supply is the first step. Chances of testicular salvage decrease drastically after 4 hours of onset of symptoms and torsion is thus an absolute surgical emergency. If there is no return of blood supply, orchiectomy is done.</li> <li>• Twenty percent of the contralateral testis have anatomic predisposition to torsion so contralateral orchiopexy is done at the same time.</li> </ul>


Picture	Note	Management
 <p><b>Figure 20.5.11:</b> USG of a child with ureterocele. Kidney shows a duplex system and USG of bladder shows a ureterocele at ureterovesical junction Photo Courtesy: Arbinder Kumar Singal</p>	<p><b>Definition:</b> A ureterocele is a cystic out-pouching of the distal ureter into the urinary bladder.</p> <p><b>Symptoms:</b></p> <ul style="list-style-type: none"> <li>• Bladder outlet obstruction.</li> <li>• Urinary infections.</li> </ul> <p><b>Diagnosis:</b></p> <ul style="list-style-type: none"> <li>• Ultrasound is the diagnostic investigation of choice.</li> <li>• MCU is done to check for anatomy and associated reflux.</li> <li>• Renal scan is important to assess function of associated renal moiety.</li> </ul>	<ul style="list-style-type: none"> <li>• Observation for small incidentally discovered ureteroceles with good renal function and no obstruction.</li> <li>• Symptomatic or obstructed ureteroceles—symptomatic – cystoscopy and deroofing.</li> <li>• In some cases open bladder surgery or reimplantation of ureters may be required.</li> </ul>

### Vesicoureteric Reflux (VUR)

 <p><b>Figure 20.5.12:</b> Vesicoureteric reflux (VUR) Photo Courtesy: Arbinder Kumar Singal</p>	<p><b>Clinical features:</b></p> <ul style="list-style-type: none"> <li>• Antenatal hydronephrosis, urinary infections, dysfunctional voiding</li> <li>• Culture positive UTI in first year of life mandates a MCU to rule out reflux.</li> </ul> <p><b>Diagnosis:</b></p> <ul style="list-style-type: none"> <li>• Urine culture showing &gt;10<sup>5</sup> bacteria per ml.</li> <li>• USG may show mild hydroureteronephrosis.</li> <li>• Micturating cystourethrogram (MCU) is the diagnostic test.</li> </ul>	<ul style="list-style-type: none"> <li>• Prevention of UTI, constipation, dysfunctional voiding, phimosis, etc.</li> <li>• Surgery is required only if there are breakthrough UTI's.</li> </ul>
--	--	---


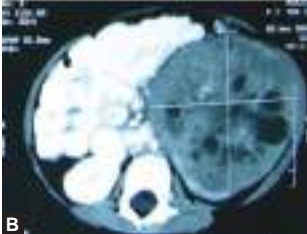
## 20.6 SOLID TUMORS OF CHILDHOOD

### Neuroblastoma

 <p><b>Figures 20.6.1A and B:</b> (A) Shows subconjunctival hemorrhages—so called Panda eyes; (B) CECT shows large heterogenous mass on right side Photo Courtesy: Arbinder Kumar Singal</p>	<p><b>Symptoms:</b></p> <ul style="list-style-type: none"> <li>• Lump abdomen, may cross midline, lump is firm and irregular.</li> <li>• <i>Others:</i> Weight loss, Panda eyes, metastatic nodules, diarrhea, (Fig. 20.6.1A) opsoclonus myoclonus.</li> <li>• <b>Diagnosis and staging:</b> USG/ CECT abdomen (Fig. 20.6.1B) urinary catecholamines, MIBG scan, bone marrow smear/biopsy.</li> </ul>	<ul style="list-style-type: none"> <li>• Surgery if resectable.</li> <li>• Neoadjuvant chemotherapy followed by surgery if unresectable and then depending on residue postoperative chemotherapy.</li> <li>• Stage 4S in newborns generally does not need therapy.</li> </ul>
---	---	---

Picture	Note	Management
<p><b>Sacroccygeal Teratoma</b></p>  <p><b>Figure 20.6.2:</b> Sacroccygeal teratoma Photo Courtesy: Manish Jain</p>	<p>Mass arising from the tip of coccyx—almost always seen at birth—pushes anus anteriorly (Fig. 20.6.2).</p>	<ul style="list-style-type: none"> <li>• Early excision with perineal reconstruction prevents malignant transformation.</li> <li>• Prognosis good.</li> </ul>

### Wilms' Tumor

 <p><b>A</b></p>  <p><b>B</b></p> <p><b>Figures 20.6.3A and B:</b> (A) Shows a left renal lump; (B) CECT abdomen shows a well defined large heterogeneous left renal mass Photo Courtesy: Arbinder Kumar Singal</p>	<p><i>Age group:</i> 1 to 5 years</p> <p><i>Symptoms:</i></p> <ul style="list-style-type: none"> <li>• Most common—lump abdomen (Fig. 20.6.3A)</li> <li>• Failure to thrive</li> <li>• Hematuria in 10%.</li> </ul> <p><i>Diagnosis:</i></p> <ul style="list-style-type: none"> <li>• USG/ CECT scan (Fig. 20.6.3B)</li> <li>• Metstatic work-up—lungs- CECT scan/bones—bone scan.</li> </ul>	<ul style="list-style-type: none"> <li>• Stage 1 and 2 resectable—followed by chemotherapy.</li> <li>• Stage 3 and 4—Neoadjuvant chemotherapy followed by surgery and then chemotherapy and radiotherapy.</li> </ul>
--	---	--





# Section 21

---

# Orthopedics

***Section Editor***  
K Sriram, Vijay Sriram

***Photo Courtesy***  
K Sriram, Vijay Sriram

- 
- 21.1 Common Conditions
  - 21.2 Uncommon Conditions but not Rare
  - 21.3 Emergencies
  - 21.4 Syndromes

## SECTION OUTLINE

### 21.1 COMMON CONDITIONS 449

- ◆ Chronic Osteomyelitis 449
- ◆ Congenital Talipes Equinovarus (Clubfoot) 449
- ◆ Developmental Dysplasia of Hip (DDH) 449
- ◆ Early Perthes' Disease 450
- ◆ Early Tuberculosis of the Spine 450
- ◆ Erb's Palsy 451
- ◆ Intoeing 451
- ◆ Mobile Flat Feet 451
- ◆ Physiological Bow Legs 452
- ◆ Physiological Genu Valgum 452

### 21.2 UNCOMMON CONDITIONS BUT NOT RARE 452

- ◆ Blount's Disease (Tibia Vara) 452
- ◆ Congenital Dislocation of the Knee 453
- ◆ Congenital Pseudarthrosis of Tibia 453
- ◆ Congenital Scoliosis with Skin Marker 453
- ◆ Congenital Vertical Talus 454

- ◆ Fibular Hemimelia 454
- ◆ Idiopathic Scoliosis 454
- ◆ Muscular Torticollis 455
- ◆ Osteogenesis Imperfecta 455
- ◆ Proximal Femoral Focal Deficiency 455
- ◆ Sarcoma of Bone 456
- ◆ Solitary Bone Cyst 456
- ◆ Spondylolisthesis 456

### 21.3 EMERGENCIES 457

- ◆ Acute Osteomyelitis 457
- ◆ Acute Septic Arthritis 457
- ◆ Supracondylar Fracture Humerus 457
- ◆ Slipped Capital Femoral Epiphysis (SCFE) 458

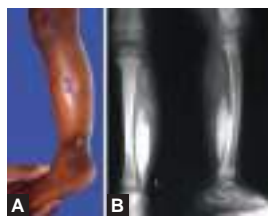### 21.4 SYNDROMES 458

- ◆ Arthrogryposis Multiplex Congenital 458
- ◆ Enchondromatosis 458
- ◆ Hereditary Multiple Exostosis 459

## 21.1 COMMON CONDITIONS

Picture	Note	Management
---------	------	------------

### Chronic Osteomyelitis

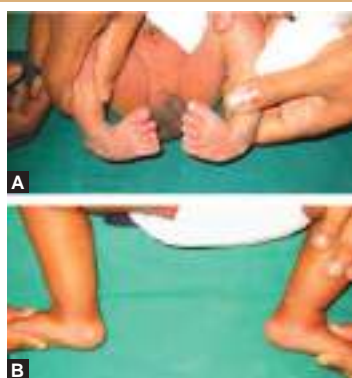


**Figures 21.1.1A and B:** Chronic osteomyelitis  
Photo Courtesy: K Sriram, Chennai

Patient may present with sinuses, which are adherent to the bone. Granulation tissue may be protruding from the sinus. Bone is thickened. X-ray reveals sequestrum surrounded by involucrum. A part of the long bone may be absent if the periosteum has been destroyed by infection.

Treatment consists of removal of the infected tissues and the sequestrum (sequestrectomy). The dead space created by surgery is filled with overlying soft tissues. Appropriate antibiotics are administered during surgery.

### Congenital Talipes Equinovarus (Clubfoot)

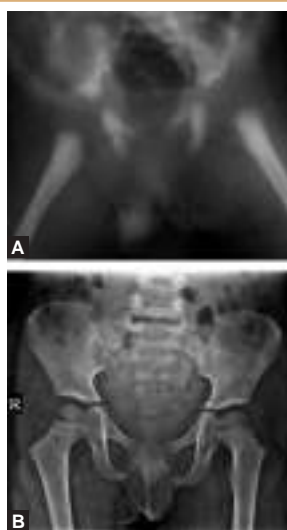

**Figures 21.1.2A and B:** Congenital talipes equinovarus (Clubfoot)  
Photo Courtesy: Vijay Sriram, Chennai

Clubfoot is probably the most common (1–2 in 1000 live births) congenital orthopedic condition requiring treatment. Idiopathic clubfoot represents a primary but local dysplasia of all tissues of the affected extremity from the knee down. Syndromic club feet are associated with various conditions like arthrogryposis, spina bifida, Streeter's dysplasia, etc. Diagnosis is obvious with the heel being in equinus and varus and the forefoot being supinated. The hips and spine should always be examined.

The Ponseti method is the most common mode of treatment. It consists of serial weekly stretching casts from the 5 to 7<sup>th</sup> day of life followed by a tendo achilles tenotomy after 5 to 6 casts. The child has to use a foot abduction brace for 4 months following the correction 24 hours a day. Night bracing is then continued till 3 years of age. The resistant and syndromic feet may require a combination of soft tissue releases, osteotomies and external fixators to correct the deformity. The syndromic feet tend to recur more often than the idiopathic feet.

### Developmental Dysplasia of Hip (DDH)



**Figures 21.1.3A and B:** Developmental Dysplasia of Hip (DDH)  
Photo Courtesy: Vijay Sriram, Chennai

Covers a wide range of abnormalities ranging from mild defects of acetabulum to subluxation, dislocation and teratologic dislocation of the hip. The common etiology is excessive laxity of the hip capsule, with failure to maintain the femoral head within the acetabulum. The syndrome in the newborn consists of instability of the hip, such that the femoral head can be displaced partially (subluxated) or fully (dislocated) from the acetabulum by an examiner. The hip may also rest in a dislocated position and be reducible on examination. Over time, the femoral head becomes fully dislocated and cannot be reduced by changing the position of the hip. In a walking child, an obvious limp will be present and in bilateral cases a waddling gait will be present. Associated conditions are torticollis (20%), and metatarsus adductus.

In the neonate, ultrasonography is useful to confirm the clinical diagnosis. In older children radiographs will confirm the diagnosis.

#### Treatment:


**Neonate:** Pavlik harness for 6 weeks. Reduction is monitored with regular ultrasound scans.

**1 to 6 months:** Pavlik harness or a closed reduction and spica immobilization for up to 8 weeks.


**6 to 18 months:** Closed or open reduction and spica casting for 4 months.


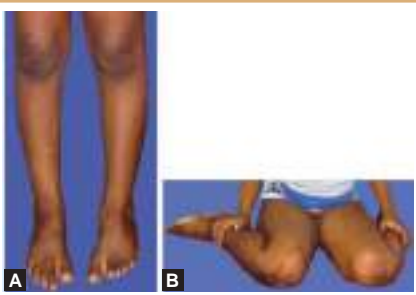

**18 to 36:** Open reduction with femoral shortening, and selective acetabular osteotomy.


**36 months-6 years:** Open reduction, femoral shortening and acetabular osteotomy.

Picture	Note	Management
<p data-bbox="152 216 448 247"><b>Early Perthes' Disease</b></p>  <p data-bbox="164 1111 597 1187"><b>Figures 21.1.4:</b> (A) Early stage of AVN right hip; (B) Stage of fragmentation <i>Photo Courtesy: Vijay Sriram, Chennai</i></p>	<p data-bbox="626 273 1015 431">Legg-Calvé-Perthes disease is a condition in which there is a temporary avascular necrosis of the capital epiphysis (head) of the femur.</p> <p data-bbox="626 441 1036 762">The disease is of variable severity, and bilateral involvement occurs in approximately 10 to 12% of patients. The disorder is most prevalent in children 4 to 12 years of age. It is more common in boys than in girls by a ratio of 4 or 5 to 1. The etiology of perthe's disease is unknown, but the disorder may be due to a silent coagulopathy in some individuals.</p> <p data-bbox="626 772 1036 1310">The symptoms are a limp that is exacerbated by activity and relieved with rest; pain, which may be located in the groin or anterior hip region. The signs are an abductor limp and restricted abduction and internal rotation of the hip. Radiological features in the early stage are the femoral head becomes uniformly dense and reduces in height. A subchondral fracture may be present. It then goes into the fragmentation stage where multiple lucencies are seen. Differential diagnosis includes sickle cell anemia, hypothyroidism, and skeletal dysplasias.</p>	<p data-bbox="1070 273 1463 656">Initial management should focus on pain relief, with a reduction in activities and the use of anti-inflammatory medications, and short periods of bed rest for major episodes of pain or loss of joint motion. In children over 8 years of age in the early stages surgical containment of the femoral head should be done. This is achieved either by femoral varus osteotomy or an acetabular procedure.</p>


### Early Tuberculosis of the Spine

 <p data-bbox="164 1806 573 1882"><b>Figures 21.1.5A and B:</b> Early tuberculosis of the spine <i>Photo Courtesy: K Sriram, Chennai</i></p>	<p data-bbox="626 1483 1027 1800">Painful spinal deformity should raise the suspicion of organic disease of the spine. (Infection or tumor). The most common infection is tuberculosis. X-ray in the early stages is normal. MRI reveals destruction of the spine with paravertebral soft tissue mass. CT guided biopsy is performed to confirm the diagnosis.</p>	<p data-bbox="1070 1483 1463 1704">Administration of antituberculous therapy according to the protocol for spinal tuberculosis leads to quiescence of the disease. Rarely, progressive destruction or the occurrence of neurological deficit may require surgery.</p>
---	--	---

Picture	Note	Management
<p><b>Erb's Palsy</b></p>  <p><b>Figures 21.1.6A and B:</b> Erb's Palsy Photo Courtesy: K Sriram, Chennai</p>	<p>This may occur due to shoulder dystocia during vaginal delivery. The babies are often large in proportion to pelvic outlet. It also occurs during breech delivery and even after cesarian section. Injury to C5 and C6 roots occur at Erb's point in the brachial plexus. There is loss of abduction and external rotation of shoulder, loss of elbow flexion and a wristdrop.</p> <p>Partial recovery results in deformities such as internal rotation contractures and posterior dislocation of the shoulder.</p>	<p>Recovery depends on the severity. Spontaneous recovery occurs in 90% of patients. Treatment starts in the neonatal period. Passive movements of all joints are performed to prevent contractures. Nonrecovery of biceps function at 4 months of age indicates poor prognosis. Nerve grafting is necessary without much delay.</p> <p>They need release of contractures and tendon transfer.</p>
<p><b>Intoeing</b></p>  <p><b>Figures 21.1.7A and B:</b> Intoeing Photo Courtesy: K Sriram, Chennai</p>	<p>Excessive femoral torsion is the most common cause of intoeing in children. It is often familial, common in girls and symmetrical. Children present between 4 to 6 years of age. Child sits in W position. Internal rotation of hips in prone position is 60 to 70 degrees. The condition resolves by 10 years of age.</p>	<p>Attempts to correct the way the child sits or walk is impossible. Braces are ineffective. Observational management is the best. About 1% fails to remodel. This may require osteotomy in later childhood.</p>
<p><b>Mobile Flat Feet</b></p>  <p><b>Figures 21.1.8A and B:</b> Mobile flat feet Photo Courtesy: Vijay Sriram, Chennai</p>	<p>One of the most common "deformities" evaluated by pediatric orthopedists. In flexible flat feet there is a decrease in the height of the medial longitudinal arch of the foot with a midfoot sag. It can be associated with a tight tendo-achilles tendon. Restoration of the arch occurs in the nonweight bearing position and when the child stands on the toes. Rigid flat feet are seen in vertical talus, tarsal coalitions, neurological and myopathic conditions. In majority of the cases apart from the deformity there are no symptoms. Occasionally these children can complain of pain.</p>	<p>Hypermobile flatfoot does not require treatment. If an Achilles tendon contracture is present, it should be stretched vigorously because of the possibility that symptoms might arise later. Nonoperative management of painful flatfeet in adolescents is generally successful and entails shoe modifications (running shoes suffice for this purpose), orthoses and stretching and strengthening exercises. Surgical correction is a last resort for this condition, and includes lateral column lengthening or a calcaneal medial sliding osteotomy, often combined with medial soft tissue imbrication, to provide symptomatic relief by realigning the subluxated talo naviculocuneiform complex.</p>


Picture	Note	Management
<p><b>Physiological Bow Legs</b></p>  <p><b>Figures 21.1.9A to C:</b> Physiological bow legs Photo Courtesy: K Sriram, Chennai</p>	<p>They are most obvious in the 2<sup>nd</sup> year and disappear by the 3<sup>rd</sup> year. The deformity is symmetrical and the children are of normal stature. It involves both femur and tibia. Femoral and tibial torsion may be associated with it. Lateral thrust on walking may be present. X-ray reveals medial beaking of tibia. If the lower two-thirds of tibia is covered with a cardboard, the knee will appear to be in valgus (Hide test).</p>	<p>The condition corrects spontaneously. Braces are unnecessary. The progress is monitored by measuring the intercondylar distance at intervals of 6 months. The genu varum may change to genu valgum at 3 years and then settle to normal valgus by 7 years of age. The parents need counseling regarding the natural history of genu varum.</p>

### Physiological Genu Valgum

 <p><b>Figure 21.1.10:</b> Physiological genu valgum Photo Courtesy: K Sriram, Chennai</p>	<p>The deformity is noticed between 3 to 5 years of age. Gradual correction to mild valgus occurs by 9 years of age in the vast majority. Patients are of normal stature. Family history of flatfeet may be present. Metabolic workup is needed if rickets is suspected. Unilateral genu valgum occurs in pathological conditions.</p>	<p>The progress is monitored by measuring the intermalleolar distance at 6 monthly intervals. Rarely, the condition persists. If the intermalleolar distance exceeds 15 cm, surgery is performed. (hemiepiphyseal arrest by stapling or guided growth plate). The procedure is a successful one.</p>
--	--	--




## 21.2 UNCOMMON CONDITIONS BUT NOT RARE




### Blount's Disease (Tibia Vara)




 <p><b>Figures 21.2.1A and B:</b> (A) Bilateral Blount's in a 3 years old; (B) 1 year following surgery Photo Courtesy: Vijay Sriram, Chennai</p>	<p>Tibia vara is defined as growth retardation at the medial aspect of the proximal tibial epiphysis and physis. It usually results in progressive or at least persistent bowlegs. The children are usually obese and bowlegs persist beyond 3 years of age. Very often there will be a lateral thrust of the involved knee in the stance phase.</p> <p>Radiographic findings are a prominent metaphyseal beak with lucencies, lateral subluxation of the tibia, widened and irregular physal line and a medially sloped and irregular epiphysis. In the later stages there will be bony physal bars and epiphysal damage.</p>	<p>In the early stages, in children below 3 years bracing is useful. If bracing fails, corrective osteotomy in children below 3 years in the early stages can cause resolution of the disease.</p> <p>In later stages mechanical axis correction has to be combined with excision of bony bridges and epiphysal osteotomies.</p> <p>Recurrence is more common when treatment is begun in the later stages of the disease.</p>
--	--	---

Picture	Note	Management
<p><b>Congenital Dislocation of the Knee</b></p>  <p><b>Figures 21.2.2A and B:</b> Congenital dislocation of the knee  <i>Photo Courtesy:</i> K Sriram, Chennai</p>	<p>This anomaly can occur in breech presentation. The tibia is dislocated anterolaterally. The femoral condyles are felt in the popliteal fossa. It is often associated with club feet and dysplasia of hips. The condition can be a part of arthrogryposis, Larsen syndrome, etc.</p>	<p>Closed reduction of the dislocation is usually successful in early infancy. This is achieved by stretching and casting the knee in flexion. Quadriceps lengthening is performed in cases of irreducible dislocations.</p>
<p><b>Congenital Pseudarthrosis of Tibia</b></p>  <p><b>Figures 21.2.3A and B:</b> Congenital pseudarthrosis of tibia  <i>Photo Courtesy:</i> K Sriram, Chennai</p>	<p>This disease manifests with anterolateral bowing of tibia. Neurofibromatosis is present in 50% of patients. It is almost always unilateral. Fractures occur within the first 2 years of life.</p>	<p>It is difficult to obtain union of the pathological fracture. Surgical treatment options are: (1) Intra-medullary rodding and bone grafting (2) Vascularized fibula transfer (3) Syme amputation and prosthesis. If surgical treatment results in repeated failures and gross shortening, Syme amputation and prosthetic fitting helps in early rehabilitation of the child. Further, psychological damage due to repeated surgery to the child is reduced.</p>
<p><b>Congenital Scoliosis with Skin Marker</b></p>  <p><b>Figures 21.2.4A and B:</b> Congenital scoliosis with skin marker  <i>Photo Courtesy:</i> K Sriram, Chennai</p>	<p>This develops due to malformation of the vertebrae. (Failure of formation, failure of segmentation or a combination of both). The spine develops at the same time as major organs. Genitourinary anomalies, cardiac anomalies and spinal cord abnormalities may be associated with it. X-ray shows the type and severity of the abnormality. Renal ultrasound, echocardiogram and MRI of the spine are performed during evaluation of the patient. Hair patch in the back indicates the presence of intraspinal anomaly.</p>	<p>The goal is to obtain a balanced spine at the end of growth. In young children, expansion of the chest and lung development is an important consideration. Progressive deformities are treated by surgery. The procedure varies according to the age of the child, type and severity of the deformity. Surgery should be performed early, as soon as progression is documented. Correction of large deformities is complicated.</p>







Picture	Note	Management
<p><b>Congenital Vertical Talus</b></p>  <p><b>Figures 21.2.5A and B:</b> Congenital vertical talus Photo Courtesy: K Sriram, Chennai</p>	<p>A rigid flat foot where the foot is boat shaped (Rocker bottom foot). The talus is felt on the plantar aspect. The medial border is convex. It can be unilateral or bilateral. Normal children can be affected with it or it can be a part of arthrogryposis, spina bifida or chromosomal anomaly. The navicular is dislocated on the dorsolateral aspect of the talus. X-ray shows the talus in vertical position and it does not change in plantar flexion of the foot.</p>	<p>The treatment is started in early infancy. The foot is stretched into equino varus and casted at weekly intervals for 6 to 8 weeks. Open reduction of talonavicular joint is performed. In syndromic children, the deformity is prone to recurrence.</p>
<p><b>Fibular Hemimelia</b></p>  <p><b>Figures 21.2.6A to C:</b> Fibular hemimelia Photo Courtesy: K Sriram, Chennai</p>	<p>Most common congenital absence of long bone. It can be partial or complete absence of fibula. The lateral rays of the foot can be absent. The foot may or may not have deformity. Congenital anomalies of the femur or the hip may be associated with it. The knee joint may have laxity of the ligaments. The shortening of the leg is variable.</p>	<p>Extreme shortening of the limb associated with a bad deformity of the foot is treated by early Syme's amputation and prosthesis. Early prosthetic fitting results in good function. Moderate shortening of the limb is treated by limb lengthening.</p>
<p><b>Idiopathic Scoliosis</b></p>  <p><b>Figures 21.2.7A and B:</b> Idiopathic scoliosis Photo Courtesy: K Sriram, Chennai</p>	<p>It is the commonest type of scoliosis after 10 years of age. Affected girls versus boys ratio is 10:1. Right thoracic curve is the commonest deformity. The patients are brought for asymmetry of shoulders, rib hump or uneven waist. The deformity progresses during growth.</p>	<p>This depends on the magnitude of the curve and the skeletal maturity of the patient. Immature children with flexible curves between 25 to 40 degrees are treated in braces. Braces prevent progression of deformity. Surgery is performed in patients with curves larger than 50 degrees. The goal of surgery is to obtain spinal balance (Level shoulders, level pelvis and normal sagittal profile). Spinal fusion of the structural curve is performed with instrumentation. The surgical approach to the spinal deformity correction can be posterior, anterior or combined. This decision is individualized.</p>

Picture	Note	Management
<p><b>Muscular Torticollis</b></p>  <p><b>Figures 21.2.8A and B:</b> Muscular torticollis <i>Photo Courtesy: K Sriram, Chennai</i></p>	<p>This occurs due to the contracture of one or both heads of sternomastoid. The condition often manifests in childhood with tilt of the head. The sternomastoid feels tight and the neck movements are limited. Asymmetry of the face may develop and increases with growth.</p>	<p>Surgery is essential to correct the deformity. The contracted muscle is released at both ends (Bipolar release). The correction is maintained by postoperative physiotherapy for 3 months.</p>
<p><b>Osteogenesis Imperfecta</b></p>  <p><b>Figures 21.2.9A to C:</b> Osteogenesis imperfecta <i>Photo Courtesy: K Sriram, Chennai</i></p>	<p>It is a genetic disorder resulting in fragility of the entire skeleton. It varies in severity from an infant with multiple fractures to an adolescent with a few fractures. The variation in clinical features is due to mutation of the gene. Bones, ligaments, dentine and the sclera show changes due to the defect in type I collagen. Diagnosis is made from clinical and radiological features. Patients are short stature. The bones are deformed. Ligaments are lax. Dentine may be translucent. Sclerae may be blue.</p>	<p>Bisphosphonates have been used for some years. They decrease osteoclastic resorption and increase bone density. Thus, fracture rate is reduced.</p> <p>Patients receiving pamidronate (bisphosphonate) will demonstrate lines of increased bone density with each administration.</p> <p>Surgery is indicated in patients with diaphyseal deformities and those with multiple fractures. Multiple osteotomies are performed and the bone is threaded on an intramedullary rod.</p>
<p><b>Proximal Femoral Focal Deficiency</b></p>  <p><b>Figures 21.2.10A and B:</b> Proximal femoral focal deficiency <i>Photo Courtesy: K Sriram, Chennai</i></p>	<p>This is due to a developmental failure of proximal femur and the hip. It varies in severity from a short femur to complete absence of the proximal femur and the acetabulum. The leg and foot on the affected side may or may not be normal. The shortening of the femur is variable. Often, the foot on the involved side is opposite the knee on the other side.</p>	<p>Children with gross shortening benefit by extension prosthesis. Sometimes, severe deformity of the foot will interfere with prosthetic fitting. Syme amputation and prosthesis are indicated in these patients. In patients with normal hip and knee joints, femoral lengthening is feasible.</p>

Picture	Note	Management
<p><b>Sarcoma of Bone</b></p>  <p><b>Figures 21.2.11A and B:</b> Sarcoma of bone Photo Courtesy: K Sriram, Chennai</p>	<p>X-ray reveals destruction of diaphysis along with new bone formation. MRI shows a large extra osseous component. Biopsy: Round cell sarcoma. Besides histopathology, immunohistochemistry are performed.</p> <p>The X-ray can be mistaken for chronic osteomyelitis.</p>	<p>Treatment consists of neoadjuvant chemotherapy (cycles of chemotherapy given before surgery), followed by radical excision of the tumor. Limb reconstruction follows excision of the tumor. Postoperative chemotherapy is continued according to the individual case (Adjuvant chemotherapy).</p>
<p><b>Solitary Bone Cyst</b></p>  <p><b>Figure 21.2.12:</b> Solitary bone cyst Photo Courtesy: K Sriram, Chennai</p>	<p>This is an expansile, bony, radiolucent lesion in the metaphysis. The cortex is thinned out. Lesion extends up to the growth plate. It is common in the humerus and femur. The condition is often discovered after a pathological fracture.</p>	<p>Symptomatic cysts are treated by aspiration of the fluid and injection of methylprednisolone. Cyst in the femur is treated by curettage and bone grafting. Recurrence and arrest of growth plate are common complications.</p>
<p><b>Spondylolisthesis</b></p>  <p><b>Figures 21.2.13A to C:</b> L5-S1 listhesis Photo Courtesy: Vijay Sriram, Chennai</p>	<p>Spondylolisthesis is defined as the forward slippage of one vertebra on its adjacent caudal segment. In children the common types are the dysplastic (congenital) and the isthmic type.</p> <p>Both types can occur at any age in children but dysplastic tends to become evident earlier. Back pain, sciatic pain, altered posture and claudication are the common symptoms. Rarely there can be neurological deficits including bladder involvement.</p> <p>Hamstring tightness, scoliosis, spasm and restriction of flexion are the common signs. A single lateral radiograph is diagnostic of a listhesis. Oblique views may be necessary to detect the pars defect.</p> <p>MRI is useful when there are neurological deficits.</p>	<p>The mainstays of treatment— rest, avoidance of inciting activities, use of anti-inflammatory pain medication, and application of a brace in extreme situations— usually allow an acute symptomatic spondylolysis to resolve. When conservative treatment fails then surgery is necessary.</p> <p>Posterolateral fusion is advocated when there are no significant neurological symptoms.</p> <p>Decompression and fusion is necessary when there are significant neurological symptoms.</p>


## 21.3 EMERGENCIES

Picture	Note	Management
 <p><b>Figures 21.3.1A and B:</b> Acute Osteomyelitis Photo Courtesy: K Sriram, Chennai</p>	<p>It produces systemic signs of infection, local signs of inflammation and pseudoparalysis of the affected limb. In the neonates, multifocal lesions can occur. CRP and ESR are raised. X-ray shows soft tissue swelling. Ultrasound and MRI help to localize the abscess.</p>	<p>If diagnosed early, intravenous antibiotics may control the infection. Patients presenting with abscess or those not responding to antibiotics need drainage. The bones remodel well, but the adjacent growth plates may be destroyed.</p>
 <p><b>Figures 21.3.2A and B:</b> Septic arthritis of L hip Photo Courtesy: Vijay Sriram, Chennai</p>	<p>Acute septic arthritis is an emergency. Hematogenous seeding of the synovium during transient bacteremia is the most common cause of septic arthritis in children. In majority of cases a single joint is affected with the hip being most common. The most common causative organism is <i>Staphylococcus aureus</i>. The clinical features include fever, pain, refusal to bear weight and most importantly pseudoparalysis.</p>	<p>Leukocytosis, raised ESR and CRP are the laboratory findings. Ultrasound or MRI can be done to confirm the diagnosis.</p> <p>Treatment is an emergency. Immediate aspiration of the affected joint followed by an arthrotomy of the involved joint should be done. Early decompression can save the joint.</p> <p>Complications include systemic sepsis, premature arthritis, physal closure, growth disturbance, synovitis, arthrofibrosis, joint stiffness, and persistent infection.</p>
 <p><b>Figures 21.3.3A and B:</b> (A) Displaced supracondylar fracture humerus; (B) Postoperative X-ray Photo Courtesy: Vijay Sriram, Chennai</p>	<p>The peak age at which supracondylar fractures occur is between 5 and 7 years. Fall on an outstretched hand is the most common mechanism of injury. Associated median or radial nerve injuries can occur in displaced fractures. Brachial artery can be injured too. Concomitant injuries of the wrist and shoulder should also be looked for. X-rays are necessary to diagnose and to assess the displacement of the fracture.</p>	<p>Undisplaced fractures can be treated in a plaster cast. Displaced fractures are treated on an urgent basis. This is because delay in treatment can cause significant swelling of the elbow which could lead to difficulty in reduction of the fracture and Volkmann's ischemia.</p> <p>Closed or open reduction with 'K' wire fixation is the mode of treatment for displaced fracture. Cubitus varus is the most common complication of this fracture.</p>


Picture	Note	Management
<p><b>Slipped Capital Femoral Epiphysis (SCFE)</b></p>  <p><b>Figures 21.3.4A and B:</b> (A) SCFE L hip; (B) Pinning <i>in situ</i> Photo Courtesy: Vijay Sriram, Chennai</p>	<p>Slipped capital femoral epiphysis (SCFE) is caused when the femoral capital epiphysis displaces from its normal position relative to the femoral neck. It is seen in adolescents. It can be acute, chronic or acute on chronic. Stable slips are those when the patient is able to bear weight but has pain and unstable ones are those where the patient cannot bear weight. Obesity, hypothyroidism, growth hormone deficiency and chronic renal failure are associated with this condition.</p> <p>Patients present with varying degrees of pain and external rotation of the affected hip. Some patients present with referred pain behind the knee.</p>	<p>Stable slips should be pinned <i>in situ</i>. Unstable slips can either be pinned <i>in situ</i>, or can be reduced with a safe surgical dislocation and pinned. Prophylactic pinning of the contralateral normal hip is done in endocrinopathies and renal failure. The complications associated are AVN, chondrolysis and early osteoarthritis of the hip.</p>


## 21.4 SYNDROMES

### Arthrogryposis Multiplex Congenital

 <p><b>Figures 21.4.1A and B:</b> Arthrogryposis multiplex congenital Photo Courtesy: K Sriram, Chennai</p>	<p>The condition is characterized by multiple congenital contractures. Muscles are replaced by fibrous tissue and fat. The condition is sporadic. All four limbs are affected in 60% of patients. Lower limbs alone are involved in 25%. Medial rotation of shoulders, deformity of elbows, flexion of wrists, hip dislocations, knee deformities and club feet are common deformities.</p>	<p>The goal of treatment is to bring the limbs to functional position. Physiotherapy and bracing are needed in infancy and early childhood to reduce the contractures. The deformities due to club feet, knee contractures and hip dislocations are rigid. Surgery is necessary to correct them. With growth and physiotherapy, the condition progressively improves.</p>
--	---	---

### Enchondromatosis

 <p><b>Figure 21.4.2:</b> Enchondromatosis Photo Courtesy: K Sriram, Chennai</p>	<p>Enchondroma is a benign cartilage tumor in the metaphysis of long bone. Enchondromatosis (Ollier's disease) is defined by the presence of at least three enchondromas. The clinical picture is variable (number, location and age of onset). Clinical presentation may be pathological fracture or growth disturbance. A small chance of malignant transformation exists.</p>	<p>Surgical treatment is indicated in case of complications, such as, pressure on a nerve or blood vessel, pain during daily activities or the appearance may be unsightly. Severe deformity of legs and forearms also need surgery.</p>
---	--	--

Picture	Note	Management
<p data-bbox="125 214 527 255"><b>Hereditary Multiple Exostosis</b></p>  <p data-bbox="138 664 544 723"><b>Figure 21.4.3:</b> Hereditary multiple exostosis <i>Photo Courtesy: K Sriram, Chennai</i></p>	<p data-bbox="600 275 1015 531">Multiple bone tumors capped by cartilage occur in the skeleton. The metaphysis of long bones are broad and poorly remodelled. Sessile or pedunculated exostosis arise from the cortices. It is inherited as autosomal dominant disorder with variable expression.</p>	<p data-bbox="1047 275 1453 470">The indications for excision of exostosis are: pressure on a nerve or blood vessel, pain during daily activities or the appearance may be unsightly. Severe deformity of legs and forearms also need surgery.</p>



## Section 22

---

# Pediatric Imaging

### *Section Editors*

Nishigandha Burute, Bhavin Jankharia

### *Photo Courtesy*

Bhavin Jankharia, Bijal Jankharia, Devang Desai,  
Govind R Jankharia, Meher Ursekar

- 22.1 Abdomen
- 22.2 Brain
- 22.3 Chest
- 22.4 Congenital (Multiorgan)
- 22.5 Musculoskeletal



## SECTION OUTLINE

### 22.1 ABDOMEN 463

- ◆ Appendicitis 463
- ◆ Appendicolith with Bowel Obstruction 463
- ◆ Budd-Chiari Syndrome 463
- ◆ Choledochal Cyst 464
- ◆ Congenital Hypertrophic Pyloric Stenosis 464
- ◆ Hematocolpos 464
- ◆ Intestinal Obstruction 465
- ◆ Intussusception 465
- ◆ Meckel's Diverticulitis 465
- ◆ Ovarian Dermoids 466
- ◆ Pneumatosis Intestinalis 466
- ◆ Pneumoperitoneum 466

### 22.2 BRAIN 467

- ◆ Aqueductal Stenosis 467
- ◆ Craniopharyngioma 467
- ◆ Dandy-Walker Syndrome 467
- ◆ Meningitis 468
- ◆ Neurocysticercus Granuloma 468
- ◆ Perinatal Insult 468
- ◆ Pilocytic Astrocytoma 469
- ◆ Pontine Glioma 469
- ◆ Tuberculoma 469
- ◆ Tuberos Sclerosis 470

### 22.3 CHEST 470

- ◆ Arteriovenous Malformation 470
- ◆ Bronchogenic Cyst 470
- ◆ Bronchopulmonary Dysplasia (BPD) 471
- ◆ Congenital Cystic Adenomatoid Malformation (CCAM) 471
- ◆ Congenital Diaphragmatic Hernia 471
- ◆ Congenital Lobar Emphysema (CLE) 472
- ◆ Hyaline Membrane Disease 472

- ◆ Lung Abscess 472
- ◆ Lymphoma 473
- ◆ Pulmonary Alveolar Microlithiasis 473
- ◆ Sequestration 473
- ◆ Tension Pneumothorax 474
- ◆ Total Anomalous Pulmonary Venous Return 474
- ◆ Vascular Ring 474

### 22.4 CONGENITAL (MULTIORGAN) 475

- ◆ Branchial Cleft Cyst 475
- ◆ Cystic Hygroma 475
- ◆ Myelomeningocele with Sacral Agenesis 475
- ◆ Thyroglossal Cyst 476

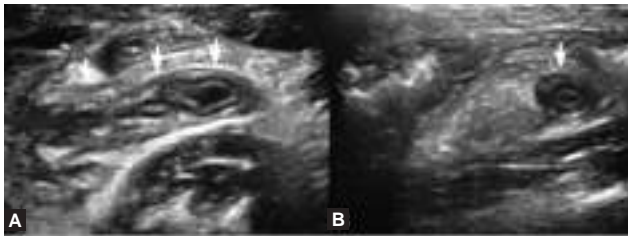
### 22.5 MUSCULOSKELETAL 476

- ◆ Aneurysmal Bone Cyst 476
- ◆ Coalition—Calcaneonavicular 476
- ◆ Congenital Dislocation of Hip 477
- ◆ Ewing's Sarcoma 477
- ◆ Fibrous Dysplasia 477
- ◆ Hemophilia 478
- ◆ Langerhan's Cell Histiocytosis 478
- ◆ Mucopolysaccharidosis 478
- ◆ Nonossifying Fibroma 479
- ◆ Osteogenesis Imperfecta 479
- ◆ Osteogenic Sarcoma 479
- ◆ Osteoid Osteoma 480
- ◆ Osteomyelitis 480
- ◆ Osteopetrosis 480
- ◆ Perthes' Disease 481
- ◆ Rickets 481
- ◆ Scurvy 481
- ◆ Thalassemia 482
- ◆ Tuberculosis Ankle 482
- ◆ Tuberculous Dactylitis 482

## 22.1 ABDOMEN

Picture	Note
---------	------

### Appendicitis



Figures 22.1.1A and B: Appendicitis

Longitudinal (Fig. 22.1.1A) and transverse (Fig. 22.1.1B) ultrasound images show an enlarged, tubular, noncompressible, nonperistaltic, blind-ending structure (arrows) in the right iliac fossa in a child with pain in the abdomen. Echogenic fat stranding is seen surrounding this.

### Appendicolith with Bowel Obstruction

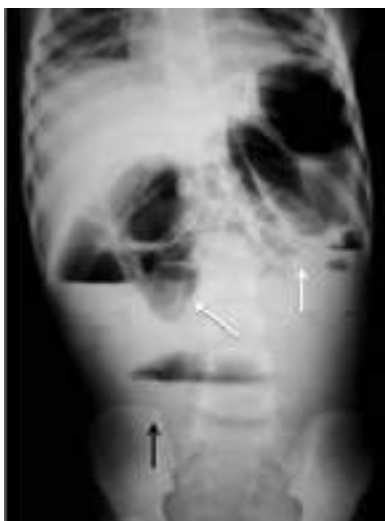
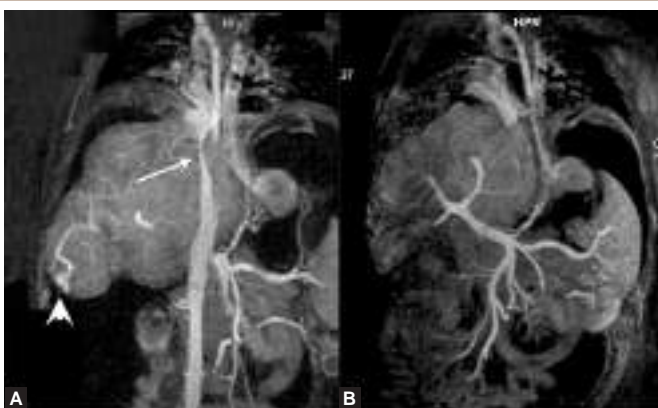
Figure 22.1.2: Appendicolith with bowel obstruction

Fluid filled distended small bowel loops (white arrows) are seen in this roentgenogram of the abdomen acquired with the patient in the upright position. A small radiopaque density; appendicolith (black arrow), is seen overlying the right iliac wing.

### Budd-Chiari Syndrome



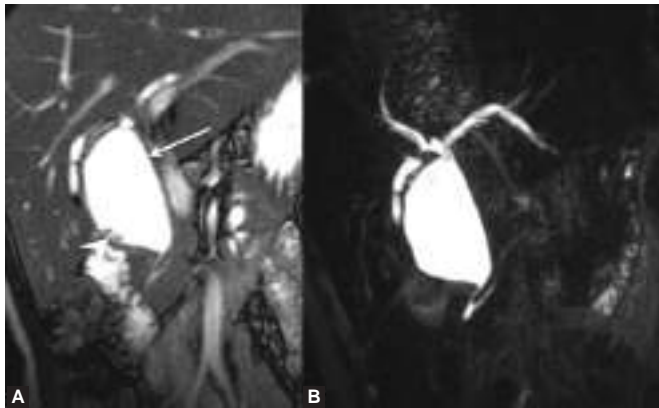
Figures 22.1.3A and B: Budd-Chiari syndrome

The intrahepatic IVC reveals smooth tapering with narrowing of the lumen (arrow) in this maximum intensity projection (MIP) MRI angiogram (Fig. 22.1.3A). A few tortuous collateral channels are seen along the lateral aspect of the liver (arrowhead). The portal vein and its branches appear normal as seen in the portal vein phase of the study (Fig. 22.1.3B).

## Picture

## Note

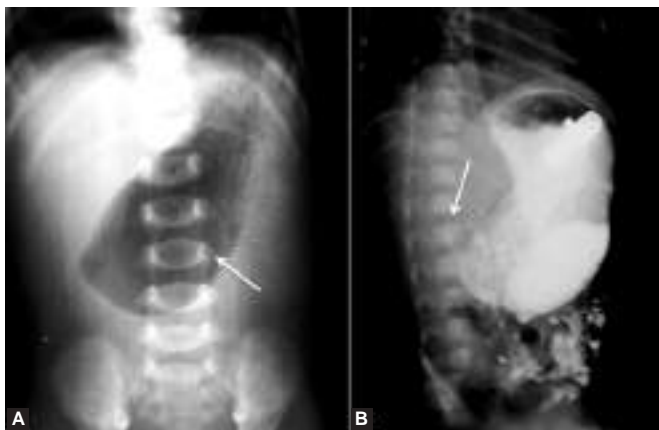## Choledochal Cyst



Figures 22.1.4A and B: Choledochal cyst

Coronal TRUE FISP MRI (Fig. 22.1.4A) reveals a large cystic dilatation (arrow) of the common bile duct. Two tiny calculi (arrowhead) are seen within the cyst. The intrahepatic biliary radicals and the pancreatic duct appear normal. MRCP (Fig. 22.1.4B) delineates the cyst and the intrahepatic radicals and pancreatic duct better.

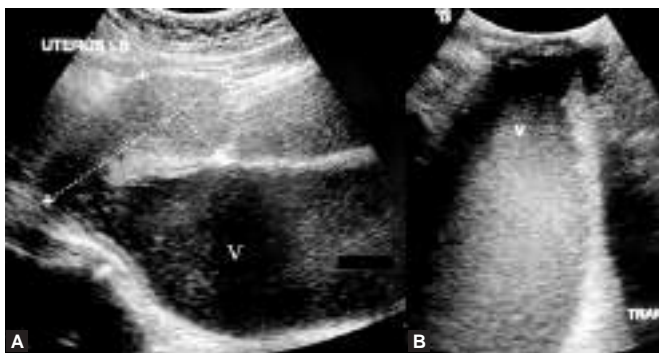
## Congenital Hypertrophic Pyloric Stenosis



Figures 22.1.5A and B: Congenital hypertrophic pyloric stenosis

A distended gastric bubble (arrow) is seen on a plain X-ray of the abdomen (Fig. 22.1.5A). Barium meal (Fig. 22.1.5B) reveals an elongated narrow pyloric canal (arrow).

## Hematocolpos



Figures 22.1.6A and B: Hematocolpos

Transabdominal ultrasound (Fig. 22.1.6A) reveals a large distended vagina (V) with dense internal echoes. The normal sized uterus is seen superior to it. Transvaginal ultrasound (Fig. 22.1.6B) confirms the presence of hematocolpos (V).

Picture

Note

### Intestinal Obstruction

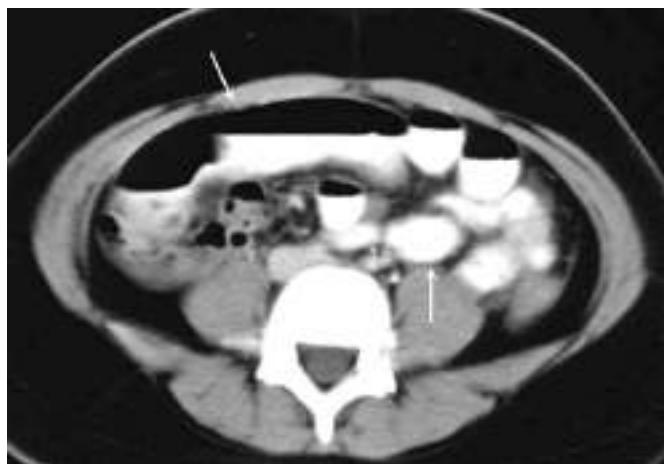
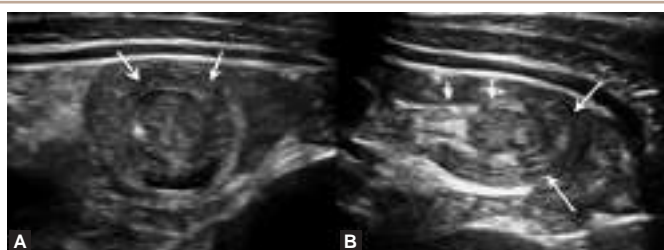
Figure 22.1.7: Intestinal obstruction

Axial CT scan of the abdomen with oral contrast shows fluid filled distended small bowel loops (arrows) in a child with intestinal obstruction.

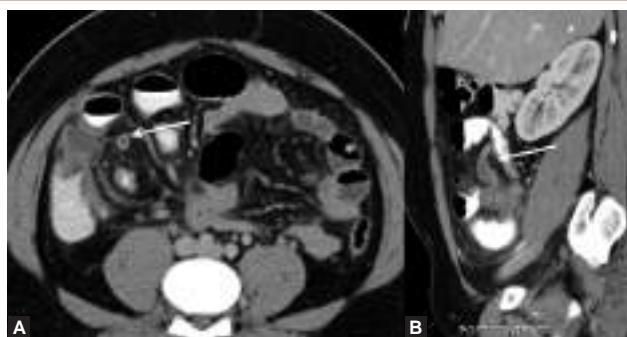
### Intussusception



Figures 22.1.8A and B: Intussusception

Transverse ultrasound (Fig. 22.1.8A) shows the typical 'target sign' (arrows) caused by bowel invaginating within bowel. Longitudinal ultrasound (Fig. 22.1.8B) shows a layered appearance of the outer loop, the intussuscepiens (long arrows) and the inner loop, the intussusceptum (short arrows).

### Meckel's Diverticulitis



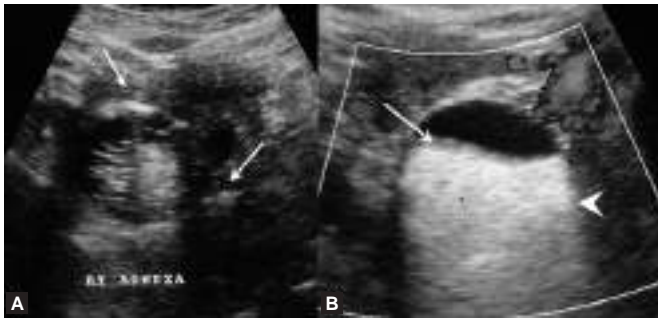
Figures 22.1.9A and B: Meckel's diverticulitis

Axial (Fig. 22.1.9A) and sagittal (Fig. 22.1.9B) contrast-enhanced CT scans reveal an enhancing, distended, tubular, blind-ending structure (arrow) originating from the distal ileum in a child with acute abdominal pain. Surrounding mesenteric fat stranding is seen.

## Picture

## Note

## Ovarian Dermoids



Figures 22.1.10A and B: Ovarian dermoids

Well-defined round mass lesions are seen on these ultrasound images involving both ovaries. The lesion in the right ovary (Fig. 22.1.10A) contains multiple linear echogenic interfaces (arrows). The lesion in the left adnexa (Fig. 22.1.10B) reveals a fluid level (arrow) with echogenic contents and posterior acoustic enhancement (arrowhead).

## Pneumatosis Intestinalis

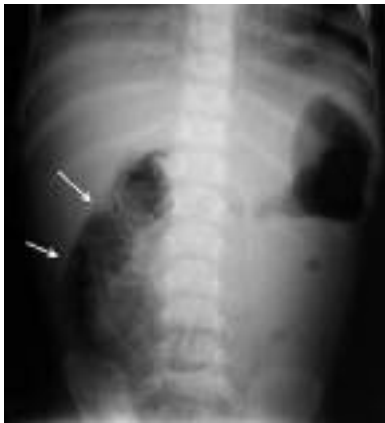

Figure 22.1.11: Pneumatosis intestinalis

A linear pattern of extraluminal gas (arrows) is seen within the small bowel wall, well appreciated along the lateral margin of the bowel loop on this supine, plain radiograph of the abdomen.

## Pneumoperitoneum

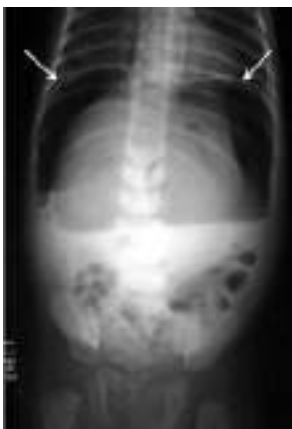

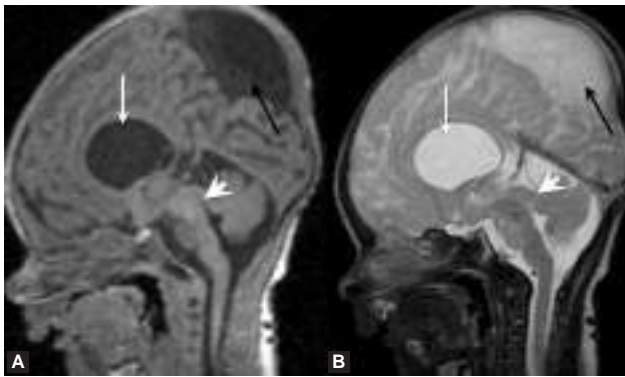Figure 22.1.12: Pneumoperitoneum

Radiograph of the abdomen in the erect position shows a large amount of free air (arrows) within the peritoneal cavity, outlining the domes of the diaphragm. The visceral shadows as well as the bowel loops are displaced inferiorly.

## 22.2 BRAIN

Picture	Note
---------	------

### Aqueductal Stenosis



Figures 22.2.1A and B: Aqueductal stenosis

Sagittal T1W (Fig. 22.2.1A) and T2W (Fig. 22.2.1B) MRIs reveal a dilated third ventricle (arrow) secondary to aqueductal stenosis (arrowhead). Both the lateral ventricles were also dilated. A dorsal cyst (black arrow) is also seen incidentally.

### Craniopharyngioma

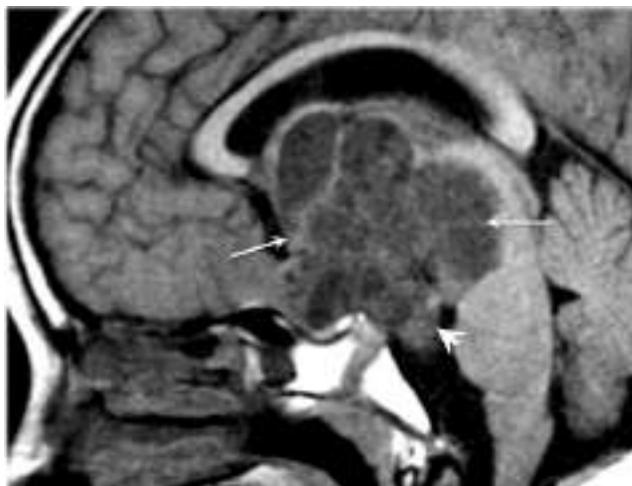
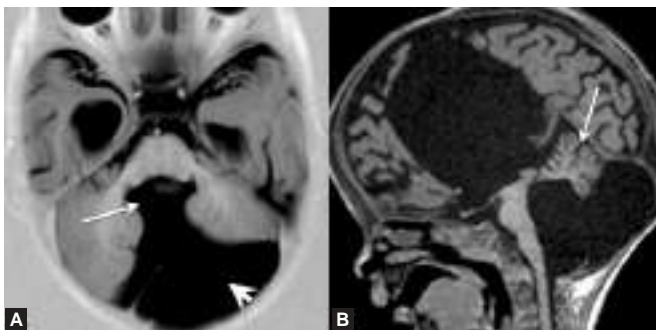


Figure 22.2.2: Craniopharyngioma

T1W sagittal MRI reveals a large, lobulated, extra-axial cystic lesion within the suprasellar region. This compresses and displaces the midbrain posteriorly. A solid component is seen along its posteroinferior margin (arrowhead).

### Dandy-Walker Syndrome



Figures 22.2.3A and B: Dandy-Walker syndrome

T1W axial MRI (Fig. 22.2.3A) reveals a hypoplastic cerebellar vermis. The fourth ventricle (arrow) communicates with the cisterna magna (arrowhead), with the characteristic 'keyhole' appearance. T1W sagittal MRI (Fig. 22.2.3B) reveals a large posterior fossa with superior displacement of the cerebellum (arrow) and the torculi. Compression of the fourth ventricle and aqueduct has led to hydrocephalus.

## Picture

## Note

## Meningitis

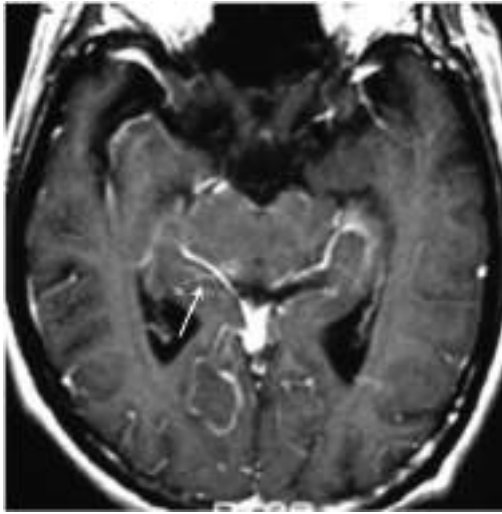
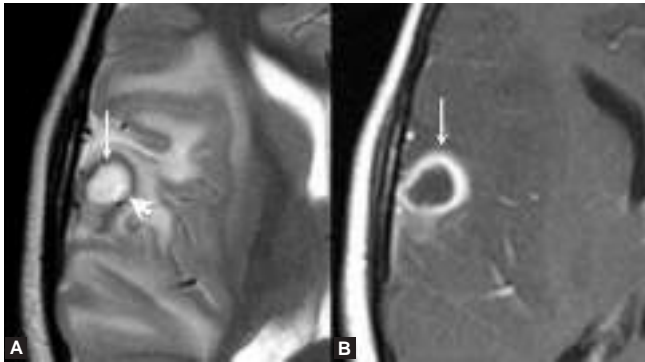


Figure 22.2.4: Meningitis

Contrast-enhanced T1W axial MRI reveals leptomeningeal enhancement (arrows) along the perimesencephalic cisterns.

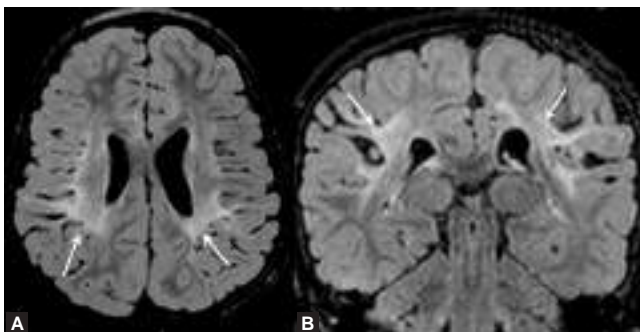
## Neurocysticercus Granuloma



Figures 22.2.5A and B: Neurocysticercus granuloma

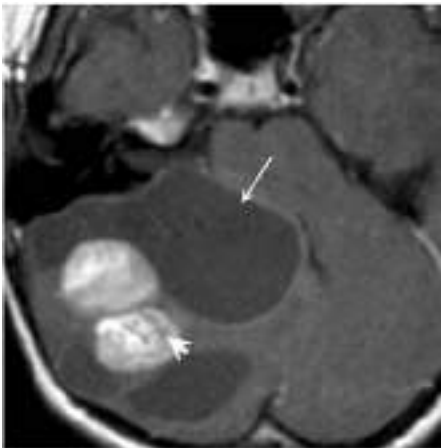
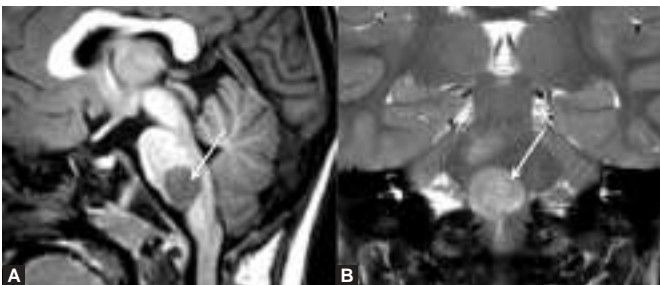
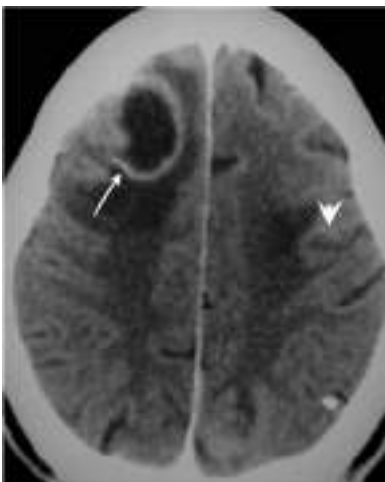
Axial T2W (Fig. 22.2.5A) and contrast-enhanced T1W (Fig. 22.2.5B) MRIs reveal a small round ring enhancing lesion (arrow) in the right temporal subcortical gray matter. Surrounding vasogenic edema is seen on the T2W image. A nodular component representing the scolex (arrowhead) is noted along the rim.

## Perinatal Insult



Figures 22.2.6A and B: Perinatal insult

Axial (Fig. 22.2.6A) and coronal (Fig. 22.2.6B) T1W MRIs reveal periventricular increased signal intensity (arrows). Mild dilatation of the lateral ventricles is seen secondary to white matter volume loss.

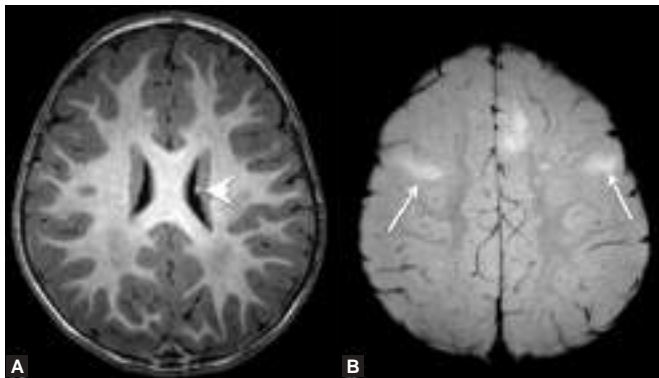
Picture	Note
<p data-bbox="126 212 422 245"><b>Pilocytic Astrocytoma</b></p>  <p data-bbox="138 737 474 764">Figure 22.2.7: Pilocytic astrocytoma</p>	<p data-bbox="831 273 1448 363">Contrast-enhanced axial T1W MRI reveals a large cystic lesion (arrow) with a mural nodule (arrowhead) involving the right cerebellar hemisphere.</p>
<p data-bbox="126 846 334 878"><b>Pontine Glioma</b></p>  <p data-bbox="138 1201 500 1228">Figures 22.2.8A and B: Pontine glioma</p>	<p data-bbox="831 901 1455 1058">T1W sagittal (Fig. 22.2.8A) and T2W coronal (Fig. 22.2.8B) MRIs show a well-defined lesion (arrow) involving the pons and the pontomedullary junction. It shows low T1 and high T2 signal. It did not show significant enhancement on the contrast-enhanced images.</p>
<p data-bbox="126 1299 308 1332"><b>Tuberculoma</b></p>  <p data-bbox="138 1855 402 1882">Figure 22.2.9: Tuberculoma</p>	<p data-bbox="831 1357 1458 1514">Contrast-enhanced axial CT scan shows a well-defined, oval, rim-enhancing lesion (arrow) in the right frontal cortex with surrounding vasogenic edema. Few other smaller enhancing lesions (arrowhead) are seen scattered in the brain parenchyma.</p>



## Picture

## Note

## Tuberous Sclerosis

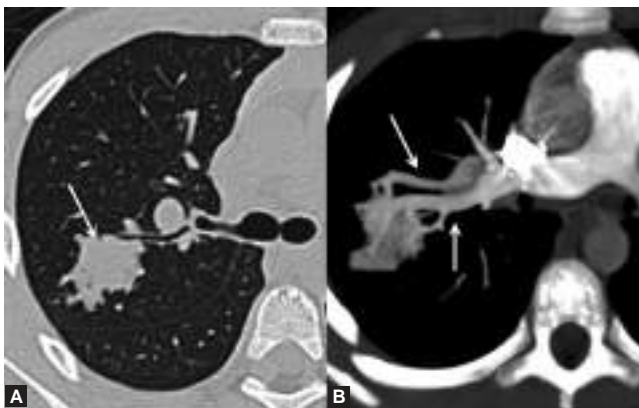

Figures 22.2.10A and B: Tuberous sclerosis

Axial T1W (Fig. 22.2.10A) and GRASE (Fig. 22.2.10B) MRIs reveal multiple cortical tubers (arrows) in both cerebral hemispheres. A tiny subependymal hamartoma (arrowhead) is noted along the lateral margin of the left lateral ventricle.

## 22.3 CHEST

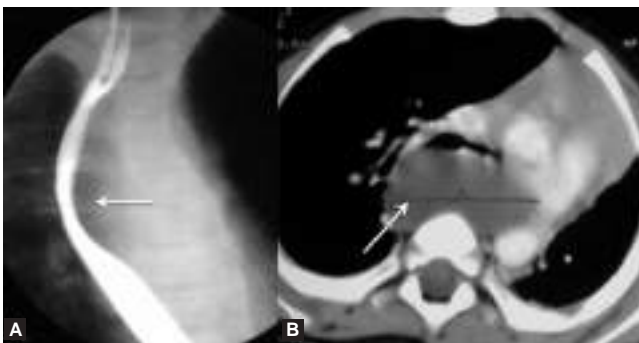
## Arteriovenous Malformation



Figures 22.3.1A and B: Arteriovenous malformation

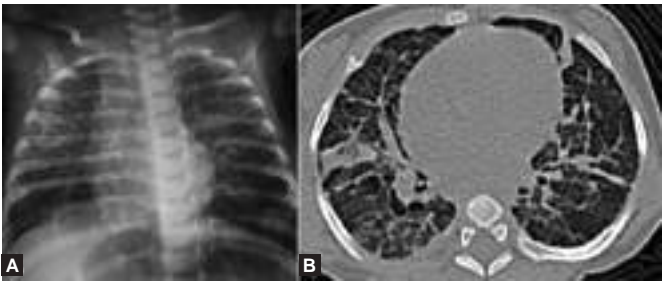


Axial high-resolution CT scan (Fig. 22.3.1A) shows an ill-defined opacity (arrow), in the right upper lobe. Axial maximum intensity projection (MIP) reconstructed CT angiogram (Fig. 22.3.1B) shows the arterial feeder and draining vein (arrows) of the arteriovenous malformation.

## Bronchogenic Cyst



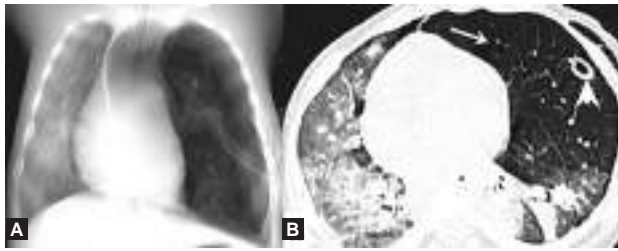
Figures 22.3.2A and B: Bronchogenic cyst

Barium swallow (Fig. 22.3.2A) shows an anteriorly displaced and compressed esophagus (arrow) due to a posteriorly located lesion. Axial contrast-enhanced CT scan (Fig. 22.3.2B) reveals an oval prevertebral fluid density lesion (arrow), which displaces the trachea anteriorly.

Picture	Note
<p data-bbox="126 210 617 245"><b>Bronchopulmonary Dysplasia (BPD)</b></p>  <p data-bbox="138 564 690 594"><b>Figures 22.3.3A and B:</b> Bronchopulmonary dysplasia (BPD)</p>	<p data-bbox="829 271 1455 396">Frontal chest radiograph (Fig. 22.3.3A) reveals patchy areas of fibrosis. High-resolution CT scan (Fig. 22.3.3B) reveals a coarse reticular pattern with areas of fibrosis. Multiple tiny cysts are seen bilaterally.</p>
<p data-bbox="126 793 844 827"><b>Congenital Cystic Adenomatoid Malformation (CCAM)</b></p>  <p data-bbox="138 1177 776 1232"><b>Figures 22.3.4A and B:</b> Congenital cystic adenomatoid malformation (CCAM)</p>	<p data-bbox="829 848 1438 972">Chest radiograph (Fig. 22.3.4A) reveals a multiloculated cystic lesion (arrow) in the left lower lobe. Coronal CT scan (Fig. 22.3.4B) shows this lesion well (arrows).</p>
<p data-bbox="126 1418 578 1453"><b>Congenital Diaphragmatic Hernia</b></p>  <p data-bbox="138 1790 662 1821"><b>Figures 22.3.5A and B:</b> Congenital diaphragmatic hernia</p>	<p data-bbox="829 1473 1430 1663">Frontal chest radiograph (Fig. 22.3.5A) in a child shows left mid and lower hemithorax heterogeneous opacities with air-fluid levels (arrow). Axial CT scan (Fig. 22.3.5B) reveals bowel-loops (arrows) within the left posterolateral hemithorax suggestive of a Bochdalek hernia.</p>

## Picture

## Note

**Congenital Lobar Emphysema (CLE)**

Figures 22.3.6A and B: Congenital lobar emphysema (CLE)

Coronal mean reconstruction simulating a frontal chest radiograph (Fig. 22.3.6A) in an infant with respiratory distress reveals significant overinflation of the left lung with shift to the right. High-resolution CT scan (Fig. 22.3.6B) reveals a hyperlucent expanded left upper lobe (arrow) with mediastinal shift. An inadvertent ICD tube (arrowhead) is seen because the lesion was mistaken to be pneumothorax. Note the associated bilateral consolidation.

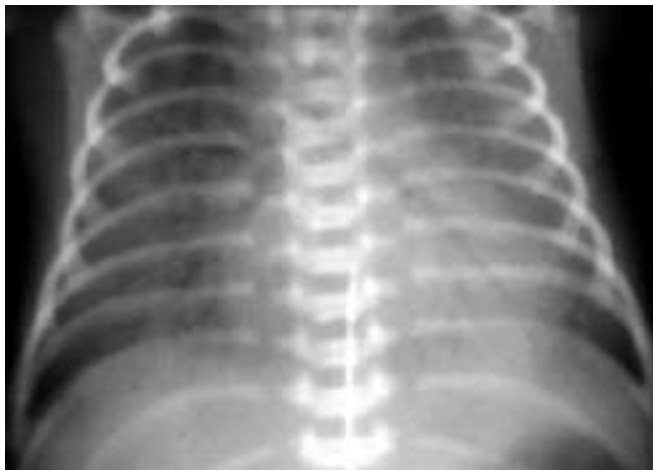
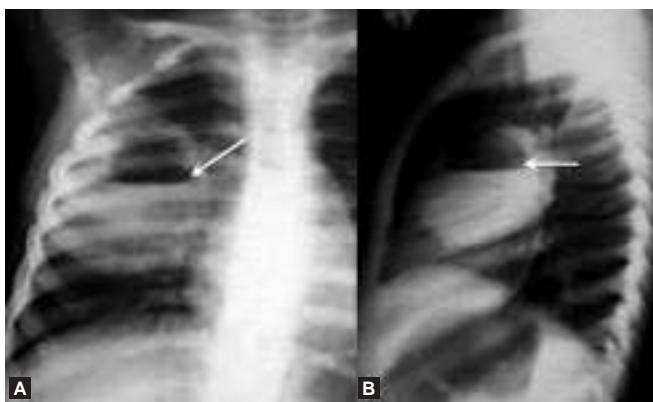
**Hyaline Membrane Disease**

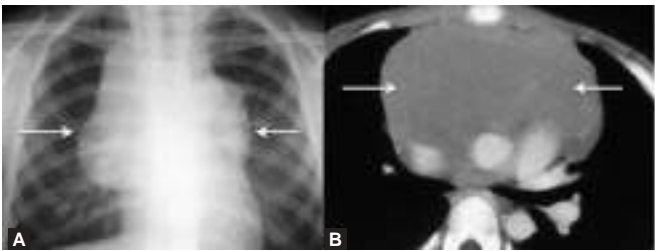
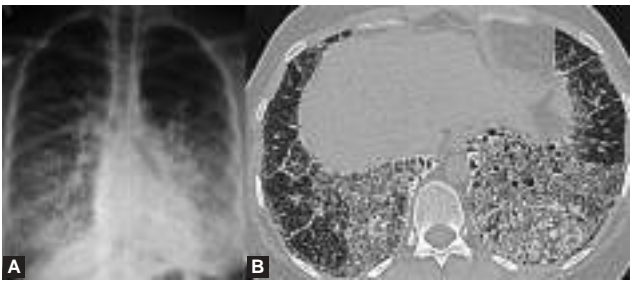
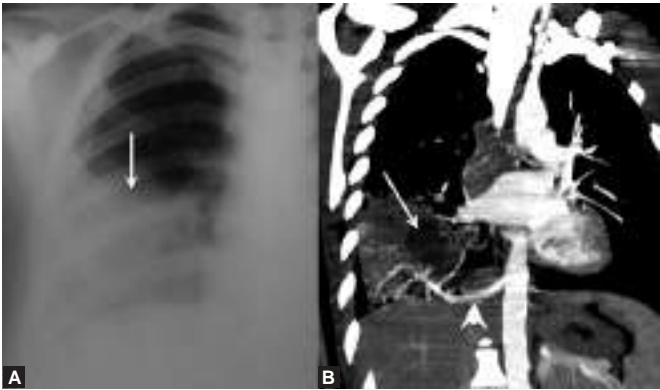
Figure 22.3.7: Hyaline membrane disease

Frontal chest radiograph in a neonate shows a ground glass haze with fine reticulonodular shadowing and an air bronchogram pattern in a premature born neonate with symptoms of respiratory distress.

**Lung Abscess**

Figures 22.3.8A and B: Lung abscess

Frontal (Fig. 22.3.8A) and lateral (Fig. 22.3.8B) chest radiographs show a large thick-walled abscess cavity (arrow) with an air-fluid level, in the right middle lobe.

Picture	Note
<p><b>Lymphoma</b></p>  <p><b>Figures 22.3.9A and B: Lymphoma</b></p>	<p>Frontal chest radiograph (Fig. 22.3.9A) shows mediastinal opacities bilaterally (arrows). Axial contrast-enhanced CT scan (Fig. 22.3.9B) shows a prevascular space mass (arrows) partly encasing the mediastinal vessels. A CT-guided core biopsy revealed Hodgkin's disease.</p>
<p><b>Pulmonary Alveolar Microlithiasis</b></p>  <p><b>Figures 22.3.10A and B: Pulmonary alveolar microlithiasis</b></p>	<p>Frontal chest radiograph (Fig. 22.3.10A) reveals a high-density interstitial reticular pattern. High-resolution CT scan (Fig. 22.3.10B) shows high-density intralobular interstitial and septal thickening with alveolar opacities and diffuse septal and pleural calcification/ossification.</p>
<p><b>Sequestration</b></p>  <p><b>Figures 22.3.11A and B: Sequestration</b></p>	<p>Frontal chest radiograph (Fig. 22.3.11A) reveals an ill-defined opacity (arrow) in the right lower lobe. A coronal contrast-enhanced CT scan (Fig. 22.3.11B) shows this to be a necrotic lesion (arrow) supplied by a systemic artery from the aorta (arrowhead), confirming it to be sequestration.</p>

## Picture

## Note

## Tension Pneumothorax

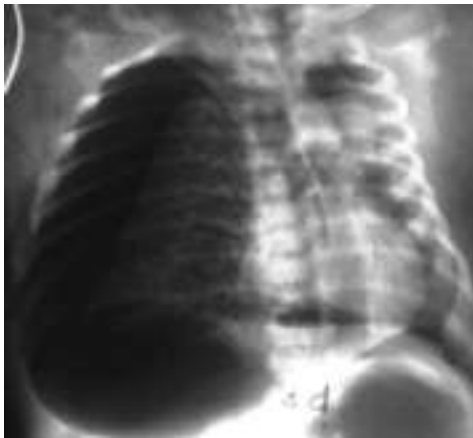

Figure 22.3.12: Tension pneumothorax

Frontal chest radiograph shows a large right pneumothorax with mediastinal shift towards the left, inversion of the diaphragm and herniation of the right lung to the contralateral side.

## Total Anomalous Pulmonary Venous Return

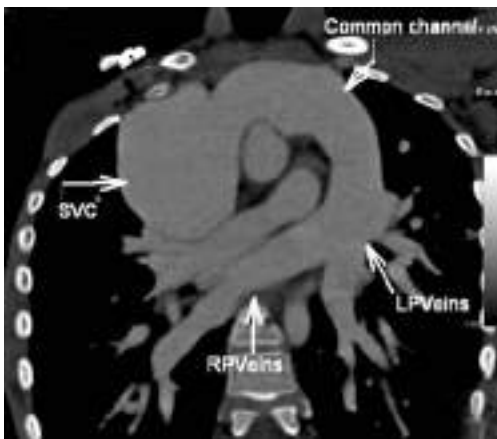
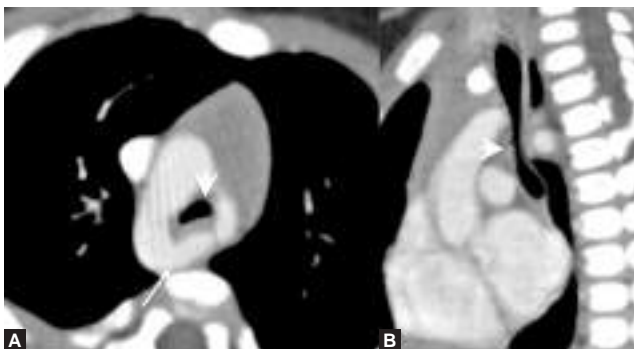


Figure 22.3.13: Total anomalous pulmonary venous return

Reconstructed CT angiogram in a 12-year-old boy shows that the pulmonary veins are seen to unite to form a common channel that then enters the dilated SVC.

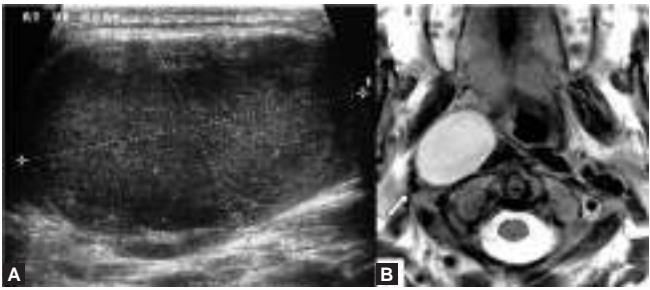
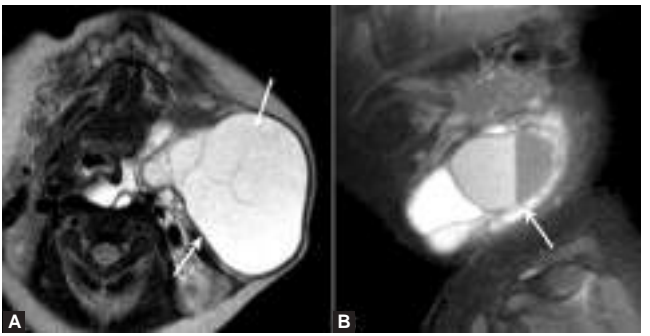

## Vascular Ring



Figures 22.3.14A and B: Vascular ring

Axial maximum intensity projection (MIP) CT angiogram (Fig. 22.3.14A) shows a right-sided aortic arch with an anomalous origin of the left subclavian artery (arrow) producing a vascular ring and compression of the trachea (arrowhead), which is better appreciated on the contrast-enhanced sagittal CT scan (Fig. 22.3.14B).

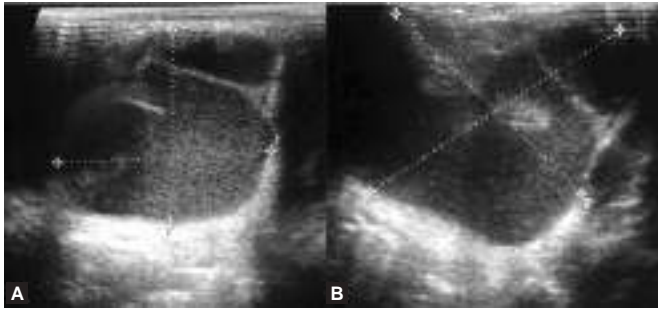
## 22.4 CONGENITAL (MULTIORGAN)

Picture	Note
<p><b>Branchial Cleft Cyst</b></p>  <p><b>Figures 22.4.1A and B:</b> Branchial cleft cyst</p>	<p>Longitudinal ultrasound (Fig. 22.4.1A) reveals an oval, thick-walled cyst with dense internal echoes along the upper third of the sternocleidomastoid muscle. Axial T2W MRI of the neck (Fig. 22.4.1B) reveals an oval, thick-walled cystic lesion (arrow) in the right parapharyngeal region.</p>
<p><b>Cystic Hygroma</b></p>  <p><b>Figures 22.4.2A and B:</b> Cystic hygroma</p>	<p>Axial (Fig. 22.4.2A) and coronal (Fig. 22.4.2B) T2W MRIs reveal a large, cystic, multiloculated lesion (arrow) along the left lateral aspect of the neck with high signal intensity fluid within. One of the cysts in the coronal MRI shows a lower signal with a fluid-fluid level (arrow) suggesting the presence of hemorrhage within.</p>
<p><b>Myelomeningocele with Sacral Agenesis</b></p>  <p><b>Figures 22.4.3A and B:</b> Myelomeningocele with sacral agenesis</p>	<p>Sagittal T1W (Fig. 22.4.3A) and T2W (Fig. 22.4.3B) MRIs reveal a large, posterior outpouching (arrow) of the dura in the thoracolumbar region. The nerve roots appear stretched with tethering of the cord. The lumbar vertebrae are fused and sacral agenesis is present.</p>

## Picture

## Note

## Thyroglossal Cyst

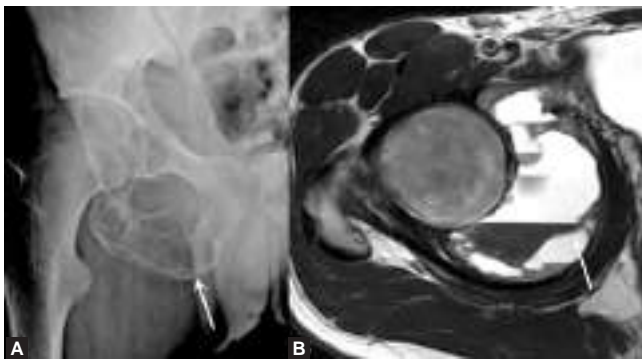

Figures 22.4.4A and B: Thyroglossal cyst

Transverse (Fig. 22.4.4A) and longitudinal (Fig. 22.4.4B) ultrasounds reveal a midline infrahyoid cystic lesion with thick walls, internal septae and dense internal echoes. The cyst shows intense posterior enhancement.

## 22.5 MUSCULOSKELETAL

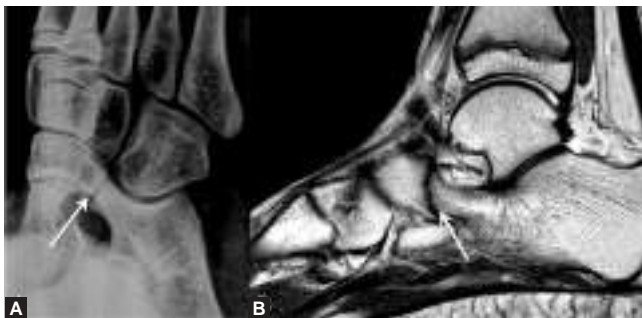
## Aneurysmal Bone Cyst



Figures 22.5.1A and B: Aneurysmal bone cyst




Frontal radiograph of the right hip (Fig. 22.5.1A) shows an expansile, trabeculated osteolytic lesion (arrow) involving the ischium with cortical thinning and a preserved endosteal margin. Axial T2W MRI (Fig. 22.5.1B) reveals multiple fluid-fluid levels (arrow) within the cystic spaces.

## Coalition—Calcaneonavicular



Figures 22.5.2A and B: Coalition—calcaneonavicular

Oblique radiograph of the foot (Fig. 22.5.2A) shows fibrous calcaneonavicular coalition (arrow), which is also well seen on the sagittal T2W MRI (Fig. 22.5.2B).

Picture	Note
<p data-bbox="126 210 519 245"><b>Congenital Dislocation of Hip</b></p>  <p data-bbox="138 558 625 582"><b>Figures 22.5.3A and B:</b> Congenital dislocation of hip</p>	<p data-bbox="828 271 1429 490">Frontal radiograph of both hips (Fig. 22.5.3A) shows that the left acetabulum is shallow and the femoral head is displaced upwards and laterally from the normal position and shows evidence of remodeling. The coronal T2W MRI (Fig. 22.5.3B) shows the dysplasia and subluxation, the shallow acetabulum and eversion of the labrum (arrow) and capsule.</p>
<p data-bbox="126 705 349 739"><b>Ewing's Sarcoma</b></p>  <p data-bbox="138 1212 430 1236"><b>Figure 22.5.4:</b> Ewing's sarcoma</p>	<p data-bbox="828 762 1404 858">Frontal radiograph of the pelvis shows a large, expansile, sclerotic lesion (arrows) with ill-defined margins seen involving the left hemipelvis.</p>
<p data-bbox="126 1359 365 1394"><b>Fibrous Dysplasia</b></p>  <p data-bbox="138 1855 438 1880"><b>Figure 22.5.5:</b> Fibrous dysplasia</p>	<p data-bbox="828 1416 1461 1573">Frontal radiograph of the arm shows bony deformity of the humerus as a result of bone softening. Expansion of the bone with a fracture is seen proximally with cotton wool like increased bone density (arrow) within the humeral shaft.</p>



## Picture

## Note

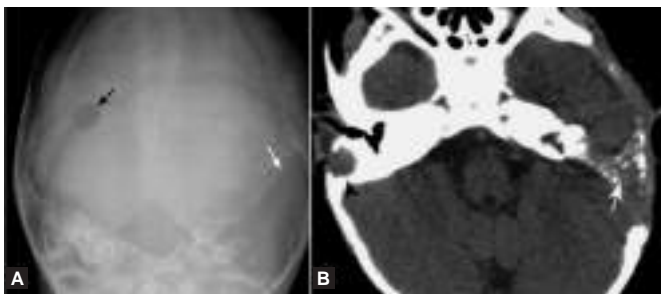
## Hemophilia

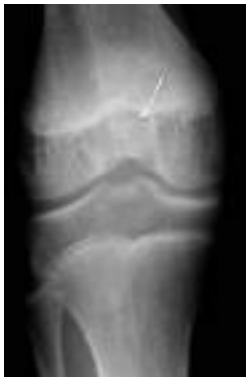

Figure 22.5.6: Hemophilia

Frontal radiograph of the knee shows osteopenia with a coarse trabecular pattern in the femoral and tibial epiphyses. Early widening of the intercondylar notch (arrow) is also present.

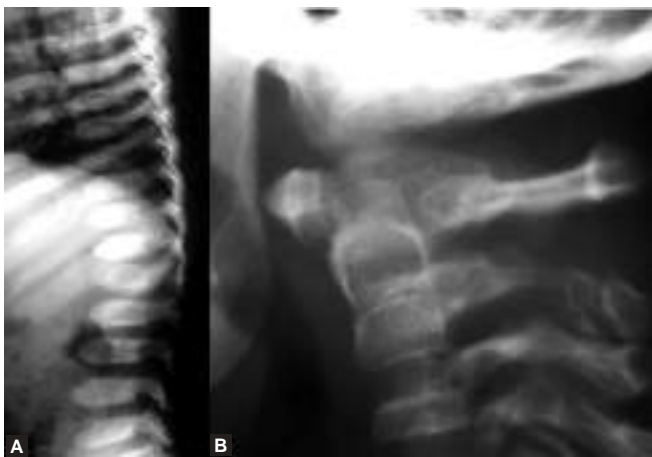
## Langerhan's Cell Histiocytosis



Figures 22.5.7A and B: Langerhan's cell histiocytosis




Frontal radiograph of the skull (Fig. 22.5.7A) shows well-defined osteolytic lesions (arrows) with a characteristic 'punched-out' appearance. Axial CT scan of the brain (Fig. 22.5.7B) reveals cortical destruction (arrow) involving the left squamous and petrous temporal bones. A small area of destruction (arrowhead) is seen involving the right petrous temporal bone as well.

## Mucopolysaccharidosis



Figures 22.5.8A and B: Mucopolysaccharidosis

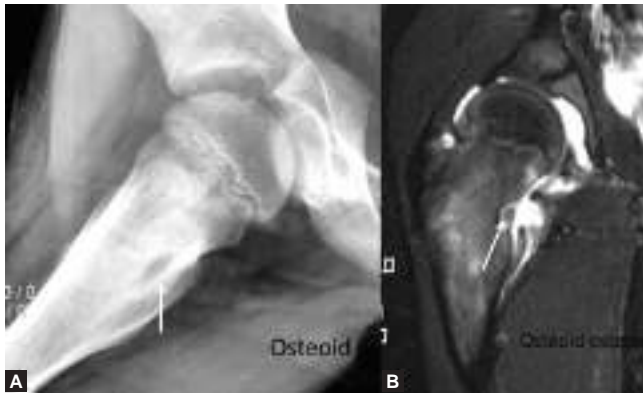
Lateral radiograph of the spine (Fig. 22.5.8A) reveals osteopenia with flattened vertebrae (platyspondyly) with protrusion of a central tongue of bone from the anterior aspect of the vertebral body (central beaking). There is atlantoaxial instability from odontoid dysplasia seen on the lateral radiograph of the cranio-vertebral junction (Fig. 22.5.8B).

Picture	Note
<p data-bbox="126 210 423 247"><b>Nonossifying Fibroma</b></p>  <p data-bbox="138 721 557 748"><b>Figures 22.5.9A and B:</b> Nonossifying fibroma</p>	<p data-bbox="829 271 1458 425">Frontal (Fig. 22.5.9A) and lateral (Fig. 22.5.9B) radiographs show a well-defined osteolytic lesion (arrow) with a narrow zone of transition and a sclerotic rim involving the cortex of the lower diaphysis of the femur.</p>
<p data-bbox="126 825 459 862"><b>Osteogenesis Imperfecta</b></p>  <p data-bbox="138 1197 596 1224"><b>Figures 22.5.10A and B:</b> Osteogenesis imperfecta</p>	<p data-bbox="829 887 1401 983">Plain radiographs of the upper (Fig. 22.5.10A) and lower (Fig. 22.5.10B) limbs show osteoporosis and bowing of the long bones with fractures (arrows).</p>
<p data-bbox="126 1302 399 1338"><b>Osteogenic Sarcoma</b></p>  <p data-bbox="138 1810 557 1837"><b>Figures 22.5.11A and B:</b> Osteogenic sarcoma</p>	<p data-bbox="829 1363 1458 1618">Lateral radiograph (Fig. 22.5.11A) of the distal femur shows an ill-defined bone-forming tumor (arrows) involving the metadiaphysis. Cortical erosion is seen. The periosteum is elevated (arrowhead) along the superior margin (Codman's triangle). Sagittal T2W MRI (Fig. 22.5.11B) reveals areas of necrosis (arrow) within the lesion, mainly in the subperiosteal soft tissue component. Marrow involvement is seen.</p>

## Picture

## Note

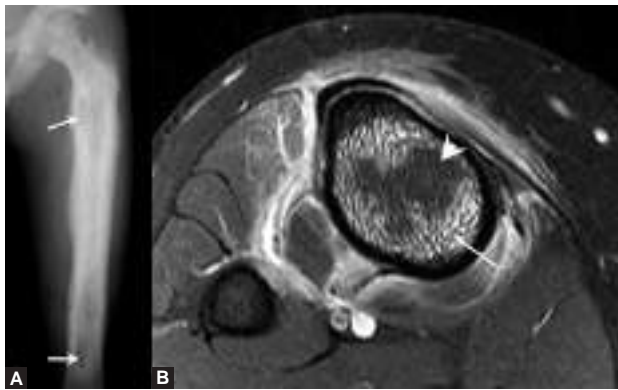## Osteoid Osteoma



Figures 22.5.12A and B: Osteoid osteoma

Oblique radiograph of the hip (Fig. 22.5.12A) shows an oval, osteolytic lesion (arrow) in the proximal diaphysis of the right femur, with surrounding sclerosis and cortical thickening. A coronal STIR MRI (Fig. 22.5.12B) shows the osteolytic lesion (arrow) well with surrounding marrow edema and effusion.

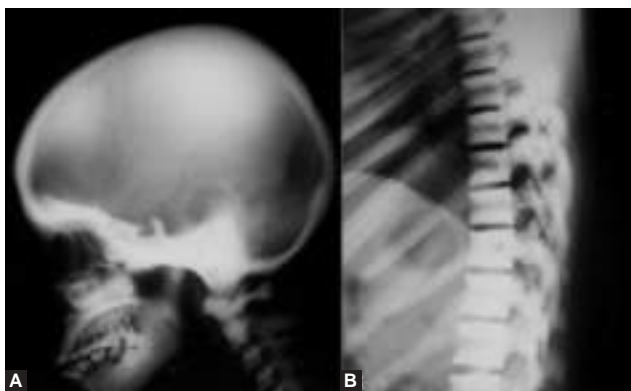
## Osteomyelitis



Figures 22.5.13A and B: Osteomyelitis

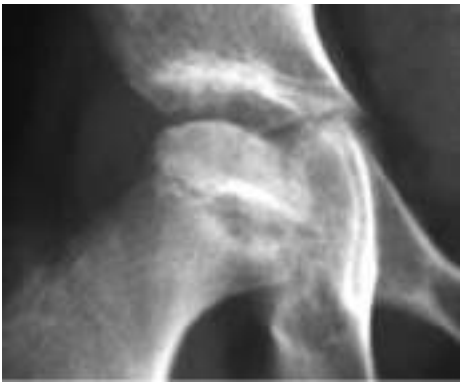


Frontal radiograph of the left femur (Fig. 22.5.13A) shows ill-defined sclerosis with cortical thickening and periosteal reaction. Sequestra are seen (arrows). Contrast-enhanced axial T1W MRI (Fig. 22.5.13B) in another patient with early osteomyelitis reveals marrow enhancement (arrow) within the tibia with necrosis (arrowhead) within and surrounding soft tissue edema.

## Osteopetrosis



Figures 22.5.14A and B: Osteopetrosis

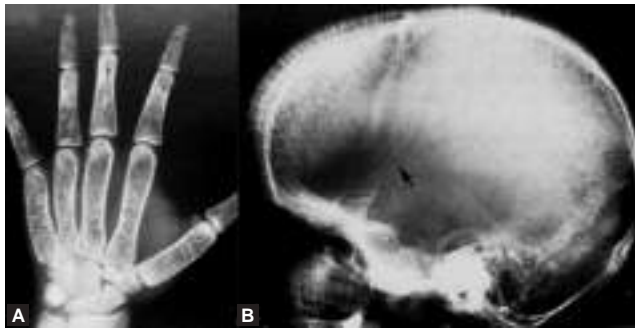
Lateral radiograph of the skull (Fig. 22.5.14A) reveals sclerosis and thickening involving the skull bones especially evident in the frontal bones and anterior cranial fossa. A Rugger-Jersey spine is seen with a bone within bone appearance in a lateral radiograph of the dorsal spine (Fig. 22.5.14B).

Picture	Note
<p><b>Perthes' Disease</b></p>  <p><b>Figure 22.5.15:</b> Perthes' disease</p>	<p>Frontal radiograph of the right hip joint shows flattening, sclerosis and irregularity of the epiphysis with subphyseal cystic changes and metaphyseal remodeling.</p>
<p><b>Rickets</b></p>  <p><b>Figures 22.5.16A and B:</b> Rickets</p>	<p>Frontal radiographs of the knee (Fig. 22.5.16A) and wrist (Fig. 22.5.16B) show splaying of the metaphyses, fraying of the metaphyseal margins and widening of the physal plates.</p>
<p><b>Scurvy</b></p>  <p><b>Figure 22.5.17:</b> Scurvy</p>	<p>Frontal radiograph of the knee reveals sharp sclerotic epiphyseal margins 'Wimberger's sign' with a dense appearing zone of provisional calcification along the growing metaphysis, 'Frankel's line' and a lucent zone underlying this, the 'Trummerfeld zone' representing the lack of mineralized osteoid. 'Pelkan spurs' resulting from fractures at the cortical margins are visualized. Periosteal elevation resulting from subperiosteal hemorrhage is seen, more prominently along the lateral femoral surface.</p>

## Picture

## Note

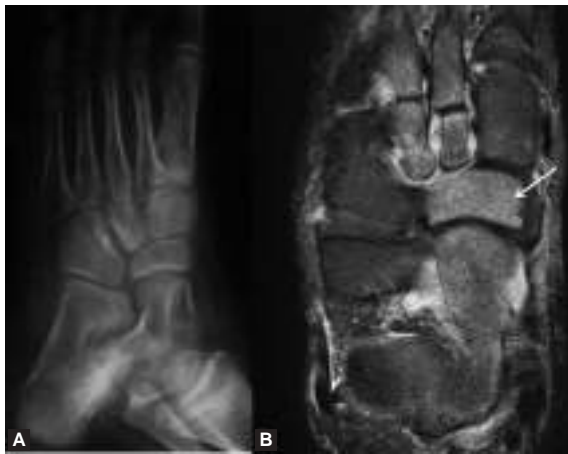## Thalassemia



Figures 22.5.18A and B: Thalassemia

Frontal radiograph of the hand (Fig. 22.5.18A) shows coarse trabeculae with expansion of the bones and thinning of the cortices due to marrow hyperplasia involving the metacarpals and phalanges. Lateral skull radiograph (Fig. 22.5.18B) shows a thickened outer table with the characteristic hair-on-end appearance predominantly involving the frontal region.

## Tuberculosis Ankle



Figures 22.5.19A and B: Tuberculosis ankle

Oblique radiograph of the foot (Fig. 22.5.19A) shows periarticular osteopenia. STIR coronal MRI (Fig. 22.5.19B) reveals marrow edema (arrow) involving the tarsal bones along with peripheral soft tissue edema. Synovial thickening is also seen.

## Tuberculous Dactylitis

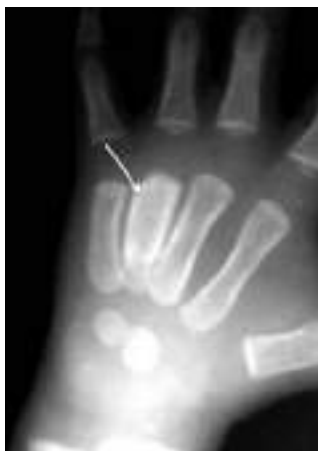

Figure 22.5.20: Tuberculous dactylitis

Frontal radiograph of the right hand and wrist shows expansion of the right fourth metacarpal bone (arrow) with cortical thickening and sclerosis. Marrow expansion may occur.

# Index

Page numbers followed by *f* refer to figure

- A**
- Abandoned  
  newborn with  
    congenital anomalies 342*f*  
    marasmus 342, 342*f*  
    rat bite marks 339, 339*f*  
  distention 10, 10*f*  
  lump 211, 211*f*  
  veins 157*f*
- Abscess 425, 425*f*
- Absent  
  bright postpituitary spot in central diabetes insipidus 236*f*  
  pulmonary valve syndrome 105, 105*f*
- Acanthosis 233, 233*f*  
  nigricans 160*f*, 365, 365*f*  
  in non-alcoholic fatty liver disease 160
- Accessory nipple 307, 307*f*
- Accommodative esotropia 381, 381*f*
- Achalasia cardia 160, 160*f*, 433
- Acholic stools 10, 10*f*
- Achondrogenesis 269, 269*f*
- Achondroplasia 11, 11*f*, 270, 270*f*
- Acne vulgaris 366, 366*f*
- Acrocephalosyndactyly 272, 272*f*
- Acrocyanosis 3, 3*f*
- Acrodermatitis enteropathica 161, 161*f*
- Acute  
  follicular tonsillitis 119, 119*f*  
  hydrocephalus 87  
  laryngotracheobronchitis 119  
  liver failure 163  
  lymphoblastic leukemia 174, 198, 198*f*, 213  
  osteomyelitis 457, 457*f*  
  otitis media 119, 401, 401*f*  
  pancreatitis 147  
  raised intracranial pressure 229, 229*f*  
  respiratory distress syndrome 60, 120, 131  
  septic arthritis 457  
  sinusitis 285
- suppurative otitis media 119*f*  
  urticaria 283
- Adam's  
  apple in boys 305, 305*f*  
  test 329, 329*f*
- Addison's disease 233, 233*f*
- Adenoid  
  facies 120, 120*f*, 401  
  hypertrophy 120*f*
- Adolescent  
  dermatology and sexually transmitted disease 324  
  friendly health services 335, 335*f*  
  scoliosis 328, 328*f*, 329, 329*f*
- Adrenal  
  calcification 166*f*  
  hypoplasia congenital 249*f*  
  tumor 249, 249*f*
- Adrenocorticotrophic hormone 79
- Advanced  
  axillary hair growth in boys 304*f*  
  stage retinoblastoma 219*f*
- Airway foreign body 431
- Alagille syndrome 165, 165*f*
- Alkaline phosphatase 148
- Allergic  
  conjunctivitis 283, 283*f*, 287, 288*f*, 319, 319*f*  
  conjunctival pigments 287  
  Horner-Trantas spots 288  
  limbal gelatinous nodules 288  
  limbus nodules 288  
  gape 289, 289*f*  
  giant papillary conjunctivitis 289, 289*f*  
  line 283, 283*f*  
  mannerisms 289, 289*f*  
  rhinitis 120, 120*f*, 289, 291, 401, 401*f*, 402, 402*f*  
  salute 290, 290*f*  
  shiners 284, 284*f*
- Allergy skin testing 290, 290*f*, 291*f*, 291
- Alopecia areata 359, 359*f*
- Alveolar rhabdomyosarcoma of chest wall 220*f*
- Ambiguous genitalia 15, 15*f*
- Amblyopia 381*f*
- Amplatzer device 111, 111*f*
- Amylase rich foods 42
- Anal agenesis 11, 11*f*
- Androgen insensitivity syndrome 233*f*
- Anemia  
  bone marrow failure syndrome 194, 194*f*  
  child with pallor 183, 183*f*  
  hemolytic 183-192  
  in newborn 199, 199*f*  
  kala-azar 193  
  malaria 193  
  nutritional 194-196, 196*f*  
    iron deficiency anemia 194*f*
- Anencephaly 80  
  with large meningocele 80
- Aneurysmal bone cyst 476, 476*f*
- Angelman syndrome 261, 261*f*
- Angiography 110
- Angular stomatitis 38
- Animal bite injuries in face and scrotum 57*f*
- Anomalous left coronary artery from pulmonary artery 96
- Ano-rectal malformations 438*f*
- Antenatal hydronephrosis 440*f*, 441*f*
- Anterior encephalocele 67, 67*f*
- Antrochoanal polyp 402
- Anxiety 336
- Apert syndrome 90, 90*f*, 272, 272*f*
- Aplasia of corpus callosum 272, 272*f*
- Aplastic anemia 194, 194*f*
- Appendicitis 463, 463*f*
- Appendicolith with bowel obstruction 463, 463*f*
- Apthous ulcers 155*f*
- Aqueductal stenosis 75, 75*f*, 80, 467
- ARDS in dengue hemorrhagic fever 120*f*
- Arnold-Chiari malformation 67
- Arterial switch operation 97, 113
- Arteriovenous malformation 470, 470*f*

- Arthrogryposis multiplex congenital 458, 458*f*  
 Arylsulfatase 85  
 Ashleaf macule 79  
 Askin rosai tumor 211, 211*f*  
 Aspergillous cavity in lung 213, 213*f*  
 Asthma 121, 121*f*  
 Asymmetric crying facies 273, 273*f*  
 Ataxia telangiectasia 70*f*, 277, 277*f*  
 Atopic dermatitis 284, 284*f*, 359*f*  
 Atrioventricular septal defect 101, 101*f*, 115  
 Atypical  
   genitalia 233, 233*f*, 234, 234*f*  
   teratoid rhabdoid tumor of brain 225, 225*f*  
 Autoimmune hemolytic anemia on  
   steroid therapy 199, 199*f*  
 Autologous serum skin test 291, 291*f*  
 Axillary hair  
   growth in boys 304  
   in girls and boys 303
- B**
- Bacterial infections 51  
 Balloon  
   atrial septostomy 113  
   dilatation of pulmonary valve 110, 110*f*  
   mitral valvotomy 110, 110*f*  
 Bardet-Biedl syndrome 272, 272*f*, 395, 395*f*  
 Barrel-chest in ventilated baby 121, 121*f*  
 Bartter's syndrome 178, 178*f*, 179  
 Basal exudates meningitis 68  
 Battered baby syndrome 205, 205*f*  
 Becker's nevus 327, 327*f*  
 Beckwith-Wiedemann syndrome 11, 11*f*, 238, 264, 264*f*, 266  
 Bell's palsy 69, 309  
 Benign  
   childhood epilepsy with  
     centrotemporal spikes 75  
   joint hypermobility syndrome 299  
   the larche 244*f*  
 Bilateral  
   branchial fistula 429*f*  
   dilatation of pelvicalyceal system 169*f*  
   paratracheal lymphadenopathy 130  
   pleural effusion in congenital  
     Chikungunya 125*f*  
   ptosis 77*f*  
 Biliary  
   ascariasis 163, 163*f*  
   atresia 147, 147*f*, 433  
 Bilirubin encephalopathy 12, 12*f*  
 Bitot's spots 160*f*, 318, 318*f*  
 Bladder  
   calculi 441  
   diverticulum 174, 174*f*  
 Bleeding disorder 196-198, 198*f*  
 Blepharophimosis syndrome 395, 395*f*  
 Blood pressure 336  
 Blount's disease 452  
 Body  
   piercing and tattooing 321  
   tattoo 322*f*  
 Bone marrow infiltration with  
   neuroblastoma cells 217*f*  
 Bony metastases in neuroblastoma 217*f*  
 Boy  
   crushing stones 348*f*  
   fixing screws on machine 349*f*  
   with stone hanging from neck 343*f*  
   working in puffed rice factory 348*f*  
   working on  
     street pot hole 348*f*  
     tea stall 352*f*, 352*f*, 353*f*  
 Brachial plexus birth injury 68  
 Branchial  
   cleft cyst 475, 475*f*  
   cyst/sinus 429  
   fistula 409, 409*f*  
 Breast  
   development in girls 303, 304, 304*f*  
   engorgement 3, 3*f*  
 Bronchiectasis 121, 121*f*  
 Bronchiolitis 122, 122*f*  
   obliterans organizing pneumonia 131*f*  
 Bronchogenic cyst 132, 132*f*, 470, 470*f*  
 Bronchopulmonary dysplasia 471, 471*f*  
 Brown syndrome 386, 386*f*  
 Brucellosis 59  
 Budd-Chiari syndrome 147, 147*f*, 463, 463*f*  
 Bulging fissure sign 123, 123*f*  
 Buried penis 234, 234*f*  
 Burkitt's lymphoma 215  
 Burn  
   injury on thighs 346*f*  
   on left leg, buttocks 345*f*  
 Button-battery  
   in stomach endotherapy 163*f*  
   battery ingestion 163
- C**
- Cabot's ring 187  
 Cafè au lait macule 366, 366*f*  
 Calcinosis cutis 296*f*  
 Calculi 441  
 Calf muscle hypertrophy 73, 73*f*  
 Candidiasis 366, 366*f*  
 Capillary  
   leak syndrome 12, 12*f*  
   refill time 3, 3*f*  
*Capnocytophaga canimorsus* 61  
 Caput succedaneum 4, 4*f*  
 Cardiac defects 421  
 Cardiofacial syndrome 273, 273*f*  
 Cardiofaciocutaneous syndrome 273, 273*f*  
 Carpenter syndrome 273, 273*f*  
 Castleman's disease 132, 132*f*  
 Cavitory tuberculosis with necrotizing  
   bronchopneumonia 128, 128*f*  
 Cellulitis 359, 359*f*  
   of nose 122*f*  
 Cellulose acetate electrophoresis 187  
 Central  
   precocious puberty 242*f*  
   with hypothalamic hamartoma 242  
 Cephalhematoma 6, 6*f*  
 Cerebral infarct 72  
 Cervical  
   lymphadenopathy of Hodgkin's  
     lymphoma 215, 215*f*  
   myelomeningocele 67*f*  
   rib 331, 331*f*  
 Characteristic rash of measles 56*f*  
 Chemical injuries 391  
 Cherry red  
   polyp 153*f*  
   spot 90, 90*f*  
 Chest tube drainage 139  
 Chickenpox 16, 16*f*, 53, 53*f*  
   in acute lymphoblastic leukemia 213  
 Child  
   abuse abandoned  
     in pediatric ward 343  
     newborn with congenital  
       anomalies 342  
   abuse  
     child used for entertainment 343  
     girls used for entertainment 343  
     Manchausan's syndrome 346  
   carrying stones 351*f*  
   labor boy  
     crushing stones 348  
     fixing screws on a machine 349  
     working in puffed rice factory 348  
     working in tea stall 352, 353  
     working on street pot hole 348  
   labor child  
     carrying cowdung cakes 351  
     carrying stones 351  
     laborers caught by police from  
       railway station 354  
     selling earrings 354  
     working in garage 351

- working in mines 350
- working in mirchi field 352
- working in workshop/factory 353
- labor children
  - carrying heavy loads/bricks/stones on head 349
  - cleaning utensils 354
  - working in different industries 347
- labor girl
  - carrying earthen pots 350
  - carrying stone on head 347
  - selling flowers, garlands 350
- labor young boy working at construction site 353
- neglect
  - due to maternal neglect 345
  - burns with hot water 346
  - rat bite 339
- nutrition 40*f*
- selling earrings 354*f*
- sexual abuse 342, 342*f*
  - in children statewide data, 2010 341
- with neuropathic bladder postsurgery for spina bifida 443*f*
- working
  - in garage 351*f*
  - mines 350*f*
  - mirchi field 352*f*
  - workshop/factory 353*f*
- Children
  - carrying heavy loads/bricks/stones on head 349*f*
  - washing utensils 354*f*
- Chlordiazepoxide 196
- Chloroma 227, 227*f*
- Choanal atresia 409, 409*f*
- Choledochal cyst 159, 433, 464, 464*f*
- Cholestasis
  - with intense pruritus 148*f*
  - with pruritus 148
- Choreoathetoid CP 72*f*
- Choreoathetosis 72
- Chorioretinitis in cytomegalovirus infection 54*f*
- Choroid tubercles 91, 91*f*
- Chronic
  - bullous dermatosis of childhood 367, 367*f*
  - calcific pancreatitis 155
  - kidney disease 174, 177, 177*f*
    - with genu valgum deformity 174*f*
  - osteomyelitis 449, 449*f*
  - sinusitis 285
- Cidofovir 363
- Ciprofloxacin 196
- Cirrhosis liver 149*f*
- Clarithromycin 196
- Classical polycystic ovary on ultrasound 252*f*
- Cleft
  - lip and palate 425, 425*f*
  - palate 409, 409*f*
- Clitoral hypertrophy 234, 234*f*
- Cloaca 434
- Closed pneumothorax 137
- Clubbing
  - and cyanosis 95, 95*f*
  - of fingers 148, 148
- Coagulopathy in acute liver failure 163
- Coarctation of aorta 97, 97*f*
- Coarse facies and
  - dysostosis multiplex 69
  - and umbilical hernia 69
- Cochlear implant 410, 410*f*
- Cockayne syndrome 265, 265*f*
- Coin in stomach 150
- Cold centrifuge 189*f*
- Collodion baby 17, 17*f*, 367, 367*f*
- Common
  - bile duct 159
  - errors in
    - growth measurements 28
    - recording head circumference 30
    - recording height 29
    - recording length 28, 28*f*
- Community programs 332
- Complete heart block 112, 112*f*
- Comprehensive Welfare Schemes 35
- Condyloma acuminata 328, 328*f*
- Congenital
  - adrenal hyperplasia 15, 235, 235*f*, 242, 253*f*
  - cataract 382
  - cystadenomatoid malformation 431
  - cystic
    - adenoid malformation of lung 431*f*
    - adenomatoid malformation 18, 133, 133*f*, 471, 471*f*
  - diaphragmatic hernia 18, 18*f*, 133, 133*f*, 431, 471, 471*f*
  - dislocation of
    - hip 477, 477*f*
    - knee 453, 453*f*
  - ear 410, 410*f*
  - esophageal stenosis 161
  - fibrosarcoma of foot 225
  - glaucoma 16, 16*f*
  - heart disease 95
  - hepatic fibrosis 161, 161*f*
  - hydrocele 425, 425*f*
  - hypertrophic pyloric stenosis 464, 464*f*
  - hypothyroidism 69, 69*f*
- laryngeal stridor 412*f*
- lobar emphysema 18, 18*f*, 134, 134*f*, 472, 472*f*
- NLD obstruction 382, 382*f*
- pseudarthrosis of tibia 453, 453*f*
- rubella syndrome 57
- scoliosis with skin marker 453, 453*f*
- talipes equinovarus 16, 16*f*, 449, 449*f*
- vertical talus 454, 454*f*
- Conjunctival
  - suffusion in leptospirosis 60*f*
  - telangiectasia 70
- Contact
  - allergic dermatitis to footwear 325, 325*f*
  - dermatitis 6, 6*f*
  - lenses 320
- Continuous positive airway pressure 124
- Contrast-enhanced computerized tomography 147
- Coomb's test 199, 203
- Corneal
  - ulcer 392, 392*f*
  - xerosis 318*f*
- Cornelia de Lange syndrome 90, 90*f*, 91, 91*f*, 265, 265*f*
- Coronary
  - artery dilatation in Kawasaki disease 105, 105*f*
  - heart disease 115
- Corporal punishment by teacher 307, 307*f*
- Corpus callosum agenesis 70, 70*f*, 71, 71*f*
- Corrosive stricture esophagus 148
- Cosmetic
  - contact lenses 320, 320*f*
  - scleral contact lens 320
- Cover test 73
- Cow's milk protein allergy 153
- Cranial auscultation 87
- Craniopharyngioma 235, 467, 467*f*
- Cri du Chat 261, 261*f*
- Crohn's disease 149, 155
- Crouzon syndrome 274, 274*f*, 396, 396*f*
- CT paranasal sinuses 285, 285*f*
- Cushing's
  - disease 236, 236*f*
  - syndrome 249
- Cutaneous
  - larva migrans 360, 360*f*
  - T-cell lymphoma 228*f*
- Cutis laxa 277, 277*f*
- Cyanosis 12, 12*f*
- Cyanotic congenital heart diseases 95
- Cyclic adenosine monophosphate 255
- Cyclophosphamide 194
- Cyclosporin A 194



Cystic hygroma 225, 225*f*, 410, 410*f*, 429, 475, 475*f*  
 Cytomegalovirus 54

## D

Dactylitis in sickle cell anemia 183, 183*f*  
 Dandruff 324, 324*f*  
 Dandy-Walker  
   anomaly 263  
   malformation 274, 274*f*  
   syndrome 80, 467, 467*f*  
 Day care transfusion center 190*f*  
 De Sanctis-Cacchione syndrome 92  
 Deafness 72  
 Decompensated liver disease 149  
 Deletion of 5P terminal 261  
 Dengue 54  
   hemorrhagic fever 54, 54*f*  
   shock syndrome 54  
 Dennis Morgan folds 291, 291*f*  
 Dental  
   braces 313, 313*f*  
   caries 313, 336  
   implant 316, 316*f*  
   malocclusion distocclusion 313, 313*f*  
 Depression 336  
 Dermal leishmaniasis 63*f*  
 Dermatitis medicamentosa 309, 309*f*  
 Dermatomyositis 367, 367*f*  
 Dermatosi of kwashiorkor 37, 37*f*  
 Desferal subcutaneous pump 191, 191*f*  
 Desmoid fibromatosis 226, 226*f*  
 Developmental dysplasia of hip 449, 449*f*  
 Developmentally supportive care 22  
 Device closure of ASD 106  
 Devil's horn 70, 70*f*  
 Dextrocardia with  
   epicardial pacemaker 97, 97*f*  
   situs  
     inversus 98, 98*f*  
     solitus 98, 98*f*  
 Diabetes insipidus 251  
 Diamond Blackfan syndrome 205, 205*f*  
 Diaper dermatitis 360, 360*f*  
 DiGeorge syndrome 114, 143  
 Dilated  
   cardiomyopathy 98, 98*f*, 109*f*  
   esophagus with smooth narrowing at  
     cardia 433*f*  
 Diplegic with convergent squint 72, 72*f*  
 Discoid lupus erythematosus 368, 368*f*  
 Disorder of sex development 441*f*  
 Displaced supracondylar fracture  
   humerus 457*f*  
 Disseminated intravascular coagulation  
   204, 204*f*

Donut sign 164*f*  
 Dorsal dermal sinus 63*f*  
 Double  
   bubble sign 434*f*  
   jointedness 299  
 Down's syndrome 115, 230, 230*f*, 262, 396, 396*f*, 420, 420*f*  
 Doxycycline 196  
 Duane's retraction syndrome 388, 388*f*  
 Duchenne muscular dystrophy 73  
 Duodenal  
   atresia 434, 438*f*  
   ulcer 149, 149*f*  
 Dysgonadotropinemia 237*f*  
 Dyskeratosis congenital 206, 206*f*  
 Dysostosis multiplex 69*f*  
 Dysplastic left kidney with poor function  
   171*f*  
 Dystrophy of nail 206

## E

Ear  
   bleed 415, 415*f*  
   contact dermatitis 321  
   discharge 403, 403*f*  
   perichondritis 321, 321*f*  
   syringing 403  
   tags 411  
   wax 403, 403*f*  
 Early  
   axillary hair growth in boys 3-4*f*  
   Perthes' disease 450  
   pubertal facial hair in boys 304*f*  
   stage retinoblastoma 219*f*  
   tuberculosis of spine 450, 450*f*  
 Ebstein anomaly 102, 102*f*, 106, 106*f*  
 Echocardiographic machine 104, 104*f*  
 Echthyma 360, 360*f*  
 Eczema herpeticum 377, 377*f*  
 Edematous pancreas with areas of  
   necrosis 147*f*  
 Edward syndrome 115, 115*f*  
 Ehlers-Danlos syndrome 277, 277*f*, 299  
 Eisenmenger syndrome 99, 99*f*  
 Ellis-Van Creveld syndrome 270, 270*f*  
 Empyema 122, 432  
 Enamel hypoplasia 72  
 Enchondromatosis 458, 458*f*  
 Enlarged kidney 174  
 ENT examination 404*f*  
 Enterovirus 54  
 Entesitis related arthritis 293, 293*f*  
 Enzyme replacement therapy 268  
 Ependymoma 212, 212*f*  
 Epidermal nevus syndrome 82  
 Epidermolysis bullosa 17, 17*f*, 368, 368*f*

Epispadias 442, 442*f*  
 Epistaxis 415, 415*f*  
 Equipment for  
   asthma therapy 140  
   resuscitation and O<sub>2</sub> therapy 141  
 Erb's palsy 7, 7*f*, 451, 451*f*  
 Erysipelas 361, 361*f*  
 Erythema  
   multiforme 63*f*, 377, 377*f*  
   nodosum 51, 51*f*, 368, 368*f*  
 Erythematous  
   exfoliate lesions 62*f*  
   maculopapular lesions 54*f*  
 Esophageal  
   atresia 134, 134*f*  
   foreign body 413, 413*f*  
   stenosis 161*f*  
   varices 150*f*  
 ET position 19*f*  
 Ethicillin resistant staphylococcal aureus  
   62  
 Ethmoidal polyp 404, 404*f*  
 Ethmoiditis 411  
 Eventration of left dome of diaphragm  
   134*f*  
 Ewing's sarcoma 212, 477, 477*f*  
   of left ulna 212, 212*f*  
   of scapula 212  
 Exomphalos 434, 434*f*  
 Exstrophy 442, 442*f*  
 Extensive thrush during leukemia  
   chemotherapy 214*f*  
 Extracorporeal  
   membrane oxygenation 120, 135  
   short wave lithotripsy 155  
 Extrahepatic portal venous obstruction  
   157  
 Eye of tiger sign 82*f*

## F

Fabry disease 268, 268*f*  
 Facial  
   asymmetry with intestinal  
     lymphangiectasia 165*f*  
   hair development in boys 304  
   nerve palsy 221, 221*f*  
   palsy 404, 404*f*  
   trauma 416, 416*f*  
 Facioscapulohumeral muscular  
   dystrophy 80, 80*f*, 81*f*, 82  
 False foreign body in chest 137, 137*f*  
 Fanconi's  
   anemia 206, 206*f*  
   pancytopenia 278, 278*f*  
 Feeding cues 4, 4*f*  
 Fetomaternal transfusion 199, 199*f*

Fibrous dysplasia 477, 477*f*  
 Fibular hemimelia 454, 454*f*  
 Fine  
   motor skills 32  
   needle aspiration cytology 414*f*  
 Fissure in ano 150, 150*f*  
 Fixed drug  
   eruption 196, 369, 369*f*  
   reaction 196, 196*f*  
 Flaky paint dermatosis 37  
 Flexural eczema 284  
 Fluconazole 196  
 Fluorescence *in situ* hybridization 114, 261, 262  
 Food impaction in esophagus 164  
 Forchheimer spots 57  
 Foreign body  
   aspiration 138, 138*f*  
   bronchus 416, 416*f*  
   right bronchus 138, 138*f*  
   stomach 150  
 Fracture  
   nasal bone 418, 418*f*  
   on upper central incisors 315*f*  
 Fragile X syndrome 278, 278*f*  
 Fragments of extracted tooth 316, 316*f*  
 Fresh frozen plasma 163  
 Frontal encephalocele 63  
 Fungal dermatitis 17, 17*f*  
 Furuncle 361, 361*f*  
 Furunculosis ear 405, 405*f*

**G**

Gallstones 159*f*  
 Gangrene of terminal phalanges 311, 311*f*  
 Gastric ulcer 151, 151*f*  
 Gastroesophageal reflux disease 156  
 Gastrointestinal and hepatobiliary disorders 433  
 Gastroschisis 13, 435  
 Gaucher's disease 200, 200*f*  
 Genitourinary infections 336  
 Genu valgum deformity 174  
 Girl carrying  
   cowdung cakes 351*f*  
   earthen pots 350*f*  
   stone on head 347*f*  
 Glanzmann's thrombasthenia 207, 207*f*  
 Glutamyl transpeptidase 151  
 Glutaric acidemia 81, 81*f*  
 Glycogen storage disorder 151  
 Goiter 237, 237*f*, 336  
 Goldenhar syndrome 397, 397*f*  
 Gonadotropin releasing analog 242  
 Gottron's papules 296*f*

Granuloma 428*f*  
 Grasping and sucking reflexes 27  
 Gratification phenomenon 74, 74*f*  
 Graves' disease 249, 249*f*  
 Griscelli syndrome with  
   hemophagocytosis 278, 278*f*  
 Grommet 405  
 Gross  
   motor skills 32  
   thickening of skin 151*f*  
 Growth  
   hormone deficiency 237, 237*f*  
   retardation 206  
 Guthaka and pan stains 315  
 Gynecomastia 238  
   in Klinefelter syndrome 238*f*

**H**

Habitual constipation 152  
 Hair  
   development in boys 304*f*  
   gel 325, 325*f*  
   perming 325, 325*f*  
 Hairy pinna in PPHI 241*f*  
 Hallermann-Streiff syndrome 265, 265*f*  
 Hallervorden-Spatz disease 82  
 Hand, foot and mouth disease 54, 54*f*, 369, 369*f*  
 Hansen's disease 369, 369*f*  
 Head and neck conditions 429  
 Headache 336  
 Healed vasculitic ulcer 297*f*  
 Health education  
   for teens 332, 332*f*  
   program 40, 40*f*  
 Hearing  
   loss 405, 405*f*  
   screening 21, 21*f*  
 Heart diseases subsections 96  
 Heat shock protein 294  
 Helicobacter pylori 149  
 Hemangioma 370, 370*f*, 411, 411*f*, 426  
 Hematocolpos 464, 464*f*  
 Hematological emergencies 204  
 Hematoma scalp 164*f*  
 Hemihyperplasia 266, 266*f*  
 Hemihypertrophy 238, 238*f*  
 Hemihypomelanosis of Ito 82  
 Hemimegalencephaly 82, 83  
 Hemiplegic CP 72, 73*f*  
 Hemoglobin 336  
 Hemolytic uremic syndrome 205, 205*f*  
 Hemophilia 197, 478, 478*f*  
 Hennekam's syndrome 165  
 Henoch Schönlein purpura 377, 377*f*  
 Hepatoblastoma 226, 226*f*

Hepatosplenomegaly in brucellosis 59*f*  
 Hereditary  
   elliptocytosis 200, 200*f*  
   multiple exostosis 459, 459*f*  
   spherocytosis 201, 201*f*  
   in family 201, 202*f*  
 Herpes  
   encephalitis 87*f*  
   simplex 370, 370*f*  
   virus 55  
   zoster 361, 361*f*  
 Heterotopia 83  
 Hiatus hernia 142  
 Hickman catheter for leukemia therapy 223, 223*f*  
 Hidradenitis suppurativa 327, 327*f*  
 High  
   frequency ventilation 124  
   performance liquid chromatography 188  
 Hilar lymphadenopathy 130  
 Hirschsprung's disease 152, 436  
 HIV 55  
 Hodgkin's lymphoma 215  
 Holoprosencephaly 275, 275*f*  
 Holt-Oram syndrome 275, 275*f*  
 Homogeneous appearance 143  
 Horner-Trantas spots 288, 288*f*  
 Hot  
   cross bun appearance 186, 186*f*  
   spot near umbilicus 438*f*  
 Humane neonatal care 22  
 Hunter syndrome 269*f*  
 Hurler  
   phenotype 69  
   syndrome 268  
 Hyaline membrane disease 472, 472*f*  
 Hydatid cyst 140, 140  
 Hydranencephaly 84  
 Hydrocephalus 74, 74*f*, 75, 426, 426*f*  
 Hydropneumothorax 123*f*  
 Hydrops 13, 13*f*  
 Hypermetropia 382, 382*f*  
 Hypermobility syndrome 299  
 Hyperpigmented nipples 235*f*  
 Hypochromic microcytic anemia 195*f*  
 Hypogammaglobulinemia 205  
 Hypoglycemia screening 21, 21*f*  
 Hypohydrotic ectodermal dysplasia 310, 310*f*  
 Hypomelanosis of Ito 91, 91*f*  
 Hypoparathyroidism causing carpopedal spasm 250, 250*f*  
 Hypopigmentation over bony points 297*f*  
 Hypoplasia of right lung 135, 135*f*  
 Hypopyon 317  
 Hypospadias 442, 442*f*

Hypothyroidism  
 causing pituitary mass 250  
 congenital 239  
 juvenile 239  
 with anemia 202  
 Hypoxic ischemic encephalopathy 70

## I

I-cell disease 268, 268f  
 Iatrogenic—Cushing 235f  
 Iceberg of malnutrition 36, 36f  
 Ichthyosis vulgaris 370, 370f  
 Icthyma gangrenosum with pneumonia 214, 214f  
 Idiopathic  
 hypertrophic pyloric stenosis 436f  
 nephrotic syndrome 172f  
 on long-term steroid therapy 171, 171f  
 with cushingoid features 172  
 scoliosis 454, 454f  
 thrombocytopenic purpura 197, 197f  
 Ileocolonic  
 irregular ulcers on colonoscopy 152f  
 tuberculosis 152  
 Illness intravenous immunoglobulin 61  
 Imaging in herpes encephalitis 87  
 Impaction of Bengal gram in esophageal stenosis 164f  
 Impedance audiometry 406, 406f  
 Imperforate anus 421  
 Impetigo 362, 362f  
 Implantable cardioverter-defibrillator 102  
 Incontinentia pigmenti 92, 92f  
 achromians 91  
 Infant  
 of diabetic mother 7  
 with thalassemia major 184, 184f  
 Infantile  
 esotropia 383, 383f  
 glaucoma 388, 388f  
 Infantometer 243f  
 Infectious diseases 49  
 Infective eczema 371, 371f  
 Infestation of scalp with pediculus humanus capitis 59f  
 Inflammatory bowel disease 158  
 Inguinal hernia 13, 13f, 426  
 Inhaled nitric oxide 124  
 Insect bite allergy 286f, 362, 362f  
 Intermediate and high arm 435f  
 Intermittent exotropia 383, 383f

Interstitial lung disease 135, 135f  
 Intestinal  
 malrotation with midgut volvulus 438f  
 obstruction 465, 465f  
 peritonitis 439f  
 roundworm infestations 437, 437f  
 Intracardiac repair 105  
 Intracytoplasmic sperm injection 262  
 Intrauterine growth retardation 7, 7f  
 Intravenous immunoglobulin 54, 96  
 Intussusception 164, 437, 465, 465f  
 Iron deficiency anemia 194  
 Irregular ulcers skip lesions 149f

## J

Japanese encephalitis 88, 88f  
 Jaundice 8, 8f  
 Jeuno-ileal atresia 437, 437f  
 Joulie's solution 176  
 Juvenile  
 angiofibroma 412, 412f  
 dermatomyositis 296, 296f  
 calcinosis cutis 296  
 nodular swellings 296f  
 hypothyroidism 239f  
 idiopathic  
 arthritis 295, 389, 389f  
 oligoarthritis 293, 293f  
 polyarthritis 294, 294f  
 polyp 153  
 systemic sclerosis 297f  
 healed vasculitic ulcer 297  
 pursed lip appearance 297

## K

Kala-azar 193f  
 Kangaroo care 23, 23f  
 Kasabach-Merritt syndrome 207, 207f  
 Kawasaki disease 61f, 96, 96f, 96, 294, 294f  
 Kayser-Fleischer ring 153  
 Kelly's syndrome 194  
 Keratoconus 319, 319f  
 Keratosis pilaris 371, 371f  
 Kerion 362, 362f  
*Klebsiella* pneumonia 123, 123f  
 Klinefelter syndrome 238, 262, 262f  
 Klippel-Trenaunay-Weber proteus syndrome 82  
 syndrome 311, 311f  
 Kommerell's diverticulum 418, 418f  
 Kwashiorkor 37, 37f

## L

Labial adhesions 427, 427f

Laminar flow 190f  
 Langer syndrome 250, 250f  
 Langerhan's cell histiocytosis 213, 251, 478, 478f  
 Large  
 head Dandy-Walker syndrome 80  
 hemangioma 310, 310f  
 umbilical hernia 162f  
 Laron dwarfism 254, 254f  
 Larsen syndrome 279, 279f  
 Laryngeal papilloma 412, 412f  
 Laryngomalacia 412, 412f  
 LASIK surgery 320, 320f  
 Lawrence-Moon-Biedl syndrome 255  
 Leflunomide 294  
 Left inguinal hernia in  
 female child 426f  
 male child 426f  
 Legg-Calvé-Perthes disease 450  
 Lennox-Gastaut syndrome 75, 75f, 76  
 Leptospirosis 60  
 Leri-Weil dyschondrosteosis 250  
 Leukemia 213, 214, 227  
 cutis 226, 226f  
 Leukocyte filter 190, 190f  
 Leukoplakia 206  
 Levocardia with situs inversus 99, 99f  
 Lichen  
 planus 371, 371f  
 striatus 372, 372f  
 Limb abnormalities 421  
 Limbal gelatinous nodules 288f  
 Limbus nodules 288f  
 Linear  
 nevus sebaceous syndrome 82, 83, 83f  
 scleroderma 298, 298f  
 Lipodystrophy in HIV 62  
 Lissencephaly 84, 84f  
 Lobulated mass with calcification near tail of pancreas 166f  
 Long  
 face syndrome 292, 292f  
 QT syndrome 102, 102f  
 Loss of teeth after accident 315, 315f  
 Low birth weight 23  
 Lung  
 abscess 124, 124f, 472, 472f  
 metastases in rhabdomyosarcoma 222f  
 Lutembacher syndrome 106, 106f  
 Lymphoblastic lymphoma 215, 215f  
 Lymphoma 215, 227, 228, 473, 473f  
 Lymphonodular hyperplasia 153, 153f  
 Lysosomal storage disorders 268

**M**

- Macro-orchidia in hypothyroidism 251, 251*f*
- Malaria 58, 193*f*
- Malignant  
  melanoma 317, 317*f*  
  peripheral nerve sheath tumor 230*f*
- Malnourished child 41
- Malnutrition  
  burden 35  
  in adolescent boy 308, 308*f*
- Malrotation 438  
  with midgut volvulus 154
- Manchaunsan's syndrome 346*f*
- Marasmic kwashiorkor 37, 37*f*
- Marasmus 38, 38*f*
- Marfan's syndrome 279, 279*f*, 312, 312, 397, 397*f*
- Massive  
  abdominal distention 436*f*  
  pleural effusion 229, 229*f*  
  splenomegaly 154, 154*f*
- Maternal uniparental disomy 256
- Matted bowel loops 435*f*
- Mauriac syndrome 240, 240*f*
- Maximum intensity projection 463
- McCune Albright  
  syndrome 252, 255  
  with precocious puberty 252*f*
- Measles 56  
  bronchopneumonia 124, 124*f*
- Meckel's  
  diverticulitis 465, 465*f*  
  diverticulum 438, 438*f*  
  radio-isotope scan 438*f*  
  scan 438
- Meconium  
  aspiration syndrome 124  
  peritonitis 439  
  plug syndrome 14, 14*f*
- Mediastinal lymphadenopathy 230, 230*f*
- Medulloblastoma with acute  
  hydrocephalus 88
- Megaloblastic anemia 195, 195*f*
- Meningitis 468, 468*f*
- Meningocele 14, 14*f*
- Mesial temporal sclerosis 76, 76*f*
- Metabolic screening 22, 22*f*
- Metachromatic leukodystrophy 85, 85*f*
- Method of examination of nose 286, 286*f*
- Methotrexate 294
- Methylprednisolone 194
- Microcephaly 76, 413
- Micronutrient deficiency 38
- Micropenis 240, 240*f*
- Microvascular complications small joint  
  involvement 236
- Miliaria rubra 372, 372*f*
- Miliary tuberculosis of lungs 125
- Miller-Dieker syndrome 92, 92*f*
- Miscellaneous monogenic disorders 276
- Mitral  
  regurgitation 107*f*  
  stenosis 107, 107*f*
- Mobile  
  flat feet 451, 451*f*  
  phone dermatitis 324, 324*f*
- Modern teen tattoo 323, 323*f*
- Molluscum contagiosum 328, 328*f*, 363, 363*f*
- Morphea 372, 372*f*
- Mosaic dermatosis 37
- Mucopolysaccharidosis 268, 268*f*, 269, 269*f*, 478, 478*f*
- Multicystic dysplastic kidney 175, 175*f*
- Multidrug resistant 126
- Multiple  
  bony metastases in  
    rhabdomyosarcoma 221*f*  
  hemangioma 162*f*  
  infantile hemangioma liver 162
- Mumps 56
- Munson's sign 319, 319*f*
- Muscular torticollis 455
- Musculoskeletal syndromes 299
- Myasthenia gravis 77
- Myelomeningocele with sacral agenesis  
  475, 475*f*
- Myopathic facies 85, 85*f*
- Myopia 384, 384*f*
- Myotonic dystrophy 85
- N**
- Nasal  
  dermal sinus 63*f*  
  examination 406, 406*f*  
  polyp 402*f*
- National nutrition programs 35
- Nebulizer 141, 141*f*
- Necrotizing  
  enterocolitis 439, 439*f*  
  fasciitis 427, 427*f*
- Neonatal  
  chickenpox 53*f*  
  cholestasis syndrome 154  
  systemic disorders 10
- Nephrocalcinosis 176
- Nephrotic syndrome on cyclosporine  
  looking normal 173
- Nestor test for thalassemia minor 187*f*
- Neuroblastoma 136, 216, 217, 444
- Neurocysticercus granuloma 468, 468*f*
- Neurodegeneration with brain iron  
  accumulation 82
- Neurofibromatosis 230, 279, 279*f*, 398, 398*f*
- Neuropathic bladder 443
- Nevus anemicus 373, 373*f*
- Newborn screening 21
- Night blindness 255*f*, 318
- Nodular swellings 296*f*
- Nonclassical congenital adrenal  
  hyperplasia 251
- Non-nucleoside reverse transcriptase  
  inhibitors 55
- Nonossifying fibroma 479, 479*f*
- Nonsteroidal anti-inflammatories 196
- Noonan syndrome 115, 115*f*, 255, 255*f*
- Normal newborn 3, 4, 4*f*
- Nucleoside reverse transcriptase  
  inhibitors 55
- Nutrition 308  
  crisis amid prosperity 35*f*  
  education 40, 41  
  status of Indian children 31, 31*f*
- O**
- Obesity 241  
  in boy 308*f*  
  in girl 308*f*
- Obstructive sleep apnea syndrome 401, 421
- Oculogyric spasm 77, 77*f*
- Omphalocele 14, 14*f*, 434*f*
- Open thoracotomy 139
- Operative cholangiography 433*f*
- Ophthalmia neonatorum 392, 392*f*
- Ophthalmology 317
- Optic atrophy 384, 384*f*
- Oral  
  aphthous ulcers 155  
  candidiasis 55*f*  
  chelation therapy 191  
  herpetic lesion 55*f*  
  thrush 8, 8*f*
- Orbital  
  cellulitis 393, 393*f*, 411, 411*f*  
  floor fracture 393, 393*f*  
  rhabdomyosarcoma 222*f*, 389, 389*f*
- Orchidometer 241
- Orientation program for teachers and  
  parents 333, 333*f*, 334, 334*f*
- Orofaciodigital syndrome 276, 276*f*
- Osteochondritis desiccans 331, 331*f*
- Osteogenesis imperfecta 270, 299, 455, 479, 479*f*
- Osteogenic sarcoma 479, 479*f*
- Osteoid osteoma 480, 480*f*
- Osteomyelitis 480, 480*f*
- Osteopetrosis 271, 271*f*, 480, 480*f*
- Osteoporosis syndrome 189

- Osteosarcoma of  
 lower end of left femur 218, 218*f*  
 upper end of left humerus 218, 218*f*
- Ostial stenosis of left renal artery on CT angiography 176, 176*f*
- Ostium secundum 107, 107*f*
- Otoacoustic emissions 413, 413*f*
- Ovarian dermoids 466, 466*f*
- P**
- Pachygyria 83, 276, 276*f*
- Pale and fissured tongue 38
- Palmar erythema 155, 155*f*
- Pan sinusitis 285, 285*f*
- Pancreatic calcification 155, 155*f*
- Paper  
 cellulose acetate 187*f*  
 electrophoresis 187
- Paracetamol 196
- Paraesophageal hiatus hernia 142, 142*f*
- Parasites 58
- Parotid gland enlargement in mumps 56*f*
- Participation in sports important for teens 306
- Patent ductus arteriosus 57
- Peak nasal inspiratory flow meter for assessment of nasal obstruction 292, 292*f*
- Pediculosis capitis 363, 363*f*
- Pediculus humanus capitis 59
- Peer pressure 306, 306*f*
- Pelvic neuroblastoma 217*f*
- Pelvi-ureteric junction obstruction 443, 443*f*
- Penetrating injury 394, 394*f*
- Perianal excoriation 156
- Perinatal insult 468, 468*f*
- Periocular capillary hemangioma 389, 389*f*
- Peripheral  
 blood smear 187, 187*f*  
 pseudoprecocious puberty 252
- Peripherally inserted central catheters 224, 224*f*
- Periventricular  
 leukomalacia 21  
 nodular heterotopia 83, 83*f*
- Persistent  
 anemia in celiac disease 203, 203*f*  
 hyperinsulinemic hypoglycemia of newborn 254
- Perthes' disease 481, 481*f*
- Peutz-Jeghers syndrome 166, 312, 312*f*, 378, 378*f*
- Phimosis 428, 428*f*
- Phlyctenular conjunctivitis 286, 286*f*
- Physiological genu valgum 452, 452*f*
- Piercing of  
 ear 321, 321*f*  
 nose 322, 322*f*
- Pierre-Robin sequence 15
- Pilocytic astrocytoma 469, 469*f*
- Pinna-hematoma 414, 414*f*
- Pituitary microadenoma 236, 236*f*
- Pityriasis  
 alba 363, 363*f*  
 rosea 373  
 versicolor 373, 373*f*
- Pleuroblastoma 136*f*
- Pneumatosis intestinalis 466, 466*f*
- Pneumococcal pneumonia 126
- Pneumocystis*  
*carinii* 55, 55*f*  
*jiroveci* 126, 126*f*  
*pneumonia* 126
- Pneumoperitoneum 19, 19*f*, 466, 466*f*
- Pneumothorax 20, 20*f*, 139, 432
- Polycystic ovary disease 336  
 syndrome 252
- Polycythemia 15, 15*f*
- Polymorphous light eruption 374*f*
- Polyp in left maxillary sinus 285, 285*f*
- Pontine glioma 469, 469*f*
- Popeye appearance 81
- Porencephaly right middle cerebral artery territory 72*f*
- Postnucleation syndrome 220, 220*f*
- Posterior urethral valves 173, 173*f*
- Postextubation collapse 20, 20*f*
- Post-kala-azar dermal leishmaniasis 63
- Poverty line 36
- Prader-Willi syndrome 256, 256*f*, 262, 262*f*
- Pranayama 332, 332*f*
- Preauricular sinus 414, 414*f*
- Precocious puberty 242
- Prepubertal  
 axillary hair 303*f*  
 breasts  
 and axillary hair 303  
 girls 303, 303*f*  
 facial hair 304*f*  
 genitalia 303*f*  
 boys 303*f*  
 girls 303*f*
- Preseptal cellulitis 394, 394*f*
- Prevention of kwashiorkor 42
- Primary complex 126, 126*f*
- Progressive familial intrahepatic cholestasis 151
- Proptosis in  
 Langerhans' cell histiocytosis 213*f*  
 neuroblastoma 216*f*
- Protein-energy malnutrition 37
- Proteus syndrome 266, 266*f*
- Protrusion of umbilicus 428*f*
- Proximal femoral focal deficiency 455, 455*f*
- Prune-belly syndrome 179, 179*f*
- Prurigo nodularis 327, 327*f*
- Pseudoachondroplasia 271, 271*f*
- Pseudoaneurysm  
 communicating with hematoma and bile duct 162  
 hepatic artery 162*f*
- Pseudocyst of pancreas 156, 156*f*
- Pseudohypoparathyroidism 88, 88*f*
- Pseudoprecocious puberty 242, 242*f*, 253, 253*f*
- Pseudostrabismus 385, 385*f*
- Psoriasis 374, 374*f*
- Ptosis 385, 385*f*
- Puberty 238  
 gynecomastia 238*f*
- Pubic hair and testes in boys 305, 305*f*
- Pulmonary  
 agenesis 136, 136*f*  
 alveolar microlithiasis 473, 473*f*  
 AV fistula 111, 111*f*  
 hypertension of newborn 135  
 vascular obstructive disease 101
- Pure tone audiometry 407, 407*f*
- Purpura fulminans 61, 203, 203*f*
- Pursed lip appearance 297*f*
- Pustules 9*f*
- Pyopneumothorax 123
- Q**
- Quantitative fluorescence polymerase chain reaction 262
- Quinine 196
- R**
- Rabies 57  
 immunoglobulin 57
- Rachitic rosary 39, 39*f*
- Radial nerve palsy 86
- Radiological changes of scurvy 39
- Ramsay Hunt syndrome 361
- Ranula 430
- Rat bite 339*f*  
 in an abandoned newborn 339, 339*f*
- Rectal polyp 440, 440*f*
- Rectovestibular fistula 440, 440*f*
- Recurrent bacterial meningitis 63

- Reflux esophagitis 156  
 Removed tattoo 323  
 Renal  
   anomalies 421  
   osteodystrophy 174  
   tubular acidosis 170, 170*f*, 173, 173*f*,  
     242, 242*f*  
 Respiratory  
   distress 127  
   in neonate 127*f*  
   syndrome 127  
   syncytial virus 122  
 Reticulocyte count 196, 196*f*  
 Reticulocytopenia 205  
 Retinitis pigmentosa 390, 390*f*  
 Retinoblastoma 219, 220*f*, 390, 390*f*  
   on CT scan 218, 218*f*  
   with orbital implant 219, 219*f*  
 Retinopathy of prematurity 22, 390, 390*f*  
 Retropharyngeal abscess 127, 127*f*, 419,  
   419*f*  
 Rett syndrome 77, 77*f*  
 Rhabdomyoma in LV 108  
 Rhabdomyosarcoma 221*f*, 222  
   of chest wall 220  
   of left parotid region 221, 221*f*  
   of middle ear 221  
   of right cheek in infant with  
     microcephaly 228*f*  
 Rheumatic fever 96  
 Rickets 39, 481, 481*f*  
 Rickettsial disease over face 60*f*  
 Right  
   adrenal neuroblastoma 216*f*  
   empyema 122*f*  
   low motor neuron facial palsy 69*f*  
   middle lobe collapse consolidation  
     129  
   -sided closed pneumothorax in  
     neonate 137*f*  
   ventricular outflow tract 108  
 Ring enhancing lesion 78, 78*f*  
 Ritonavir 363  
 Rubella 57  
 Rubinstein-Taybi syndrome 263, 263*f*  
 Russell-Silver syndrome 256, 256*f*, 267,  
   267*f*
- S**  
 Sacrococcygeal teratoma 223, 445, 445*f*  
 Salt wasting crisis 253  
 Sarcoma of bone 456, 456*f*  
 Scabies 59, 364, 364*f*  
 Scalloped duodenal mucosa 157, 157*f*  
 Scalp hematoma in neonatal cholestasis  
   syndrome 164  
 Scaphoid abdomen 436*f*  
 Scapular Ewing's sarcoma 212*f*  
 Scarlet fever 52, 52*f*  
 Schizencephaly 84, 84*f*  
 School  
   counseling 334, 334*f*  
   health check-up  
     dental examination 336, 336*f*  
     ENT examination 336, 336*f*  
 Scleral icterus 157, 157*f*  
 Scrofuloderma 52  
 Scurvy 481, 481*f*  
 Seborrheic dermatitis 9, 9*f*, 364, 364*f*  
 Seckel syndrome 267, 267*f*  
 Sectoral heterochromia 317, 317*f*  
 Self-inflicted wounds 308, 308*f*  
 Septal  
   hematoma 419  
   occluder 111  
 Septic arthritis 53  
   in multiple joints 53*f*  
 Sequelae of acne 326, 326*f*  
 Serous otitis media 405  
 Serum ascites albumin gradient 158  
 Severe  
   abuse 340, 340*f*  
   bowing of legs 176, 176*f*  
   deformities of lower limbs 173, 173*f*  
   herpes zoster skin lesion 55*f*  
   perianal excoriation 156*f*  
 Sexual  
   abuse 341  
   maturity rating 303  
 SHOX gene defect 256, 256*f*  
 Sigmoid colon 153  
 Sign of allergic rhinitis 291  
 Silver beaten appearance 89, 89*f*  
 Simple  
   front tooth fracture 314, 314*f*  
   obesity 241*f*  
 Skeletal dysplasia 243, 243*f*, 269  
 Skin  
   peeling 5, 5*f*  
   tags 5, 5*f*  
 Sliding hernia 142  
 Slipped capital femoral epiphysis 458*f*  
 Small vessel vasculitis 310, 310*f*  
 Solid tumors of childhood 444  
 Solitary  
   bone cyst 456, 456*f*  
   rectal ulcer 158, 158*f*  
 Sotos syndrome 267, 267*f*  
 Spider's web 35  
 Spina bifida  
   cystica 68, 68*f*  
   occulta 68
- Splenectomy in thalassemia child 192,  
   192*f*  
 Spondyloepiphyseal dysplasia 271, 271*f*  
 Spondylolisthesis 456  
 Stadiometer 243*f*  
 Staphylococcal  
   pneumonia 128, 128*f*  
   scalded skin syndrome 62, 62*f*  
*Staphylococcus aureus* 9, 62, 122, 311  
 Steeple sign 119*f*  
 Stem cell transplantation in thalassemia  
   192, 192*f*  
 Stenosed renal artery on CT angiography  
   178*f*  
 Steroid resistant nephrotic syndrome 171  
 Stevens-Johnson syndrome 63, 63*f*  
 Strawberry tongue 52*f*  
 Stress management 332, 332*f*  
 Stretched penile length 243, 243*f*  
 Stridor 420*f*  
 Sturge-Weber syndrome 78, 78*f*, 378,  
   378*f*, 398, 398*f*  
 Subarachnoid hemorrhage 89, 89*f*  
 Subconjunctival hemorrhages 444*f*  
 Subcortical heterotopia 83*f*  
 Subcutaneous nodules of anaplastic large  
   cell lymphoma 227, 227*f*  
 Subsection orthopedic 328  
 Superficial abscess 311, 311*f*  
 Supracondylar fracture humerus 457  
 Swyer-James-Macleod syndrome 140,  
   140*f*  
 Syringingear 403*f*  
 Systemic  
   lupus erythematosus 374, 374*f*  
   onset juvenile idiopathic arthritis 295,  
     295*f*  
   sclerosis 375, 375*f*
- T**  
 Tanner's staging 303  
 Tattoo initials 322, 322*f*  
 Technique of administration of intranasal  
   steroids in  
   adolescent 293, 293*f*  
   small child 292, 292*f*  
 Teenage girl with Turner syndrome 114,  
   114*f*  
 Tension pneumothorax 139, 139*f*, 474,  
   474*f*  
 Testicular torsion 443, 443*f*  
 Tetralogy of Fallot 95, 100, 100*f*, 108*f*  
 Thalassemia 187-192, 482, 482*f*  
   child 186  
   intermedia 185, 185*f*  
   major 185, 185*f*  
   with growth retardation 186, 186*f*

Thalassemic child 184, 186, 186*f*  
 Thelarche 244  
 Therapeutic endoscopic retrograde  
 cholangiopancreatography 163  
 Thyroglossal cyst 253, 253*f*, 476, 476*f*  
 Thyroid 414  
   carcinoma in adolescent female 229,  
   229*f*  
   function tests 237  
 Tibia vara 452  
 Tinea  
   capitis 364, 364*f*  
   cruris 375, 375*f*  
 Tongue  
   and lip pigmentation 233*f*  
   tie 415, 415*f*  
 Tonic seizure 76, 76*f*  
 Tonsillar  
   enlargement 287, 287*f*  
   lymphoma 228, 228*f*  
 Tonsillectomy 407, 407*f*  
 Tooth jewelry 314  
 Torticollis 430  
 Total anomalous pulmonary venous  
   return 474, 474*f*  
 Toxic epidermal necrolysis 378, 378*f*  
 Tracheoesophageal fistula 20, 20*f*, 134,  
 421, 432  
 Tracheotomy 420, 420*f*  
 Tram-track sign 78  
 Trauma to front tooth 314, 314*f*  
 Tricuspid atresia 103, 103*f*  
 Tuberculoma 469, 469*f*  
   of right lung 129, 129*f*  
 Tuberculosis  
   ankle 482, 482*f*  
   bilateral paratracheal  
     lymphadenopathy 130*f*  
   hilar lymphadenopathy 130*f*  
   right middle lobe collapse  
     consolidation 129*f*  
   verrucosacutis 375, 375*f*  
 Tuberculous dactylitis 330, 330*f*, 482, 482*f*  
 Tuberos sclerosus 79, 79*f*, 82, 280, 280*f*,  
 376, 376*f*, 470, 470*f*  
 Turner syndrome 257, 257*f*, 263, 263*f*  
 Typical purpuric rash of HSP 295

## U

Ulcerative colitis 158  
 Umbilical  
   granuloma 9, 9*f*  
   hernia 428  
   polyp 428, 428*f*  
 Uncal transtentorial herniation 89  
 Undescended testis 10, 10*f*, 429, 429*f*  
 Untreated congenital hypothyroidism  
   239*f*  
 Uppgaze palsy 72  
 Upper  
   gastrointestinal endoscopy 157  
   gastrointestinal 165  
   lateral incisor 314*f*  
   respiratory tract infection 401  
 Ureterocele 444  
 Urinary  
   calculi 441*f*  
   tract infection 170  
 Urolithiasis 441*f*  
 Urticaria 365, 365*f*

## V

Vactral syndrome 421, 421*f*  
 Vaginal  
   botryoid 222  
   rhabdomyosarcoma 222*f*  
   discharge 5, 5*f*  
 Valley sign of DMD 73, 73*f*  
 Variceal bleeding 165  
 Vascular ring 474, 474*f*  
 Vegetation on aortic valve 109, 109*f*  
 Vein of Galen malformation 87  
 Velocardiofacial syndrome 263, 263*f*  
 Ventricular septal defect 115  
 Vernal keratoconjunctivitis 386, 386*f*  
 Verner-Morrison syndrome 166  
 Vernix caseosa 6, 6*f*  
 Verruca vulgaris 365, 365*f*  
 Vertebral anomalies 421  
 Vesicoureteric reflux 444, 444*f*  
 Video-assisted thoracoscopic surgery  
   122, 139

Villous atrophy  
   duodenal mucosa 159*f*  
   in celiac disease 159  
 Viral  
   conjunctivitis 391, 391*f*  
   infections 53  
   myocarditis 109  
 Vitamin  
   A deficiency 39, 39*f*, 40, 40*f*, 318, 318*f*  
   D  
     deficiency 39  
     resistant rickets 244, 244*f*  
   K deficiency 198, 198*f*  
 Vitiligo 376, 376*f*  
 Vocal nodules 408, 408*f*

## W

Waardenburg syndrome 280, 280*f*  
 Warts in HIV infection 55*f*  
 Webbing of neck 257*f*  
 Wenckebach phenomenon 103, 103*f*  
 Whirlpool sign 154*f*  
 Williams syndrome 264, 264*f*  
 Wilms' tumor 224, 224*f*, 264, 267, 445  
 Wilson's disease 86, 86*f*  
 Wiscott-Aldrich syndrome 208, 208*f*  
 Wolf-Hirschhorn syndrome 264, 264*f*  
 Wolf-Parkinson-White syndrome 103,  
 103*f*  
 Wolman's syndrome 166

## X

Xanthoma tuberosum right knee 309,  
 309*f*  
 Xeroderma pigmentosum 92, 92*f*, 376,  
 376*f*  
 Xerophthalmia 318  
 X-linked anhidrotic ectodermal dysplasia  
   280, 280*f*  
 X-ray scoliosis Cobb's angle 330, 330*f*

## Z

Zidovudine 363